


Analgesic efficacy of the superficial versus deep serratus plane blocks for mastectomy with axillary clearance

A randomized controlled trial

Kok Wang Tan, MD^a, Syarifah Noor Nazihah Sayed Masri, MD^{b,*} , Qurratu Aini Musthafa, BSc^b, Azrin Mohd Azidin, MD^c, Amiruddin Nik Mohamed Kamil, MD^c, Azarinah Izaham, MD^b, Nadia Md Nor, MBBCh, BAO^b

Abstract

Background: The serratus plane block is an effective technique for providing analgesia to patients undergoing breast surgery.

Methods: This prospective, double-blind, randomized study enrolled 60 female patients scheduled for unilateral mastectomy and axillary clearance. The patients received either a superficial serratus plane block or deep serratus plane block. Dermatomal spread was recorded 30 minutes after block administration. Postoperatively, pain visual analog scale (VAS) scores were documented at recovery (time 0), at 30 minutes; and in the ward hourly for 4 hours, and 4-hourly until 24 hours postoperatively. The time to first analgesic rescue and cumulative morphine consumption using patient-controlled analgesia morphine (PCAM) were recorded.

Results: The results showed lower VAS scores at rest (at 1, 2, 3, and 4 hours postoperatively), and during movement (at 1, 2, 3, 4, 8, and 24 hours postoperatively) in the superficial serratus plane block group, $P < .005$. Similarly, cumulative morphine usage was lower in the superficial serratus plane group, $P < .005$. The time to the first rescue analgesic was also significantly longer in the superficial group, $P < .001$. More patients in the superficial serratus plane group achieved greater dermatomal spread at T2 and T7 than those in the deep group.

Conclusions: Superficial serratus plane block provides better analgesic efficacy than deep serratus plane block in mastectomy and axillary clearance.

Abbreviations: ASA = American Society of Anesthesiologists, BMI = body mass index, HR = heart rate, PCAM = patient-controlled analgesia morphine, VAS = visual analog scale.

Keywords: mastectomy, regional anaesthesia, serratus anterior block

1. Introduction

Breast surgery is increasingly common in women. Surgical incision at the breast and axillary areas is associated with significant pain, with high incidence of acute pain progressing to chronic pain in 25% to 60% of patients.^[1] Post-mastectomy pain managed by solely with opioids often lead to side effects of nausea and vomiting. Therefore, regional analgesic techniques are advocated for effective pain management.^[2]

Much data has supported the efficacy of paravertebral blocks in providing thoracic analgesia, however they are not without risks.^[3] In recent years, there has been a need for a simple, safe,

and effective plane block, and the serratus anterior plane block is one that provides ipsilateral paresthesia of the hemithorax.^[4] It has been used to provide analgesia for breast surgery, thoracoscopy, rib fractures, and shoulder surgery.^[5–9]

The serratus anterior plane block is a safe block, and easily performed under ultrasound guidance, by administration of local anesthetic in the plane between serratus anterior and latissimus dorsi muscles, at the mid-axillary line between the 4th and 5th ribs. It can be performed either superficial, or deep to the serratus muscle, as described by Blanco.^[4]

Local anesthetic deposited superficial or deep to the serratus anterior muscle, specifically targets the lateral cutaneous

This study was funded by Fundamental Grant, Universiti Kebangsaan Malaysia: FF-2019-003.

Informed consent was obtained from all subjects involved in the study.

The authors have no conflicts of interest to disclose.

The datasets generated during and/or analyzed during the current study are available from the corresponding author on reasonable request.

The study was conducted in accordance with the Declaration of Helsinki, and approved by the Medical Research and Ethics Committee of Universiti Kebangsaan Malaysia Medical Centre (FF-2019-003) on 12 December 2018 and the Medical Research & Ethics Committee (MREC) under Clinical Research Centre (CRC), National Medical Research Register (NMRR-18-2157-42354), Ministry Of Health (MOH) Malaysia on March 20, 2019.

^a Department of Anaesthesiology & Intensive Care, Hospital Tuanku Jaafar Seremban, Negeri Sembilan, Malaysia, ^b Department of Anaesthesiology & Intensive Care, Universiti Kebangsaan Malaysia Medical Centre, Kuala Lumpur, Malaysia, ^c Department of Anaesthesiology & Intensive Care, Hospital Kuala Lumpur, Kuala Lumpur, Malaysia.

*Correspondence: Syarifah Noor Nazihah Sayed Masri, Department of Anaesthesiology & Intensive Care, Universiti Kebangsaan Malaysia Medical Centre, 56000 Kuala Lumpur, Malaysia (e-mail: syarifahnazihah@yahoo.com.my).

Copyright © 2022 the Author(s). Published by Wolters Kluwer Health, Inc. This is an open-access article distributed under the terms of the Creative Commons Attribution-Non Commercial License 4.0 (CCBY-NC), where it is permissible to download, share, remix, transform, and build up the work provided it is properly cited. The work cannot be used commercially without permission from the journal.

How to cite this article: Tan KW, Masri SNNS, Musthafa QA, Azidin AM, Kamil ANM, Izaham A, Nor NM. Analgesic efficacy of the superficial versus deep serratus plane blocks for mastectomy with axillary clearance: A randomized controlled trial. *Medicine* 2022;101:35(e30515).

Received: 7 February 2022 / Received in final form: 3 August 2022 / Accepted: 5 August 2022

<http://dx.doi.org/10.1097/MD.00000000000030515>

branches of the thoracic intercostal nerves.^[4] The block is a technically easier alternative to the multiple puncture intercostal, epidural and paravertebral blocks for breast surgery, and provides simultaneous blockade of multiple dermatomes, with lower incidence of adverse events.^[10]

This study assessed the analgesic efficacy, opioid consumption, and dermatomal spread of these two regional blocks. We hypothesized that the superficial serratus plane block was superior in analgesic efficacy to the deep serratus plane block for mastectomy and axillary clearance surgery.

2. Materials and Methods

2.1. Design and setting

This multicenter prospective clinical trial adhered to Consolidated Standards of Reporting Trials guidelines and was approved by the Dissertation Committee of the Department of Anesthesiology and Intensive Care, Universiti Kebangsaan Malaysia Medical Centre (UKMMC), the Medical Research and Ethics Committee (MREC), UKMMC (FF-2019-003), and the MREC, Clinical Research Centre, National Medical Research Register (NMRR-18-2157-42354), Ministry Of Health Malaysia (<https://bit.ly/39BGUis>).

2.2. Participants

Adult female patients of American Society of Anesthesiologists I or II clinical status, scheduled for unilateral mastectomy with axillary clearance, were recruited. Excluded were patients with body mass index more than 40 kg/m², history of opioid dependence, coagulopathy, allergy to amide local anesthetic, local infection at the blockade site, pregnancy and sensory deficit of the anterolateral chest wall. Data were collected from Kuala Lumpur Hospital and UKMMC from January to June 2020.

Consent was obtained during the premedication round, where the patient was briefed on the visual analog scale (VAS) that ranged from 0 (“no pain”) to 10 (“worst conceivable pain”). The patient was fasted for at least 6 hours prior to surgery, and no sedative premedication was served.

2.3. Randomization

The patient was randomly assigned by medical officers blinded to the study, to the superficial serratus plane block or the deep serratus plane block groups with 1:1 allocation ratio, using a computer-generated list of numbers. The group allocation was sealed in an envelope, attached with the anesthesia assessment form. The primary investigator unsealed the envelope and performed the block allocated to the patient. The patient and acute pain service medical officers were blinded to the intervention.

2.4. Intervention

At the regional anesthesia corner, standard patient monitoring which included the non-invasive blood pressure, pulse oximetry, and electrocardiography, was instituted. An 18-G intravenous (IV) cannula was inserted on the contralateral side of surgery.

Both blocks were performed under ultrasound guidance under aseptic technique. The site to be blocked was cleaned with 2% chlorhexidine and draped. A high-frequency linear, Sonosite M-Turbo ultrasound transducer, covered with sterile sheath was placed at the mid-axillary line corresponding to the level of the 5th rib. The skin was infiltrated with 5 mL of lignocaine 2%. A 100-mm SonoPlex 22G PAJUNK® needle was introduced and advanced in the plane between the latissimus dorsi and serratus anterior muscle (superficial serratus plane block), or deep to the serratus anterior muscle (deep serratus plane block). Both

groups were administered 30 mL of ropivacaine 0.375%, and the spread of local anesthetic visualized in real time. The dermatomal distribution of sensory loss was assessed by skin prick testing 30 minutes after the block.

In the operating room, all patients were administered IV propofol 2 to 3 mg/kg and fentanyl 2 µg/kg. The ProSeal® laryngeal mask airway was inserted based on the patient’s mouth opening range and body weight, after adequate depth of anesthesia was achieved. General anesthesia was maintained with sevoflurane at a minimum alveolar concentration of 1.0 to 1.2, in 1:1 oxygen/air ratio.

All patients received IV morphine 0.1 mg/kg as analgesia intra-operatively. Heart rate (HR) and mean arterial blood pressure was maintained within 20% of the preoperative baseline values. Any patients perceived to be in pain, suggested by increase in mean arterial pressure or HR of >20% of baseline values, was administered bolus doses of IV fentanyl 50 µg, titrated to effect. At the end of surgery, the patient the ProSeal® laryngeal mask airway was removed and the patient sent to the recovery area.

Blood pressure, HR, oxygen saturation (SpO₂), and the VAS pain score were monitored and recorded. Patient-controlled analgesia morphine (PCAM) was initiated upon arrival at the recovery area (time 0). The time to first analgesic rescue (from time 0 until the first dose of morphine delivered via PCAM) was documented. The VAS score at rest and during ipsilateral arm movement (operated side), and the amount of PCAM usage were documented.

In the ward postoperatively, standardized oral analgesics (tramadol 50 mg 8-hourly, and paracetamol 1 g 6-hourly) were administered to all patients. The primary outcome was VAS score at rest and with movement, recorded hourly for the first 4 hours, and 4-hourly thereafter until 24 hours postoperatively. Secondary outcomes were cumulative morphine consumption via PCAM over 24 hours postoperatively, time of first rescue analgesia from PCAM, and dermatomal distribution of sensory loss. Block related complications such as pneumothorax, accidental vascular puncture, or hematoma at the block site were recorded. The acute pain service team reviewed the patients and recorded these observations.

2.5. Sample size calculation

Sample size was calculated using the Power and Sample Size Calculations® program for Windows (version 3.0; Vanderbilt University, TN). Based on a prior study which compared the superficial serratus plane block versus local wound infiltration for breast surgery among female patients^[11]; median VAS score with the superficial serratus plane block was 2 [2–3], and with local wound infiltration, VAS score was 8 [7–10]. A total of 60 patients inclusive of a 10% dropout, was required for a study power of 80%, and α -value of 0.05. Patients in whom VAS score could not be assessed due to reasons such as postoperative delirium, ventilation or intensive care unit admission were considered dropouts.

2.6. Statistical analysis

Data were analyzed using IBM® SPSS® Statistics Windows (version 23.0; IBM Corporation, NY). Results are presented as mean ± standard deviation, median (interquartile range), and frequency (percentages), as appropriate. The independent *t* test and Mann–Whitney *U* test for between-group analysis were used for normally and not-normally distributed continuous data respectively. Repeated measure analysis of variance was used for intra-group analysis where applicable. The chi-squared test was used for categorical variables. Pearson’s correlation coefficient was used to analyze the relationship between dermatomal spread and cumulative morphine consumption. Statistical significance was set at $P < .05$.

3. Results

Of the 60 patients recruited, two patients were dropped out due to postoperative delirium. The details are provided in Figure 1 (Consolidated Standards of Reporting Trials diagram).

Table 1 shows that demographic and surgical data between the two groups were comparable.

Tables 2 and 3 show the mean VAS scores at rest and during movement. Postoperative VAS scores at rest were significantly lower at 1, 2, 3, and 4 hours ($P = .019$, $P = .005$, $P = .003$, and $P = .001$, respectively) in the Superficial Group. Similarly, VAS on movement were also significantly lower in the Superficial Group at 1, 2, 3, 4, 8, and at 24 hours postoperatively ($P =$

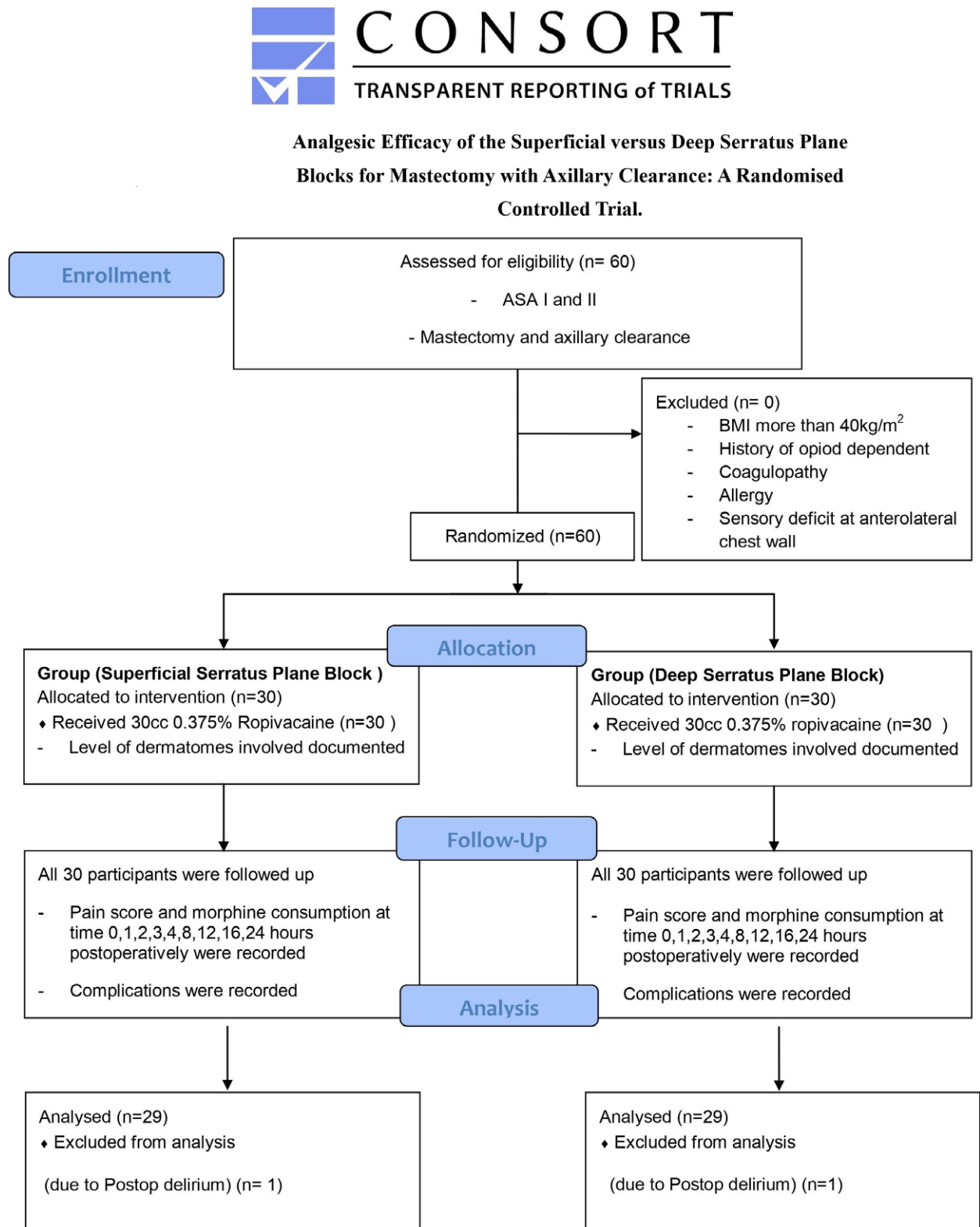


Figure 1. The CONSORT flow diagram describing patient progress through the study. CONSORT = Consolidated Standards of Reporting Trials.

Table 1
Patient demographic and surgical data.

	Superficial group (n = 29)	Deep group (n = 29)	P value
Age (yr)	56.5 ± 9.3	57.7 ± 9.7	.61
ASA physical status			.72
I	5 (17.2)	4 (13.8)	
II	24 (82.8)	25 (86.2)	
Weight (kg)	66.5 ± 14.3	63.2 ± 11.9	.39
Height (cm)	155.5 ± 4.9	155.1 ± 5.30	.44
BMI (kg/m ²)	27.2 ± 4.9	27.14 ± 4.40	.95
Surgical duration (min)	86.3 ± 27.9	81.4 ± 23.9	.48
Intraoperative morphine (mg)	4.8 ± 0.8	4.5 ± 0.6	.08

Data expressed as mean ± SD or n (%).

Table 2
VAS pain score at rest.

Time frame in hours (h)	Superficial group (n = 29)	Deep group (n = 29)	P value
0	0.9 ± 1.4	1.4 ± 1.6	.202
0.5	1.7 ± 1.8	2.1 ± 1.6	.357
1	1.4 ± 1.4	2.3 ± 1.4	.019*
2	1.1 ± 1.1	2.0 ± 1.2	.005*
3	1.1 ± 1.0	1.9 ± 1.1	.003*
4	0.9 ± 0.9	1.7 ± 1.0	.001*
8	0.8 ± 0.9	1.2 ± 1.0	.099
12	0.7 ± 0.8	0.9 ± 0.9	.293
16	0.5 ± 0.6	0.8 ± 0.6	.099
20	0.4 ± 0.5	0.7 ± 0.6	.065
24	0.4 ± 0.5	0.6 ± 0.6	.108

Data expressed in mean ± SD.

*denotes significant value.

Table 3
VAS pain score during movement.

Time frame in hours	Superficial group (n = 29)	Deep group (n = 29)	P value
0	1.8 ± 2.0	2.0 ± 2.0	.656
0.5	2.8 ± 1.8	3.2 ± 1.7	.415
1	2.5 ± 1.4	3.5 ± 1.3	.004*
2	2.3 ± 1.1	3.2 ± 1.1	.004*
3	2.1 ± 1.1	2.8 ± 1.1	.014*
4	1.9 ± 1.1	2.6 ± 1.0	.015*
8	1.6 ± 0.9	2.3 ± 0.9	.013*
12	1.6 ± 0.9	1.9 ± 0.8	.295
16	1.3 ± 0.7	1.5 ± 0.7	.207
20	1.1 ± 0.7	1.2 ± 0.6	.350
24	0.9 ± 0.6	1.2 ± 0.6	.027*

Data expressed in mean ± SD.

*denotes significant value.

.004, $P = .004$, $P = .014$, $P = .015$, $P = .013$, and $P = .027$, respectively).

Figure 2 shows that mean cumulative morphine consumption in the superficial group was significantly lower than that in the deep group at 0, 0.5, 1, 2, and 24 hours postoperatively.

Cumulative morphine usage was 0.2 ± 0.5 versus 0.7 ± 0.7 ($P = .002$), 1.2 ± 1.2 versus 2.0 ± 1.2 ($P = .024$), 1.9 ± 1.1 versus 2.6 ± 1.4 ($P = .044$), 2.2 ± 1.2 versus 2.9 ± 1.5 ($P = .044$), and 3.3 ± 1.9 versus 4.4 ± 1.9 ($P = .042$), at 0, 0.5, 1, 2, and 24 hours respectively. The time before first analgesic rescue was also significantly later postoperatively in the superficial group at 35 (30–45), versus 20 (15–27.5) minutes in the deep group, $P < .001$.

Table 4 shows the extent of dermatomal spread at the anterior, lateral and posterior aspects of the hemithorax between both groups. The chi-squared test showed a greater area of sensory loss in the superficial group. Significantly more patients in the superficial group had sensory loss at T2 dermatome of the anterior hemithorax ($P = .03$), and at T7 dermatomes of the anterior, lateral and posterior aspects of the hemithorax ($P < .001$)

4. Discussion

This study demonstrated that the superficial serratus plane block produced better analgesic efficacy than the deep serratus plane block in terms of, VAS pain scores ($P < .005$), morphine consumption ($P < .005$), time to first analgesic rescue ($P < .001$) and dermatomal spread of sensory block ($P < .005$, $P < .001$) for mastectomy with axillary clearance. Studies have reported that the superficial serratus plane block can significantly reduce pain associated with chest tumor surgery.^[12,13] In this study, despite the statistically lower VAS scores at rest and movement in the superficial group, this was clinically insignificant as mean VAS scores were < 4 in both groups. Both superficial and deep serratus anterior plane blocks produced sufficient analgesia for mastectomy and axillary clearance, as concluded by Razek et al^[14] in 2018.

Abdallah et al,^[15] however, found comparable pain score and opioid consumption between the superficial and deep serratus plane blocks. Their study included a variety of breast surgeries namely mastectomy alone, or with sentinel lymph node biopsy or axillary lymph node dissection; and partial mastectomy with sentinel lymph node biopsy or axillary lymph node dissection. Axillary lymph node dissection or clearance involved extension of the surgical incision to the lateral aspect of the hemithorax, where the superficial serratus plane block would provide adequate analgesic coverage, but not the deep serratus plane block.^[16] Their patients who did not have axillary clearance may not have benefited from the added analgesic coverage provided by the superficial serratus plane block, hence possibly accounting for the comparable results. In our study, all the patients had mastectomy and axillary clearance. This may explain the significant analgesic advantage of the superficial serratus plane block over the deep serratus plane block in our patients.

In contrast, Edwards et al found a 30% decrease in opioid consumption over a 24-hour period post-block, and lower pain scores at 12 hours in the deep serratus plane block group, for either unilateral or bilateral mastectomy, with or without tissue expander placement, and with or without axillary node dissection.^[17] They proposed that a possible explanation for the better analgesia may be the ease at which “good” spread within the deep serratus anterior plane is obtained as the needle tip often touches the rib, as opposed to the superficial serratus anterior plane where a potential space must be opened between two muscles.^[18] In addition, Edwards et al had fewer patients with axillary clearance so the potential improved analgesic effect of superficial block may not have been appreciated.

Qiu et al observed a more stable and longer lasting analgesic effect of the superficial serratus plane block compared to the deep serratus plane block, post thoracoscopic lobectomy. Upper limb movement, and serratus anterior muscle contraction after thoracoscopic surgery or with inspiration, may irritate the

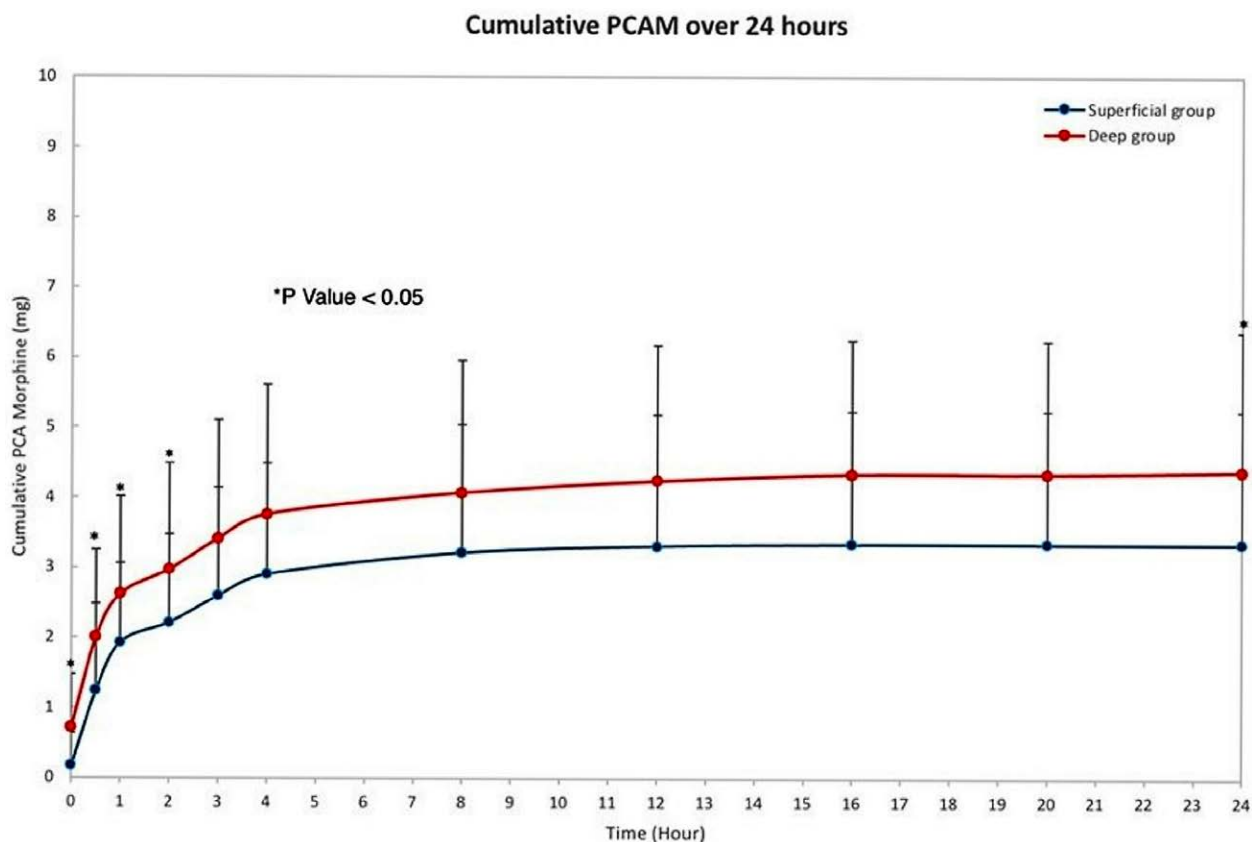


Figure 2. Cumulative morphine consumption between superficial versus deep serratus anterior block within 24 hours.

Table 4
Extent of dermatomal spread.

Dermatome level	Anterior			Lateral			Posterior		
	Superficial group (n = 29)	Deep group (n = 29)	P value	Superficial group (n = 29)	Deep group (n = 29)	P value	Superficial group (n = 29)	Deep group (n = 29)	P value
T1	0	0	-	0	0	-	0	0	-
T2	17 (58.6)	9 (31)	.03*	14 (48)	9 (31)	.18	10 (34.5)	6 (20.7)	.24
T3	29 (100)	29 (100)	-	29 (100)	29 (100)	-	29 (100)	29 (100)	-
T4	29 (100)	29 (100)	-	29 (100)	29 (100)	-	29 (100)	29 (100)	-
T5	29 (100)	29 (100)	-	29 (100)	29 (100)	-	29 (100)	29 (100)	-
T6	29 (100)	27 (100)	.15	29 (100)	26 (100)	.07	28 (99.6)	25 (86)	.16
T7	25 (86.2)	5 (17.2)	<.001*	19 (65)	4 (13.8)	<.001*	11 (38)	2 (6.9)	<.001*
T8	0	0	-	0	0	-	0	0	-

Data expressed as n (%).

injured intercostal muscles and increase their tension, predisposing to postoperative pain. The serratus anterior muscle is innervated by the long thoracic nerve which lies on its surface. The superficial serratus plane block can potentially completely or partially block this nerve while blocking the anterior branches of intercostal nerves. In contrast, because of their origin and trajectory, the long thoracic nerve cannot be blocked by the deep serratus plane block.^[16]

In this study, the median time to first analgesia rescue was longer in the superficial serratus block group ($P < .001$), which was similar to that observed in the case series reported by Bhoi et al^[19] An earlier study by Blanco’s among healthy volunteers found longer duration of paresthesia with the superficial than the deep serratus plane block, where mean duration (SD)

of paresthesia was 752 (21) minutes and 386 (160) minutes, respectively.^[4] Abdallah however found no difference in time to first analgesic request between the blocks.^[15]

In this study, all patients in both groups showed dermatomal spread from T2 to T6, with significantly more patients in the superficial group with cephalad dermatomal spread to T2 and caudally to T7. Blanco et al demonstrated dermatomal paresthesia from T2 to T9 with both superficial and deep serratus plane blocks administered to four healthy subjects. The superficial serratus plane block provides adequate pain relief along T2 to T9.^[4] The serrato-costal fascia of the serratus anterior muscle as thickest at the inferior angle of the scapula, which gradually thins out as it extends to the origin of the serratus anterior muscles.^[20] Cellular content and matrix density of

fascial extracellular fluid affects fascial function. Hyaluronan acid, the most important glycosaminoglycan affecting gliding functions of the fasciae, can alter its concentration, density, and viscosity. The thickness of loose connective tissue increases with increase in density and viscosity, hence leading to less fascial flexibility.^[21] We hypothesized that the fascia deep to serratus anterior muscle may comparatively have denser extracellular matrix than the overlying fascia, due to its gliding movement on the chest wall, and its microscopic myofascial changes as it inserts to the ribs. The denser myofascial matrix texture may provide higher resistance to local anesthetic spread along its plane, hence limiting its distribution. The overlying fascia in contrast, may offer comparatively low resistance to local anesthetic spread due to the presence of loose myofascial matrix content, hence enabling more extensive spread. These differences may explain the difference in extent of dermatomal parathesia between the two blocks.

This study showed that 30 mL of local anesthetic provided sufficient analgesia with adequate coverage of dermatomes. Dermatomal spread is also dependent on local anesthetic volume, where Biswas et al^[22] and Kunigo et al,^[23] greater dermatomal spread to T1 and T8 with 40 mL of local anesthetic.

This study had some limitations. The total duration of analgesia provided by both superficial and deep serratus plane blocks was not studied. In addition, we did not seek feedback from the surgeon regarding possible problems associated with the superficial serratus plane block during axillary interventions (i.e., sentinel lymph node biopsy and axillary lymph node dissection), such as disruption of surgical tissue planes due to axillary spread, unintentional block of the motor long thoracic and thoracodorsal nerves, hindering preservation of these nerves during surgery, and inadvertent needling into metastatic nodes risking tumor seeding.^[24] This raises the justification for the superficial serratus plane block which resulted in statistically improved VAS which was not clinically significant, but at the expense of these surgical complications. On the other hand, the superficial serratus plane block provides successful analgesia without the potentially hazardous need for advancing the needle deeper toward the pleura.^[4,25]

5. Conclusions

The superficial serratus plane block resulted in better analgesic efficacy in terms of VAS pain scores and opioid consumption, compared to the deep serratus plane block in mastectomy with axillary clearance.

Author contributions

Conceptualization: Kok Wang Tan, Syarifah Noor Nazihah Sayed Masri.

Data curation: Amiruddin Nik Mohamed Kamil.

Formal analysis: Qurratu Aini Musthafa.

Funding acquisition: Nadia Md Nor.

Investigation: Kok Wang Tan, Azrin Mohd Azidin.

Methodology: Kok Wang Tan, Syarifah Noor Nazihah Sayed Masri, Azrin Mohd Azidin.

Project administration: Kok Wang Tan.

Resources: Amiruddin Nik Mohamed Kamil.

Software: Amiruddin Nik Mohamed Kamil.

Supervision: Syarifah Noor Nazihah Sayed Masri, Azrin Mohd Azidin.

Validation: Qurratu Aini Musthafa, Azarinah Izaham.

Visualization: Amiruddin Nik Mohamed Kamil, Azarinah Izaham.

Writing – original draft: Kok Wang Tan.

Writing – review & editing: Syarifah Noor Nazihah Sayed Masri, Azarinah Izaham, Nadia Md Nor.

Acknowledgments

We would like to thank the Director-General of Health, Ministry of Health Malaysia, for permission to publish this article.

References

- Andersen KG, Kehlet H. Persistent pain after breast cancer treatment: a critical review of risk factors and strategies for prevention. *J Pain*. 2011;12:725–46.
- Bolin ED, Harvey NR, Wilson SH. Regional anesthesia for breast surgery: techniques and benefits. *Curr Anesthesiol Rep*. 2015;5:217–24.
- Coveney E, Weltz CR, Greengrass R, et al. Use of paravertebral block anesthesia in the surgical management of breast cancer: experience in 156 cases. *Ann Surg*. 1998;227:496–501.
- Blanco R, Parras T, McDonnell JG, et al. Serratus plane block: a novel ultrasound-guided thoracic wall nerve block. *Anaesthesia*. 2013;68:1107–13.
- Ohgoshi Y, Yokozuka M, Terajima K. Serratus-intercostal plane block for breast surgery. *Masui*. 2015;64:610–4.
- Madabushi R, Tewari S, Gautam SK, et al. Serratus anterior plane block: a new analgesic technique for post-thoracotomy pain. *Pain Physician*. 2015;18:E421–4.
- Kunhabdulla NP, Agarwal A, Gaur A, et al. Serratus anterior plane block for multiple rib fractures. *Pain Phys*. 2014;17:E553–5.
- Womack J, Varma MK. Serratus plane block for shoulder surgery. *Anaesthesia*. 2014;69:395–6.
- May L, Hillermann C, Patil S. Rib fracture management. *BJA Educ*. 2015;16:26–32.
- Tighe SQ, Karmakar MK. Serratus plane block: do we need to learn another technique for thoracic wall blockade? *Anaesthesia*. 2013;68:1103–6.
- Shokri H, Kasem AA. Efficacy of postsurgical ultrasound guided serratus intercostal plane block and wound infiltration on postoperative analgesia after female breast surgeries. A comparative study. *Egypt J Anaesth*. 2017;33:35–40.
- Chen G, Li Y, Zhang Y, et al. Effects of serratus anterior plane block for postoperative analgesia after thoracoscopic surgery compared with local anesthetic infiltration: a randomized clinical trial. *J Pain Res*. 2019;12:2411–7.
- Takimoto K, Nishijima K, Ono M. Serratus Plane block for persistent pain after partial mastectomy and axillary node dissection. *Pain Physician*. 2016;19:E481–6.
- Razek A, AbouAllo M, El Hamid SA, et al. Ultrasound-guided pectoral nerve blocks versus serratus intercostal plane block in breast surgeries. *Res Opin Anesth Intensive Care*. 2018;5:162–9.
- Abdallah FW, Cil T, MacLean D, et al. Too deep or not too deep?: a propensity-matched comparison of the analgesic effects of a superficial versus deep serratus fascial plane block for ambulatory breast cancer surgery. *Reg Anesth Pain Med*. 2018;43:480–7.
- Qiu L, Bu X, Shen J, et al. Observation of the analgesic effect of superficial or deep anterior serratus plane block on patients undergoing thoracoscopic lobectomy. *Medicine (Baltim)*. 2021;100:e24352.
- Edwards JT, Langridge XT, Cheng GS, et al. Superficial vs. deep serratus anterior plane block for analgesia in patients undergoing mastectomy: a randomized prospective trial. *J Clin Anesth*. 2021;75:110470.
- Piracha MM, Thorp SL, Puttanniah V, et al. “A Tale of Two Planes”: deep versus superficial serratus plane block for postmastectomy pain syndrome. *Reg Anesth Pain Med*. 2017;42:259–62.
- Bhoi D, Selvam V, Yadav P, et al. Comparison of two different techniques of serratus anterior plane block: a clinical experience. *J Anaesthesiol Clin Pharmacol*. 2018;34:251–3.
- Lung K, St Lucia K, Lui F. Anatomy, Thorax, Serratus Anterior Muscles. In: StatPearls [Internet]. Treasure Island (FL): StatPearls Publishing; 2022. Available at: <https://www.ncbi.nlm.nih.gov/books/NBK531457/>.
- Fede C, Pirri C, Fan C, et al. A closer look at the cellular and molecular components of the deep/muscular fasciae. *Int J Mol Sci*. 2021;22:1411.
- Biswas A, Castanov V, Li Z, et al. Serratus plane block: a cadaveric study to evaluate optimal injectate spread. *Reg Anesth Pain Med*. 2018;43:854–8.
- Kunigo T, Murouchi T, Yamamoto S, et al. Injection volume and anesthetic effect in serratus plane block. *Reg Anesth Pain Med*. 2017;42:737–40.
- Loughran CF, Keeling CR. Seeding of tumour cells following breast biopsy: a literature review. *Br J Radiol*. 2011;84:869–74.
- Bhoi D, Selvam V, Yadav P, et al. Comparison of two different techniques of serratus anterior plane block: a clinical experience. *Letter To Editor. J Anaesthesiol Clin Pharmacol*. 2018;34:251–3.