

Cutaneous Miliary Tuberculosis in a Chronic Kidney Disease Patient

Pudit Suraprasit Narumol Silpa-archa Daranporn Triwongwanat

Department of Dermatology, Siriraj Hospital, Mahidol University, Bangkok, Thailand

Key Words

Tuberculosis · Cutaneous · Cutaneous miliary tuberculosis · Chronic kidney disease

Abstract

A 79-year-old Thai woman with advanced renal failure, dyslipidemia and anemia of chronic disease was admitted to hospital with prolonged fever, productive cough and multiple discrete small pustules on her face, trunk and extremities. A chest X-ray revealed diffuse miliary infiltration. *Mycobacterium tuberculosis* complex DNA was detected by polymerase chain reaction in sputum and scrapings of pustules from her skin. Blood culture identified *M. tuberculosis* complex. Pulmonary and cutaneous miliary tuberculosis was diagnosed. The patient's symptoms improved after 3 weeks of treatment with isoniazid, rifampicin, ethambutol and pyrazinamide. This report details a case of cutaneous miliary tuberculosis in a non-dialysis chronic kidney disease patient.

© 2014 S. Karger AG, Basel

Introduction

Tuberculosis is a common cause of mortality worldwide. Globally, the incidence of all forms of tuberculosis infection was approximately 1.2 million cases per year between 1990 and 2013 [1]. Extrapulmonary tuberculosis infection accounts for 5.8–44.4% of all tuberculosis cases [2]. This form of tuberculosis affects the lymph nodes, pleura, urinary tract, bones, joints, eyes and skin [3] and is observed more commonly in HIV and immunocompromised patients and patients with chronic diseases such as chronic kidney disease (CKD) than in otherwise healthy people [3, 4]. Disseminated tuberculosis presenting with cutaneous lesions is rare [5].

Cutaneous miliary tuberculosis presents a small proportion of all cutaneous tuberculosis cases [6]. This variant is usually reported in children, HIV and immunocompromised patients [5–7]. Generally, cutaneous miliary tuberculosis shows a hematogenous spread of

infection and is commonly seen in advanced pulmonary or disseminated tuberculosis [5]. Here, we report a case of pulmonary tuberculosis with cutaneous miliary tuberculosis in a CKD patient.

Case Report

A 79-year-old Thai woman with a history of CKD stage 5 (serum creatinine level 4.5–5.0 mg/dl), dyslipidemia and anemia of chronic disease presented with fatigue, low-grade fever and a productive cough for the last 2 months. She denied any history of tuberculosis infection. Her current medication was manidipine hydrochloride (10 mg/day) and furosemide (20 mg/day). Physical examination revealed fever, fine crepitation in both lungs and multiple discrete small pustules on her face, trunk and extremities (fig. 1). Laboratory findings showed a hemoglobin level of 9.2 g/dl, a white cell count of 21,060/mm³ with 91.2% neutrophils, and a platelet count of 210,000/mm³. An anti-HIV test was negative. Radiography of the chest revealed diffuse reticulonodular infiltration of both lungs. Sputum examination was positive for acid-fast bacilli and *Mycobacterium tuberculosis* complex DNA was detected by polymerase chain reaction. Skin scrapings from pustules of the right thigh were positive for acid-fast bacilli and *M. tuberculosis* complex DNA was detected by polymerase chain reaction. She was diagnosed with pulmonary and cutaneous miliary tuberculosis. Blood cultures identified *M. tuberculosis* complex 50 days later. She was started on an initial therapy of isoniazid (300 mg/day), rifampicin (450 mg/day), ethambutol (800 mg/day) and pyrazinamide (1,500 mg/day). The pustules subsided after 3 weeks of treatment and pulmonary symptoms improved after 5 weeks of treatment.

Discussion

The incidence of cutaneous tuberculosis has increased with the resurgence of pulmonary tuberculosis. Cutaneous tuberculosis accounts for 1.5% of all extrapulmonary tuberculosis cases [4]. The mechanism of cutaneous tuberculosis consists of direct inoculation, contiguous infection of the organs (e.g. lymph nodes, bones, joints), hematogenous dissemination or a hypersensitivity reaction against *M. tuberculosis* [3, 5]. Conditions predisposing people to disseminated tuberculosis include HIV infection, immunosuppressive therapy, alcoholism, diabetes mellitus, hematologic disorders, being elderly and chronic diseases [3, 8]. The patient in this report was elderly with CKD. CKD can cause cellular immune impairments, making a person susceptible to tuberculosis.

The manifestation of cutaneous miliary tuberculosis is nonspecific. The lesions can be generalized discrete erythematous papules, pustules or vesicles [5]. Our patient presented with prolonged fever with multiple discrete small pustules on her face, trunk and extremities. Other causes of disseminated infection (bacteria, fungus, herpesvirus, non-tuberculous mycobacteria) and acute febrile neutrophilic dermatosis should be excluded. We suspected cutaneous miliary tuberculosis based on the clinical presentation of pustules and confirmed the diagnosis by identification of the organism in skin lesions. Following treatment with anti-tuberculosis agents, the patient's fever and pustules resolved within 3 weeks. The cutaneous remission is responsive similar to previous case reports [7, 9].

The gold standard for the diagnosis of cutaneous tuberculosis is the identification of *M. tuberculosis* from a skin biopsy. Significant response to a therapeutic trial of anti-tuberculosis agents for 6 weeks can suggest cutaneous tuberculosis [10]. Subsequent isolation of

M. tuberculosis in blood cultures supports the mechanism of hematogenous spread in cutaneous miliary tuberculosis [5].

Before the era of HIV infection, cutaneous miliary tuberculosis occurred predominantly in infants. In a review published in 1991, Rietbroek et al. [11] described 24 cases in adult patients with virtually no underlying illnesses. Recently, such a condition tends to occur in HIV and immunocompromised adult patients [3, 6–8, 12]. Only a few cases of disseminated *M. tuberculosis* of the skin in renal transplant recipients or CKD patients have been reported with the various clinical manifestations (table 1). A common feature of these cases is chronic immunosuppressive therapy.

Conclusion

This case highlights that a rare cutaneous manifestation with a hematogenous dissemination of *M. tuberculosis* can develop in immunocompromised patients, such as those with HIV, on immunosuppressive therapy and even with CKD.

References

- 1 Murray CJ, Ortblad KF, Guinovart C, Lim SS, Wolock TM, Roberts DA, et al: Global, regional, and national incidence and mortality for HIV, tuberculosis, and malaria during 1990–2013: a systematic analysis for the Global Burden of Disease Study 2013. *Lancet* 2014;384:1005–1070.
- 2 Sandgren A, Hollo V, van der Werf MJ: Extrapulmonary tuberculosis in the European Union and European Economic Area, 2002 to 2011. *Euro Surveill* 2013;18.
- 3 Daido-Horiuchi Y, Kikuchi Y, Kobayashi S, Fujii T, Oshima S, Kondo T: Tuberculous cellulitis in a patient with chronic kidney disease and polymyalgia rheumatica. *Intern Med* 2012;51:3203–3206.
- 4 Mehta PK, Raj A, Singh N, Khuller GK: Diagnosis of extrapulmonary tuberculosis by PCR. *FEMS Immunol Med Microbiol* 2012;66:20–36.
- 5 Bravo FG, Gotuzzo E: Cutaneous tuberculosis. *Clin Dermatol* 2007;25:173–180.
- 6 Marcoval J, Alcaide F: Evolution of cutaneous tuberculosis over the past 30 years in a tertiary hospital on the European Mediterranean coast. *Clin Exp Dermatol* 2012;38:131–136.
- 7 Yodmalai S, Chiewchanvit S, Mahanupab P: Cutaneous miliary tuberculosis in a renal transplant patient: a case report and literature review. *Southeast Asian J Trop Med Public Health* 2011;42:674–678.
- 8 Crump JA, Reller LB: Two decades of disseminated tuberculosis at a university medical center: the expanding role of mycobacterial blood culture. *Clin Infect Dis* 2003;37:1037–1043.
- 9 Park KW, Kim US, Shin JW, Yoo CG, Oh MD, Choe K: Disseminated erythematous papules in a renal transplant recipient: a case of disseminated tuberculosis. *Scand J Infect Dis* 2002;34:775–777.
- 10 Ramam M, Mittal R, Ramesh V: How soon does cutaneous tuberculosis respond to treatment? Implications for a therapeutic test of diagnosis. *Int J Dermatol* 2005;44:121–124.
- 11 Rietbroek RC, Dahlmans RP, Smedts F, Frantzen PJ, Koopman RJ, van der Meer JW: Tuberculosis cutis miliaris disseminata as a manifestation of miliary tuberculosis: literature review and report of a case of recurrent skin lesions. *Rev Infect Dis* 1991;13:265–269.
- 12 Daikos GL, Uttamchandani RB, Tuda C, Fischl MA, Miller N, Cleary T, Saldana MJ: Disseminated miliary tuberculosis of the skin in patients with AIDS: report of four cases. *Clin Infect Dis* 1998;27:205–208.
- 13 Ram R, Uppin S, Swarnalatha G, Desai M, Harke M, Prasad N, Dakshinamurthy KV: Isolated skin ulcers due to *Mycobacterium tuberculosis* in a renal allograft recipient. *Nat Clin Pract Nephrol* 2007;3:688–693.
- 14 Seyahi N, Apaydin S, Kahveci A, Mert A, Sariyur M, Ereke E: Cellulitis as a manifestation of miliary tuberculosis in a renal transplant recipient. *Transpl Infect Dis* 2005;7:80–85.
- 15 Maejima H, Arai S, Ebata T, Takeda H, Kusunoki M, Katsuoka K: Tuberculous gumma associated with idiopathic thrombocytopenic purpura: report of a Japanese female patient. *J Dermatol* 2007;34:86–91.

Table 1. Summary of cases of disseminated cutaneous tuberculosis in CKD patients

Number of patients [reference]	Gender/ age (years)	Underlying disease	Immunosuppressive therapy	Duration of immuno-suppressive therapy	Form of cutaneous tuberculosis	Anti-tuberculosis therapy	Time for cutaneous complete remission
1 [4]	male/ 89	CKD, polymyalgia rheumatica	prednisolone 5 mg/day	13 years	tuberculous cellulitis	yes	NA
2 [7]	male/ 56	post renal transplantation	cyclosporin 100 mg/day	NA	cutaneous miliary tuberculosis	yes	2 weeks
3 [9]	female/ 62	post renal transplantation	azathioprine 100 mg/day; prednisolone 10 mg/day	16 years	cutaneous miliary tuberculosis	yes	3 days
4 [13]	male/ 27	post renal transplantation	cyclosporin 3 mg/kg/day	12 years	leg ulcers	yes	7 weeks
5 [14]	male/ 37	post renal transplantation	azathioprine 100 mg/day; methylprednisolone 8 mg/day	14 years	tuberculous cellulitis	yes	3 weeks
6 [15]	female/ 77	CKD, ITP	prednisolone 15 mg/day	4 years	tuberculous gumma	yes	several months
Current case	female/ 79	CKD	no	–	cutaneous miliary tuberculosis	yes	3 weeks

ITP = Idiopathic thrombocytopenic purpura; NA = data not available.

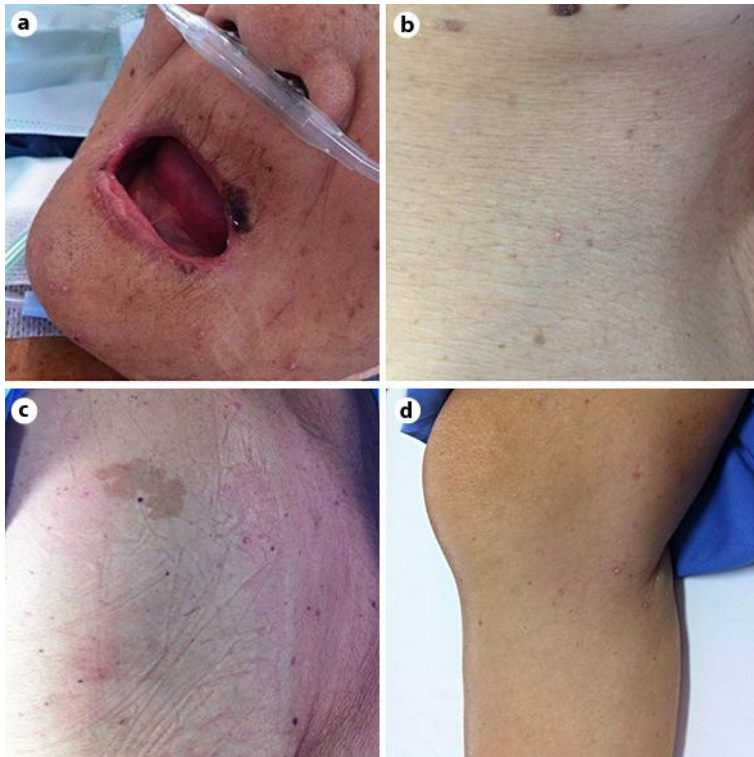


Fig. 1. Multiple discrete small pustules distributed on the face (a), trunk (b) and extremities (c, d).