



Regression of a symptomatic thoracic disc herniation with a calcified intervertebral disc component



Hidayet Sari ^a, Tugce Ozekli Misirlioglu ^{b,*}, Deniz Palamar ^a

^a Istanbul University, Cerrahpasa Medical Faculty, Physical Medicine and Rehabilitation Department, Istanbul, Turkey

^b Koc University Hospital, Physical Medicine and Rehabilitation Department, Istanbul, Turkey

ARTICLE INFO

Article history:

Received 19 September 2014

Received in revised form

22 February 2015

Accepted 17 May 2015

Available online 10 December 2016

Keywords:

Calcification

Pathologic

Herniated disc

Intervertebral disc

Thoracic vertebrae

ABSTRACT

There were only a few cases describing spontaneous regression of calcified thoracic disc herniation in the literature. We present a 38-year-old male office worker who had left paramedian-foraminal extruded disc at T7–T8 with calcifications of the T7–T8 and T8–T9 intervertebral discs. This case was unique in that the non-calcified extruded disc material regressed almost completely in 5 months while the calcified intervertebral discs remained the same during the process of regression. This report stresses that regression of the herniated material of the thoracic discs with subsidence of the symptoms is still possible even if the disc material is calcified.

© 2016 Turkish Association of Orthopaedics and Traumatology. Publishing services by Elsevier B.V. This is an open access article under the CC BY-NC-ND license (<http://creativecommons.org/licenses/by-nc-nd/4.0/>).

Introduction

Spontaneous regression or decrease in size of a herniated disc is commonly described in the lumbar and to a lesser extent in the cervical region while that of the thoracic region has rarely been reported.¹ In most of the cases, it was not indicated whether the discs that spontaneously regressed were calcified or not. There are only a few cases in the literature describing spontaneous regression of calcified thoracic disc herniation (TDH) in adults.^{2,3} We report a case of symptomatic TDH, in which the non-calcified extruded disc material regressed almost completely while the calcified intervertebral discs (IVDs) remained the same during the process of regression.

Case report

A 38-year-old male office worker, presented with a 2-month history of subscapular left-sided dorsal pain radiating in a belt-like distribution accompanied by occasional pain and paresthesia radiating to the left lower anterolateral chest wall. He reported that his pain had gradually increased and, recently had become unresponsive to medical treatment. His physical examination revealed

active myofascial trigger points (MTrP) in left lower paravertebral muscles in the thoracic spine with a predicted referred pain pattern compatible with the patient's symptoms. Upon diagnosing the patient with myofascial pain syndrome (MPS), we performed MTrP injections. He reported that his pain had decreased dramatically following the injection, but resumed a couple of days later. So, after we performed the MTrP injections two more times and observed the same partial relief, we re-evaluated the patient. Plain radiographs showed vague calcifications of the T7–T8 and T8–T9 IVDs with minimal degenerative changes of the corresponding end plates (Fig. 1A). Magnetic resonance imaging (MRI) revealed left paramedian-foraminal extruded disc at T7–T8 with left T7 nerve compression with hypointense signal in the central area of T7–T8 and T8–T9 discs (Fig. 2). We diagnosed the patient as having MPS accompanying T7–T8 TDH and, started a conservative treatment program including simple analgesic and non-steroid anti-inflammatory drugs with 15 sessions of physical therapy program. Gradually, his clinical symptoms subsided and, he returned to his activities of daily living without any complaints. Five months later, the patient was admitted to our clinics with his new X-ray and MRI scans that had been performed upon his request in a private hospital. We observed almost complete disappearance of the extruded fragment of the T7–T8 disc with a persisting hypointense zone in T8–T9 disc (Fig. 3). The hypointense zone in MRI was matched with the calcifications on X-ray (Fig. 1B) and, the patient was still asymptomatic.

* Corresponding author.

E-mail address: tozeklim@gmail.com (T.O. Misirlioglu).

Peer review under responsibility of Turkish Association of Orthopaedics and Traumatology.

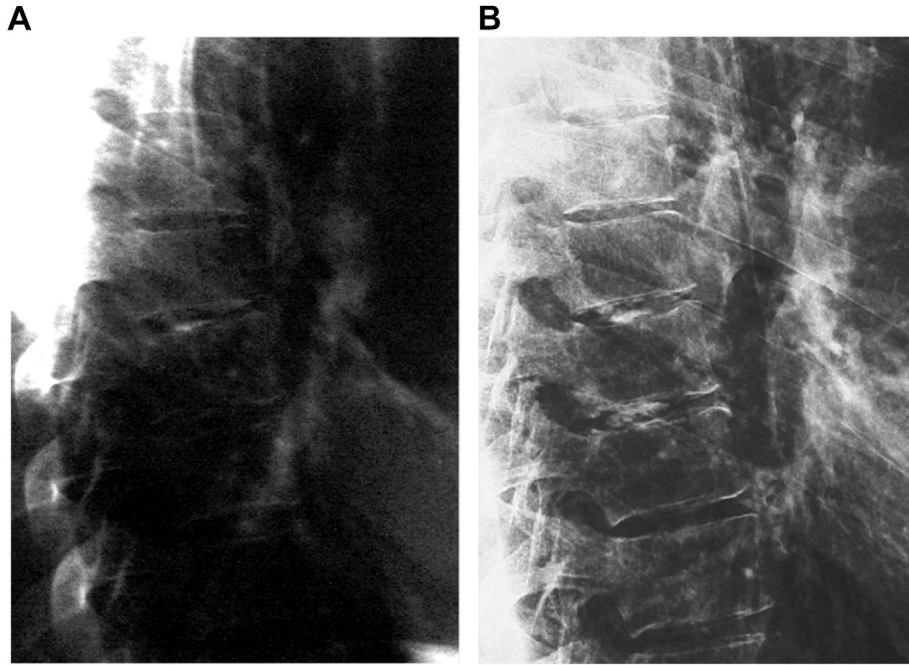


Fig. 1. (A) X-ray scan showing vague calcifications of the T7–T8 and T8–T9 IVDs; (B) 5 months later symptoms onset X-ray scan showing more prominent calcifications of the T7–T8 and T8–T9 IVDs.

Discussion

Thoracic disc herniations account for only about 0.25%–0.75% of all symptomatic herniated discs in adults.⁴ The diagnosis of symptomatic TDH is often overlooked because of the mismatch between the symptoms and location of the herniation.⁵ Disc calcification accompanying disc herniation is commonly reported in children and referred to as a ‘no touch lesion’ because of its benign nature and high rate of complete clinical and radiologic resolution.⁶ In adults, however, disc calcifications are thought to represent disc degeneration and herniation, and the rate of regression of calcified disc herniations are considered to be rare.³

Three mechanisms have been proposed to explain the process of disc regression. These are mechanical retraction of the herniated nucleus, gradual dehydration and shrinkage of the disc, and enzymatic degradation of herniated disc material.⁷ Among these, we find the third mechanism, namely, enzymatic degradation of herniated material, to be the most compelling and studied one. In that instance, extruded disc material is recognized as a foreign body and an inflammatory reaction is induced.

Almost 65% of herniated thoracic discs were shown to be calcified at presentation,⁸ and the presence of calcifications in the IVD is frequently found to be associated with hard herniated discs.⁹ Disc calcification is an important consideration since it is shown as

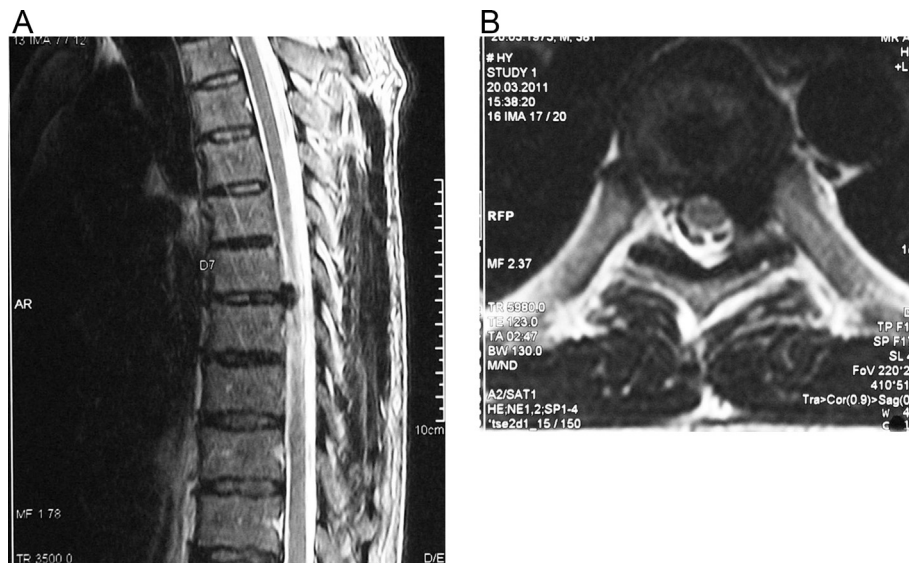

Fig. 2. (A) T2 weighted sagittal MRI scan showing the extruded disc at T7–T8 with hypointense signal in the central area of T7–T8 and T8–T9 discs; (B) T2 weighted axial MRI scan showing left paramedian-foraminal extruded disc at T7–T8 with left T7 nerve compression.

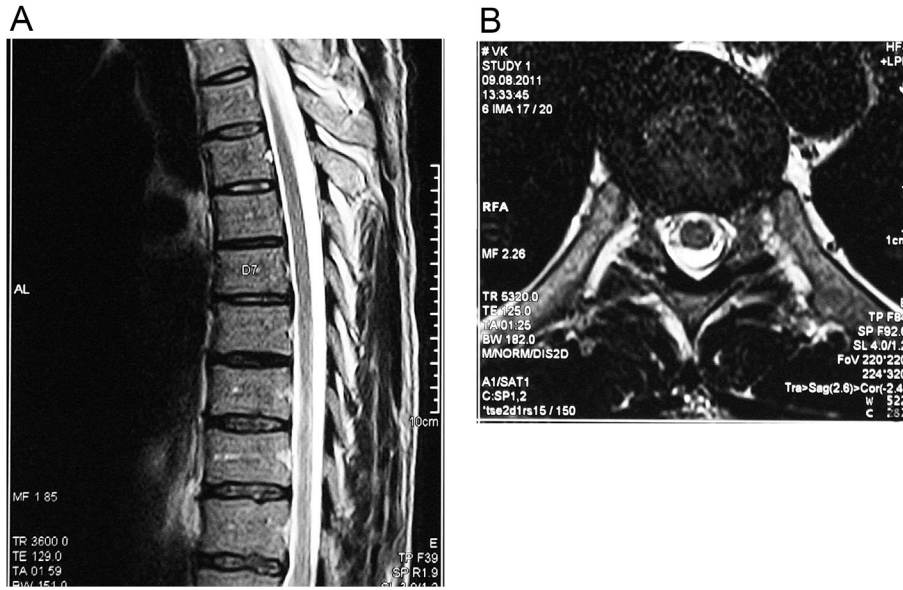

Fig. 3. (A) T2 weighted sagittal and (B) axial MRI scan showing the disappearance of the previously reported lesions.

the main reason for lower regression rate of TDHs.¹⁰ In addition, calcified herniated discs, mainly interpreted as hard herniated discs, are difficult to resect during the surgery.¹¹ On the other hand, some of the TDHs, even if calcified on the preoperative imaging studies can be found to be soft and non-adherent intraoperatively, thus easily resectable.^{11,12}

In the literature, there are only a few cases of spontaneously regressed TDHs that have been described.^{1,13,14} The common

question for all of these cases was that it was not specified whether the discs were calcified or not. On the other hand, to the best of our knowledge, only three cases of spontaneously calcified TDH regression have been reported in the literature. In two cases, which were reported by Eap et al while the IVD calcifications remained, the regression of the calcified part of the herniated discs was observed.² However, in the other case, which was reported by Piccirilli et al it was observed that both the calcified extruded

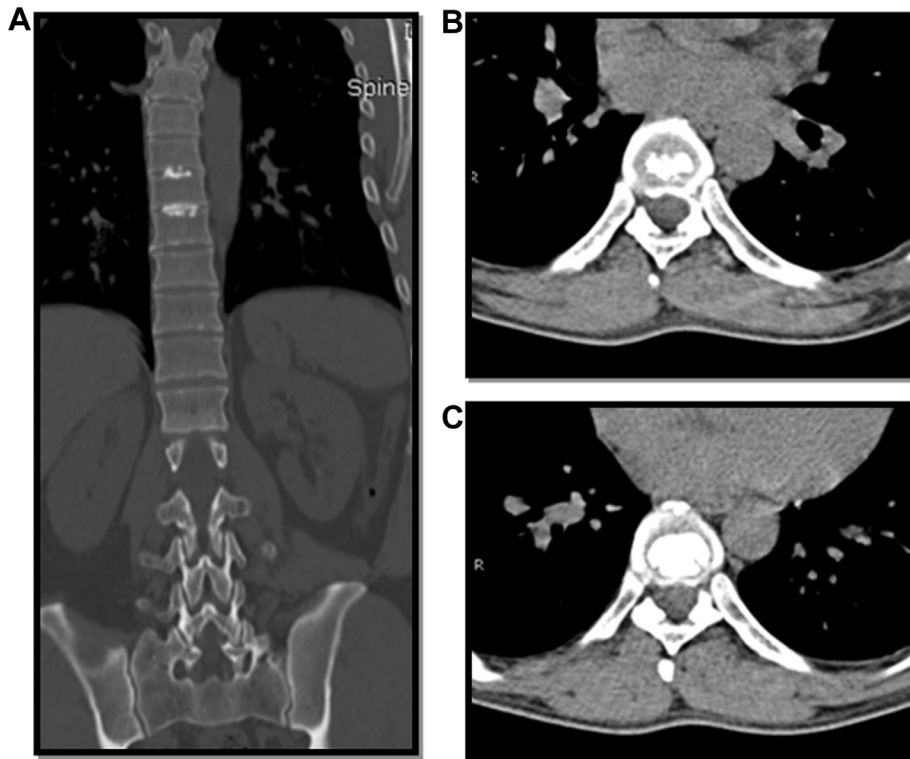


Fig. 4. Control CT showing calcifications of the T7–T8 and T8–T9 IVDs.

material and IVD calcification of the T7–T8 disc spontaneously regressed.³

In our case, the regression of the herniated material seemed to have taken place in 5 months, and was associated with a gradual reduction of pain. Like the cases reported by Eap et al,² IVD calcifications of the herniated discs remained in place as the non-calcified extruded disc material totally regressed and the patient's symptoms subsided. In computed tomography (CT) taken almost 2 years after the beginning of the patient's complaints, IVD calcifications were still present (Fig. 4), the patient was still asymptomatic and his MTrPs were latent.

Conclusion

The reported case supports two main findings. Firstly, it suggests that for those having recalcitrant MTrPs of the paravertebral muscles in the thoracic spine, TDH should be kept in mind as an underlying cause. Secondly, regression of the herniated material of the thoracic discs with subsidence of the symptoms is still possible even though the disc material is calcified.

References

1. Eap C, Bennis S, Blauwblomme T, et al. Spontaneous resorption of thoracic calcified disc herniation: report of two cases and review of the literature. *Neurochirurgie*. 2012;58(6):353–357.
2. Piccirilli M, Lapadula G, Caporlingua F, Martini S, Santoro A. Spontaneous regression of a thoracic calcified disc herniation in a young female: a case report and literature review. *Clin Neurol Neurosurg*. 2012 Jul;114(6):779–781.
3. Okada Y, Shimizu K, Ido K, Kotani S. Multiple thoracic disc herniations: case report and review of the literature. *Spinal Cord*. 1997;35:183–186.
4. Shirzadi A, Drazin D, Jeswani S, Lovely L, Liu J. Atypical presentation of thoracic disc herniation: case series and review of the literature. *Case Rep Orthop*. 2013;2013:621476.
5. Garg M, Kumar S, Satija B, Gupta R. Pediatric intervertebral disc calcification: a no touch lesion. *J Craniovertebr Junction Spine*. 2012;3(1):23–25.
6. Ryu SJ, Kim IS. Spontaneous regression of a large lumbar disc extrusion. *J Korean Neurosurg Soc*. 2010;48:285–287.
7. Stillerman CB, Chen TC, Couldwell WT, et al. Experience in the surgical management of 82 symptomatic herniated thoracic discs and review of the literature. *J Neuro Surg*. 1998;88:623–633.
8. Gille O, Soderlund C, Razafimahandri HJ, Mangione P, Vital JM. Analysis of hard thoracic herniated discs: review of 18 cases operated by thoracoscopy. *Eur Spine J*. 2006 May;15(5):537–542.
9. Ribes R, Vilanova JC. *Learning Musculoskeletal Imaging*. vol. 93. Springer; 2010.
10. Franssen P, Collignon F, Van Den Heule B. Foraminal disc herniation Th9-Th10 mimicking abdominal pain. *Acta Orthop Belg*. 2008;74(6):881–884.
11. Paolini S, Ciappetta P, Guiducci A, et al. Foraminal deposition of calcium pyrophosphate dihydrate crystals in the thoracic spine: possible relationship with disc herniation and implications for surgical planning. Report of two cases. *J Neurosurg Spine*. 2005;2:75–78.
12. Martínez-Quinones JV, Aso-Escario J, Consolini F, Arregui-Calvo R. Regresión espontánea de hernias discales intervertebrales. A propósito de una serie de 37 casos. *Neurocirurgia*. 2010;21:108–117.
13. Coevoet V, Benoudiba F, Lignières C. Régression spontanée et complete en IRM d'une hernie discale dorsale. *J Radiol*. 1997;78:149–151.
14. Morandi X, Crovetto N, Carsin-Nicol B, Carsin M, Brassier G. Spontaneous disappearance of a thoracic disc hernia. *Neuro-Chirurgie*. 1999 May;45(2):155–159.