



## Endodontic Retreatment of a Maxillary Central Incisor with Two Root Canals in a Patient with Cleft Lip and Palate

George Tácio Miranda Candeiro<sup>a</sup> , Francisca Livia Parente Viana<sup>b\*</sup> , Hermano Camelo Paiva<sup>c</sup> ,  
Celso Luiz Caldeira<sup>c</sup> , Elaine Faga Iglecias<sup>c</sup> , Giulio Gavini<sup>c</sup>

<sup>a</sup> Post-graduation Program Dental Sciences, University Center Christus, Fortaleza, Ceará, Brazil; <sup>b</sup> Post-graduation Program in Dentistry, Federal University of Ceará, Fortaleza, Ceará, Brazil; <sup>c</sup> Post-graduation Program in Dentistry, Faculty of Dentistry, University of São Paulo, São Paulo, São Paulo, Brazil

### ARTICLE INFO

Article Type: **Case Report**

Received: 30 Mar 2019

Revised: 29 May 2019

Accepted: 10 Jun 2019

Doi: 10.22037/iej.v14i3.24911

\*Corresponding author: Francisca Livia Parente Viana, Federal University of Ceara, Rua Ronaldo Pontes Dias, 1362-Das Nações, Sobral, Brazil, ZIP: 62053-660.

E-mail: liviapviana@hotmail.com



© The Author(s). 2018 Open Access This work is licensed under the terms of the Creative Commons Attribution-NonCommercial-ShareAlike 4.0 International.

### ABSTRACT

The failures in endodontic treatments are often related to anatomical variations. Some anatomical changes in anterior teeth occur in patients with cleft lip and palate. This paper aims to report the endodontic retreatment of a maxillary central incisor with two roots and two canals on a patient who presents cleft lip and palate. A male patient, 11-year-old, reported pain when chewing related to the left maxillary central incisor tooth (tooth 21) which featured a sinus tract after primary endodontic treatment. In periapical radiograph, it was observed an alteration on the anatomy of the root on the tooth 21, which featured a radiolucent area on the dental apex and had been properly endodontically treated. In cone-beam computed tomography (CBCT) images the presence of an accessory root in the palatal region was observed, that had not been prepared, or filled. Thus, the non-treated accessory canal was instrumented with the crown-down technique and filled with gutta-percha and endodontic sealer. After 1 year of follow-up, the patient presented the tooth with a normal masticatory function and no painful symptoms. Therefore, it can be concluded that the additional root canals may be present and the CBCT is an important tool to evaluate the internal root morphology. In cleft lip and palate patients, the root canals morphology should be carefully analyzed due to high prevalence of dental anomalies which may influence the success in endodontic treatment.

**Keywords:** Cleft Lip-palate; Cone-Beam Computed Tomography; Dental Anatomy; Endodontic Retreatment; Maxillary Central Incisor

## Introduction

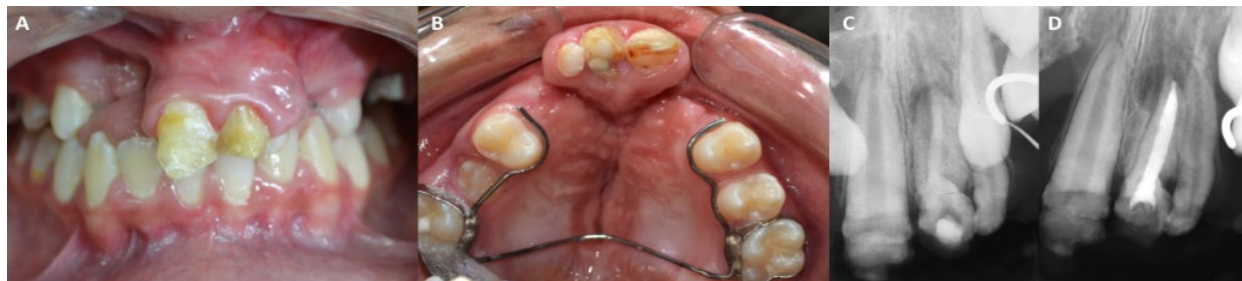Variations in the internal morphology of root canals may influence on the success of the endodontic therapy [1, 2]. One of the many associated reasons to the flaws in this therapy is the persistence of infection within the root canals [3-5].

Previous studies show that 100% of the maxillary central incisors presented single root and one root canal [6-8]. However, there are a few reported cases in the literature of maxillary central incisors presenting two [4, 9-11], three [12, 13], four [14-16] and, even, five root canals [17]. Usually, the presence of more than one canal in the maxillary central incisors is related to some rare anomalies in the development of the teeth, such as gemination [18], fusion [11], dens invaginatus [17] or supernumerary roots

[19]. Other cases of anatomical changes in the antero-superior teeth occur in patients with cleft lip and palate [20-22].

The cleft lip and palate are the most frequent congenital anomalies in the head and neck region [20, 23] and are a result of a failure in the merging of the nasal and the maxillary processes [24]. Some studies show that the frequency of dental anomalies is directly associated with the severity of the cleft [24, 25] and it occurs in about 70% of the cases [20, 21, 25]. The main anatomical changes are hypodontia, microdontia, root dilaceration and the presence of supernumerary teeth [20-22, 26].

Although periapical radiographies are important for diagnosis, planning and implementation of the endodontic treatment, their use is quite limited in cases of alterations in root canal morphology [7, 27, 28]. In order to overcome the radiograph



**Figure 1.** Clinical and radiographic exams. A) Intraoral clinical examination in frontal view, observing the upper arch; B) Evidencing the presence of cleft palate; C) Periapical radiograph, before primary endodontic treatment; D) After primary endodontic treatment

limitations and to provide higher resolution images, cone-beam computed tomography (CBCT) has been used as an efficient resource to identify and locate roots and additional canals in anomalous teeth [7]. Hence, this work aims to report the endodontic retreatment of a maxillary central incisor with two canals on a patient with cleft lip and palate.

## Case Report

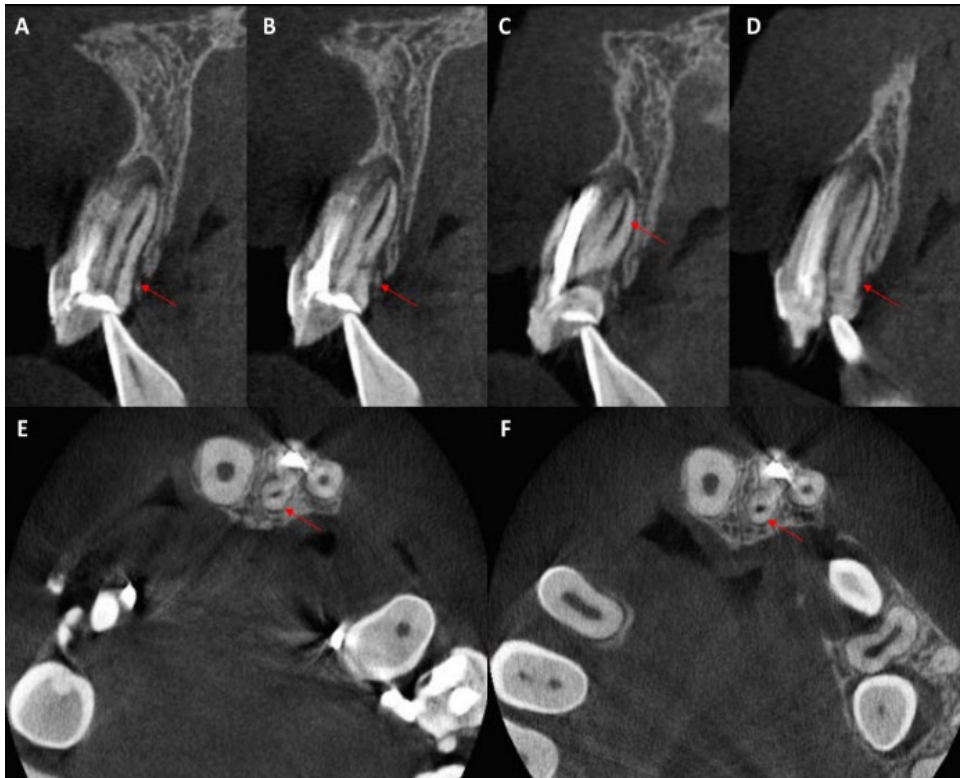
An 11-year-old male with cleft lip and palate was referred to the Endodontic Specialization Course of the School of Dentistry of the University of São Paulo (São Paulo, Brazil), reporting sensitivity to chewing related to the left maxillary central incisor (tooth #21). The patient reported a previous endodontic treatment and, after 4 months, he observed the development of a “small bubble on the gum”.

The intraoral examination showed dental absences, alteration on the dental crowns of teeth 11 and 21 (probable imperfect amelogenesis), and cleft palate. The patient was wearing a space maintainer device and a maxillary expander fixed to the maxillary molar teeth (Figures 1A and 1B). The presence of a sinus tract in the palatal groove region of the tooth 21 was also noted (Figure 1C). In the periapical radiographic examination, it was observed a change in the anatomy of the root on the tooth 21 in comparison with its contralateral tooth. This tooth has also presented a periapical radiolucent area which had been endodontically treated (Figure 1D).

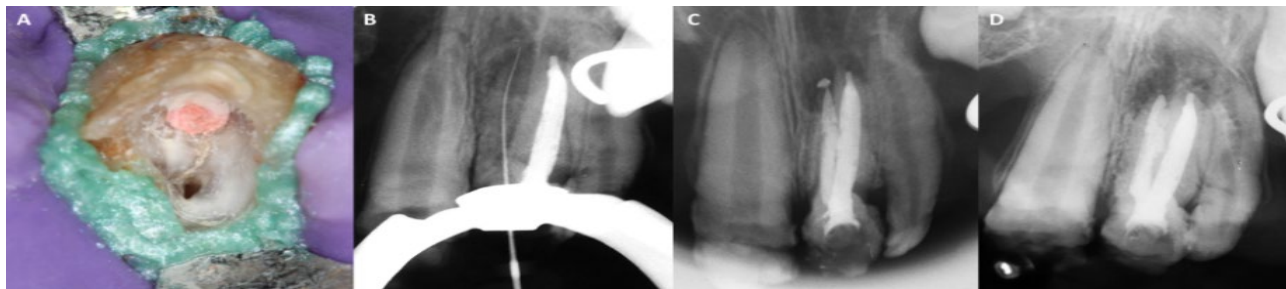
Next, a CBCT exam was requested to improve the assessment of the internal and the external root anatomy, in order to assist the diagnosis as well as the clinical planning. The CBCT scan was performed by an ICAT device (Sorensen, Helsinki, Finland) which confirmed the presence of two roots and two canals (Figure 2). It was noticed that the buccal root canal had been well shaped and sealed. In the face of the recent endodontic treatment of the buccal canal, it was decided to carry out the treatment only on the palatal root canal.

After explaining the choice of treatment to the patient and getting the consent form of him, the access to the canals was performed with a 1014 drill, removing the dentine until the palatine canal was found (Figure 3A). The new canal was explored with a #10 K-file and the working length was performed with a #15 K-file, using an electronic foramen locator (RomiApex A15; Romidan, Kiryat Ono, Israel). The working length was established 1 mm short of the apical foramen (Figure 3B). The canal instrumentation was done manually by crown-apex technique and the apical preparation was performed with the #40 NiTiflex file (Dentsply Maillefer, Ballaigues, Switzerland). At every file change, the canal was irrigated with 2 mL of 2.5% sodium hypochlorite (Fórmula e Ação Farmácia de Manipulação, São Paulo, São Paulo, Brazil). To remove the smear layer, the canal was rinsed with 1 mL of 17% Ethylene diamine tetraacetic acid (EDTA) solution (Fórmula e Ação Farmácia de Manipulação, São Paulo, Brazil) for 3 min. Afterwards, irrigation was performed with saline solution and the root canal was filled with calcium hydroxide paste, which remained for 15 days. In the second session, the patient was asymptomatic. So, the interappointment medication inside root canal was removed with 2.5% sodium hypochlorite, followed by irrigation with 17% EDTA and saline solution. After drying the root canal, obturation procedure was performed with gutta-percha cones associated with EndoFill sealer (Dentsply Maillefer, Ballaigues, Switzerland) by the lateral condensation technique (Figure 3C). The tooth was restored with A2 Filtek™ Z250 XT composite resin (ESPE, Rio de Janeiro, Brazil).

After one year follow-up, the patient reported no pain to apical palpation or vertical percussion. Radiographically, there was a decrease in the periapical bone rarefaction (Figure 3D). In the face of signs of repair of the periapical region and the tooth having a regular masticatory function, the patient was referred for surgical treatment of the cleft lip and palate.



**Figure 2.** A–D) Imaginological exams: CBCT scan in sagittal; E and F) Axial sections, evidencing the presence of a root and an additional canal in the palatine region (red arrows)



**Figure 3.** Endodontic retreatment. A) Display of the pulp chamber, being observed the buccal canal filled with shutter and the empty palatine canal; B) Evidencing the presence of an accessory canal with a file in the working length; C) Post-filling of the canal; D) One year after completion of the endodontic treatment, highlighting a decrease in periapical bone rarefaction

## Discussion

In the present case report, two root canals in a maxillary central incisor were observed in a patient with cleft lip and palate. There is a consensus in previously published papers regarding the anatomy of the maxillary central incisors presenting single root and single canal in 100% of cases [6-8]. However, there are few case reports in which these teeth present two to five root canals, constituting a rare clinical finding [4, 10, 11, 13, 15-17]. The vast majority of these reports are related to the presence of associated anomalies, such as gemination, [18, 29], fusion [11, 30-33], dens invaginatus [14, 17], macrodontia [34] and

enamel hypoplasia [35, 36]. Several cases have been reported where the maxillary central incisors with 2 canals were considered typical anatomy [4, 9, 16, 37].

In this case report, the observed dental alteration was the amelogenesis imperfecta, which is a genetic condition that affects the development of the tooth enamel. As the defective enamel is quite thin or completely absent, the yellowish or brown dentin of the crown is revealed, presenting dentin sensitivity and poor aesthetics [38]. At the moment, even a single study relating the amelogenesis imperfecta to the presence of two roots and two canals in the maxillary central incisor has not been found in the literature.

With regards to patients with cleft lip and palate, anomalies of number, size and shape of teeth, as well as changes in periods of formation and eruption, are frequently observed, causing not only aesthetic problems but also difficulties in chewing, swallowing, breathing and phonation [21]. In a retrospective analysis of 207 panoramic radiographs of patients with cleft lip and palate, the presence of dental anomalies in 75.4% of the cases was observed, being 31.2% of those presenting dental agenesis [20]. In another study, Ajami *et al.* [1] observed the presence of dental anomalies in 92.5% of the studied cleft patients. The most prevalent ones were hypodontia (71.25%), microdontia (30%), root lacerations (21.25%) and supernumerary teeth (15%), respectively. Usually the most affected teeth are the maxillary lateral incisors [22, 25]. However, in the present case report, the patient presented agenesis of the right lateral incisor and the central incisors with amelogenesis imperfecta. The association between the presence of teeth with amelogenesis imperfecta and cleft lip and palate could not be found in the literature, that shows a rare clinical presentation. It has also been observed that only the maxillary left central incisor presented two roots and two root canals, and there was no prior similar report.

Several papers have already discussed the importance of a complete disinfection of all root canals so that healing of the periapical region happens especially if the canals present independent foramen [4, 16, 17, 39], as shown in this case. Nevertheless, some root canals might be left untreated during treatment, mostly in the teeth with difficult access or visualization of these canals. One possible difficulty in the identification of an additional canal might be due to the arrangement of the roots in buccal and palatal direction. Periapical radiographs present limitations in the diagnosis, showing overlapping structures. The CBCT is a viable option to diagnose calcified and additional canals [40-42]. In the present case, the patient felt persistent pain after the endodontic treatment, which ended only after the preparation and filling of the additional canal in the palatine region. After 1 year of follow-up, absence of the infection and decrease of the periapical bone rarefaction was observed.

## Conclusions

Cleft lip and palate patients might have dental anomalies that hinder the endodontic treatment, mainly related to the presence of supernumerary canals. Additional care, such as the use of CBCT should be employed, in order to check with high fidelity the anatomical condition of the teeth of patients with cleft palate.

Conflict of Interest: 'None declared'.

## References

1. Durack C, Patel S. Cone beam computed tomography in endodontics. *Braz Dent J.* 2012;23(3):179-91.
2. Pecora JD, Estrela C, Bueno MR, Porto OC, Alencar AH, Sousa-Neto MD, Estrela CR. Detection of root canal isthmuses in molars by map-reading dynamic using CBCT images. *Braz Dent J.* 2013;24(6):569-74.
3. AlShwaimi E, Bogari D, Ajaj R, Al-Shahrani S, Almas K, Majeed A. In Vitro Antimicrobial Effectiveness of Root Canal Sealers against *Enterococcus faecalis*: A Systematic Review. *J Endod.* 2016;42(11):1588-97.
4. Chaniotis A, Filippatos CG. The Use of a Novel Approach for the Instrumentation of a Cone-beam Computed Tomography-discernible Lateral Canal in an Unusual Maxillary Incisor: Case Report. *J Endod.* 2017;43(6):1023-7.
5. Kapralos V, Koutroulis A, Orstavik D, Sunde PT, Rukke HV. Antibacterial Activity of Endodontic Sealers against Planktonic Bacteria and Bacteria in Biofilms. *J Endod.* 2018;44(1):149-54.
6. Vertucci FJ. Root canal anatomy of the human permanent teeth. *Oral Surg Oral Med Oral Pathol.* 1984;58(5):589-99.
7. Estrela C, Bueno MR, Couto GS, Rabelo LE, Alencar AH, Silva RG, Pecora JD, Sousa-Neto MD. Study of Root Canal Anatomy in Human Permanent Teeth in A Subpopulation of Brazil's Center Region Using Cone-Beam Computed Tomography - Part 1. *Braz Dent J.* 2015;26(5):530-6.
8. Martins JNR, Marques D, Mata A, Carames J. Root and root canal morphology of the permanent dentition in a Caucasian population: a cone-beam computed tomography study. *Int Endod J.* 2017;50(11):1013-26.
9. Levin A, Shemesh A, Katzenell V, Gottlieb A, Ben Itzhak J, Solomonov M. Use of Cone-beam Computed Tomography during Retreatment of a 2-rooted Maxillary Central Incisor: Case Report of a Complex Diagnosis and Treatment. *J Endod.* 2015;41(12):2064-7.
10. S SJ. Primary Maxillary Bilateral Central Incisors with Two Roots. *Int J Clin Pediatr Dent.* 2017;10(3):309-12.
11. Persic Bukmir R, Braut A, Brekalo Prso I. Conservative endodontic management of a fused tooth: A case report. *Gerodontology.* 2017;34(3):398-400.
12. Sheikh-Nezami M, Mokhber N. Endodontic treatment of a maxillary central incisor with three root canals. *J Oral Sci.* 2007;49(3):245-7.
13. Gondim E, Jr., Setzer F, Zingg P, Karabucak B. A maxillary central incisor with three root canals: a case report. *J Endod.* 2009;35(10):1445-7.
14. Mangani F, Ruddle CJ. Endodontic treatment of a "very particular" maxillary central incisor. *J Endod.* 1994;20(11):560-1.
15. de Almeida-Gomes F, Maniglia-Ferreira C, Vitoriano MD, de Sousa BC, dos Santos RA, Duarte MA. A maxillary central incisor with four root canals. *European J Gen Dent.* 2012;1(3):201.
16. Aznar Portoles C, Moinzadeh AT, Shemesh H. A Central Incisor with 4 Independent Root Canals: A Case Report. *J Endod.* 2015;41(11):1903-6.

17. Zoya A, Ali S, Alam S, Tewari RK, Mishra SK, Kumar A, Andrabi SM. Double Dens Invaginatus with Multiple Canals in a Maxillary Central Incisor: Retreatment and Managing Complications. *J Endod.* 2015;41(11):1927-32.
18. Mahendra L, Govindarajan S, Jayanandan M, Shamsudeen SM, Kumar N, Madasamy R. Complete bilateral gemination of maxillary incisors with separate root canals. *Case Rep Dent.* 2014;2014:425343.
19. Vertucci FJ. Root canal morphology and its relationship to endodontic procedures. *Endod Topics.* 2005;10(1):3-29.
20. Sá J, Mariano LC, Canguçu D, Coutinho TS, Hoshi R, Medrado AP, Martelli-Junior H, Coletta RD, Reis SR. Dental anomalies in a Brazilian cleft population. *Cleft Palate Craniofac J.* 2016;53(6):714-9.
21. Ajami S, Pakshir H, Samady H. Prevalence and characteristics of developmental dental anomalies in Iranian orofacial cleft patients. *J Dent.* 2017;18(3):193.
22. Suzuki A, Nakano M, Yoshizaki K, Yasunaga A, Haruyama N, Takahashi I. A Longitudinal Study of the Presence of Dental Anomalies in the Primary and Permanent Dentitions of Cleft Lip and/or Palate Patients. *Cleft Palate Craniofac J.* 2017;54(3):309-20.
23. Shapira Y, Haklai Z, Blum I, Shpack N, Amitai Y. Prevalence of non-syndromic orofacial clefts among Jews and Arabs, by type, site, gender and geography: a multi-center study in Israel. *Isr Med Assoc J.* 2014;16(12):759-63.
24. Wu TT, Chen PK, Lo LJ, Cheng MC, Ko EW. The characteristics and distribution of dental anomalies in patients with cleft. *Chang Gung Med J.* 2011;34(3):306-14.
25. Al Jamal GA, Hazza'a AM, Rawashdeh MA. Prevalence of dental anomalies in a population of cleft lip and palate patients. *Cleft Palate Craniofac J.* 2010;47(4):413-20.
26. Paranaiba LM, Coletta RD, Swerts MS, Quintino RP, de Barros LM, Martelli-Junior H. Prevalence of Dental Anomalies in Patients With Nonsyndromic Cleft Lip and/or Palate in a Brazilian Population. *Cleft Palate Craniofac J.* 2013;50(4):400-5.
27. Rani AK, Metgud S, Yakub SS, Pai U, Toshniwal NG, Bawaskar N. Endodontic and esthetic management of maxillary lateral incisor fused to a supernumerary tooth associated with a talon cusp by using spiral computed tomography as a diagnostic aid: a case report. *J Endod.* 2010;36(2):345-9.
28. Sharma S, Grover S, Sharma V, Srivastava D, Mittal M. Endodontic and esthetic management of a dilacerated maxillary central incisor having two root canals using cone beam computed tomography as a diagnostic aid. *Case Rep Dent.* 2014;2014:861942.
29. Hosomi T, Yoshikawa M, Yaoi M, Sakiyama Y, Toda T. A maxillary central incisor having two root canals geminated with a supernumerary tooth. *J Endod.* 1989;15(4):161-3.
30. Christie WH, Peikoff MD, Acheson DW. Endodontic treatment of two maxillary lateral incisors with anomalous root formation. *J Endod.* 1981;7(11):528-34.
31. Cimilli H, Kartal N. Endodontic treatment of unusual central incisors. *J Endod.* 2002;28(6):480-1.
32. Brunet-Llobet L, Miranda-Rius J, Lahor-Soler E, Cahuana A. A fused maxillary central incisor and its multidisciplinary treatment: an 18-year follow-up. *Case Rep Dent.* 2014;2014:503478.
33. Sammartino G, Cerone V, Gasparro R, Riccitiello F, Trosino O. Multidisciplinary approach to fused maxillary central incisors: a case report. *J Med Case Rep.* 2014;8:398.
34. Cabo-Valle M, Gonzalez-Gonzalez JM. Maxillary central incisor with two root canals: an unusual presentation. *J Oral Rehabil.* 2001;28(8):797-8.
35. al-Nazhan S. Two root canals in a maxillary central incisor with enamel hypoplasia. *J Endod.* 1991;17(9):469-71.
36. Shivakumar TA, Makandar S, Kadam A. Unusual anatomy of maxillary central incisor with two roots. *Dental Hypotheses.* 2012;3(2):79.
37. Garlapati R, Venigalla BS, Chintamani R, Thumu J. Re - treatment of a Two-rooted Maxillary Central Incisor - A Case Report. *J Clin Diagn Res.* 2014;8(2):253-5.
38. Bechor N, Finkelstein T, Shapira Y, Shpack N. Conservative orthodontic treatment for skeletal open bite associated with amelogenesis imperfecta. *J Dent Child (Chic).* 2014;81(2):96-102.
39. Dorielo MCO, Gonini-Junior A, de Oliveira D, Bordignon RT, Borges AH. Root canal treatment of a fused mandibular incisor using cone-beam computed tomography as a diagnostic aid. *J Conserv Dent.* 2017;20(1):58-61.
40. Abella F, Patel S, Duran-Sindreu F, Mercade M, Roig M. Mandibular first molars with disto-lingual roots: review and clinical management. *Int Endod J.* 2012;45(11):963-78.
41. Patel S, Wilson R, Dawood A, Mannocci F. The detection of periapical pathosis using periapical radiography and cone beam computed tomography - part I: pre-operative status. *Int Endod J.* 2012;45(8):702-10.
42. Cheung GS, Wei WL, McGrath C. Agreement between periapical radiographs and cone-beam computed tomography for assessment of periapical status of root filled molar teeth. *Int Endod J.* 2013;46(10):889-95.

*Please cite this paper as:* Miranda Candeiro GT, Parente Viana FL, Camelo Paiva H, Luiz Caldeira C, Faga Iglecias E, Gavini G. Endodontic Retreatment of a Maxillary Central Incisor with Two Root Canals in a Patient with Cleft Lip and Palate. *Iran Endod J.* 2019;14(3): 235-9. *Doi:* 10.22037/iej.v14i3.24911.