



# Assessment of Cerebral Circulatory Arrest via CT Angiography and CT Perfusion in Brain Death Confirmation

Asli Irmak Akdogan, MD<sup>1</sup>, Yeliz Pekcevik, MD<sup>2</sup>, Hilal Sahin, MD<sup>2</sup>, Ridvan Pekcevik, MD<sup>3</sup>

<sup>1</sup>Department of Radiology, Buca Women Birth and Child Diseases Hospital, Izmir, Turkey; <sup>2</sup>Department of Radiology, University of Health Sciences, Tepecik Training and Research Hospital, Izmir, Turkey; <sup>3</sup>Department of Radiology, Katip Çelebi University, Atatürk Training and Research Hospital, Izmir, Turkey

**Objective:** To compare the utility of computed tomography perfusion (CTP) and three different 4-point scoring systems in computed tomography angiography (CTA) in confirming brain death (BD) in patients with and without skull defects.

**Materials and Methods:** Ninety-two patients clinically diagnosed as BD using CTA and/or CTP for confirmation were retrospectively reviewed. For the final analysis, 86 patients were included in this study. Images were re-evaluated by three radiologists according to the 4-point scoring systems that consider the vessel opacification on 1) the venous phase for both M4 segments of the middle cerebral arteries (MCAs-M4) and internal cerebral veins (ICVs) (A60-V60), 2) the arterial phase for the MCA-M4 and venous phase for the ICVs (A20-V60), 3) the venous phase for the ICVs and superior petrosal veins (ICV-SPV). The CTP images were independently reviewed. The presence of an open skull defect and stasis filling was noted.

**Results:** Sensitivities of the ICV-SPV, A20-V60, A60-V60 scoring systems, and CTP in the diagnosis of BD were 89.5%, 82.6%, 67.4%, and 93.3%, respectively. The sensitivity of A20-V60 scoring was higher than that of A60-V60 in BD patients ( $p < 0.001$ ). CTP was found to be the most sensitive method (86.5%) in patients with open skull defect ( $p = 0.019$ ). Interobserver agreement was excellent in the diagnosis of BD, in assessing A20-V60, A60-V60, ICV-SPV, CTP, and good in stasis filling ( $\kappa$ : 0.84, 0.83, 0.83, 0.83, and 0.67, respectively).

**Conclusion:** The sensitivity of CTA confirming brain death differs between various proposed 4-point scoring systems. Although the ICV-SPV is the most sensitive, evaluation of the SPV is challenging. Adding CTP to the routine BD CTA protocol, especially in cases with open skull defect, could increase sensitivity as a useful adjunct.

**Keywords:** Brain death; Computed tomography angiography; Computed tomography perfusion; Stasis filling

## INTRODUCTION

Brain death (BD) is defined as the irreversible cessation of functioning of the entire brain, including the brainstem.

**Received:** August 31, 2019 **Revised:** May 17, 2020

**Accepted:** June 17, 2020

This study did not receive any specific grant from funding agencies in the public, commercial, or not-for-profit sectors.

**Corresponding author:** Asli Irmak Akdogan, MD, Department of Radiology, Buca Women Birth and Child Diseases Hospital, Hoca Ahmet Yesevi Street, No:42-44, Izmir 35390, Turkey.

• E-mail: [irmakbiranci@gmail.com](mailto:irmakbiranci@gmail.com)

This is an Open Access article distributed under the terms of the Creative Commons Attribution Non-Commercial License (<https://creativecommons.org/licenses/by-nc/4.0>) which permits unrestricted non-commercial use, distribution, and reproduction in any medium, provided the original work is properly cited.

The diagnosis of BD is established using clinical criteria including coma, absence of brainstem reflexes, and positive apnea test (1). However, the diagnostic process is complicated and depends on multiple variations such as the management of the apnea test, waiting period before testing, sedative medication effects, the experience of the physicians, and the requirement for ancillary tests (2). Besides, there is no consensus on the necessity of the ancillary tests; for instance, in some countries, the ancillary tests are obligatory, in others, they are required when uncertainty exists about the reliability of the clinical examination (3). Due to these regional and international variations, there are still differences between studies regarding the method and interpretation criteria of ancillary tests, in the context of BD.

Among the ancillary tests, computed tomography angiography (CTA) is a viable method due to its noninvasiveness, easy access, and rapidity (4). Although there is no international consensus on the evaluation criteria for CTA regarding the number of vessels, the 4-point scoring system by Frampas et al. (4) appears the most efficient and reliable in BD diagnosis (5). This scoring system, which is accepted as the reference scoring system, considers the absence of opacification of the distal segments (M4) of both the middle cerebral arteries (MCAs) and internal cerebral veins (ICVs) at the venous phase is performed after a fixed delay of 60 seconds following intravenous contrast medium administration (4). However, Nunes et al. (6) favored the usage of the revised 4-point arteriovenous scoring system to evaluate the MCAs at the arterial phase (at 20s) and ICVs at the venous phase (at 60s); this was shown to have a better sensitivity. Furthermore, considering only the veins, a revised 4-point venous CTA score, including non-opacification of the ICVs and superior petrosal veins (SPVs) was also suggested especially in patients with craniectomy (7).

Recently, computed tomography perfusion (CTP) has been shown to have a promising role in the confirmation of BD by demonstrating the absence of cerebral parenchymal perfusion (8-11). Increased intracranial pressure resulting from an intracranial pathology leads to a decrease, and finally an arrest, in cerebral perfusion according to the Monro-Kellie hypothesis. The capillary level is the first place in which cerebral circulatory arrest starts. By demonstrating the early perfusion changes in this level, CTP might be a fast method, which can make a valuable contribution to the BD diagnosis (8-10).

A skull defect may also present a challenge to interpret, due to changes in the intracranial hemodynamics and decrease in the diagnostic accuracy of ancillary tests that assess the brain circulation (6). The modified Frampas criteria have been showed to increase the sensitivity of CTA, particularly in patients with a skull defect (6). However, no specific studies address the role of CTP for confirmation of BD in those groups of patients, to our knowledge.

In this study, we aimed to compare the diagnostic performances of CTP and three different 4-point scoring systems in CTA in confirming BD in patients with and without skull defect.

## MATERIALS AND METHODS

### Study Population

This study was approved by the Institutional Review Board. Written informed consent was waived due to the retrospective nature of this study. The patients clinically diagnosed as BD in our tertiary center intensive care unit and having an ancillary test for cerebral circulatory arrest were selected. In the presence of a recognized severe brain injury, and after prerequisites have been met, the diagnosis of BD was decided clinically by two physicians, including a neurologist or a neurosurgeon, and an anesthesiologist or an intensivist with at least 3 years of experience in clinical diagnosis of BD related to their field (12). The diagnosis required the essential clinical criteria of BD (12, 13). All patients with a mean arterial pressure over 80 mm Hg underwent CTA and/or CTP at least 6 hours after clinical diagnosis of BD.

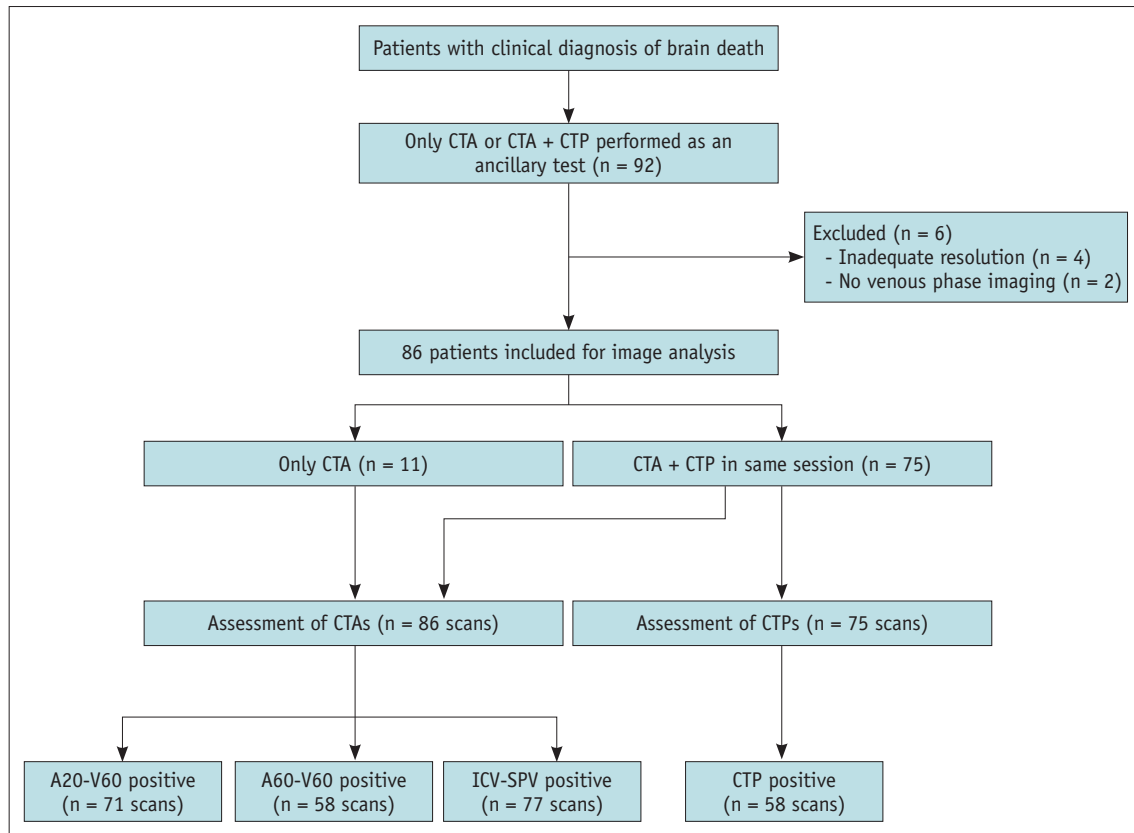
The CTA and CTP images of a consecutive series of 92 clinically diagnosed BD patients, between September 2014 and March 2018, were evaluated retrospectively. The inclusion criteria were clinical BD diagnosis confirmed by two physicians in a consensus, and the presence of CTA as an ancillary test. Exclusion criteria were the absence of BD by clinical diagnosis and technically inadequate radiological examination. The study flowchart is presented in Figure 1.

### Image Acquisition

All examinations were performed by a 128-detector (SOMATOM Definition AS, Siemens Healthineers) or 64-detector (Aquilion, Toshiba Medical Systems) CT scanner. The scanning parameters were 100 kVp, 200 mAs, section thickness of 0.6 mm, pitch 0.55, 220 mm field of view, and 512 x 512 matrix. All patients were hemodynamically stable and monitored during the examination and had a systolic pressure greater than 80 mm Hg.

CTA scans were acquired with the same routine protocol constituted of an unenhanced scan, arterial phase scan at the 20th and venous phase scan at the 60th second. After the unenhanced images, a total of 80–85 mL of nonionic iodinated contrast media (iobitridol, Xenetix; 350 mg iodine/mL, Guerbet) was injected at a rate of 3 mL/s.

CTP scans were performed with a bolus of contrast medium (40 mL) 10 minutes after CTA only if the patient was stable. Perfusion images were acquired between the level of the internal carotid artery bifurcation and the superior edge of the lateral ventricles to place the arterial



**Fig. 1. Study flowchart.** The ancillary test (CTA or CTP) is positive for confirmation of brain death when radiological findings were consistent with cerebral circulatory arrest. A20-V60 = 4-point scoring system that evaluate vessel opacification on arterial phase for arteries and venous phase for veins, A60-V60 = 4-point scoring system that evaluate vessel opacification on venous phase for both arteries and veins, CTA = computed tomography angiography, CTP = computed tomography perfusion, ICV-SPV = 4-point scoring system that evaluate vessel opacification on venous phase for internal cerebral vein and superior petrosal vein

input function to an appropriate vessel and achieve the qualitative assessment of the cerebral parenchyma. A section thickness of 10 mm was used with a total scan time of approximately 45 seconds. Regions of interest (ROIs) were placed automatically at the anterior cerebral artery for the arterial input, and at the superior sagittal sinus for venous outflow. The location of the ROI was determined manually in case the program was inadequate for the detection of the artery and vein. The semiautomatic postprocessing method was used in our protocol for cerebral blood flow (CBF), cerebral blood volume (CBV) and mean transit time maps.

### Image Analysis

All images were transferred to a workstation (Aquarius workstation, TeraRecon), providing unenhanced, arterial and venous phase images synchronically. The subtraction images of both arterial and venous phases were obtained. The accuracy of the technique was confirmed by normal

opacification of the superficial temporal arteries in the arterial phase. Images were re-evaluated independently according to three different 4-point scoring systems that assess four vessels opacification at different phases by three radiologists with one, five, and seven years of expertise in evaluating CTA and CTP in BD patients. Readers were blind to the neurological examination results, apnea test, and final radiological report. Assessment of CTA images were blinded to the CTP results. The reference and revised 4-point CTA scoring systems evaluated in the study were:

- 1) A60-V60: lack of opacification of the MCAs-M4 and ICVs evaluated at the venous phase. This is the reference 4-point scoring system introduced by Frampas et al. (4).
- 2) A20-V60: lack of opacification of MCAs-M4 evaluated at the arterial phase and ICVs at the venous phase. This is the revised arteriovenous scoring system, which was used by Nunes et al. (6).
- 3) ICV-SPV: lack of opacification of ICVs and SPVs evaluated at the venous phase. This is the revised venous

scoring system introduced by Marchand et al. (7).

A score of 1 was assigned to each of the non-opacified vessel segments. In CTA, findings were interpreted as cerebral circulatory arrest (i.e., positive for confirmation of BD) only when a score of 4 (i.e., non-opacification of all vessels) was achieved with each reference and revised 4-point scoring systems. All CTA evaluations were done qualitatively by visual assessment of vessel opacification in the subtracted series. The CTP images of 75 patients were evaluated independently and readers were blind to the CTA results of the patients. All CTP evaluation was done qualitatively by the visual assessment of perfusion in CBF and CBV maps, which were acquired by automatic calculation. A matched complete absence of perfusion in CBF and CBV maps was interpreted as cerebral circulatory arrest (i.e., positive confirmation of BD). The presence of partial or complete perfusion in the brain parenchyma in CTP was considered incompatible with BD. A quantitative analysis regarding ROI measurements for CBF and CBV was not performed to avoid bias that may be related to the study protocol (i.e., performing CTP after CTA). The CTA and CTP images of a patient with normal vasculature and cerebral perfusion are given as Supplementary Figure 1.

The presence of open skull defect (OSD) was noted during the evaluation of the CTA images by the readers and classified as decompressive craniectomy, shunt defect, craniotomy, and calvarial fracture.

Stasis filling of intracranial arteries was also evaluated in the CTA images. The stasis filling phenomenon, which was first described by Kricheff et al. (14) in 1978, is a common condition observed in angiographic studies in BD patients (15). It is a specific angiographic pattern of cerebral circulatory arrest, which can cause problems in interpretation of CTA results in the diagnosis of BD. Stasis filling is defined as a delayed, weak, persistent, and progressive opacification of the proximal segments of intracranial arteries, without opacification of the cortical branches or venous outflow found between the arterial and venous acquisitions of CTA (6, 15). In this study, the presence of the stasis-filling phenomenon in between the 20th and 60th second phases in CTA studies was evaluated independently by each reader. Discrepancies in interpretation were solved by a consensus of readers.

### Statistical Analysis

Statistical analysis was performed using SPSS software version 21.0 (IBM Corp.). The sensitivity of each scoring

system and the benefit of CTP were calculated. Sensitivity was defined as the percentage of BD patients who were correctly confirmed with the relevant imaging modality and criteria. McNemar test was used to compare the sensitivities of the A20-V20 and A60-V60 4-point scoring systems. The relationship between the stasis filling and OSD were evaluated by the chi-square test.

The degree of interobserver agreement was determined by using free marginal multirater kappa statistics (16). Kappa values, including the range of between 0 and 1, were classified as follows: < 0.20, poor agreement; 0.21–0.40, fair agreement; 0.41–0.60, moderate agreement; 0.61–0.80, good agreement; 0.81–1.00, very good agreement (17). *P* value < 0.05 was considered significant.

## RESULTS

Eighty-six patients, clinically diagnosed as BD (39 females, 47 males, age range 0–80 years, mean age  $\pm$  standard deviation,  $43.4 \pm 22.7$  years), including 15 pediatric patients (15/86, 17.4%), were included in our study. Six patients were excluded due to inadequate techniques and/or insufficient contrast filling. Detailed demographic data of the patients is summarized in Table 1.

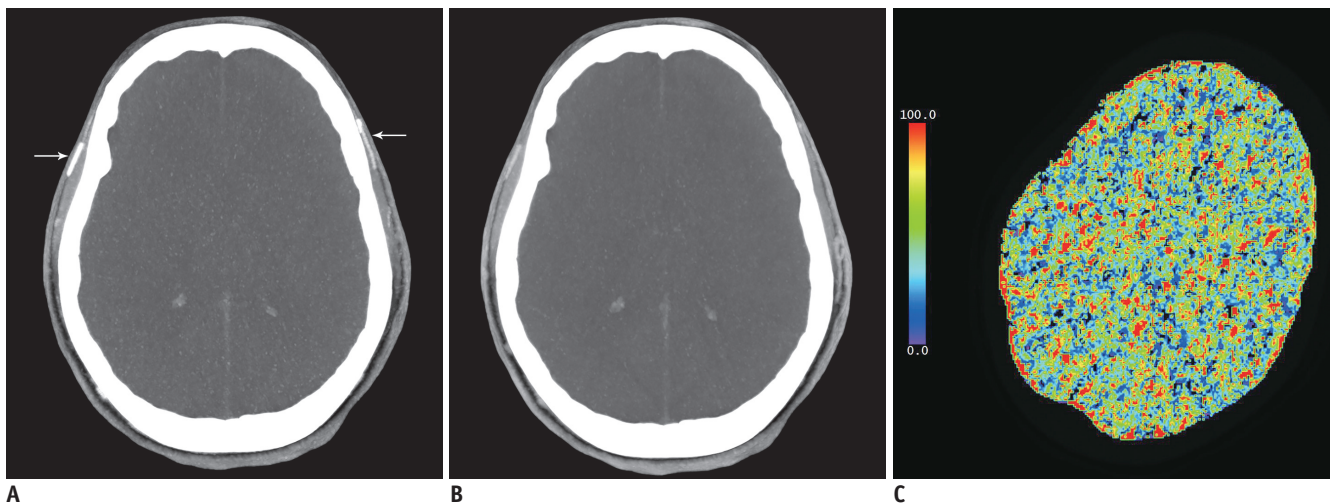
**Table 1. Demographic Data and Status of Skull Defect of the Patients Included in the Study**

Variable	Number (%)
Age (years)	43.4 $\pm$ 22.7
Sex	
Male	47 (54.7)
Female	39 (45.3)
Etiology of coma	
Intracranial hemorrhage	40 (46.5)
High energy trauma (motorcycle/car accident)	15 (17.4)
Cardiac arrest	10 (11.6)
Postoperative clinical conditions	8 (9.3)
Intoxication (methanol, CO, drug abuse)	7 (8.1)
Ischemic stroke	3 (3.4)
Infection (septic shock, skull base osteomyelitis)	2 (2.3)
Asphyxia	1 (1.1)
Open skull defect	
Absent	40 (46.5)
Present	46 (53.5)
Shunt defect	15 (32.6)
Decompressive craniectomy	12 (26.1)
Craniotomy	9 (19.5)
Extensive calvarial fracture	5 (10.8)
More than two skull defects	5 (10.8)

There were 46 patients (46/86, 53.5%) with OSD (12 patients had craniectomies, 15 had shunt defects, 9 had craniotomies, 5 had extensive calvarial fractures, 5 had more than two skull defects).

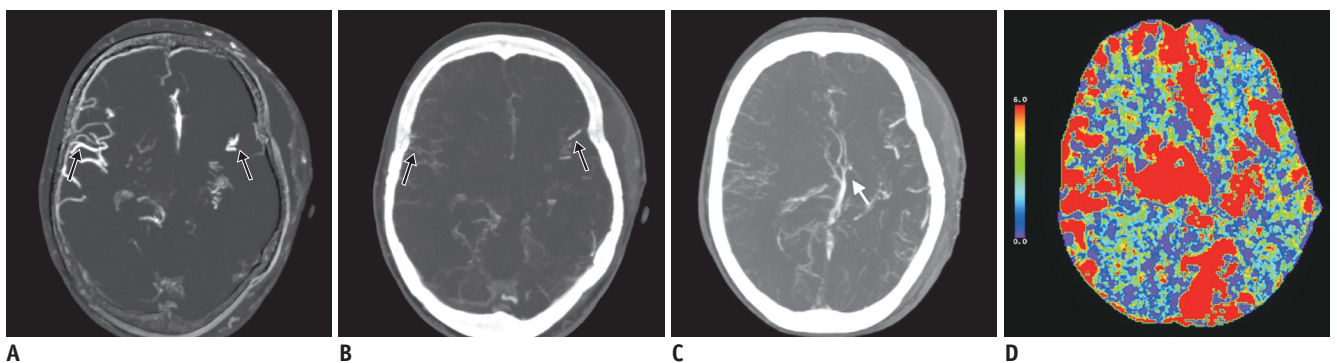
In 86 patients, the sensitivities of the ICV-SPV, A20-V60, A60-V60 4-point scoring systems in the diagnosis of cerebral circulatory arrest were 89.5%, 82.6%, and 67.4%, respectively (Fig. 2). Among the scoring systems of CTA, ICV-SPV was found to be the most sensitive method in the confirmation of BD. The sensitivity of the revised 4-point scoring system (A20-V60) was significantly higher when compared to that of the reference 4-point scoring system (A60-V60) ( $p < 0.001$ ).

Seventy-five patients had CTP in the study group. Seventy patients (70/75, 93.3%) had the absence of cerebral perfusion confirming the diagnosis of BD whereas in 5 patients (5/75, 6.7%) cerebral perfusion was maintained partially or totally (Fig. 3). When CTP was used as an adjunct to CTA and evaluated together, 8 patients using A20-V60 scoring, 19 patients using A60-V60 scoring and 3 patients using ICV-SPV scoring with initially false-negative results were confirmed with BD (true positives). In 75 patients, the sensitivities of the ICV-SPV, A20-V60, and A60-V60 4-point scoring systems were 89.3%, 82.6%, and 68.0%, respectively. The sensitivities of the CTA 4-point scoring systems were found to be increased when evaluated



**Fig. 2. A 19-year-old female patient clinically diagnosed as brain death due to diabetic ketoacidosis.**

The arterial phase axial MIP image (A) shows the contrast filling of the superficial temporal arteries, which indicates the adequacy of the technique (white arrows). Note the absence of an opacification of the MCAs. The venous phase MIP image (B) shows the absence of opacification of both the MCAs and ICVs. The CBF map (C) shows the lack of blood flow, which demonstrates the absence of cerebral perfusion (CBV and MTT maps not shown). This patient was interpreted as brain death according to both CTA and CTP images. CBF = cerebral blood flow, CBV = cerebral blood volume, ICV = internal cerebral vein, MIP = maximum intensity projection, MCA = middle cerebral artery, MTT = mean transit time



**Fig. 3. An 80-year-old female patient clinically diagnosed as brain death.**

The arterial phase axial MIP subtraction image (A) and venous phase axial MIP image (B) show the intense enhancement of the bilateral MCA-M4 segments, especially at the right side (black arrows). The white arrow indicates the opacification of ICVs on the venous phase axial MIP image (C). The CBF map (D) shows the partial cerebral parenchymal perfusion (CBF and MTT maps not shown). This patient was diagnosed as being brain dead clinically, but each 4-point scoring systems of CTA and CTP did not confirm the clinical diagnosis. MCA-M4 = M4 segment of the medial cerebral artery

**Table 2. Overall Sensitivities and Comparison of the Sensitivities of CTP and 4-Point Scoring Systems of CTA in Patients with and without Open Skull Defect**

	Overall Sensitivity	Open Skull Defect (-)	Open Skull Defect (+)	<i>p</i>
CTA (%)				
ICV-SPV	89.5	100	80.4	0.003
A20-V60	82.6	95.0	71.7	0.005
A60-V60	67.4	77.5	58.7	0.063
CTP (%)	93.3	100	86.5	0.019

*P* values refer to statistically significant difference between the sensitivities of CTA and CTP of the open skull defect absence (-) and presence (+) group. A20-V60 = 4-point scoring system that evaluate vessel opacification on arterial phase for arteries and venous phase for veins, A60-V60 = 4-point scoring system that evaluate vessel opacification on venous phase for both arteries and veins, CTA = computed tomography angiography, CTP = computed tomography perfusion, ICV-SPV = 4-point scoring system that evaluate vessel opacification on venous phase for internal cerebral vein and superior petrosal vein

with CTP. However, these sensitivities were similar to the assessment of CTP alone (93.3%).

In patients with OSD, the sensitivity of each scoring system was lower when compared to that of the intact skull group. Sensitivities of the ICV-SPV, A20-V60, A60-V60 4-point scoring systems of CTA and CTP in the OSD group were 80.4%, 71.7%, 58.7%, and 86.5%, respectively (Table 2). CTP was found to be the most sensitive method in patients with OSD (Figs. 4, 5).

Stasis filling was demonstrated in 54 patients (54/86, 62.7%). Among these, 28 (28/54, 51.8%) of them had OSD. The relation between OSD and stasis filling was not statistically significant ( $p = 0.693$ ).

Interobserver agreement of three radiologists with different experience levels in the diagnosis of cerebral circulatory arrest was found excellent in assessing the A20-V60, A60-V60, ICV-SPV scoring systems of CTA and CTP. Kappa values were calculated as 0.84, 0.83, 0.83, and 0.83 respectively. In evaluating the stasis filling, agreement was good with the kappa value of 0.67.

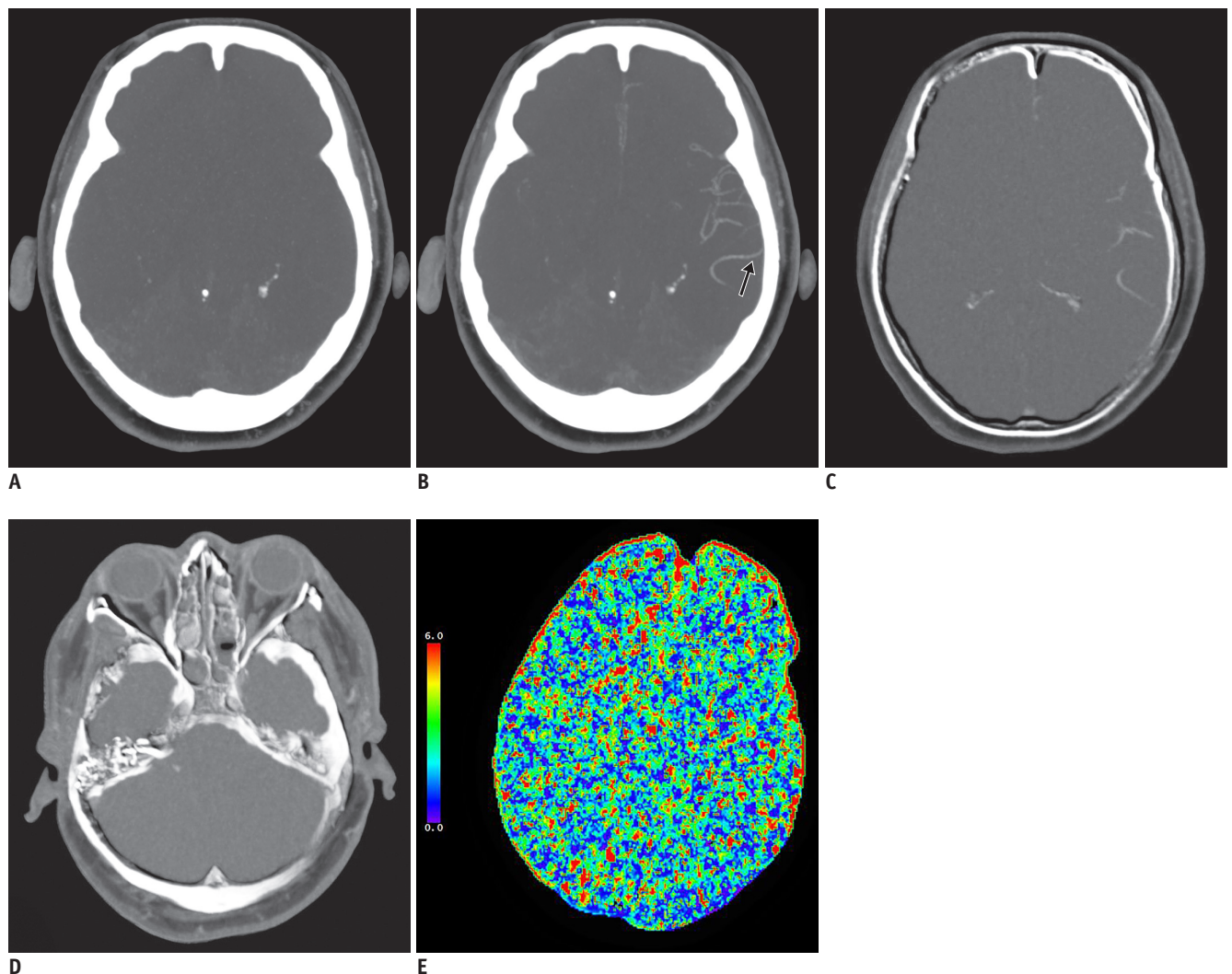
## DISCUSSION

In comparison to the 4-point scoring systems of CTA, ICV-SPV scoring was found to be the most sensitive method in the diagnosis of cerebral circulatory arrest in this study. A revised 4-point scoring (A20-V60), evaluating arteries in the arterial phase and veins in the venous phase, was found to have a higher sensitivity when compared with the

reference 4-point scoring (A60-V60) (sensitivities 82.6% and 67.4%, respectively). In addition, the sensitivity of a combined protocol of CTA-CTP was found to be higher than that of CTA alone in the whole cohort and OSD group (sensitivities 93.3% and 86.5%, respectively). Interobserver agreement among three readers with different levels of experience was excellent in assessing the 4-point scoring systems and CTP.

The differences in technique, interpretation of CTA at different phases, and using different CTA scoring systems resulted in wide variations in sensitivity (18). The 4-point CTA scoring system has been accepted as the most reliable scoring among other CTA scoring systems in the diagnosis of BD, although some challenges still exist with the reference 4-point scoring system (4, 19, 20). Welschhold et al. (19) evaluated the arteries in the arterial phase and found higher sensitivity than in the single venous phase evaluation (sensitivities 95% and 65%, respectively). Recently, Nunes et al. (6) reported that false negative diagnoses of BD, which were mainly due to stasis filling, significantly reduced when the revised criteria was used instead of the reference criteria. The results of those studies were compatible with our study. Apart from those scoring systems, a revised 4-point venous scoring system (ICV-SPV) was proposed by Marchand et al. (7) in 2016 with a 95% sensitivity for confirming clinical BD. However, in their study, they reported that anatomical variations in SPV might cause difficulties in the analysis (7). In our opinion, beam hardening artifacts or confounding situations such as brainstem herniation or subarachnoid hemorrhage around the brainstem may also be a challenge in the assessment of opacification of SPV.

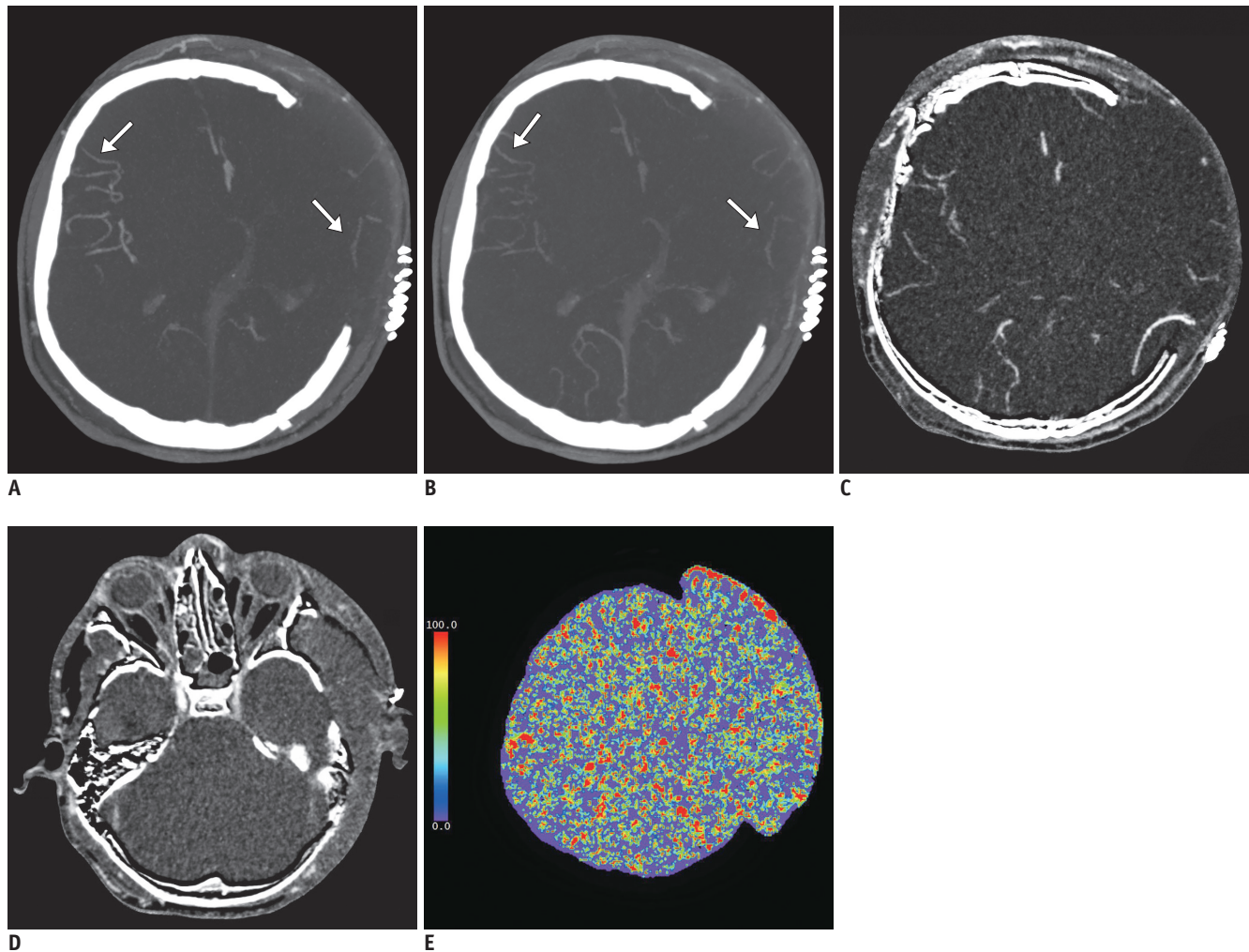
It has been shown that in 15% of patients meeting clinical criteria for BD, conflicting results may arise between CTA and CTP in which CTA shows some persistent intracranial flow but CTP shows absence in cerebral perfusion (11, 18). Recently, Sawicki et al. (11) compared to the 4-point CTA scoring system and CTP in the diagnosis of BD and found the sensitivity of each method to be 86% and 100%, respectively. In their study, the opacification of the distal segments of MCAs and/or ICVs on CTA were the cause of false negative CTA results in 7 patients. According to their results, they suggested the combination of CTP with CTA in cases with negative CTA results for BD, which was also in parallel with our opinions. Additionally, we compared CTA scoring systems and CTP in particular groups of patients with OSD, which was different from other studies. Our



**Fig. 4. A 54-year-old female patient clinically diagnosed as brain death after an anaphylactic reaction due to an antibiotic.** The patient's skull was intact. The arterial phase axial MIP image (A) shows the absence of opacification of the MCAs. The venous phase MIP image (B) shows the opacification of the distal segments of the left MCA (black arrow) due to stasis filling. Venous phase axial MIP subtraction images (C, D) show the absence of opacification of ICVs and SPVs which was interpreted as a cerebral circulatory arrest by ICV-SPV scoring. The CBV map (E) shows the lack of blood flow, which demonstrates the absence of cerebral perfusion (CBF and MTT maps not shown). These findings were evaluated as brain death according to both the revised 4-point scoring systems (A20-V60 and ICV-SPV) and CTP; whereas the reference 4-point scoring system (A60-V60) was not compatible with brain death. SPV = superior petrosal vein

results revealed that the use of CTP combined with CTA could contribute to the confirmation of BD diagnosis to decrease the false negative results of CTA, especially in this group of patients. Another important point in their study (11) was that they formed the study group from patients with an intact skull and found a 100% sensitivity for CTP, which was similar with our result in patients without OSD. This could be explained by the fact that CBF reduces significantly as the intracranial pressure exceeds the mean arterial pressure in patients with intact skull, thus this group is less likely to be affected by preserved intracranial filling compared to patients with OSD (15).

Substantial variability still exists in the clinical diagnosis of BD and in how physicians approach this examination (21). According to some national guidelines, the determination of BD requires a consensus opinion with at least two physicians. However, there is no published requisite on a consensus report for CTA or CTP. In our study, the interobserver agreement among three reviewers with different levels of experience was found to be excellent in assessing the 4-point scoring systems and CTP, and good in stasis filling. Similarly, interobserver agreement for the 10-point, 7-point, and 4-point scoring systems were found to be high for all scales in previous studies



**Fig. 5. A 15-year-old male patient clinically diagnosed as brain death with decompressive craniectomy which led to extracranial herniation.**

The arterial phase axial MIP image (A) and venous phase axial MIP image (B) show the contrast filling of bilateral MCA-M4 segments, especially at the right side (white arrows). The venous phase axial MIP subtraction images (C, D) demonstrate the absence of opacifications of the ICVs and SPVs. The CBF map (E) shows the lack of blood flow, which demonstrates the absence of cerebral perfusion (CBV and MTT maps not shown). In this patient, the CTP and the revised 4-point scoring system (ICV-SPV) confirmed brain death, but the other two CTA scoring systems were falsely negative for brain death.

(22, 23). Concerning our study, the excellent compliance of CTA 4-point scoring systems could be explained by using the subtraction images. The baseline density of the subarachnoid space, which may cause false negative results in subarachnoid hemorrhage and pseudosubarachnoid hemorrhage, was aimed to be eliminated with subtraction technique (22).

There are some limitations in our study. First, there was no control group for the BD patients, which hindered us from analyzing the specificity of CTA and CTP. Yet, this is one of the main limitations in many studies on BD. Although some previous studies involve control groups including acute ischemic stroke patients, their neurological

statuses are not clearly defined (6). To investigate the real specificity of those techniques in future studies, the control groups should involve patients who are comatose, have locked-in syndrome or in a persistent vegetative state with negative results for BD. Second, our results were not compared with other invasive or noninvasive confirmatory tests. However, all of our patients had a clinical diagnosis of BD including an apnea test. Third, CTP was performed after CTA in our study. In our routine imaging protocol for BD, we performed CTA before the CTP, since CTP has not yet been proven as a diagnostic test to replace CTA in BD diagnosis. Hence, contrast stasis in vessels may potentially create a limitation for CTP. In our opinion, since contrast



stasis may affect the ROI measurements of CBF and CBV maps, quantitative analysis could cause false negative results in this protocol. Therefore, we thought that visual analysis would be more appropriate for this study. To minimize the limitation of visual analysis, the interobserver agreement was evaluated and found to be excellent in assessing CTP images.

In conclusion, the accuracy of CTA varies according to the scoring system used for BD confirmation. Although the ICV-SPV scoring system was found to be the most sensitive method among three different 4-point CTA scoring systems in this study, the evaluation of the SPV opacification may be challenging and, in our opinion, it is not as practical as that of the ICVs. In the pursuit of new sensitive and feasible techniques for BD confirmation, CTP might be a viable method with a promising contribution to CTA. Furthermore, CTP could increase the sensitivity of CTA especially in the presence of OSD, which is frequently encountered among BD patients. However, future studies including control groups are needed to be designed to reveal the role of CTP in this area.

## Supplementary Materials

The Data Supplement is available with this article at <https://doi.org/10.3348/kjr.2019.0859>.

## Conflicts of Interest

The authors have no potential conflicts of interest to disclose.

## ORCID iDs

Asli Irmak Akdogan

<https://orcid.org/0000-0002-6262-1799>

Yeliz Pekcevik

<https://orcid.org/0000-0003-1421-3376>

Hilal Sahin

<https://orcid.org/0000-0001-8726-8998>

Ridvan Pekcevik

<https://orcid.org/0000-0002-5706-5011>

## REFERENCES

1. Wijdicks EFM. Determining brain death in adults. *Neurology* 1995;45:1003-1011
2. Manara AR. All human death is brain death: the legacy of the Harvard criteria. *Resuscitation* 2019;138:210-212
3. Wahlster S, Wijdicks EFM, Patel PV, Greer DM, Hemphill JC 3rd, Carone M, et al. Brain death declaration: practices and perceptions worldwide. *Neurology* 2015;84:1870-1879
4. Frampas E, Videcoq M, de Kerviler E, Ricolfi F, Kuoch V, Mourey F, et al. CT angiography for brain death diagnosis. *AJNR Am J Neuroradiol* 2009;30:1566-1570
5. Leclerc X, Taschner CA, Vidal A, Strecker G, Savage J, Gauvrit JY, et al. The role of spiral CT for the assessment of the intracranial circulation in suspected brain-death. *J Neuroradiol* 2006;33:90-95
6. Nunes DM, Maia ACM Jr, Boni RC, da Rocha AJ. Impact of skull defects on the role of CTA for brain death confirmation. *AJNR Am J Neuroradiol* 2019;40:1177-1183
7. Marchand AJ, Seguin P, Malledant Y, Taleb M, Raoult H, Gauvrit JY. Revised CT angiography venous score with consideration of infratentorial circulation value for diagnosing brain death. *Ann Intensive Care* 2016;6:88
8. Escudero D, Otero J, Marqués L, Parra D, Gonzalo JA, Albaiceta GM, et al. Diagnosing brain death by CT perfusion and multislice CT angiography. *Neurocrit Care* 2009;11:261-271
9. Shankar JJ, Vandorpe R. CT perfusion for confirmation of brain death. *AJNR Am J Neuroradiol* 2013;34:1175-1179
10. Bohatyrewicz R, Sawicki M, Walecka A, Walecki J, Rowinski O, Bohatyrewicz A, et al. Computed tomographic angiography and perfusion in the diagnosis of brain death. *Transplant Proc* 2010;42:3941-3946
11. Sawicki M, Sołek-Pastuszka J, Chamier-Ciemińska K, Walecka A, Walecki J, Bohatyrewicz R. Computed tomography perfusion is a useful adjunct to computed tomography angiography in the diagnosis of brain death. *Clin Neuroradiol* 2019;29:101-108
12. Wijdicks EFM, Varelas PN, Gronseth GS, Greer DM. Evidence-based guideline update: determining brain death in adults: report of the Quality Standards Subcommittee of the American Academy of Neurology. *Neurology* 2010;74:1911-1918
13. Drake M, Bernard A, Hessel E. Brain death. *Surg Clin North Am* 2017;97:1255-1273
14. Kricheff II, Pinto RS, George AE, Braunstein P, Korein J. Angiographic findings in brain death. *Ann N Y Acad Sci* 1978;315:168-183
15. Sawicki M, Bohatyrewicz R, Safranow K, Walecka A, Walecki J, Rowinski O, et al. Dynamic evaluation of stasis filling phenomenon with computed tomography in diagnosis of brain death. *Neuroradiology* 2013;55:1061-1069
16. Randolph JJ. *Free-marginal multirater kappa (multirater  $\kappa_{free}$ ): an alternative to Fleiss' fixed-marginal multirater kappa*. Joensuu learning and instruction symposium;2005 October 14-15;Joensuu, Finland
17. Altman DG. *Practical statistics for medical research*, 1st ed. London: Chapman and Hall, 1991
18. Kramer AH, Roberts DJ. Computed tomography angiography in the diagnosis of brain death: a systematic review and meta-analysis. *Neurocrit Care* 2014;21:539-550
19. Welschehold S, Kerz T, Boor S, Reuland K, Thömke F, Reuland A, et al. Detection of intracranial circulatory arrest in brain

- death using cranial CT-angiography. *Eur J Neurol* 2013;20:173-179
20. Welschehold S, Kerz T, Boor S, Reuland K, Thömke F, Reuland A, et al. Computed tomographic angiography as a useful adjunct in the diagnosis of brain death. *J Trauma Acute Care Surg* 2013;74:1279-1285
21. Braksick SA, Robinson CP, Gronseth GS, Hocker S, Wijidicks EFM, Rabinstein AA. Variability in reported physician practices for brain death determination. *Neurology* 2019;92:e888-e894
22. Sawicki M, Bohatyrewicz R, Safranow K, Walecka A, Walecki J, Rowinski O, et al. Computed tomographic angiography criteria in the diagnosis of brain death-comparison of sensitivity and interobserver reliability of different evaluation scales. *Neuroradiology* 2014;56:609-620
23. Şahin H, Pekçevik Y. CT angiography as a confirmatory test in diagnosis of brain death: comparison between three scoring systems. *Diagn Interv Radiol* 2015;21:177-183