

Evaluation of demographic and rare clinical characteristics of patients with thoracic carcinoid tumor in Razi and Aria Hospitals of Rasht during 2006-2016

Manouchehr Aghajanzadeh, Mohammad Reza Asgary, Ali Alavi Fomani, Alireza Jafarinagad, Azita Tangestaninejad, Hossein Hosseinzadeh Asli, Maryam Ahmad Khan beige, Rastin Hosseinzadeh Asli, Mohammad Madi Asgari

Inflammatory Lung Diseases Research Center, Department of Internal Medicine, Razi Hospital, School of Medicine, Guilan University of Medical Sciences, Rasht, Iran

ABSTRACT

Introduction: Carcinoid tumors are malignant neoplasms of neuroendocrine cells. This study tended to evaluate the demographic and rare clinical characteristics of patients with thoracic carcinoid tumor during 2006-2016 at Razi and Aria Hospitals in Rasht. **Materials and Methods:** The present study was performed on records of 43 patients with lung carcinoid tumors referred to Razi and Aria Hospitals of Rasht during 2006-2016. Information on age, gender, rare clinical symptoms, smoking history, diagnosis tools, treatment, and outcome were analyzed. **Results:** Of 43 patients treated with definitive diagnosis of carcinoid tumor pathology, 31 patients had typical carcinoid tumor and 12 patients with atypical carcinoma (mean age 43.14 ± 15.16 years). The most common clinical symptom was cough and hemoptysis. Two cases presented with Cushing syndrome. The most common diagnostic method in this study was simultaneous use of both CT scans and bronchoscopy. In 95.3% of cases, the tumor was pulmonary and in 4.7% of cases, it was extrapulmonary. Right lower lobe was the most common site of tumors and most of the surgeries used were lobectomy. **Conclusion:** This study showed that the most common clinical sign of thoracic carcinoid is cough and the tumor is pulmonary in 95.3% of cases. Right lower lobe was the most common site of tumors and most of the surgeries used were lobectomy. outcome was good.

Keywords: Carcinoid tumor, chest, demographic

Introduction

The incidence of neuroendocrine tumors has been increasing in recent years.^[1] Neuroendocrine tumors are uncommon, slow-growing neoplasms with incidence of 1-2

in 100,000 patients.^[2-4] Carcinoid tumors were described first in 1882. In 1930, it was classified and designated as bronchial adenoma.^[5] Carcinoid tumors originate from neuroendocrine cells and are slow-growing tumors.^[6] In terms of embryology, carcinoid tumor originate from any part of the foregut, such as stomach, duodenum, gall bladder, pancreas and from trachea, bronchus, and lung.^[5] Limited information is currently available on long-term clinical prognosis and prognostic factors of these tumors.^[7] The use of newer diagnostic techniques, including biochemical, immunohistochemical, and molecular methods,

Address for correspondence: Dr. Mohammad Reza Asgary, Inflammatory Lung Diseases Research Center, Department of Internal Medicine, Razi Hospital, School of Medicine, Guilan University of Medical Sciences, Rasht, Iran.
E-mail: tsasgary85@yahoo.com

Received: 25-10-2021

Revised: 03-03-2022

Accepted: 14-04-2022

Published: 14-10-2022

Access this article online

Quick Response Code:



Website:
www.jfmpc.com

DOI:
10.4103/jfmpc.jfmpc_2134_21

This is an open access journal, and articles are distributed under the terms of the Creative Commons Attribution-NonCommercial-ShareAlike 4.0 License, which allows others to remix, tweak, and build upon the work non-commercially, as long as appropriate credit is given and the new creations are licensed under the identical terms.

For reprints contact: WKHLRPMedknow_reprints@wolterskluwer.com

How to cite this article: Aghajanzadeh M, Asgary MR, Fomani AA, Jafarinagad A, Tangestaninejad A, Asli HH, *et al.* Evaluation of demographic and rare clinical characteristics of patients with thoracic carcinoid tumor in Razi and Aria Hospitals of Rasht during 2006-2016. *J Family Med Prim Care* 2022;11:5437-41.

has had a significant effect on identification, diversity of histopathological species, clinical behavior, and prognosis of these tumors. The new WHO classification, considering the biological behavior of tumors based on tumor location and differentiation rate, is useful both clinically and in terms of prognostic factors.^[8] Neuroendocrine carcinoma is a neoplasm of the neuroendocrine system, which contains organs in which amine precursor uptake and decarboxylation (APUD) cells are uncommon. Neuroendocrine carcinoma has been found in a wide range of organs in humans and animals.^[9] In animals, this carcinoma has been reported in the intestines, liver, bile ducts, lungs, gall bladder, esophagus, nasal cavity, and skin.^[10,11] most of which are highly invasive.^[11-14] In the human body, the most common site of neuroendocrine carcinoma is the gastrointestinal tract and the lung.^[9,15] Bronchopulmonary carcinoid tumor comprises 1 to 2% of all malignant lung tumors. Surgery is the most effective treatment of all types of lung carcinoid tumors. Chemotherapy and radiotherapy have no effective role in treatment of these tumors, although they are used in treatment of advanced carcinoid tumors.^[16] Surgical treatment is not recommended in cases where the tumor is locally advanced and encounters adjacent vital structures.^[17] Therefore, demographic and clinical characteristics can be helpful in diagnosis, treatment, and evaluation of prognosis.

Materials and Methods

Population and sampling

Participants included all patients with lung carcinoid tumors who were treated during 2006-2016 at Razi and Aria Hospitals of Rasht (Guilan University of Medical Sciences). Pathologic responses were obtained from Razi Laboratory, Sina Laboratory, and Dr. Ashtiani Laboratory. In this study, all patients with lung carcinoid tumors who had undergone surgical treatment for the past 11 years (2006-2016) were evaluated.

Methods

In this retrospective cross-sectional study, all patients with lung carcinoid tumor who were treated during 2006-2016 at Razi and Aria Hospitals of Rasht (Guilan University of Medical Sciences) and in collaboration with the Sina, Razi, and Dr. Ashtiani's laboratories were examined. In this study, the exact type of tumor and all the information about thoracic carcinoid tumor is based on pathology. The studied data included age, gender, tumor location, metastatic status, tumor location, site of involvement, history of smoking, type of tumor (typic or atypic), resection type, diagnostic methods, signs, and symptoms of the disease. Forms were designed as checklists to extract information. Non-probabilistic convenient sampling was used.

Data analysis

The collected data were inserted into SPSS software version 22. Descriptive indices including frequency, frequency percentage, mean, and standard deviation were used to report descriptive data. Independent t-test was used to determine the relationship between patient gender and age ($p < 0.05$).

Ethical considerations

The information obtained from the patient files will be kept confidential and the results will be published in full in the form of information from the studied group and the results will be presented without mentioning their names and personal details.

Results

Gender and age

Of 43 patients (39.5%), 17 were male and 26 (60.5%) were female. The mean age of the patients was 43.14 ± 15.16 years. Maximum and minimum age of patients were 78 and 17 years, respectively. After dividing the age of the patients into 10-year groups, the majority of patients were in the age range of 31-40 years. The mean age of males was 44.82 ± 14.12 years and the mean age of females was 42.03 ± 15.97 years and there was no significant difference between males and females in terms of age ($p = 0.562$).

Diagnostic methods

The most common diagnostic method in this study was simultaneous use of CT scan and bronchoscopy with 27 cases (62.8%), followed by bronchoscopy with nine cases (20.9%) and CT scan with seven cases (16.3%) [Figure 1].

Smoking and symptoms

In this study, nine patients (20.9%) were smokers, 32.4% (74.4%) had no history of smoking and 4.7% had quit smoking [Figure 2]. The most common symptoms observed in this study were cough, hemoptysis, pneumonia, shortness of breath, fever, chest pain, sputum, and Cushing's syndrome [Table 1].

Location, most affected site, and type of tumor

Forty-one (95.3%) cases had pulmonary tumor and 2 (4.7%) cases had extrapulmonary tumor. The most frequent lung involvement was right lower lobe with 25.6% [Figure 3]. Right lower lobe was the most frequently observed tumor site (25.6%). There was no significant relationship between smoking and tumor site ($p = 0.511$) [Table 2]. In 31 cases (72.1%), the tumor was typic and 12 cases (27.9%) had atypic tumor. There was no significant relationship between type of tumor and age ($p = 0.127$). There

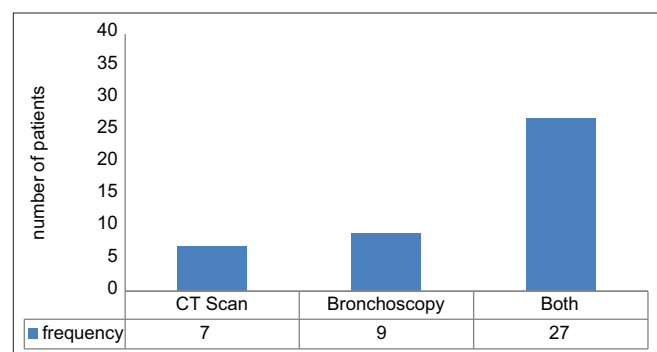


Figure 1: Frequency of diagnostic methods

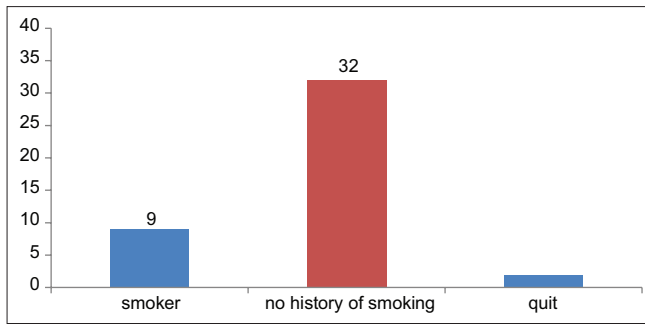


Figure 2: Frequency of smoking in patients

was no significant relationship between smoking and type of tumor ($p = 0.687$).

Performed surgeries

The most common surgeries included lobectomy (26 cases), followed by segmental resection, pneumonectomy, sleeve resection, lung wedge resection, and bilobectomy [Table 3].

In this study, 43 patients were studied, with three cases of recurrence in the atypical group which occurred within one and five years and one case in the typical group in year 8 undergoing surgical treatment of wedge resection. Ten-year survival was observed in the typical form (90%) and in atypical type (60-70%). In recurrent cases, lobectomy or pneumonectomy was performed. There was one case of hospital mortality that occurred during surgery due to tumor aspiration and removal during manipulation, and the patient was not anesthetized with double lumen. The observed complication was atelectasis in four patients who recovered with physiotherapy. Air leaks were also observed in two patients who recovered spontaneously. The average length of hospital stay was six days.

Discussion

Lung carcinoid tumor originates from a specific group of bronchial epithelial cells that have neuroendocrine activity. Carcinoid tumors, despite their slow growth and slow progression, are considered malignant because they have the ability to invade surrounding tissues locally and metastases.^[18] The preferred treatment for all types of carcinoid tumors is surgery, since chemotherapy and radiotherapy have little effect in treatment of this disease.^[19] Of 43 patients studied, 17 (39.5%) were male and 26 (60.5%) were female. The mean age of the patients was 43.14 ± 15.16 years. Maximum and minimum age of patients were 78 and 17 years, respectively. The majority of people were in the age range of 31-40 years. There was no significant difference between males and females in terms of age. The most common diagnostic method used in this study was simultaneous use of CT scan and bronchoscopy, followed by bronchoscopy and CT scan. Moreover, 20.9% of patients were smokers and most of the symptoms were cough, hemoptysis, pneumonia, shortness of breath, fever, chest pain, sputum, and Cushing's syndrome, respectively. In 95.3% of

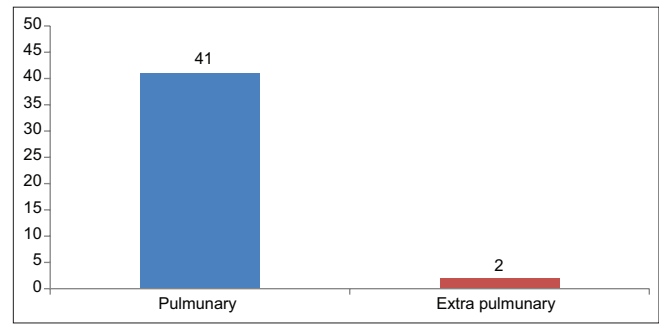


Figure 3: Frequency of tumor site in the studied patients

Table 1: Symptoms by frequency and percentage

| Symptoms | n | % |
|---------------------|----|------|
| Hemoptysis | 36 | 83.7 |
| Cough | 37 | 86 |
| Shortness of breath | 10 | 23.3 |
| Pneumonia | 16 | 37.2 |
| Chest pain | 3 | 7 |
| Fever | 8 | 18.6 |
| Sputum | 2 | 4.7 |
| Cushing's syndrome | 2 | 4.7 |

Table 2: Site of involvement by frequency and percentage

| Tumor site | n | % |
|-----------------------|----|------|
| Right Main Bronchus | 7 | 16.3 |
| Right Upper Lobe | 6 | 14 |
| Right Middle Lobe | 2 | 4.7 |
| Right Lower Lobe | 11 | 25.6 |
| Left Main Bronchus | 4 | 9.3 |
| Left Upper Lobe | 5 | 11.6 |
| Lingula | 1 | 2.3 |
| Left Lower Lobe | 3 | 7 |
| Carina Angle | 2 | 4.7 |
| Posterior Mediastinum | 1 | 2.3 |
| Thymus | 1 | 2.3 |

Table 3: Type of surgery by frequency and percentage

| Type of surgery | n | % |
|-----------------------|----|------|
| Lobectomy | 26 | 60.5 |
| Pneumonectomy | 4 | 9.3 |
| Sleeve Resection | 3 | 7 |
| Segmental Resection | 5 | 11.6 |
| Lung Wedge Resection | 3 | 7 |
| Bilobectomy Resection | 2 | 4.7 |

the cases, the tumor was pulmonary and in 4.7% of the cases it was extrapulmonary. The most frequent lung involvement was in the right lower lobe with 25.6%. In 72.1% of cases, the tumor was typical and in 27.9%, it was atypical. There was no significant relationship between tumor type and age. The most common surgeries included lobectomy (26 cases), followed by segmental resection, pneumonectomy, sleeve resection, lung wedge resection, and bilobectomy resection.

Arab *et al.*^[20] conducted a study in 2007 to evaluate clinical features, diagnostic, and therapeutic practices on lung carcinoid tumors at Masih Daneshvari Hospital within 11 years (1997-2007). There was no statistically significant difference between male and female patients, which is consistent with the results of this study. The history of smoking in 14 patients (19.2%) was consistent with the results of our study. The most common clinical symptoms were hemoptysis and cough, which is consistent with the results of our study. The final pathologic response was typical carcinoid in 81.8% and atypical carcinoid in 12.1% and tumor was not found in 6.1%. Concerning the prevalence of typical carcinoid, it is consistent with our results. Herde *et al.*^[21] evaluated the clinical and radiologic symptoms and treatment of patients with carcinoid tumor on records of 21 patients with lung carcinoid. Of 21 patients treated with definitive diagnosis of carcinoid tumor pathology, 19 patients had typical carcinoid tumor and 2 patients had atypical carcinoma, which is consistent with our results. As Klöppel G *et al.*^[9] reported, the right bronchus was most frequently involved. This is in contrast to the results reported by Fink *et al.*^[22] and Ronchod *et al.*^[23] who introduced the right lobe, or Okike *et al.*^[24] who reported the lower right and left lobes as the sites most affected. Surgery was the most common treatment in our study and lobectomy was performed more than pneumonectomy, which was similar to other studies.^[25-28] Morandi *et al.*^[29] reported in 2006 that carcinoid tumors had an equal prevalence of gender and appeared to occur in women at a younger age than men (although this difference was not statistically significant). There was a history of smoking in 30% of patients with typical carcinoid and 60-80% of patients with atypical carcinoid, but there was no statistically significant difference, which is consistent with our results. The significance of diagnosing this tumor lesion is that: First, due to slow tumor growth, nonspecific symptoms including cough, shortness of breath, and wheezing, it is sometimes confused with pulmonary disease and treated with inhaled and systemic bronchodilators. Second, carcinoid tumor treatment is complete resection of the tumor through surgery. Third, recurrence of the lesion is very low with timely surgical treatment. Therefore, this disease should be considered in patients with chronic cough, recurrent pneumonia, localized or even diffuse pneumonia, stridor, and hemoptysis.^[21,30]

Conclusion

According to results of the present study, the majority of people were in the age range of 31-40 years. There was no statistically significant difference between males and females in terms of age. The most common diagnostic method used in this study was simultaneous use of CT scans and bronchoscopy. The most common symptoms observed in this study were cough and hemoptysis. In 95.3% of the cases, the tumor was pulmonary and in 4.7% of the cases, it was extrapulmonary and the most frequent lung involvement was in the right lower lobe. In 72.1% of the cases, it was typical and in 27.9%, it was atypical. There was no significant relationship between tumor type and age. The most common surgery was lobectomy (n = 26), followed by segmental resection,

pneumonectomy, sleeve resection, lung wedge resection, and bilobectomy resection.

Financial support and sponsorship

Nil.

Conflicts of interest

There are no conflicts of interest.

References

1. Kocha W, Maroun J, Kennecke H, Law C, Metrakos P, Ouellet JF, Reid R, *et al.* Consensus recommendation for the diagnosis and management of well differentiated gastroenterohepatic neuroendocrine tumours. *Curr Oncol* 2010;17:49-64.
2. Durante C, Boukheris H, Dromain C, Duvillard P, Leboulleux S, Elias D, *et al.* prognostic factors influencing survival from metastatic (stage IV) gastroenteropancreatic well differentiated endocrine carcinoma. *Endocr Relat Cancer* 2009;16:585-97.
3. Rosenau J, Bahr MJ, Wasielewski R, Mengel M, Schmidt HH, Nashan B, *et al.* Ki67, as a prognostic indicator of long term outcome after liver transplantation for metastatic neuroendocrine tumour. *Clin Transplant* 2002;73:386-94.
4. Touzios JG, Kiely JM, Pitt SC, Rilling WS, Quebbeman EJ, Wilson SD, *et al.* Neuroendocrine hepatic metastasis: Does aggressive management improve survival? *Ann Surg* 2005;241:776.
5. Jochmanova I, Abcede AMT, Guerrero RJS, Malong CLP, Wesley R, Huynh T, *et al.* Clinical characteristics and outcomes of SDHB-related pheochromocytoma and paraganglioma in children and adolescents. *J Cancer Res Clin Oncol* 2020;146:1051-63.
6. Marchevsky AM. Neuro endocrine tumors of the lung. In: Marchevsky AM, editor. *Surgical Pathology of Lung Neoplasms*. New York: Marcel Dekker; 1990. p. 246-88.
7. Modlin IM, Sandor A. Analysis of 8305 cases of carcinoid tumors. *Cancer* 1997;79:813-29.
8. Sun TY, Hwang G, Pancirer D, Hornbacker K, Codima A, Lui NS, *et al.* Diffuse idiopathic pulmonary neuroendocrine cell hyperplasia: Clinical characteristics and progression to carcinoid tumour. *Eur Respir J* 2022;59:2101058. doi: 10.1183/13993003.01058-2021.
9. Klöppel G, Perren A, Heitz PU. The gastroenteropancreatic neuroendocrine cell system and its tumors: The WHO classification. *Ann N Y Acad Sci* 2004;1014:13-27.
10. Kulve MH, Mayer RJ. Carcinoid tumors. *N Engl J Med* 1999;340:858-68.
11. Pantnaik AK, Liu SK, Johnson GF. Feline intestinal adenocarcinoma: A clinicopathologic study of 22 cases. *Vet Pathol* 1976;13:1-10.
12. Arnold R. Diagnosis and management of neuroendocrine tumors. *United Eur Gastroenterol Week* 2001;8:1-12.
13. Pantnaik AK. Canine and feline nasal and paranasal neoplasms. In: Reznik G, editor. *Morphology and Origin of Nasal Tumor in Animals and Man*. 2nd ed, vol 2. Boca Raton, FL: CRC Press; 1983. p. 199-228.
14. Pantnaik AK. A morphologic and immunity to chemical study of hepatic neoplasms in cats. *Vet Pathol* 1992;29:405-15.

15. Pantnaik AK, Lieberman PH, Hurvitz AJ, Johnen GF. Canine hepatic carcinoids. *Vet Pathol* 1981;18:445-53.
16. Al-khafaji B, Noffsinger AE, Miller MA, Devoe G, Stemmermann NU, Fenoglio-presser C. Immunohistologic analysis of GI and pulmonary carcinoid tumors. *Hum Pathol* 1998;29:992-9.
17. Naalsund A, Rostad H, Strom EH, Lund MB, Strand TE. Carcinoid lung tumors-incidence, treatment and outcomes: A population-based study. *Eur J Cardiothorac Surg* 2011;39:565-9.
18. Srirajaskanthan R, Toumpanakis C, Karpathakis A, Marelli L, Quigley AM, Dusmet M, *et al.* Surgical management and palliative treatment in bronchial neuroendocrine tumors: A clinical study of 45 patients. *Lung Cancer* 2009;65:68-73.
19. John R. Roberts: Other lung malignancy. *Sabiston and Spencer Surgery of the Chest*. 7th ed, vol 1. Chapter 22. Elsevier Inc.; 2005.
20. Darling G, Robert J. Ginsberg: Carcinoid tumors. *Shields General Thoracic Surgery*. 6th ed, vol II, Chapter 116. Lippincott Williams and Wilkins; 2005.
21. Herde RF, Kokeny KE, Reddy CB, Akerley WL, Hu N, Boltax JP, *et al.* Primary pulmonary carcinoid tumor: A long-term single institution experience/Primary pulmonary carcinoid tumor. *Am J Clin Oncol* 2018;41:24-9.
22. Gould WE, Warren WH. *Epithelial Neoplasms of the Lung, Thoracic Oncology*. 2nd ed. Chapter 4. W. B. Sanders Company. 4. Thunnissen: Beasley MB; 1995.
23. Beasley MB, Thunnissen FB, Brambilla E, Hasleton P, Steele R, Hammar SP, *et al.* Pulmonary atypical carcinoid: Predictors of survival in 106 cases. *Hum Pathol* 2000;31:1255-65.
24. Gomez A, Zalacain R, Lopez L, Cancelo L, Jaca C, *et al.* Bronchial carcinoid tumors. Analysis of 41 cases. *Rev Clin ESP* 2004;204:202-5.
25. Ducreux M, Baudin E, Schlumberger M. Treatment strategy of neuroendocrine tumors. *Rev Prat* 2002;52:290-6.
26. Filosso PL, Rena O, Donati G, Casadio C, Ruffini E, Papalia E, *et al.* Bronchial carcinoid tumors: Surgical management and long-term outcome. *J Thorac Cardiovasc Surg* 2002;123:303-9.
27. Divisi D, Crisci R. Carcinoid tumors of the lung and multimodal therapy. *Thorac Cardiovasc Surg* 2005;53:168-72.
28. Canizares MA, Garcia-Fontan EM, Rivo JE, Gonzalez-Piñeiro A. Local recurrence and metastatic disease in a typical N1 carcinoid bronchial tumor. *Clin Transl Oncol* 2005;7:216-8.
29. Hage R, de la Riviere AB, Seldenrijk CA, van den Bosch JM. Update in pulmonary carcinoid tumors. *Ann Surg Oncol* 2003;10:697-704.
30. McMullan DM, Wood DE. Pulmonary carcinoid tumors. *Semin Thorac Cardiovasc Surg* 2003;15:289-300.