

research article

A novel mutation in the FOXC2 gene: a heterozygous insertion of adenosine (c.867insA) in a family with lymphoedema of lower limbs without distichiasis

Tanja Planinsek Rucigaj^{1,3}, Matija Rijavec², Jovan Miljkovic³, Julij Selb², Peter Korosec²

¹ Dermatovenereological Clinic, University Medical Centre Ljubljana, Ljubljana, Slovenia

² University Clinic of Respiratory and Allergic Diseases Golnik, Golnik, Slovenia

³ Faculty of Medicine, University of Maribor, Maribor, Slovenia

Radiol Oncol 2017; 51(3): 363-368.

Received 26 December 2016

Accepted 23 May 2017

Correspondence to: Tanja Planinšek Ručigaj, M.D., Dermatovenereological Clinic, University Medical Center Ljubljana, Zaloška cesta 2, 1000 Ljubljana, Slovenia. E-mail: t.rucigaj@gmail.com

Disclosure: No potential conflicts of interest were disclosed.

Background. Primary lymphoedema is a rare genetic disorder characterized by swelling of different parts of the body and highly heterogenic clinical presentation. Mutations in several causative genes characterize specific forms of the disease. FOXC2 mutations are associated with lymphoedema of lower extremities, usually distichiasis and late onset.

Patients and methods. Subjects from three generations of a family with lymphoedema of lower limbs without distichiasis were searched for mutations in the FOXC2 gene.

Results. All affected family members with lymphoedema of lower limbs without distichiasis, and still asymptomatic six years old girl from the same family, carried the same previously unreported insertion of adenosine (c.867insA) in FOXC2.

Conclusions. Identification of a novel mutation in the FOXC2 gene in affected family members of three generations with lymphoedema of lower limbs without distichiasis, highlights the high phenotypic variability caused by FOXC2 mutations.

Key words: primary lymphoedema; FOXC2 mutation; distichiasis; lower limbs lymphoedema

Introduction

Lymphoedema, swelling due to excess accumulation of the protein-rich lymph in the tissues, is caused by inadequate lymph reabsorption or when the lymphatic vessels are absent or function defectively.¹ Primary lymphoedema is affecting approximately 1.15/100,000 of less than 20 years of age population.² Affected individuals suffer from chronic lymphoedema and are at greater risk for developing infections, including bacterial infection of the skin and underlying tissue (cellulitis) or infection of the lymphatic vessels (lymphangitis).³ They are also at a greater risk than the general population

for developing a malignancy, at the affected site. The most common malignancy associated with the affected area is the angiosarcoma⁴⁻⁶ (the condition called the Stewart-Treves syndrome), however, also other malignancies, the basal cell carcinoma, squamous cell carcinoma, melanoma, Kaposi sarcoma, Merkel cell carcinoma, and several cutaneous lymphomas⁶ can occur, and are probably due to the immunocompromised district of the affected area or because of the environment rich in growth factors due to the formation of collateral lymphatic vessels.⁶ Therefore, identification (also with the aid of genetic testing) and monitoring of patients with chronic lymphoedema (no matter the etiology)

should be performed periodically to identify and treat malignant changes that can develop in the affected areas.⁶

The clinical presentation of primary lymphoedema is very variable and varies in the age of onset, the edematous part of the body affected, associated anomalies and different inheritance patterns.⁷ The most recent classification of primary lymphoedema has been developed as a diagnostic algorithm, proposed by Connell in 2010⁷ and 2013⁸, and is based first on different clinical presentations and second on the genetic findings.

The genetic basis of primary lymphoedema are mutations in five causative genes that also underlie specific forms of the disease^{9,10} namely: *FLT4* (fms-related tyrosine kinase 4 encoding VEGFR-3 (vascular endothelial growth factor receptor 3)) mutations, that cause Milroy disease¹¹⁻¹⁵; *CCBE1* (collagen and calcium binding EGF domain containing protein 1) mutations that are responsible for autosomal-recessive generalized lymphatic dysplasia¹⁶⁻¹⁸; *SOX18* (sex determining region Y-box 18) mutations that account for the hypotrichosis-lymphoedema-telangiectasia syndrome¹⁹; *GJC2* (gap junction protein gamma 2, encoding (CX47) connexin-47) mutations which were identified in patients with four-limb lymphoedema^{20,21} and *FOXC2* (fork head box protein C2) mutations that are responsible for autosomal dominant lymphoedema distichiasis syndrome (LDS).^{22,23} With the advent of the next generation sequencing technology, muta-

tions in the number of new candidate genes (*NRP2* (neuropilin 2), *SOX17* (sex determining region Y-box 17), *FABP4* (fatty acid binding protein 4), *VCAM1* (vascular cell adhesion molecule 1) have been also linked to primary lymphoedema.^{10,24}

In patients with LDS, lymphoedema of both lower limbs, that typically starts in late childhood or during puberty^{10,15}, and varicose veins are accompanied by extra eyelashes (known as distichiasis) and also other comorbidities, such as ptosis (35% of patients), congenital heart disease (8%) and cleft palate (3%).^{7,8,15} In the majority (95%) of patients with LDS, mutations in the *FOXC2* gene, on chromosome 16q24, are responsible for the disease (15). *FOXC2* encodes a transcription factor for the signal transduction pathway ensuring normal development of the lymphatic collecting vessels and valves.²⁵

Besides causing LDS, *FOXC2* mutations have also been identified in lymphoedema without distichiasis.²⁶ Therefore, the aim of our study was to search for causative mutations in the *FOXC2* gene in three generations of a family with lymphoedema of lower limbs without distichiasis.

Patients and methods

Patients

Three family members, a 39-year-old woman, her 74-year-old father and 14-year-old son, have been

TABLE 1. Clinical findings of family members with primary lymphoedema

	Patients				
	M	F	M	F	F
Gender	M	F	M	F	F
Age (years)	74	39	14	9	6
Lymphoedema	Yes	Yes	Yes	No	No
Lower limbs	Yes ^a	Yes ^a	Yes ^b	No	No
Genital	Yes	No	No	No	No
Distichiasis	No	No	No	No	No
Onset (years)	11	9	13	/	/
Varicose veins	Yes	Yes	No	No	No
Ptosis	No	No	No	No	No
Cleft palate	No	No	No	No	No
Congenital heart disease	No	No	No	No	No
<i>FOXC2</i> mutation	c.867insA	c.867insA	c.867insA	No	c.867insA
Cellulitis	Yes	Yes	No	No	No
Yellow nails	No	No	No	No	No

^a = whole lower limbs; ^b = calves only; F = female; M = male

diagnosed with primary lymphoedema at the Dermatovenerological Clinic, University Clinical Centre Ljubljana.

The 74-year-old has lymphoedema of both lower limbs stage III with fibrosis and sclerosis with only some small reticular veins present and genital edemas with lymphatic cysts. The disease started when the patient was 11 years old. The patient does not have distichiasis, ptosis, and cleft palate. There is no known history of lymphoedema in the patient's family and his wife, who had died, also did not have any history of lymphoedema. The patient has suffered a myocardial infarction in 2007 and had a mitral and a tricuspid valve replacement. Patient is being treated with short-stretch bandages and manual lymph drainage and in the maintenance phase with compression garments (bermuda shorts, and flat knitted thigh high stocking class III). Before therapy, he had suffered several erysipelas which have not reoccurred after regular therapy for lymphoedema.

The 39-years-old daughter has lymphoedema stage III of both lower limbs without genital involvement, with the disease onset at age 9. The patient, like her father, also does not have distichiasis, ptosis or cleft palate. She has varicose veins present on both of her legs. Her husband does not have lymphoedema. She is being treated with flat

knitted thigh high stocking class III. Again, she had suffered several erysipelas which were stopped after regular therapy for lymphoedema. She has three children.

In her son, lymphoedema stage II of both lower limbs first occurred at the age of 13. He has no other pathological clinical findings. He is being treated with round knitted stockings class II. He has not suffered any erysipelas.

Both her daughters aged 9 and 6 years have no symptoms and signs of lymphoedema. Age, gender, and detailed clinical characteristics of the recruited subject are presented in Table 1.

The study was approved by the Slovenian national ethics committee (number: 157/07/10) and all participants gave their informed written consent.

Genetics analysis

Genomic DNA was extracted from EDTA-containing whole blood samples using a QIAamp DNA Blood Mini Kit (Qiagen, Hilden, Germany) according to the manufacturer's instructions. The detection of *FOXC2* mutations in the 1506 bp single exon coding region, as well as in the 5' and 3' regions of *FOXC2* gene was performed as previously described.^{26,27} The primer sequence and conditions used are presented in Table 2. PCR prod-

TABLE 2. Primer sequences and conditions used to amplify and sequence the *FOXC2* gene and its upstream and downstream regions

Name of primer	Sequence (5'-3')	Annealing temp (°C)	Product size (bp)	DMSO %	MgCl ₂ mM
FOXC2-1F ^a	TCTGGCTCTCTCGCGCTCT	58	476	6	1.5
FKHL14-2R	AGTAACTGCCCTTGCCGG				
FOXC2-2F ^a	ACCGCTCCCCCTTCTACCGG	60	519	10	1.5
FOXC2-2R	TCATGATGTTCTCCACGCTGAA				
FKHL14-4F ^a	GAAGGTGGTGATCAAGAGCG	60	496	6	1.5
FOXC2-3R	GAGGTTGAGAGCGCTCAGGG				
FOXC2-4F ^a	CTGGACGAGGCCCTCTCGGAC	61	464	10	1.5
FOXC2-4R	GGAGGTCCCGGGACACGTCA				
FOX_5P_1F ^b	GCCGACGGATTCTGCGCTC	61	378	10	1.5
FOX_5P_1R	CCGCTCTCGCTGGCTCCA				
FOX_5P_2F ^b	CCGATTGCTGGGGGCTGGAG	61	607	6	1.5
FOX_5P_2R	GCGGGCTGGTGGTGGTAGG				
FOX_3P_1F ^b	CAACGTGCGGGAGATGTTCAAC	61	464	10	1.5
FOX_3P_1R	CACAGCACAGCCGCTCCTGGTAG				
FOX_3P_2F ^c	TACTGACGTGTCCCGGGACC	61	468	6	1.5
FOX_3P_2R	CCACACATTGTACAGCACGGTGTG				

^a = Primer pairs from²⁷; ^b = Primer pairs from²⁶; ^c = Primer pairs from²⁶

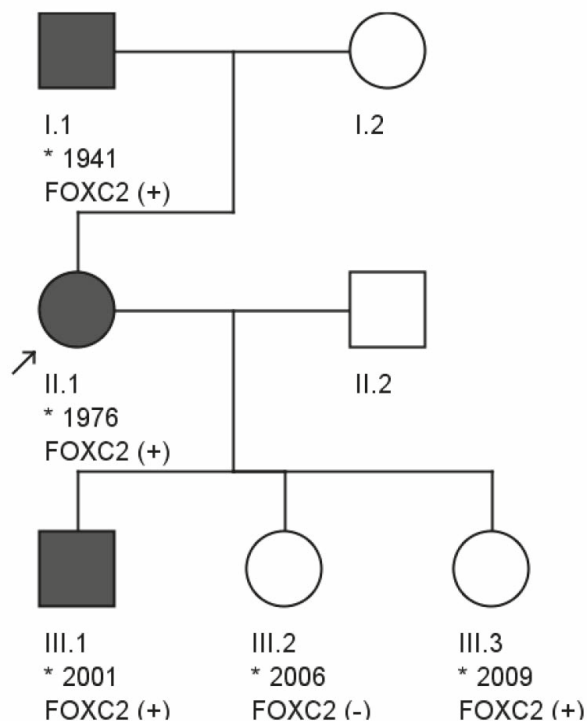


FIGURE 1. Pedigree of the family with new mutation in *FOXC2* gene. Full symbols indicate patients with lymphoedema, asterisk (*) indicate year of birth of the recruited subjects and subjects with c.867insA *FOXC2* mutation are indicated as FOXC2 (+).

ucts were sequenced using Big Dye Terminator kit (Thermo Fisher Scientific) and 3730xl DNA analyzer (Thermo Fisher Scientific). To identify mutations, sequences were compared with the *FOXC2* reference sequence in the GenBank (GenBank accession number NG_012025.1) using the SeqScape Software v2.6 (Thermo Fisher Scientific). Mutations numbering is based on cDNA sequence, where the first nucleotide (A) of the initiation codon (ATG) is considered nucleotide number one.

Results

Clinical details

The clinical detail of all five patients are shown in Table 1.

Genetics analysis

In all affected members of the described three generation family with lymphoedema of lower limbs without distichiasis the same mutation in *FOXC2* responsible for the disease was identified (Figure 1). The mutation identified in our

patients is a heterozygous insertion of adenosine (c.867insA) and was not previously described. This insertion was present in three family members affected by primary lymphoedema, as well as in a six years old girl without any symptoms and signs of lymphoedema at the time of analysis, while it was absent in a healthy nine years old girl.

Since the discovered mutation was not previously reported we additionally evaluated this mutation in 182 normal controls. None of the controls harbored the mutation, which further supports the causative nature of the mutation.

Discussion

Up to date only one lymphedema family with *FOXC2* mutation without any individual with distichiasis was found.²⁶ We report the second family of three generations with *FOXC2* mutation and in which all affected individuals demonstrated lymphedema without distichiasis. Molecular analysis helped to identify the causative heterozygous insertion of adenosine (c.867insA) in the *FOXC2* gene, which was previously not described. This mutation causes frameshift and premature termination of the mature protein since stop codon is inserted behind amino acid 461, leading to a truncation of the mature protein and consequently to the elimination of key alpha-helical domains required for the transcription process.²⁶ Frameshift mutations are expected to alter the reading frame or lead to a premature termination of the protein, and as a result those unstable mRNA transcripts are removed through the nonsense-mediated mRNA decay pathway.^{28,29} The causative nature of the identified variant was further supported by the fact that the mutation was not found in any of the 182 tested normal controls.

In all three patients of our family, lymphoedema developed between the age of 9 and 13. The onset of lymphoedema in literature is typically during puberty or in late childhood.^{7,26,30} In the 6 years old girl without clinical manifestations of lymphoedema with mutation in *FOXC2*, lymphoedema will very likely develop within the next few years. She also has no other clinical findings that were described in patients with *FOXC2* mutations. All three patients have lymphoedema of both lower limbs like the patients described in the literature.^{14,28} Because of delayed therapy with compression in the female patient and her father, lymphoedema of the legs is in the IIIrd stage. Patient's father also has lymphoedema of genital region with oc-

casional lymphorrhoea. Several papers have mentioned that lymphoscintigraphy, because of valve failure, indicate distal lymph reflux in patients with LDS.^{6,29,31} In our two older patients not only early therapy, but also lymphoscintigraphy have been performed in other institutions abroad, and thus unfortunately any information about those findings are not available. Also for the young boy, his mother did not allow to perform early diagnostic procedures, because of known family diagnosis. Both, the patient and her father had suffered many erysipelas before therapy. After regular wearing of compression garments erysipelas were stopped. The son started with compression stockings class II immediately after the onset of edema. He has lymphoedema stage II with morning swelling, without sequelae. Our female patient and her father both have reticular varicose veins without reflux. In the literature lymphoedema and varicose veins are accompanied by distichiasis, which occur in 94.3% of the patients with mutations in the *FOXC2* gene.^{15,32} Affected individuals can also have ptosis (in 35% of patients), congenital heart disease (8%), cleft palate (3%) and in some patients yellow nails and cystic hygromas have been described.²⁶ In our patients there were no distichiasis, no cleft palate, no ptosis or yellow nails, no congenital heart defects or cystic hygromas.

Mutations in the *FOXC2* appear to be the primary cause of LDS. However, not only that some features of the LDS phenotype can be found in patients without *FOXC2* mutations²⁶ our study and also previous report²⁶ obviously suggest that mutations in the *FOXC2* gene can be found in lymphoedema patients without distichiasis.

The *FOXC2* gene encodes for a forkhead transcription factor implicated in the development of lymphatic and vascular system, particularly affecting the function of the valves.^{25,32} The role has been implicated from animal models where it is expressed in developing mesenchymal cells which develop into blood and lymphatic vessels. Moreover, homozygous null mice (*foxc2*^{-/-}) have non-functioning blood vessels.^{25,32} In humans *FOXC2* mutations were associated with primary valve failure and venous reflux, indicating its requirement for proper venous function.^{15,25,32} Mutations in *FOXC2* most often cause LDS, with lymphoedema of lower extremities, distichiasis, and the disease onset usually after puberty.^{7,8,10,15,26,32-35} However, the penetrance and disease expression seems to be highly variable. This was also confirmed by our family in which none of the patients with the novel *FOXC2* mutation had distichiasis.

Conclusions

In conclusion, we identified a causative previously unreported insertion in *FOXC2* in affected members of three generation family with lymphoedema of lower limbs without distichiasis, highlighting the high heterogeneity of phenotypic variability caused by *FOXC2* mutations.

References

1. Planinsek Rucigaj T, Tlaker Zunter V. Lymphedema: clinical picture, diagnosis and management. In: Singh N, editor. *Radioisotopes - applications in bio-medical science*. InTech; 2011. Available from: <https://www.intechopen.com/books/radioisotopes-applications-in-bio-medical-science/lymphedema-clinical-picture-diagnosis-and-management>. doi:10.5772/24515
2. Smeltzer DM, Stickler GB, Schirger A. Primary lymphedema in children and adolescents: a follow-up study and review. *Pediatrics* 1985; **76**: 206-18.
3. Al-Niimi F, Cox N. Cellulitis in lymphoedema: a vicious cycle. *J Lymph* 2009; **42**: 38-42.
4. Sharma A, Schwartz RA. Stewart-Treves syndrome: pathogenesis and management. *J Am Acad Dermatol* 2012; **67**: 1342-8. doi:10.1016/j.jaad.2012.04.028
5. Dürr HR, Pellengahr C, Nerlich A, Baur A, Maier M, Jansson V. Stewart-Treves syndrome as a rare complication of a hereditary lymphedema. *Vasa* 2004; **33**: 42-5. doi:10.1024/0301-1526.33.S65.42
6. Lee R, Saardi KM, Schwartz RA. Lymphedema-related angiogenic tumors and other malignancies. *Clin Dermatol* 2014; **32**: 616-20. doi:10.1016/j.clindermatol.2014.04.008
7. Connell F, Brice G, Jeffery S, Keeley V, Mortimer P, Mansour S. A new classification system for primary lymphatic dysplasias based on phenotype. *Clin Genet* 2010; **77**: 438-52. doi:10.1111/cge.12173
8. Connell F, Gordon K, Brice G, Keely V, Jeffrea S, Mortimer P, et al. The classification and diagnostic algorithm for primary lymphatic dysplasia: an update from 2010 to include molecular findings. *Clin Genet* 2013; **84**: 303-14.
9. Ostergaard P, Simpson MA, Jeffery S. Massively parallel sequencing and the identification of genes for primary lymphoedema: a perfect fit. *Clin Genet* 2011; **80**: 110-6. doi:10.1111/j.1399-0004.2011.01706.x
10. Mendola A, Schlögel MJ, Ghalamkarpour A, Irrthum A, Nguyen HL, Fastré E, et al. Mutations in the VEGFR3 signaling pathway explain 36% of familial lymphedema. *Mol Syndromol* 2013; **4**: 257-66. doi:10.1159/000354097
11. Ferrell RE, Levinson KL, Esmen JH, Kimak MA, Lawrence EC, Barmada NM, et al. Hereditary lymphedema: evidence for linkage and genetic heterogeneity. *Hum Mol Genet* 1998; **7**: 2073-8.
12. Evans AL, Brice G, Sotirova V, Mortimer P, Beninson J, Burnard K, et al. Mapping of primary congenital lymphedema to the 5q35.3 region. *Am J Hum Genet* 1999; **64**: 547-55. doi:10.1086/302248
13. Karkkainen MJ, Ferrell RE, Lawrence EC, Kimak MA, Levinson KL, McTigue MA, et al. Missense mutations interfere with VEGFR-3 signalling in primary lymphoedema. *Nat Genet* 2000; **25**: 153-9. doi:10.1038/75997
14. Irrthum A, Karkkainen MJ, Devriendt K, Alitalo K, Vikkula M. Congenital hereditary lymphedema caused by a mutation that inactivates VEGFR3 tyrosine kinase. *Am J Hum Genet* 2000; **67**: 295-301. doi:10.1086/303019
15. Brice G, Mansour S, Bell R, Collin JR, Child AH, Brady AF, et al. Analysis of the phenotypic abnormalities in lymphoedema distichiasis syndrome in 74 patients with *FOXC2* mutations or linkage to 16q24. *J Med Genet* 2002; **39**: 478-83. doi:10.1136/jmg.39.7.478
16. Hennekam RCM, Geerdink RA, Hamel BCI, Hennekam FA, Kraus P, et al. Autosomal recessive intestinal lymphangiectasia and lymphedema, with facial anomalies and mental retardation. *Am J Med Genet* 1989; **34**: 593-600. doi:10.1002/ajmg.1320340429

17. Alders M, Hogan BM, Gjini E, Salehi F, Al-Gazali L, Hennekam EA, et al. Mutations in *CCBE1* cause generalized lymph vessel dysplasia in humans. *Nat Genet* 2009; **41**: 1272-4. doi:10.1038/ng.484
18. Alders M, Mendola A, Ades L, Al Gazali L, Bellini C, Dallapicola B, et al. Evaluation of clinical manifestations in patients with severe lymphedema with and without *CCBE1* mutations. *Mol Syndromol* 2013; **4**: 107-13. doi:10.1159/000342486
19. Irrthum A, Devriendt K, Chitayat D, Matthijs G, Glade C, Steijlen PM, et al. Mutations in the transcription factor gene *SOX18* underlie recessive and dominant forms of hypotrichosis-lymphedema-telangiectasia. *Am J Hum Genet* 2003; **72**: 1470-8. doi:10.1086/375614
20. Ferrell RE, Baty CJ, Kimak MA, Karlsson JM, Lawrence EC, Franke-Snyder M, et al. GJC2 missense mutations cause human lymphedema. *Am J Hum Genet* 2010; **86**: 943-8. doi:10.1016/j.ajhg.2010.04.010
21. Ostergaard P, Simpson MA, Brice G, Mansour S, Connell FC, Onaoufridaï A, et al. Rapid identification of mutations in GJC2 in primary lymphoedema using whole exome sequencing combined with linkage analysis with delineation of the phenotype. *J Med Genet* 2011; **48**: 251-5. doi:10.1136/jmg.2010.085563
22. Fang J, Dagenais SL, Erickson RP, Arlt MF, Glynn MW, Gorski JL, et al. Mutations in *FOXC2* (MFH-1), a forkhead family transcription factor, are responsible for the hereditary lymphedema-distichiasis syndrome. *Am J Hum Genet* 2000; **67**: 1382-8. doi:10.1086/316915
23. Shimoda H, Bernas MJ, Witte MH. Dysmorphogenesis of lymph nodes in *Foxc2* haploinsufficient mice. *Histochem Cell Biol* 2011; **135**: 603-13. doi:10.1007/s00418-011-0819-x
24. Ferrell RE, Kimak MA, Lawrence EC, Finegold DN. Candidate gene analysis in primary lymphedema. *Lymphat Res Biol* 2008; **6**: 69-76. doi:10.1089/lrb.2007.1022
25. Bell R, Brice G, Child AH, Murday VA, Mansour S, Sandy CJ, et al. Analysis of lymphoedema-distichiasis families for *FOXC* mutations reveals small insertions and deletions throughout the gene. *Hum Genet* 2001; **108**: 546-51.
26. Finegold DN, Kimak MA, Lawrence EC, Levinson KL, Cherniske EM, Pober BR, et al. Truncating mutations in *FOXC2* cause multiple lymphedema syndromes. *Hum Mol Genet* 2001; **10**: 1185-9.
27. Kovacs P, Lehn-stefan A, Stumvoll M, Bogardus C, Baier LJ. Genetic variation in the human winged helix/forkhead transcription factor gene *FOXC2* in Pima Indians. *Diabetes* 2003; **52**: 1292-5. doi:10.2337/diabetes.52.5.1292
28. Frischmeyer PA, van Hoof A, O'Donnell K, Guerrero AL, Parker R, Dietz HC. An mRNA surveillance mechanism that eliminates transcripts lacking termination codons. *Science* 2002; **295**: 2258-61. doi:10.1126/science.1067338
29. Van Steensel MA, Damstra RJ, Heitink M, Bladergroen RS, Veraart J, Steijlen PM, et al. Novel missense mutations in the *FOXC2* gene alter transcriptional activity. *Hum Mutat* 2009; **30**: E1002-9. doi:10.1002/humu.21127
30. Burnand KG, Mortimer PS. Lymphangiogenesis and genesis of lymphedema. In: Browse N, Burnand KG, Mortimer PS, editors. *Diseases of the lymphatics*. London: Arnold; 2003. p. 102-9.
31. Sholto-Douglas-Vernon C, Bell R, Brice G, Mansour S, Satfarazi M, Child AH, et al. Lymphoedema distichiasis and *FOXC2*: unreported mutations, *de novo* mutation estimate, families without coding mutations. *Hum Genet* 2005; **117**: 238-42. doi:10.1007/s00439-005-1275-2
32. Mellor RH, Brice G, Stanton AW, French J, Fernch J, Smith A, et al. Mutations in *FOXC2* are strongly associated with primary valve failure in veins of the lower limb. *Circulation* 2007; **115**: 1912-20. doi:10.1161/CIRCULATIONAHA.106.675348
33. Sutkowska E, Gil J, Stembalska A, Hill-Bator A, Szuba A. Novel mutation in the *FOXC2* gene in three generations of a family with lymphoedema-distichiasis syndrome. *Gene* 2012; **498**: 96-9. doi:10.1016/j.gene.2012.01.098
34. Rosbotham JL, Brice GW, Child AH, Nunan TO, Mortimer PS, Burnand KG. Distichiasis-lymphoedema: clinical features, venous function and lymphoscintigraphy. *Br J Dermatol* 2000; **142**: 148-52. doi:10.1046/j.1365-2133.2000.03258.x
35. Petrova TV, Karpanen T, Norrm'en C, Mellor R, Tamakoshi T, Finegold D, et al. Defective valves and abnormal mural cell recruitment underlie lymphatic vascular failure in lymphedema distichiasis. *Nat Med* 2004; **10**: 974-81. doi:10.1038/nm1094