



Retrograde percutaneous transgastric esophageal endoscopic submucosal dissection: a peculiar endoscopic submucosal dissection technique for therapy of esophageal cancer with esophageal stenosis after chemoradiation therapy

Yugo Suzuki, MD,¹ Toshiro Iizuka, PhD,² Daisuke Kikuchi, PhD,¹ Masaki Ueno, PhD,³ Shu Hoteya, PhD¹

The patient was a 69-year-old man who had received chemoradiotherapy for T3N2M0, stage III cervical esophageal cancer 10 years earlier and exhibited complete response. He developed cervical esophageal stenosis caused by fibrosis as a result of treatment and experienced dysphagia within 1 year after treatment.

Although the patient had a very narrow cervical esophagus, he was able to take in sufficient nutrition by devising a dietary form. Therefore, no dilatation procedure was performed to treat the stenosis. Close follow-up using an ultrathin endoscope for routine surveillance revealed a superficial esophageal tumor covering two-thirds of the thoracic esophagus 28 to 30 cm from the incisors. Biopsy results confirmed it to be squamous cell carcinoma (Fig. 1A to C). He was admitted for further treatment.

The stenosis was located 15 to 16 cm from the incisors. The tumor was located 13 cm distal from the stenosis and clearly delineated/distanced from the stenosis. Preoperative CT revealed no lymph node metastasis, so the patient was scheduled for endoscopic submucosal dissection (ESD). During ESD, we first attempted to perform endoscopic balloon dilatation and incision of the cervical esophagus that was stenosed from scarring. However, the esophagus could not be dilated sufficiently to allow passage of the endoscope, and we abandoned transoral ESD. Because the irradiation field of the preceding chemoradiotherapy was up to the esophagus, including the lesion area, radiotherapy was not an option. We then decided to perform ESD via percutaneous gastrostomy with the patient under general anesthesia (Video 1, available online

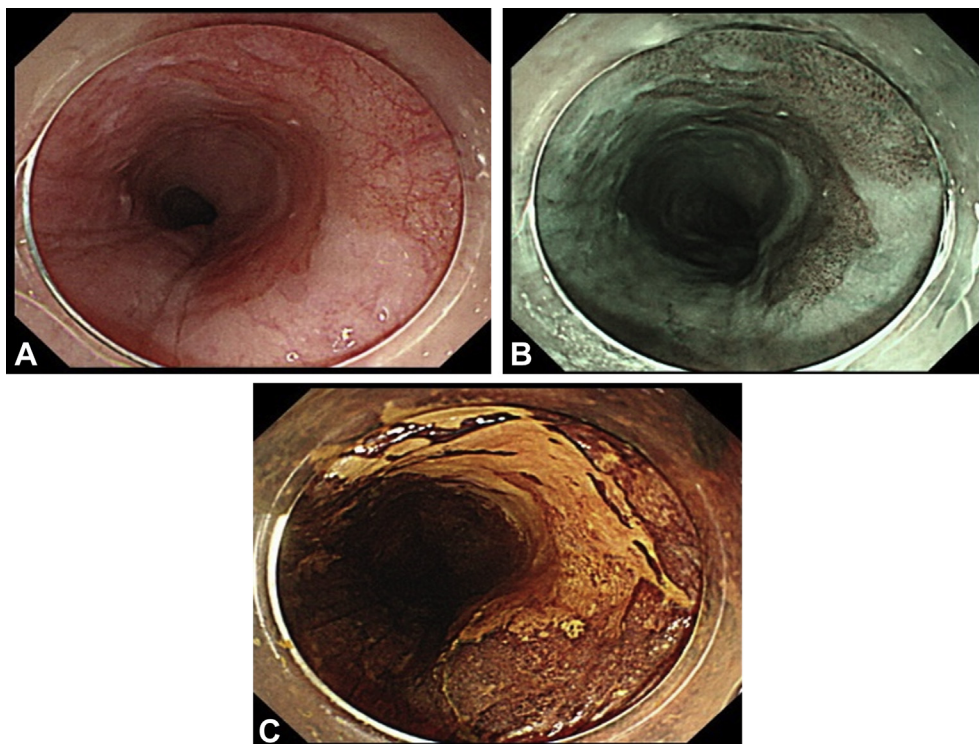


Figure 1. A, White-light endoscopy. B, Narrow-band image. C, Lugol chromoendoscopy revealed the presence of a superficial esophageal tumor covering two-thirds of the thoracic esophagus.

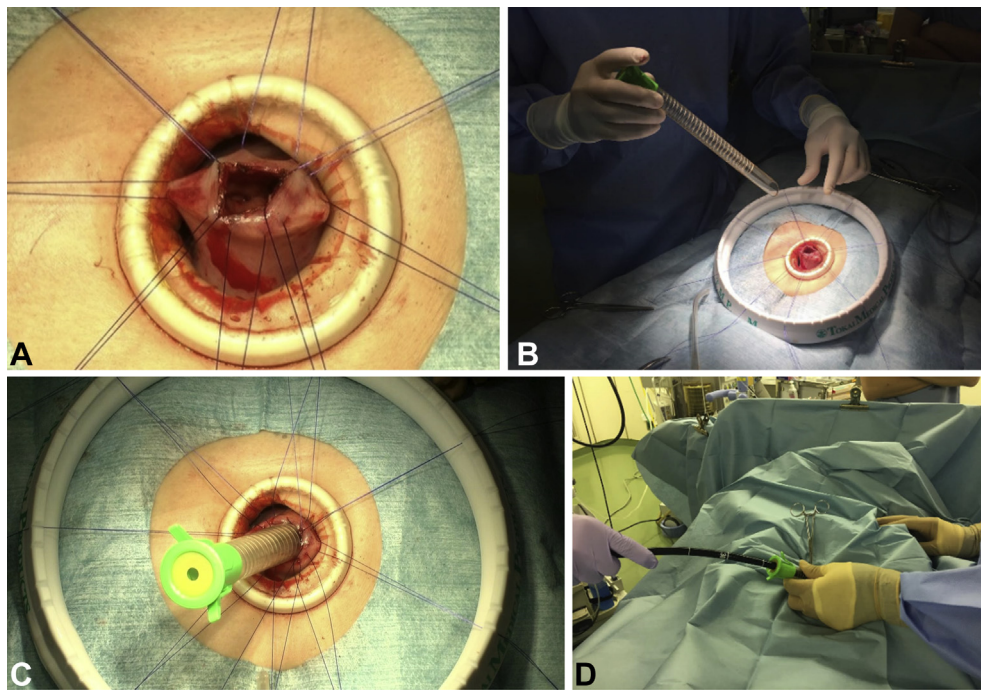


Figure 2. **A and B,** A midline incision was made in the epigastrium, and a suture was placed and secured into the anterior wall of the gastric antrum as a hoist. **C,** The overtube was inserted into the esophagus via the gastrostomy and advanced into the esophagus. **D,** Endoscopic submucosal dissection was performed via a percutaneous gastrostomy through an overtube.

at www.VideoGIE.org). First, we made a midline incision in the epigastrium, placed and secured a suture into the anterior wall of the gastric antrum as a hoist, and inserted the overtube into the stomach. We inserted the overtube into the esophagus via the gastrostomy and advanced it into the esophagus. We then performed ESD via a percutaneous gastrostomy through an overtube (Fig. 2A to D). The schema is shown in Figure 3. Insertion of the overtube facilitated the endoscopic procedure, and the lesion was resected en bloc in 27 minutes. We sutured all layers of the stomach and closed the incision, with a total operation time of 105 minutes. Surgery was completed without adverse events. The patient resumed oral intake on postoperative day 4 and was discharged on postoperative day 10 after satisfactory wound examination results.

Histopathology evaluation showed a squamous cell carcinoma measuring 25 × 18 cm. The depth of tumor invasion was the lamina propria mucosa, and the surgical margins were clear, indicating that curative resection had been achieved. We evaluated the ESD site 6 weeks after the treatment and followed with peroral endoscopy using the ultrathin endoscope every 6 months.

DISCUSSION

Treatment for esophageal cancer includes surgical resection, chemotherapy, radiotherapy, or a combination of these, and treatment is selected based on disease stage and patient

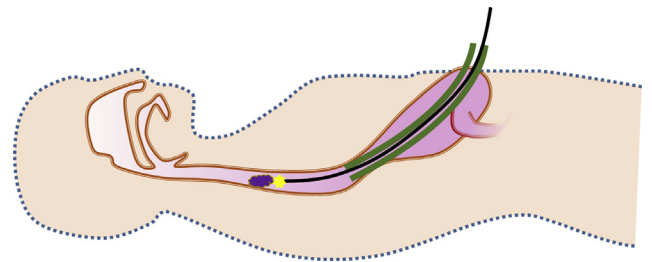


Figure 3. The schema shows the retrograde percutaneous transgastric esophageal endoscopic submucosal dissection.

characteristics. However, the esophagus has a relatively narrow lumen, so any therapeutic procedure performed on the cervical esophagus for lesions that occupy a large portion of the circumference increases the risk of esophageal stenosis.^{1,2} In addition, many patients have multiple synchronous or metachronous tumors, and we frequently encounter patients with metachronous recurrent lesions caudal to the areas that are stenosed before treatment starts. To date, attempts have been made to treat esophageal stenosis using a percutaneous gastrostomy tube (G-tube) via an endoscopic or surgical approach.^{3,4} Some reports have described the application of traction to the stomach when performing transoral endoscopic treatment,⁵ but to our knowledge, there are no previous reports of retrograde endoscopic treatment of esophageal cancer performed via a percutaneous gastrostomy.

We performed retrograde percutaneous transgastric ESD in the operating room and coordinating with a

surgical team. This technique is not only less surgically invasive, but it can also be performed at hospitals that already perform esophageal ESD without the need for special techniques if it is possible to coordinate with a surgical team.

In this case, the aim of this procedure was to cure esophageal cancer. The patient was able to take in sufficient nutrition by devising a dietary form before treatment, so we did not perform stent placement after ESD. We considered leaving the percutaneous endoscopic gastrostomy tube after the procedure, but it was not removed at this time because the patient had adequate peroral nutrition with the dietary form.

We believe that one of the limitations of this technique is that some patients may require emergency endoscopy for delayed hemorrhage from the ESD site. In such a case, hemostasis may be required with use of an ultrathin endoscope. For patients at risk of late hemorrhage, percutaneous endoscopic gastrostomy may be needed in the short term.

ESD performed via percutaneous gastrostomy is a promising minimally invasive treatment option for patients with concomitant superficial esophageal cancer and esophageal stenosis.

DISCLOSURE

All authors disclosed no financial relationships.

Abbreviation: ESD, endoscopic submucosal dissection.

REFERENCES

1. Jain D, Singhal S. Esophageal stricture prevention after endoscopic submucosal dissection. *Clin Endosc* 2016;49:241-56.
2. Best SR, Ha PK, Blanco RG, et al. Factors associated with pharyngoesophageal stricture in patients treated with concurrent chemotherapy and radiation therapy for oropharyngeal squamous cell carcinoma. *Head Neck* 2011;33:1727-34.
3. Perbtani Y, Suarez AL, Wagh MS. Emerging techniques and efficacy of endoscopic esophageal reconstruction and lumen restoration for complete esophageal obstruction. *Endosc Int Open* 2016;4:136-42.
4. Bueno R, Swanson SJ, Jaklitsch MT, et al. Combined antegrade and retrograde dilation: a new endoscopic technique in the management of complex esophageal obstruction. *Gastrointest Endosc* 2001;54:368-72.
5. Chen PJ, Huang WC, Wang HP, et al. Percutaneous transgastric traction-assisted esophageal endoscopic submucosal dissection: a randomized controlled trial in a porcine model. *Scand J Gastroenterol* 2012;47:1386-93.

Department of Gastroenterology, Toranomon Hospital, Tokyo, Japan (1), Department of Gastroenterology, Tokyo Metropolitan Cancer and Infectious Diseases Center, Komagome Hospital, Tokyo, Japan (2), Department of Gastroenterological Surgery, Toranomon Hospital, Tokyo, Japan (3).

Copyright © 2020 American Society for Gastrointestinal Endoscopy. Published by Elsevier Inc. This is an open access article under the CC BY-NC-ND license (<http://creativecommons.org/licenses/by-nc-nd/4.0/>).

<https://doi.org/10.1016/j.vgje.2020.06.007>

Twitter

Become a follower of *VideoGIE* on Twitter. Learn when new articles are posted and receive up-to-the-minute news as well as links to our latest videos. Search @VideoGIE on Twitter.