

# Single-Incision Laparoscopic Intraperitoneal Onlay Mesh Repair for the Treatment of Multiple Recurrent Inguinal Hernias

Hanh Minh Tran, MD, Kim Tran, Marta Zajkowska, RN, Vincent Lam, MD, Wayne Hawthorne, MD

## ABSTRACT

**Introduction:** Despite an exponential rise in laparoscopic surgery for inguinal herniorrhaphy, overall recurrence rates have remained unchanged. Therefore, an increasing number of patients present with recurrent hernias after having failed anterior and laparoscopic repairs. This study reports our experience with single-incision laparoscopic (SIL) intraperitoneal onlay mesh (IPOM) repair for these hernias.

**Materials and methods:** All patients referred with multiply recurrent inguinal hernias underwent SIL-IPOM from November 1 2009 to October 30 2013. A 2.5-cm infraumbilical incision was made and a SIL surgical port was placed intraperitoneally. Modified dissection techniques, namely, “chopsticks” and “inline” dissection, 5.5 mm/52 cm/30° angled laparoscope and conventional straight dissecting instruments were used. The peritoneum was incised above the symphysis pubis and dissection continued laterally and proximally raising an inferior flap, below a previous extraperitoneal mesh, while reducing any direct/indirect/femoral/cord lipoma before placement of antiadhesive mesh that was fixed into the pubic ramus as well as superiorly with nonabsorbable tacks before fixing its inferior border with fibrin sealant. The inferior peritoneal flap was then tacked back onto the mesh.

**Results:** There were 9 male patients who underwent SIL-IPOM. Mean age was 55 years old and mean body mass index was 26.8 kg/m<sup>2</sup>. Mean mesh size was 275 cm<sup>2</sup>. Mean operation time was 125 minutes with hospital stay of 1 day and umbilical scar length of 21 mm at 4 weeks' follow-up. There were no intraoperative/postoperative complications, port-site hernias, chronic groin pain, or recurrence with mean follow-up of 20 months.

Discipline of Surgery, Sydney Medical School, University of Sydney, Sydney, New South Wales, Australia (Drs. H. M. Tran, Lam, and Hawthorne); The Sydney Hernia Specialists Clinic, Sydney, New South Wales, Australia (Dr. H. M. Tran, Ms. K. Tran, and Ms. Zajkowska).

Address correspondence to: Hanh Minh Tran, MD, The Sydney Hernia Specialists Clinic, Level 2, 195 Macquarie Street, Sydney, New South Wales 2000, Australia. E-mail: drhmtran@hotmail, info@sydneyherniaspecialists.com.au

DOI: 10.4293/JLS.2014.00354

© 2014 by JLS, *Journal of the Society of Laparoendoscopic Surgeons*. Published by the Society of Laparoendoscopic Surgeons, Inc.

**Conclusions:** Multiply recurrent inguinal hernias after failed conventional anterior and laparoscopic repairs can be treated safely and efficiently with SIL-IPOM.

**Key Words:** Intraperitoneal onlay mesh repair, Multiply recurrent inguinal hernia, Single-incision laparoscopic surgery.

## INTRODUCTION

Laparoscopic inguinal herniorrhaphy has become widely accepted as an effective alternative to the treatment of inguinal hernias compared with the anterior approach owing to its minimal invasiveness and its ability to achieve identical success and quicken the recovery by decreasing time to return to work or physical activities.<sup>1</sup> In Australia, the rate of laparoscopic inguinal herniorrhaphy, in 2012, was 48% of the total numbers of inguinal hernias being repaired<sup>2</sup>. In Australia, from 2010 to 2011, there were 46,651 hospital separations for inguinal hernia and ≥3,711 (7.9%) were for those specified as recurrent, although these figures do not differentiate between the rates of recurrence for each type of repair.<sup>2</sup> It is generally accepted that the best repair for a recurrent inguinal hernia after the laparoscopic repair is the anterior repair, whereas that after an anterior repair is the laparoscopic repair.<sup>3–6</sup> However, there is currently no consensus as to the best repair for multiply recurrent hernias after a failed anterior and laparoscopic repair. Part of the reason for this is that not all surgeons performing laparoscopic inguinal hernia repair perform laparoscopic ventral hernia repair and vice versa. Consequently, there are experts in laparoscopic inguinal hernia repair who have successfully attempted relaparoscopic repair, but this practice is confined to very few surgeons in specialized hernia centers.<sup>7,8</sup> On the other hand, surgeons who are confident with laparoscopic ventral hernia repair and total extraperitoneal (TEP) or transabdominal preperitoneal (TAPP) repair might consider the intraperitoneal onlay mesh (IPOM) repair as merely an extension of laparoscopic ventral hernia repair, although detailed knowledge of the laparoscopic extraperitoneal inguinal anatomy would be essential.<sup>9</sup>

In an attempt to further reduce parietal trauma, single-incision laparoscopic surgery (SILS) has been touted as the most important innovation in laparoscopic surgery since the latter's popularization with the first laparoscopic cholecystectomy in 1988.<sup>10</sup> Indeed, since the first commercial availability of the SILS port in 2007, multiple different single ports have been made available. Multiple prospective randomized controlled trials, mainly for cholecystectomy<sup>11,12</sup> and appendectomy,<sup>13</sup> mostly with small numbers of patients, but more significantly during the learning curve, comparing single-port and multiport surgery, have shown consistent safety and effectiveness of the single-port approach. Similarly, single-port laparoscopic inguinal herniorrhaphy has been shown to be safe and effective.<sup>14–16</sup> However, data regarding the superiority the single-port (over conventional multiport) surgery, other than cosmesis,<sup>17</sup> are still lacking, although it is hoped that with increasing experience with SILS, more high-powered randomized controlled trials will provide us with a clearer picture of the place of SILS.

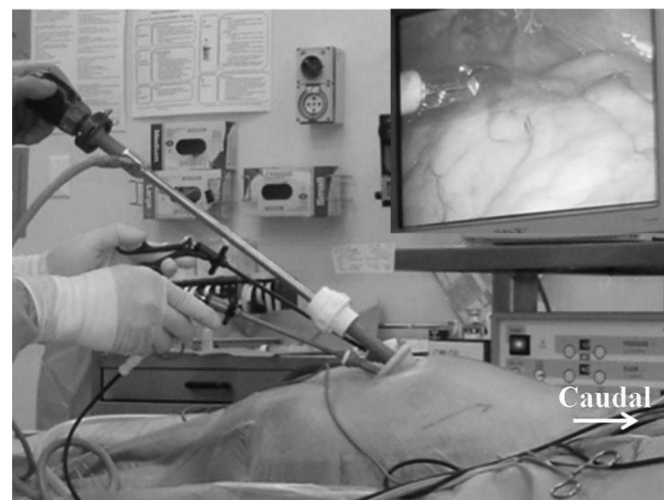Our unit has been offering routine laparoscopic herniorrhaphy for inguinal hernias since 1991 and ventral hernias since 2003. Since December 2009, we have routinely treated virtually all ventral (including parastomal) and inguinal hernias with the single-port approach.<sup>9,18</sup> The treatment of multiply recurrent inguinal hernias after conventional anterior and laparoscopic approaches with laparoscopic IPOM repair represents an obvious choice. In addition, parietal trauma could now be reduced with single-port compared with multiport surgery.<sup>9</sup> To our knowledge, this is the first case series of SIL-IPOM repair for the treatment of recurrent inguinal hernias after both failed conventional anterior and failed laparoscopic repairs with mesh. The Independent Review Board of Holroyd Private Hospital approved this study.

## MATERIALS AND METHODS

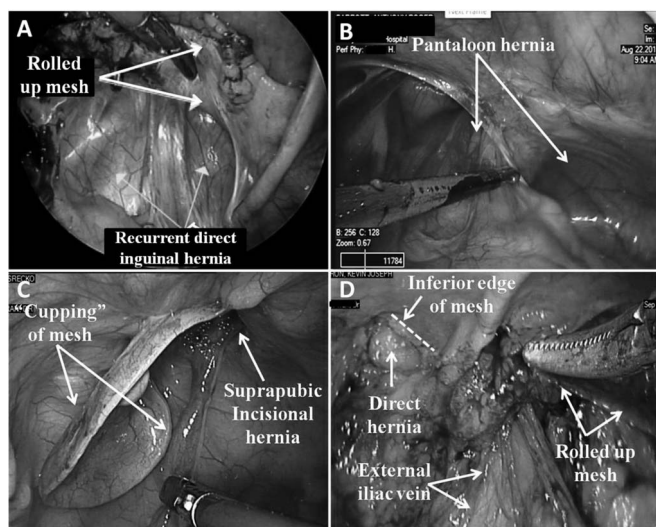
Between November 2009 and October 2013, all patients referred with inguinal/femoral hernias underwent SIL inguinal herniorrhaphy. For this study, inclusion criteria include patients presenting with recurrent inguinal hernias after both failed anterior and failed laparoscopic repairs with mesh. Exclusion criteria include patients who were not fit for a general anesthetic. Patients were informed of our practice of performing laparoscopic IPOM repair and that this could now be achieved with SILS.

After induction with general anesthetic, patients were prepped and draped with iodine from epigastrium to mid thighs, and then draped with iodine-impregnated adhe-

sive cover (Ioband; 3M, St Paul, Minnesota) to expose the entire abdomen and both groins (**Figure 1**). A preoperative intravenous dose of cephalosporin was given, and the patient was routinely catheterized. After infiltration with 20 ml of bupivacaine 0.5% with 1:200,000 ephedrine in the umbilical area, a 2- to 2.5-cm (depending on the laxity of the skin) crescentic infraumbilical incision was made and the anterior rectus sheath was incised transversely and the rectus sheath was retracted laterally. This site of entry was made on the contralateral side from the previous laparoscopic entry (if total extraperitoneal approach was used) to avoid scar tissues. The posterior rectus sheath and the peritoneum were then entered for placement of a SILS port (Covidien, Norwalk, Connecticut). Insufflation with carbon dioxide was maintained at 12 mm Hg. The patient was then placed in a Trendelenburg position at 10° to 15° (**Figure 1**). Laparoscopy was performed with 52 cm/30° angled laparoscope to assess the amount of adhesions (**Figure 2**) and these were meticulously divided by sharp dissection with avoidance of electrocautery (**Figure 3**). Modified dissection techniques, namely, “chopsticks” and “inline,” were employed to overcome the relative loss of triangulation. The pubic symphysis was identified and the peritoneum was incised 2 cm superior to this and extended laterally, or superior to a direct sac, if present (**Figure 4**). No attempt was made to incise through (or remove any part of) the previously placed (extraperitoneal) mesh, and the dissection was performed from the inferior aspect of this mesh and continued proximally.

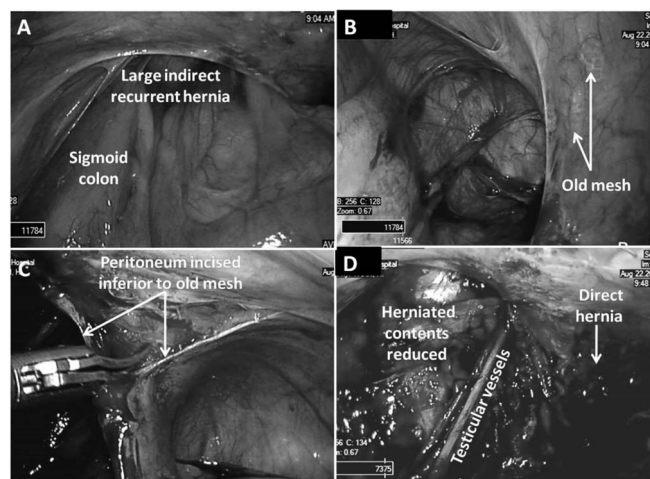


**Figure 1.** Setup for single-incision laparoscopic intraperitoneal onlay mesh repair for a left multiply recurrent inguinal hernia; the extra long laparoscope was used to prevent clashing of the handles of the conventional straight dissecting instruments with the side arm of the scope.



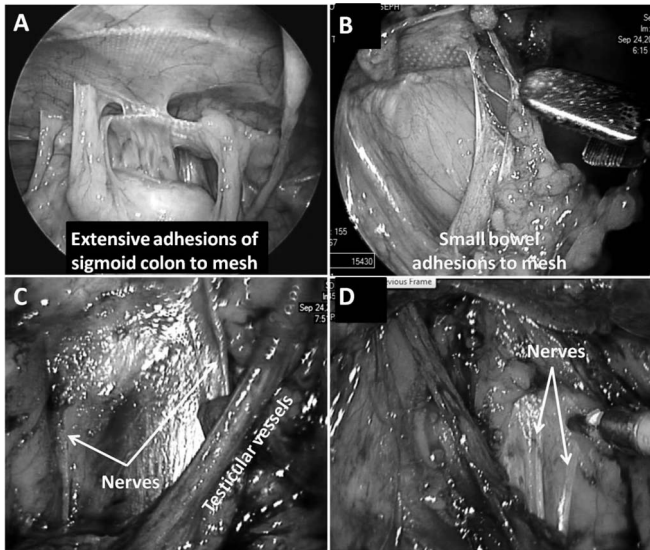
**Figure 2.** Laparoscopic findings in patients with multiply recurrent inguinal hernias after TEP/TAPP and a mean of 2 anterior repairs: rolled up mesh after TEP repair exposing a direct inguinal defect (A); a pantaloona hernia after a TAPP repair (B); a “cupped” intraperitoneally placed mesh exposing a suprapubic defect (C); and a direct defect after TEP repair with the inferolateral aspect of mesh rolled up (D). TAPP, transabdominal preperitoneal; TEP, total extraperitoneal.

Care was taken to stay below the inferior epigastric vessels as the dissection continued laterally. The peritoneum was then reflected inferiorly over the pubic symphysis and continued laterally over the spermatic cord and its structures, reducing any direct, femoral, and indirect hernia and lipoma of the cord akin to the dissection during a TAPP inguinal hernia repair. Extreme care was taken to preserve retroperitoneal nerves in the vicinity (Figure 4). No attempt was made to dissect the superior flap of peritoneum overlying the previously laparoscopically placed mesh. Often the previously placed extraperitoneal mesh had folded up during placement or deflation, causing the recurrence, and consequently the inferior peritoneal flap was usually surprisingly easy to raise (Figures 3 and 4). After deflation to 8 mm Hg, measurements were taken externally for the size of the mesh (Gore-tex Dualmesh; W. L. Gore & Associates, Flagstaff, Arizona), which was at least 5 cm longer craniocaudally to extend inferior to the pubic symphysis. A PDS 0 suture (Ethicon, Somerville, New Jersey) was placed in the medial and superior corner of the mesh, and the mesh was marked 5 cm up from its inferior and medial corner to correspond to the superior edge of the symphysis pubis (Figure 5). The mesh was rolled inward along its horizontal axis, like a scroll, and placed intraperitoneally via a 12-mm trocar,



**Figure 3.** Intraoperative photos of dissection of a pantaloona hernia after previous TEP and 3 anterior repairs: incarcerated loop of sigmoid colon (A); previous extraperitoneal mesh, which has been displaced upward allowing indirect and direct recurrence (B); incision of peritoneum along inferior edge of mesh, which is then extended medially and laterally (C); and complete reduction of direct and indirect defects with preservation of cord structures (D). TEP, total extraperitoneal.

which had temporarily replaced the 5-mm camera trocar. One of the 5-mm trocars was temporarily withdrawn until it was outside of the fascial defect to facilitate insertion of the 12-mm trocar. The mesh was then unrolled and positioned to cover the defect(s). A stab incision was then made in the midline and inferior to the umbilicus to retrieve the PDS suture in the superior and medial corner of the mesh with a suture passer. This allowed the mesh to be more easily maneuvered into the correct position before nonabsorbable tacks (Protack; Covidien) were placed on the pubic bone and along the pubic ramus, taking care to stay clear of the external iliac vein (Figures 2 and 5). The mesh was then tacked medially, superiorly, and cautiously laterally to avoid the nerves in the vicinity. This was aided by the fact the mesh used was sufficiently sized in the craniocaudal dimension such that its superior edge was well above the iliohypogastric nerve; hence, the tacks would be unlikely to be accidentally placed into it, the ilioinguinal nerve, the genital branch of the genitofemoral nerve, or the lateral cutaneous nerve of the thigh. Fibrin sealant (2 ml) (Tisseel Duo; Baxter AG, Vienna, Austria) was sprayed along the inferior edge of the mesh (Figure 5). The inferior peritoneal flap was then reflected up and tacked lightly onto the mesh with care being taken not to leave any significant gaps that would allow herniation of the bowel loops. Fibrin sealant (2 ml) was also then sprayed along the mesh-peritoneum interface, periphery

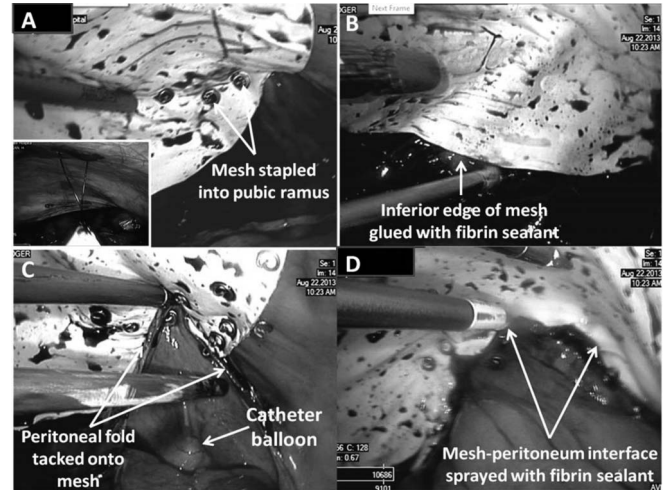


**Figure 4.** Intraoperative findings on multiply recurrent inguinal hernias: extensive bowel adhesions to the rolled up mesh, which must be meticulously divided by sharp dissection (**A, B**) and exposure of retroperitoneal nerves, which can be at risk of damage during dissection and hence no mesh fixation with tacks in these areas (**C, D**).

of the mesh, and over the tacks to minimize the risk of adhesions (**Figure 5**). The fascial defect in the umbilical wound was closed in layers with interrupted PDS 0 sutures and absorbable sutures subcutaneously and subcuticular. The urinary catheter was left in place overnight and removed before the patient was discharged home. All patients were seen at 1 week and 4 weeks with plans to see them annually for 5 years.

## RESULTS

Between November 2009 and October 2013, there were 9 patients with recurrent inguinal hernias after previous failed anterior and laparoscopic repairs with mesh with no patients excluded from the study. This was part of a cohort of 415 patients, over the same period, who had undergone SIL inguinal herniorrhaphy. Each patient had had 1 laparoscopic repair (5 TEPs and 4 TAPPs) and a mean of 2 anterior repairs (range 1–4). The mean age was 55 years (range 42–74); all patients were men. The mean body mass index was 26.5 kg/m<sup>2</sup> (range 24.5–28.4 kg/m<sup>2</sup>) (**Table 1**). All patients were found to have direct hernias with 4 patients having incarcerated hernias containing small bowel/colon that needed to be reduced. Furthermore, there were always omental adhesions in the inguinal region (even in the 5 patients who had had laparoscopic extraperitoneal approach) that had to be divided.



**Figure 5.** Single-incision laparoscopic intraoperative onlay mesh repair for multiply recurrent inguinal hernias: arrow on the mesh corresponding to top of pubic symphysis with mesh stapled into pubic ramus (**A**); stay suture placed in the midline and inferior to the umbilicus to aid orientation of the mesh (**A inset**); inferior edge of mesh glued with fibrin sealant (**B**); the inferior peritoneal fold tacked back onto the mesh (**C**); and fibrin sealant sprayed along mesh-peritoneum interface (**D**).

In all patients, the mesh was found to be deficient medially with the mesh either within the direct defect or that it had folded up exposing a direct defect. In 4 patients, the mesh was also found to be rolled up laterally. Two patients also had a contralateral primary hernia, which was also treated by IPOM repair at the same time. The mean mesh size was 275 mm<sup>2</sup> (range 255–285 mm<sup>2</sup>). The mean operation time was 125 minutes (range 95–165 minutes). There were no mortalities, morbidities, port-site hernias, or recurrences with a mean follow-up of 20 months (range 1–48 months).

## DISCUSSION

Since the first laparoscopic extraperitoneal inguinal hernia repair by Ger et al<sup>19</sup> in 1989, there has been an exponential increase in the uptake of the laparoscopic repair for inguinal hernias worldwide. Data from Medicare Australia ([www.medicareaustralia.gov](http://www.medicareaustralia.gov)) showed that the rates of laparoscopic versus conventional anterior repair were 9.4% in 1994, 20.5% in 2000, and 48% in 2012.<sup>2</sup> The latter figure is reflected in the same percentage of surgeons performing laparoscopic repair (as defined by any surgeon who lodged a claim to Medicare Australia with the item number 30609, which corresponded to laparoscopic inguinal hernia repair). This exponential rise in the uptake of laparoscopic inguinal herniorrhaphy is remarkable

**Table 1.**  
Patient Demographic and Sequence of Previous Hernia Operations

Patient	Age, yrs	BMI, kg/m <sup>2</sup>	Sequence of Previous Hernia Operations
1	54	26.4	Suture repair, anterior mesh repair, TAPP
2	62	28.4	Anterior mesh repair, TEP, anterior IPOM
3	64	24.5	Suture repair, anterior mesh repairs × 3, TAPP
4	74	26.8	Anterior mesh repairs × 2, TEP
5	56	26.6	Anterior mesh repair, TAPP
6	52	26.5	Anterior mesh repair, suture repair, TAPP
7	42	26.2	Anterior mesh repair, TEP
8	47	27.1	Anterior mesh repair, anterior mesh plug repair, TEP
9	44	26.0	Suture repair, anterior mesh repair, TEP

All patients were males.

BMI, body mass index; IPOM, intraperitoneal onlay mesh repair; TAPP, transabdominal preperitoneal; TEP, totally extraperitoneal.

given that the vast majority of the laparoscopic repairs are only performed in private hospitals where surgical trainees are not normally trained and the surgery is normally only performed by the consultants. It is possible that many surgeons go overseas to attend hands-on animal workshops in TEP/TAPP repair, possibly due to the lack of such courses offered in Australia due to the stringent animal ethics requirements to run such courses in Australia. It has been estimated that the recurrence rates for inguinal hernias range from 7% to 10% in Australia and this means that there are increasingly more patients with multiply recurrent inguinal hernias after failed anterior and laparoscopic repairs.<sup>2</sup>

The International Endohernia Society Guidelines<sup>6</sup> suggest that the best repair for the treatment of an inguinal hernia recurrence after an anterior approach is the laparoscopic approach and vice versa. Yet, there are no specific recommendations for the treatment of multiply recurrent hernias after both anterior and laparoscopic approaches. Anecdotal reports of a relaparoscopic approach, usually TAPP, have come from highly specialized centers but the incidence of complications are much higher even though the success rates are higher than another anterior approach. Van den Heuvel and Dwars<sup>7</sup> reported a series of 51 patients who underwent a TAPP repair for a recurrent inguinal hernia after previous posterior hernia repair. In two-thirds of the patients, the recurrence was located caudally or medially from the previously placed mesh. There was no recurrence with a mean follow-up of 70 months. However, there were 9 postoperative adverse events, 4 port-site hernias, and 4 with postoperative pain, which restricted daily activities.

The concept of IPOM in the management of inguinal hernia is not new. In 1998, Kingsley et al.<sup>20</sup> demonstrated the feasibility of inguinal hernia repair using IPOM with polytetrafluoroethylene mesh (10–15 cm<sup>2</sup>) but the recurrence rate was 43% at 41-month follow-up. Sarli et al<sup>21</sup> compared TAPP with IPOM in a prospective, randomized fashion. A total of 76 patients underwent TAPP and 72 underwent IPOM; 10 × 7 cm<sup>2</sup> polytetrafluoroethylene mesh was used for IPOM and 15 × 12 cm<sup>2</sup> polypropylene mesh was used for TAPP. There were no recurrences in TAPP at 32 months compared with an 11.1% recurrence rate for IPOM. Neuralgia was noted with 3 TAPP and 11 IPOM patients (*P* < .05). As a results of these and other studies, the IPOM technique has been considered inferior to the TAPP/TEP repair.<sup>6</sup> Clearly, multiple factors have contributed to these poor results, including no reduction of the hernia sacs, inadequate mesh size, lack of permanent bony fixation as well as lack of tissue glue fixation of the inferior edge of the mesh.

Central to the conventional laparoscopic approach is the attempt to place the mesh in the extraperitoneal position, and this means having to raise the peritoneal flaps sufficiently to cover the new mesh. This is almost impossible, as often the peritoneum is so densely adherent to the previous mesh that one ends up with multiple defects in the peritoneal flaps. This would then expose the normal mesh to bowel-causing adhesions with possible deleterious sequelae. Indeed, Lo Menzo et al<sup>8</sup> showed, in a series of 6 patients with 7 recurrent inguinal hernias after laparoscopic repairs, there were 2 cases where the peritoneal flap was not able to cover the mesh and a tissue-separating mesh with fibrin sealant had to be used to cover the

myopectineal orifice. Additionally, the TAPP repair involves placement of a 10-mm trocar through the linea alba in the umbilical region and 2 × 5 mm trocars more inferiorly (although some surgeons prefer to place these latter trocars laterally on each side of the abdomen), all of these trocar sites are at risk of port-site hernia formation. An extraperitoneal approach, with the inferiorly placed 5-mm trocars, would be difficult, if not impossible, because the extraperitoneal space is likely to be obliterated from the previous laparoscopic repair, and this is the reason why most relaparoscopic repairs have been performed as a TAPP procedure where the 5-mm trocars can be placed laterally on either side of the umbilical camera port. In our study, the umbilical (and only) port was placed via transverse incisions in the anterior and posterior rectus sheaths with retraction of the rectus muscle laterally, and this was closed with slowly absorbable monofilament sutures. These entry and closure techniques prevented port-site hernia formation.

With the introduction of the first commercial single-port device, SILS port, in 2007, there has been an exponential rise in the number and variety of SIL procedures performed. It has been estimated the learning curve for SILS for an experienced laparoscopic surgeon is between 25 and 50 cases,<sup>22</sup> and this means that it should not take more than a year for a general surgeon in Australia, who would, on average, perform 26 inguinal hernias per annum (www.medicareaustralia.gov), to be competent with SILS.

While the conventional laparoscopic ventral hernia repair involves placement of a 10-mm camera port in the upper outer quadrant and 2 × 5 mm ports more inferiorly in the anterior axillary line, such a configuration of ports would be quite a distance from the inguinal region, causing poor ergonomics for the dissecting instruments as well as the fact that longer dissecting instruments would have to be used, which would further compromise the ergonomics of dissecting instruments. While SILS suffers from the relative lack of triangulation, this can be overcome by modifying dissection techniques, the use of a smaller and longer laparoscope, and with increased experience.

Our recently completed prospective randomized controlled study comparing single-port and multiport laparoscopic totally extraperitoneal inguinal herniorrhaphy demonstrated similar safety, efficacy, and additional cosmetic and noncosmetic benefits of the single-port technique beyond the learning curve. To date, the principal author has performed >700 SIL-TEP repairs and 100 SIL-ventral hernia repairs, with the latter including some of the most difficult abdominal wall hernias, namely, parastomal

hernias. Therefore, it became a natural progression to treat the multiply recurrent inguinal hernias after open and laparoscopic repairs with SILS, using the umbilicus as the only point of access for placement of the single port. The SILS port allows for placement of a 12-mm trocar for ease of placing an antiadhesive mesh intraperitoneally. The SIL-IPOM repair follows closely the dissection of the inferior flap during the TAPP repair as meticulous dissection of the inferior flap, below the inferior border of the previous extraperitoneally placed mesh, is important to reduce any direct, indirect, and femoral hernias, as well as any lipoma of the cord with preservation of the latter and its structures. Because virtually all of these hernias have a direct component, fixation of the mesh into the pubic ramus with nonabsorbable tacks is an important aspect of the repair to ensure permanent fixation to prevent any further mesh displacement or eventration into the direct defect. However, unlike a TAPP repair of a recurrent inguinal hernia, the SIL-IPOM does not interfere with the previously placed extraperitoneal mesh, but it aims to cover the defective inferior/medial border of the previous mesh with an antiadhesive mesh that is then extended well above the previous extraperitoneally placed mesh in an attempt to prevent accidental stapling of the relevant nerves in the groin with consequent severe postherniorrhaphy chronic pain. The fact that multiply recurrent hernias seem to have a direct component suggests an intrinsic weakness of the myopectineal orifice. Indeed, Henriksen et al<sup>23</sup> found a consistent, significant increase in immature type III collagen relative to the stronger type I collagen in patients with a hernia, and these changes were most pronounced in patients with a direct inguinal hernia than in those with an indirect inguinal hernia. Furthermore, although the inferior edge of the mesh cannot be tacked to avoid damage to vital neurovascular structures, it can be fixed with fibrin sealant. Additionally, reflection of the inferior peritoneal fold back onto the mesh and its fixation with tacks prevents any further folding of the mesh, which should minimize the risks of recurrence.

Lau,<sup>24</sup> in a prospective randomized study of mesh fixation with either fibrin sealant or tacks in laparoscopic inguinal hernia repair, showed that fibrin sealant reduced the incidence of postherniorrhaphic chronic pain. In our study, we used fibrin sealant to fix the inferior edge of the mesh. But additionally, we also used fibrin sealant for its antiadhesive property based on our experimental and clinical research.<sup>25</sup> Indeed, since 2007, for all our patients undergoing laparoscopic ventral hernia repair, we have sprayed fibrin sealant along the periphery of the mesh, where adhesions are likely to take place, as well as on the tacks,

which are known to cause adhesions. Furthermore, the application of fibrin sealant along the mesh-peritoneum interface also reduces the risk of bowel loops herniating through undetected gaps.

One important technical aspect in our study relates to the use of the mesh, which must be big enough in the cranio-caudal dimension such that the superior edge of the mesh was tacked well above the relevant nerves in the inguinal region to avoid nerve entrapment even though, theoretically, only a 5-cm overlap of the defect is normally required for a sound repair. The single-port approach not only allowed the instruments to be inserted sufficiently far from the inguinal region, hence facilitating ease of dissection, but also permitted the mesh to be tacked more superiorly than would have been possible with the multiport approach. In addition, the inferior peritoneal flap had to be meticulously raised, with avoidance of electrocautery, to prevent accidental damage to the retroperitoneal nerves that otherwise could have caused chronic pain postoperatively. In our case series of 9 patients over 4 years, all were successfully treated with SIL-IPOM repair without any complication or recurrence with a mean follow-up of 20 months. Furthermore, none of the patients reported chronic pain after SIL-IPOM repair. This compares favorably with the alternative TAPP repair, which would not be suitable for surgeons only trained in the TEP repair. On the other hand, successful SIL-IPOM repair demands the highest level of competence in laparoscopic surgery to achieve safe adhesiolysis, avoidance of inadvertent nerve damage or entrapment through detailed knowledge of laparoscopic inguinal anatomy, and the use of sufficiently large antiadhesive mesh, which must be judiciously fixed to achieve successful repair.

## CONCLUSIONS

Multiply recurrent inguinal hernias following failed conventional anterior and laparoscopic repairs can be safely and effectively treated with laparoscopic IPOM repair. When combined with SILS, the umbilicus can be used as the only incision site, which apart from having the potential to reduce port-site complications also allowed improved ergonomics of the dissecting instruments, albeit with modified dissection techniques, by being at optimal proximity to the inguinal regions, where bilateral repairs can be performed safely and effectively.

## References:

1. Simons MP, Aufenacker T, Bay-Nielsen M, et al. European Hernia Society guidelines on the treatment of inguinal hernia in adult patients. *Hernia*. 2009;13(4):343–403.

2. Australian Government, Department of Health and Ageing. Surgical repair of inguinal hernia: review report. [www.medicareaustralia.gov](http://www.medicareaustralia.gov). December 17 2013.

3. Shah NR, Mikami DJ, Cook C, et al. A comparison of outcomes between open and laparoscopic surgical repair of recurrent inguinal hernias. *Surg Endosc*. 2011;25(7):2330–2337.

4. Demetrashvili Z, Qerqadze V, Kamkamidze G, et al. Comparison of Lichtenstein and laparoscopic transabdominal preperitoneal repair of recurrent inguinal hernias. *Int Surg*. 2011;96(3):233–238.

5. Bignell M, Partridge G, Mahon D, Rhodes M. Prospective randomized trial of laparoscopic (transabdominal preperitoneal—TAPP) versus open (mesh) repair for bilateral and recurrent inguinal hernia: incidence of chronic groin pain and impact on quality of life: results of 10 year follow-up. *Hernia*. 2012;16(6):635–640.

6. Bittner R, Arregui ME, Bisgaard T, et al. Guidelines for laparoscopic (TAPP) and endoscopic (TEP) treatment of inguinal hernia [International Endohernia Society (IEHS)]. *Surg Endosc*. 2011;25(9):2773–2843.

7. van den Heuvel B, Dwars BJ. Repeated laparoscopic treatment of recurrent inguinal hernias after previous posterior repair. *Surg Endosc*. 2013;27(3):795–800.

8. Lo Menzo E, Spector SA, Iglesias A, et al. Management of recurrent inguinal hernias after total extraperitoneal (TEP) herniorrhaphies. *J Laparoendosc Adv Surg Tech A*. 2009;19(4):475–478.

9. Tran H. Safety and efficacy of laparoendoscopic single-site surgery for abdominal wall hernias. *JLSLS*. 2012;16(2):242–249.

10. Reynolds W Jr. The first laparoscopic cholecystectomy. *JLSLS*. 2001;5(1):89–94.

11. Zapf M, Yetasook A, Leung D, et al. Single-incision results in similar pain and quality of life scores compared with multi-incision laparoscopic cholecystectomy: a blinded prospective randomized trial of 100 patients. *Surgery*. 2013;154(4):662–671.

12. Qiu J, Yuan H, Chen S, He Z, Han P, Wu H. Single-port versus conventional multiport laparoscopic cholecystectomy: a meta-analysis of randomized controlled trials and nonrandomized studies. *J Laparoendosc Adv Surg Tech A*. 2013;23(10):815–831.

13. Lee WS, Choi ST, Lee JN, et al. Single-port laparoscopic appendectomy versus conventional laparoscopic appendectomy: a prospective randomized controlled study. *Ann Surg*. 2013;257(2):214–218.

14. Soon Y, Yip E, Onida S, Mangat H. Single-port hernia repair: a prospective cohort of 102 patients. *Hernia*. 2012;16(4):393–396.

15. Buckley FP 3rd, Vassaur H, Monsivais S, et al. Comparison of

outcomes for single-incision laparoscopic inguinal herniorrhaphy and traditional three-port laparoscopic herniorrhaphy at a single institution. *Surg Endosc*. 2014;28(1):30–35.

16. Tsai YC, Ho CH, Tai HC, Chung SD, Chueh SC. Laparoendoscopic single-site versus conventional laparoscopic total extraperitoneal hernia repair: a prospective randomized clinical trial. *Surg Endosc*. 2013;27(12):4684–4692.

17. Golkar FC, Ross SB, Sperry S, et al. Patients' perceptions of laparoendoscopic single-site surgery: the cosmetic effect. *Am J Surg*. 2012;204(5):751–761.

18. Tran H. Safety and efficacy of single incision laparoscopic surgery for total extraperitoneal inguinal hernia repair. *JLS*. 2011;15(1):47–52.

19. Ger R, Monroe K, Duvivier R, Mishrick A. Management of indirect inguinal hernias by laparoscopic closure of the neck of the sac. *Am J Surg*. 1990;159(4):370–373.

20. Kingsley D, Vogt DM, Nelson MT, Curet MJ, Pitcher DE.

Laparoscopic intraperitoneal onlay inguinal herniorrhaphy. *Am J Surg*. 1998;176(6):548–553.

21. Sarli L, Pietra N, Choua O, Costi R, Cattaneo G. Laparoscopic hernia repair: a prospective comparison of TAPP and IPOM techniques. *Surg Laparosc Endosc*. 1997;7(6):472–476.

22. Sherwinter DA. Transitioning to single-incision laparoscopic inguinal herniorrhaphy. *JLS*. 2010;14(3):353–357.

23. Henriksen NA, Yadete DH, Sorensen LT, Agren MS, Jorgensen LN. Connective tissue alteration in abdominal wall hernia. *Br J Surg*. 2011;98(2):210–219.

24. Lau H. Fibrin sealant versus mechanical stapling for mesh fixation during endoscopic extraperitoneal inguinal hernioplasty: a randomized prospective trial. *Ann Surg* 2005;242(5):670–675.

25. Tran H, Saliba L, Chandratnam E, Turingan I, Hawthorne W. Strategies to minimize adhesions to intraperitoneally placed mesh in laparoscopic ventral hernia repair. *JLS*. 2012; 16(1):89–94.