

Radiographic findings of Proteus Syndrome

Nishant Mukesh Gandhi, MD, and Eric A. Davalos, MD; plus Rajeev K. Varma, MD

The extremely rare Proteus Syndrome is a hamartomatous congenital syndrome with substantial variability between clinical patient presentations. The diagnostic criteria consist of a multitude of clinical findings including hemihypertrophy, macrodactyly, epidermal nevi, subcutaneous hamartomatous tumors, and bony abnormalities. These clinical findings correlate with striking radiographic findings.

Introduction

This case report radiographically presents many of the findings associated with the rare Proteus Syndrome, also known as Wiedemann syndrome. The Proteus Syndrome was first described in four patients in 1983 by Wiedeman (1). It is thought to affect roughly 1 out of a million, to 1 out of 10 million (2). The diagnosis is difficult due to the high variability of clinical presentations. General diagnostic criteria suggested as mandatory for diagnosis are mosaic distribution of lesions, progressive course, and sporadic occurrence. More specific clinical manifestations have also been suggested, including distorting, progressive overgrowth of the skeleton; cerebriiform connective tissue nevi, which have been considered pathognomonic for the syndrome; linear verrucous epidermal nevus; adipose dysregulation; and several other cutaneous malformations (3, 4). We review several of the radiographic findings of the Proteus Syndrome in a 26-year-old Guatemalan male who presented with chronic foot and abdominal pain.

Case report

A 26-year-old male presented to Harbor-UCLA General Hospital with a chief complaint of chronic abdominal and foot pain. The patient had no previous diagnosis for his congenital deformities. He was referred to multiple subspe-

cialties for further evaluation of enlarging feet since age 1, multiple congenital skin lesions, and chronic chest wall and abdominal pain.

Upon evaluation by the Dermatology service, the patient was found to have diffuse congenital epidermal nevi throughout the body and multiple malformations, including a left-flank lymphangioma circumscriptum and a right-flank dermatofibroma. There were also superficial hyperpigmented lesions overlying the anterior chest wall masses, seen on CT.

The patient had a history of congenital deformities including cryptorchism, for which he had an orchiopexy in 2002. The only laboratory abnormality found was low testosterone, thought to be secondary to cryptorchism. After evaluation by the GI-Oncology service, the chest wall

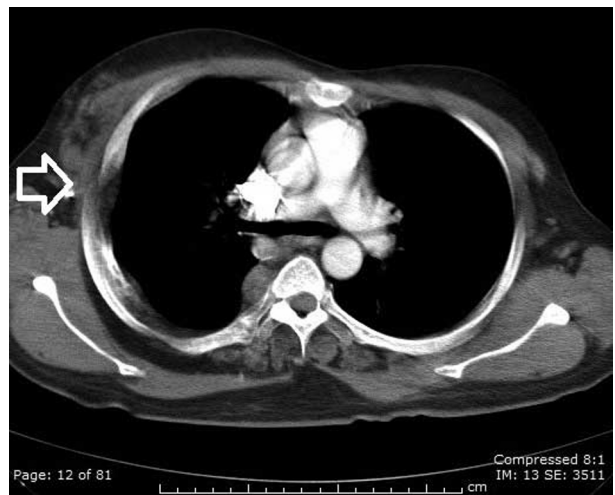

Figure 1. Proteus Syndrome in a 26-year-old male. Axial CT (All images were created with Siemens SOMATOM Sensation 64 Slice, mA 200, KVp 120). Note hemihypertrophy of the right chest, and a soft-tissue mass under the right crus (white open arrow).

Citation: Gandhi NM, Davalos EA, Varma RK. Radiographic findings of Proteus Syndrome. *Radiology Case Reports*. (Online) 2014;2:911.

Copyright: © 2014 The Authors. This is an open-access article distributed under the terms of the Creative Commons Attribution-NonCommercial-NoDerivs 2.5 License, which permits reproduction and distribution, provided the original work is properly cited. Commercial use and derivative works are not permitted.

The authors are all in the Department of Radiology at Harbor-UCLA Hospital, Los Angeles CA. Contact Dr. Gandhi at NishantGandhiMD@gmail.com.

Competing Interests: The authors have declared that no competing interests exist.

DOI: 10.2484/rcr.v9i2.911

Radiographic findings of Proteus Syndrome

masses were followed radiographically, as they were thought to be part of the patient's broader syndrome. The patient claimed normal pubertal onset, and a negative family history.

Based on complete radiographic evaluation and physical exam findings, the diagnosis of the Proteus Syndrome was made.

Discussion

The rare Proteus Syndrome is difficult to diagnose due to its multisystem involvement and broad variability in both

clinical presentation and radiographic findings. The radiographic findings can also be easily confused with neoplasm. Proteus Syndrome has been associated with mosaicism for a somatic activating mutation in the *AKT1* gene on chromosome 14q32.3 (5). Genetic testing may be performed to make the diagnosis (2). The differential diagnosis can include Klippel-Trenaunay-Weber syndrome, Ollier disease, and Maffucci syndrome (4, 6).

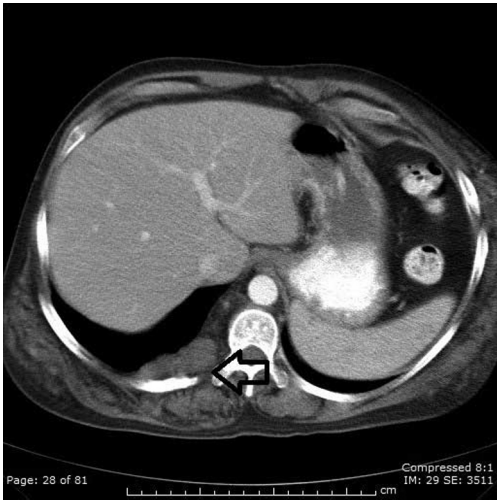


Figure 2. Proteus Syndrome in a 26-year-old male. Axial CT. An 8 x 2cm soft-tissue mass appears posterior to the right crus (black open arrow). Also note diffuse soft-tissue infiltration of the right flank musculature, thought to be secondary to subcutaneous nevi.

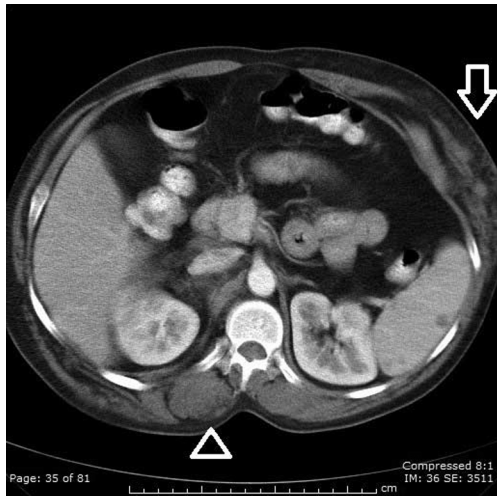


Figure 3. Proteus Syndrome in a 26-year-old male. Axial CT. The asymmetry of the paraspinal muscles is thought to be due to deposition within the muscles (open arrowhead). Note soft-tissue infiltration of the left anterior chest wall (white open arrow), as well as nonspecific, low-density lesions in the spleen.

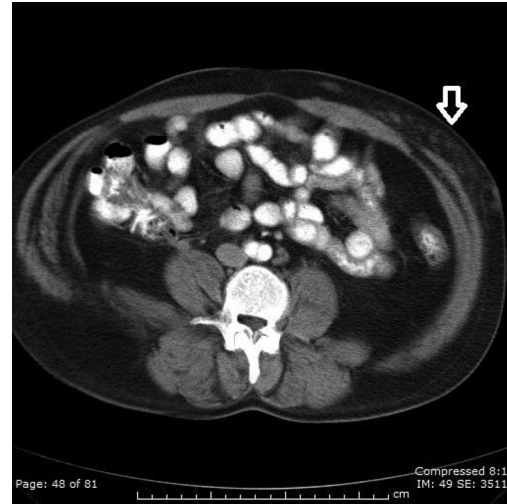


Figure 4. Proteus Syndrome in a 26-year-old male. Axial CT. Note soft-tissue infiltration of the left anterior abdominal wall fat (white open arrow).

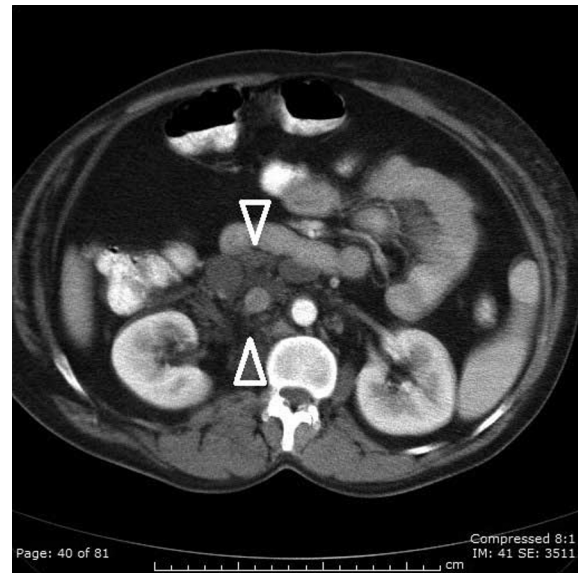


Figure 5. Proteus Syndrome in a 26-year-old male. Axial CT. Note striking para-aortic lymphadenopathy versus conglomerate soft-tissue mass (white open arrowheads).

Named after the Greek god Proteus—"the polymorphous"—the disorder combines a multitude of highly variable congenital features that include partial gigantism of

Radiographic findings of Proteus Syndrome

the hands and/or feet, diffuse nevi, hemihypertrophy (Fig. 1), subcutaneous tumors, macrocephaly or other skull anomalies, lipomatosis, and possible accelerated growth

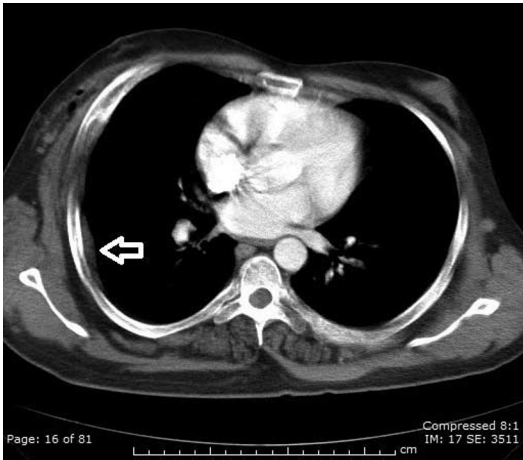


Figure 6. Proteus Syndrome in a 26-year-old male. Axial CT. Note extrapleural lesion in the peripheral right lung (white open arrow), and soft-tissue infiltration of the right anterior lateral chest wall.

and visceral affections (3). The Proteus syndrome is considered a sporadic congenital disorder; however, some have suggested familial transmission (3).

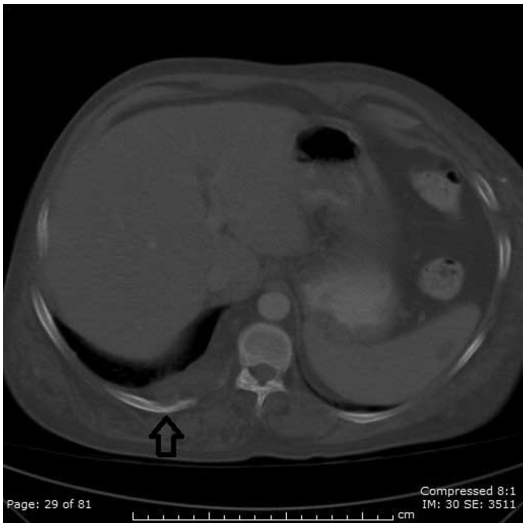


Figure 7. Proteus Syndrome in a 26-year-old male. Axial CT. Note bony erosions in the 10th rib adjacent to soft-tissue mass under the right crus (black open arrow).

Radiographic findings progress in severity as a patient with this diagnosis is followed (7). Proteus Syndrome is a progressive condition; children are born without any deformities, but tumors, and skin and bone growths, appear as the child ages (6). As demonstrated in this case, one of the typical findings of the syndrome is adipose dysregulation, causing infiltration of muscular and subcutaneous

tissues (Fig. 2). On cross-sectional imaging, this can be confused radiographically with fatty infiltration of the musculature, seen in disuse scenarios (Figs. 3 and 4). Also seen in this patient were multiple areas of soft-tissue overgrowth

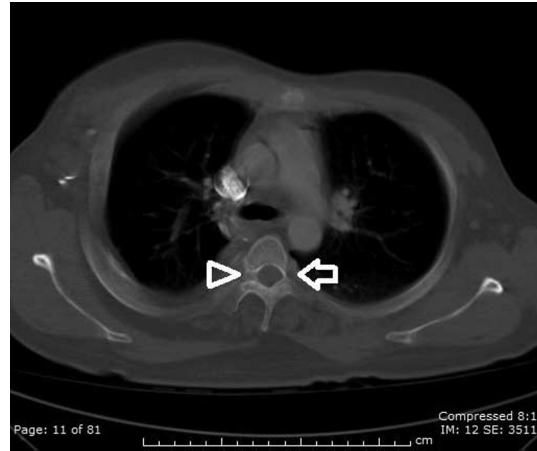


Figure 8. Proteus Syndrome in a 26-year-old male. Axial CT. Note left pedicle hypoplasia (white open arrow) and right pedicle hyperplasia (white open arrowhead) at the 4th vertebral level.

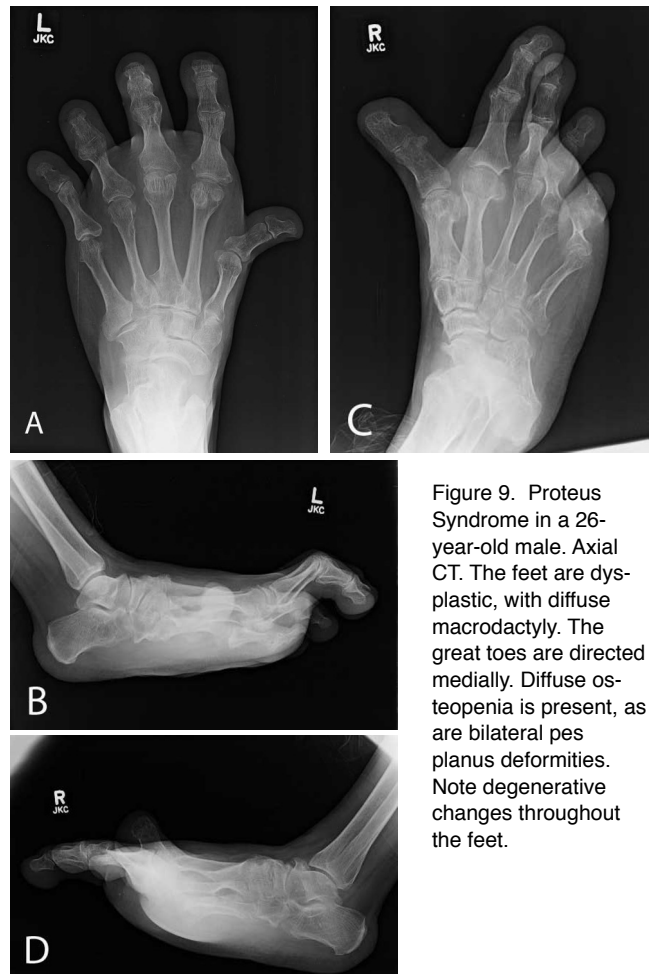


Figure 9. Proteus Syndrome in a 26-year-old male. Axial CT. The feet are dysplastic, with diffuse macrodactyly. The great toes are directed medially. Diffuse osteopenia is present, as are bilateral pes planus deformities. Note degenerative changes throughout the feet.

Radiographic findings of Proteus Syndrome

that corresponded to the hamartomatous nature of this syndrome (Figs. 5, 6, and 7). Several of these were suspected to be malignant given the radiographic findings; however, no interval change was noted, and these lesions were found to be benign. However, it is paramount to note that these can be easily observed to be radiographically malignant. As seen in our case, the adjacent bone demonstrated erosions secondary to the adjacent soft-tissue mass, a typical finding that is concerning for malignancy (Fig. 7).

Skeletal dysplasia is another hallmark of the Proteus Syndrome (6). In our patient, there was marked vertebral dysplasia, demonstrated by unilateral megaspondylodysplasia with simultaneous microspondylodysplasia of the contralateral pedicle at the same vertebral level (Fig. 8). There was also macrodactyly and severe derangement of the feet (Fig. 9). These findings will continue to progress both radiographically and clinically as the patient grows older.

The Proteus Syndrome presents with a multitude of radiographic findings that can be easily confused with malignancy or infiltrative disease. Radiologists should be familiar with the constellation of findings to assist clinicians in the diagnosis of this disorder.

References

1. Wiedemann HR, Burgio GR, Aldenhoff P, Kunze J, Kaufmann HJ, Schirg E. The proteus syndrome: partial gigantism of the hands and/or feet, nevi, hemihypertrophy, subcutaneous tumors, macrocephaly or other skull anomalies and possible accelerated growth and visceral affections. *Eur J Pediatr.* 1983;140:5-12. [PubMed]
2. Legendre C-M, Charpentier-Côté C, Drouin R, Bouffard C. Neurofibromatosis type 1 and the “elephant man's” disease: the confusion persists: an ethnographic study. *PLoS ONE.* 2011;6(2):e16409. [PubMed]
3. Biesecker, L. G. The multifaceted challenges of Proteus syndrome. *JAMA* 285: 2240-2243, 2001. [PubMed]
4. Rizzo R, Pavone L, Sorge G, Parano E, Baraitser M. Proteus syndrome: report of a case with severe brain impairment and fatal course. *J Med Genet.* 1990 Jun;27(6):399-402. [PubMed]
5. Online Mendelian Inheritance in Man, OMIM®. Johns Hopkins University, Baltimore, MD. MIM Number: 176920; last edited: 8/1/2011. World Wide Web URL: <http://omim.org/176920>.
6. Cohen, M. M. (2005), Proteus syndrome: An update. *Am. J. Med. Genet.*, 2005; 137C: 38-52. [PubMed]
7. E.M. Azouz, T. Costa, N. Fitch. Radiologic findings in the proteus syndrome. *Pediatric Radiology.* 1987, Volume 17, Issue 6 pp 481-485. [PubMed]