

[CASE REPORT]

Hyperparathyroidism-jaw Tumor Syndrome Confirmed by Preoperative Genetic Testing

Kenji Koikawa¹, Yosuke Okada¹, Hiroko Mori¹, Mayuko Kawaguchi¹,
Shinya Uchino² and Yoshiya Tanaka¹

Abstract:

We herein report the case of a young woman who was diagnosed with primary hyperparathyroidism and in whom genetic testing confirmed a diagnosis of hyperparathyroidism-jaw tumor syndrome. Familial hyperparathyroidism was suspected based on the patient's young age at the onset of the disease. Thus, genetic testing was performed. It showed a germline mutation in the *HRPT2/CDC73* gene and confirmed the diagnosis of hyperparathyroidism-jaw tumor syndrome. Total parathyroidectomy was performed to prevent recurrence. In patients with early-onset hyperparathyroidism, genetic testing should be considered to facilitate the selection of a proper surgical procedure based on the consideration of future life expectancy.

Key words: younger age, hyperparathyroidism, *HRPT2/CDC73*, hyperparathyroidism-jaw tumor syndrome

(Intern Med 57: 841-844, 2018)

(DOI: 10.2169/internalmedicine.9509-17)

Introduction

Primary hyperparathyroidism (PHPT) is a disease caused by the autonomous over-secretion of parathyroid hormone (PTH) due to adenoma and hyperplasia of the parathyroid gland, with an estimated prevalence of 6.7 per "1,000" population (1). The majority of PHPT cases are not inherited, and some are caused by genetic mutations, including multiple endocrine neoplasia (MEN), familial hypocalciuric hypercalcemia, neonatal severe hyperparathyroidism, hyperparathyroidism-jaw tumor (HPT-JT) syndrome (caused by mutations in the *CDC73* gene), and familial isolated hyperparathyroidism (2).

The majority of cases of PHPT are seen in women of 40 to 75 years of age, while HPT-JT syndrome occurs in patients who are relatively younger (3), with an autosomal dominant mode of inheritance. PHPT is observed in 80-90% of patients with the HPT-JT syndrome, parathyroid carcinoma is seen in 10-15%, and ossifying fibromas of the maxilla or mandible is seen in approximately 30%; furthermore, some patients have renal or uterine abnormalities (4). The clinical presentation of HPT-JT syndrome is similar to that

of most PHPT cases, with no difference in the laboratory findings (i.e., serum calcium, inorganic phosphorus, and PTH levels) or urinary calcium excretion (2).

The 17-exon gene that causes HPT-JT, *CDC73* (*HRPT2*), is located on chromosome 1q25-q31 and encodes parafibromin, a 531-amino acid protein. The latter is expressed in the parathyroid glands, adrenal glands, kidneys, heart, and skeletal muscle. *CDC73* (*HRPT2*) is identified as a tumor suppressor gene; thus, the loss of the parafibromin function is considered to lead to tumor development (5). Mutations in the *CDC73* gene are found in approximately 50-75% of patients with HPT-JT syndrome (6); thus, the identification of these genetic mutations is necessary for the diagnosis HPT-JT syndrome.

We herein report our experience with a case in which genetic testing was useful for confirming the diagnosis of HPT-JT syndrome and determining the treatment strategy in a woman with an early-onset form of PHPT.

Case Report

A 20-year-old woman who had experienced recurrent ureteric calculi and hydronephrosis since 18 years of age,

¹First Department of Internal Medicine, School of Medicine, University of Occupational and Environmental Health, Japan and ²Noguchi Thyroid Clinic and Hospital Foundation, Japan

Received: May 15, 2017; Accepted: July 27, 2017; Advance Publication by J-STAGE: December 8, 2017

Correspondence to Dr. Yoshiya Tanaka, tanaka@med.uoeh-u.ac.jp

Table. The Laboratory Data on Admission.

(Urine)	
pH	6.0
S.G.	1.027
glu	(-)
prot	(+2)
OB	(±)
(CBC)	
WBC	5,300 / μ L
RBC	396×10^5 / μ L
Hb	8.6 g/dL
Hct	28.3 %
Plt	47.8 / μ L
(Biochemistry)	
TP	7.4 g/dL
Alb	4.4 g/dL
AST	9 U/I
ALT	11 U/I
γ -GTP	13 U/I
ALP	618 U/I
Amy	48 U/I
BUN	9 mg/dL
Cre	0.65 mg/dL
eGFR	97.21 mL/min/1.73 m ²
(Bone metabolism)	
s-Ca	11.8 mg/dL
s-iP	2.1 mg/dL
u-Ca	5.3 mg/dL
u-iP	15.5 mg/dL
Urine Ca excretion	160 mg/day
FECa	1.14
%TRP	76.3 %
intact-PTH	256 pg/mL
BAP	47.2 μ g/L
TRACP-5b	913 mU/dL

%TRP: % tubular reabsorption of phosphate, intact-PTH: intact-parathyroid hormone, BAP: bone-specific alkaline phosphatase, TRACP-5b: tartrate-resistant acid phosphatase-5b

presented to the emergency outpatient clinic with thirst, polyuria, malaise, anorexia and vomiting. Detailed blood tests showed hypercalcemia (serum calcium: 12.5 mg/dL), and she was admitted for further examination and treatment. She had no history of fracture. A physical examination showed no obvious abnormal findings. Biochemical tests indicated hyperalkalinephosphatasemia (serum alkaline phosphatase: 618 U/L), hypercalcemia (serum calcium: 11.8 mg/dL), hypophosphatemia (inorganic phosphorus: 2.1 mg/mL), a high level of intact PTH (256 pg/mL), increased urinary calcium excretion (fractional calcium excretion: 1.14%), and decreased urinary phosphate reabsorption (tubular phosphate reabsorption: 76.3%) (Table). The provisional diagnosis, based on these findings, was PHPT. Ultrasonography showed a 15×11×6 mm hypoechoic mass with a smooth margin and poor blood flow. Technetium-99m methoxyisobutylisonitrile scintigraphy showed accumulation in the

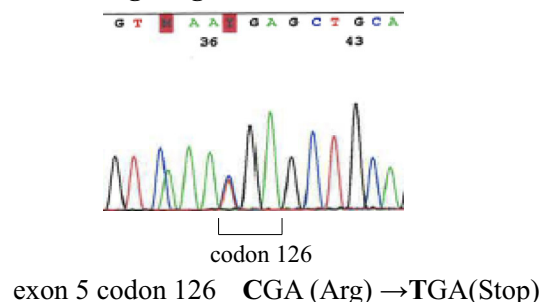
HRPT2/CDC73 gene germline mutation

Figure 1. The results of genetic testing. A germline mutation was identified in the *HRPT2/CDC73* gene, which changed codon 126 in exon 5 from CGA (Arg) to TGA (Stop). The identification of this mutation allowed for the diagnosis of hyperparathyroidism-jaw tumor syndrome to be confirmed.

same region as the hypoechoic area. The results of these imaging studies confirmed the diagnosis of PHPT.

Familial hyperparathyroidism was suspected due to the young age of the patient, but MEN was ruled out due to the absence of pituitary adenoma, adrenal mass, and pancreatic mass. Thus, genetic testing was performed to confirm the suspected diagnosis of familial hyperparathyroidism (excluding MEN). The results showed a germline mutation in the *HRPT2/CDC73* gene [a change of CGA (Arg) → TGA (Stop) at codon 126 in exon 5] (Fig. 1). This finding confirmed the diagnosis of HPT-JT syndrome, one of several forms of familial hyperparathyroidism. The patient underwent total parathyroidectomy with auto-transplantation to the forearm (autotransplantation of one-half of the right inferior, left superior, and left inferior parathyroid glands). A histopathological examination showed chief cells without any abnormal mitosis, vascular invasion, capsular invasion, or stromal fat cells in the right inferior parathyroid gland, indicating parathyroid adenoma; the other three parathyroid glands were normal (Fig. 2).

Genetic testing of her family members showed that her mother and one of her brothers were carriers of HPT-JT syndrome. Her mother did not have PHPT but she had uterine and ovarian tumors. Her brother did not have PHPT or the associated complications (Fig. 3).

With regard to complications associated with HPT-JT syndrome, the patient only had a uterine mass. At the last clinical examination, the patient showed a favorable clinical course without complications or recurrence.

Discussion

We presented the case of a female patient with early-onset PHPT in whom genetic testing confirmed the diagnosis of HPT-JT syndrome and helped to determine the appropriate surgical procedure, as she was considered to be at risk of developing parathyroid carcinoma. The current clinical guidelines recommend total parathyroidectomy with auto-transplantation of normal parathyroid glands to the forearm

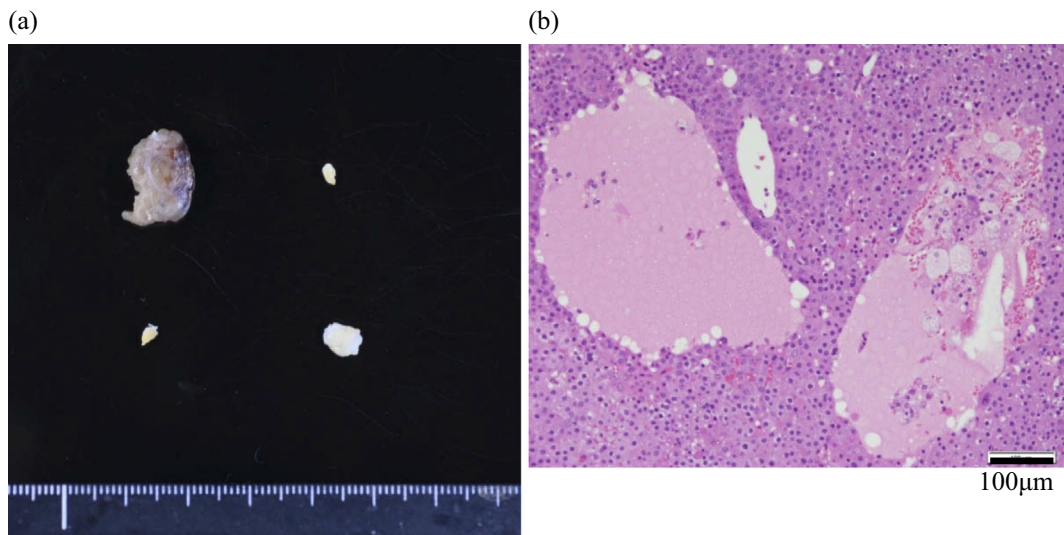


Figure 2. The results of the histopathological examination. (a) The examination of an excised adenoma specimen from the right superior parathyroid gland, and specimens from three other parathyroid glands. (b) The right inferior parathyroid gland had chief cells without abnormal mitosis, vascular invasion, capsular invasion, or stromal fat cells, indicating parathyroid adenoma. The other three parathyroid glands were normal.

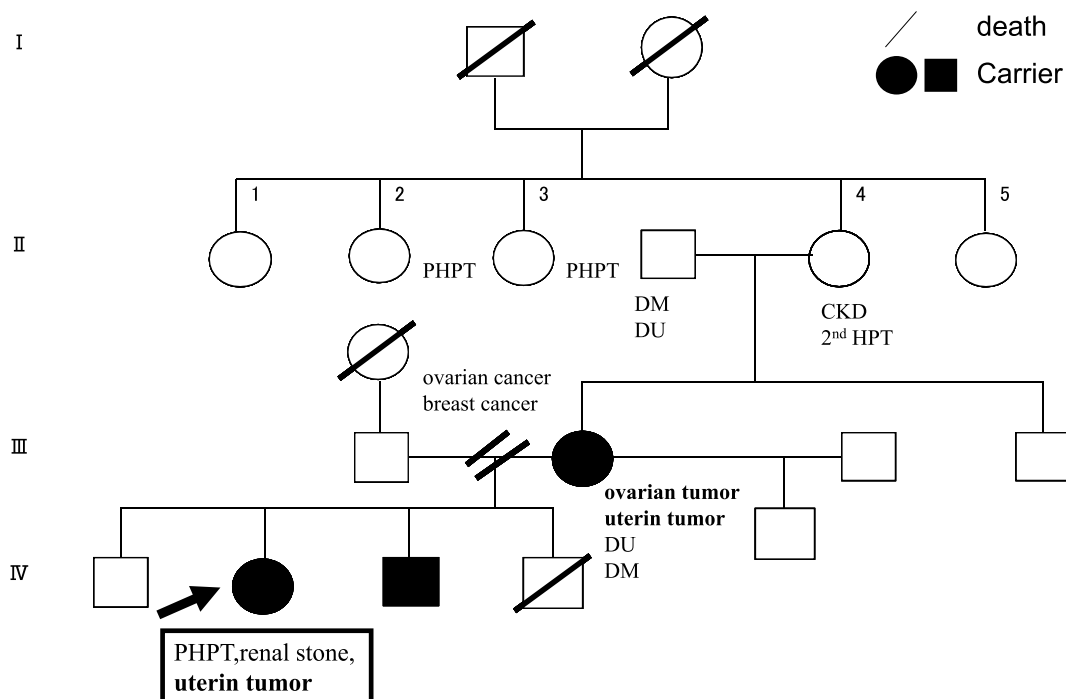


Figure 3. The patient's family tree. This family tree shows that the patient's mother and one of her brothers were carriers of HPT-JT syndrome; they did not have PHPT but the mother had uterine and ovarian tumors. HPT-JT: hyperparathyroidism-jaw tumor, PHPT: primary hyper parathyroidism

as a treatment for HPT-JT syndrome, in order to prevent recurrence (7), which may occur after the enlargement of the parathyroid gland following the removal of the lesions in one parathyroid gland (8). In such cases, further surgery is difficult to perform due to adhesion after the first surgery. Thus, total parathyroidectomy with auto-transplantation to the forearm (auto-transplantation of one-half of the right inferior, left superior, and left inferior parathyroid glands) was

performed in this case.

A previous report showed that 30% of patients with HPT-JT syndrome had jaw tumors while others had other complications, primarily renal tumors, uterine diseases, thyroid carcinomas, pancreatic carcinomas, testicular tumors, and neurofibromas (4). Our patient was also examined for complications, and a uterine mass was detected. Thus, genetic testing for the diagnosis of HPT-JT, as well as a detailed ex-

amination to detect the presence or absence of complications is needed for the full assessment of the prognosis. Furthermore, PHPT is not inherited in many cases, while HPT-JT syndrome is inherited in an autosomal dominant manner. Thus, if a patient is diagnosed with HPT-JT syndrome, follow-up genetic testing of the patient's family members is needed in order to rule out the same disease. In the present case, genetic testing was extended to other family members after they gave their consent, and revealed that the mother and brother were carriers of HPT-JT syndrome. They did not have PHPT, but the mother had uterine and ovarian tumors. Regular checks are needed in order to identify the development of hypercalcemia or complications associated with HPT-JT. As described above, the treatment for the HPT-JT syndrome differs from the treatment for PHPT with regard to interventions (including surgical procedures), examinations for complications, and the follow-up of family members. Thus, it is important to avoid misdiagnosing HPT-JT syndrome as PHPT. Since both HPT-JT syndrome and PHPT are associated with hypercalcemia, hypophosphatemia, and high PTH levels, it is difficult to differentiate HPT-JT syndrome from PHPT based on laboratory test results alone. If genetic testing cannot be performed in patients with HPT-JT syndrome, the removal of one parathyroid gland is performed, which may lead to the development of a recurrent lesion for which surgery is difficult to perform. In addition, complications including renal and uterine diseases may be missed due to the absence of detailed examinations. A misdiagnosis may also mean that the regular follow-up of the patient for recurrent parathyroid adenoma, and the presence or absence of complications, as well as the detailed examination of the family members, are not performed in the future.

In clinical practice, it is important to identify the forms of PHPT for which genetic testing should be performed. First, focus should be placed on the age at the onset of disease when considering the use of genetic testing because HPT-JT syndrome commonly occurs in patients of <30 years of age, while PHPT typically occurs in much older patients (40-75 years of age). Even in patients with the nonfamilial forms of PHPT, mutations in the genes causing MEN1, MEN2, or HPT-JT syndrome were reportedly identified in 23.5% of patients of ≤ 45 years of age (9). Thus, HPT-JT syndrome should always be included in the differential diagnosis of patients with early-onset PHPT. Second, when a patient has other family members who are afflicted with PHPT, genetic testing should be performed to confirm the provisional diagnosis of familial hyperparathyroidism. Third, parathyroid carcinoma is rare, accounting for 1% of all parathyroid adenoma cases (10); however, 15% of patients with HPT-JT

syndrome have parathyroid carcinoma. Thus, HPT-JT syndrome should be suspected in patients with parathyroid carcinoma. Lastly, the presence of complications specific to HPT-JT syndrome should prompt genetic testing.

Genetic testing is currently the only method used for obtaining a definitive diagnosis of HPT-JT syndrome. Thus, it is important to perform genetic testing to establish a diagnosis and provide adequate treatment and follow-up for patients of <30 years of age with early-onset PHPT, patients with familial PHPT, patients with parathyroid carcinoma, and patients with complications that are characteristically associated with HPT-JT syndrome.

The authors state that they have no Conflict of Interest (COI).

References

1. Yu N, Donnan PT, Murphy MJ, Leese GP. Epidemiology of primary hyperparathyroidism in Tayside, Scotland, UK. *Clin Endocrinol (Oxf)* **71**: 485-493, 2009.
2. Uchino S, Matsumoto K, Ito A, et al. Familial hyperparathyroidism except for MEN. *J Jpn Assoc Endocr Surg Jpn Soc Thyroid Surg* **32**: 179-183, 2015 (in Japanese).
3. Mizusawa N, Uchino S, Iwata T, et al. Genetic analyses in patients with familial isolated hyperparathyroidism and hyperparathyroidism-jaw tumor syndrome. *Clin Endocrinol (Oxf)* **65**: 9-16, 2006.
4. Haven CJ, Wong FK, van Dam EW, et al. A genotypic and histopathological study of a large Dutch kindred with hyperparathyroidism-jaw tumor syndrome. *J Clin Endocrinol Metab* **85**: 1449-1454, 2000.
5. Carpten JD, Robbins CM, Villablanca A, et al. *HRPT2*, encoding parafibromin, is mutated in hyperparathyroidism-jaw tumor syndrome. *Nat Genet* **32**: 676-680, 2002.
6. Newey PJ, Bowl MR, Cranston T, Thakker RV. Cell division cycle protein 73 homolog (*CDC73*) mutations in the hyperparathyroidism-jaw tumor syndrome (HPT-JT) and parathyroid tumors. *Hum Mutat* **31**: 295-307, 2010.
7. Mehta A, Patel D, Rosenberg A, et al. Hyperparathyroidism-jaw tumor syndrome: Results of operative management. *Surgery* **156**: 1315-1324, 2014.
8. Shibata Y, Yamazaki M, Takei M, Uchino S, Sakurai A, Komatsu M. Early-onset, severe, and recurrent primary hyperparathyroidism associated with a novel *CDC73* mutation. *Endocr J* **62**: 627-632, 2015.
9. Starker LF, Akerström T, Long WD, et al. Frequent germ-line mutations of the *MEN1*, *CASR*, and *HRPT2/CDC73* genes in young patients with clinically non-familial primary hyperparathyroidism. *Horm Cancer* **3**: 44-51, 2012.
10. Shane E. Parathyroid carcinoma. *J Clin Endocrinol Metab* **86**: 485-493, 2001.

The Internal Medicine is an Open Access article distributed under the Creative Commons Attribution-NonCommercial-NoDerivatives 4.0 International License. To view the details of this license, please visit (<https://creativecommons.org/licenses/by-nc-nd/4.0/>).