

# Epicardial access and ventricular tachycardia ablation in a postmyocarditis patient using a nonfluoroscopic catheter visualization system



Akiko Ueda, MD,\* Mika Nagaoka, MD,<sup>†</sup> Kyoko Soejima, MD,<sup>†</sup> Yosuke Miwa, MD,<sup>†</sup> Noriko Matsushita, MD<sup>†</sup>

From the \*Division of Advanced Arrhythmia Management, Kyorin University Hospital, Tokyo, Japan, and <sup>†</sup>Department of Cardiology, Kyorin University Hospital, Tokyo, Japan.

## Introduction

The efficacy of catheter ablation for scar-related ventricular tachycardia (VT) has significantly improved since the introduction of percutaneous epicardial access by Sosa in 1996.<sup>1</sup> Percutaneous epicardial ablation has been used in approximately 30% of VT ablation cases associated with nonischemic cardiomyopathy.<sup>2</sup> However, complications such as cardiac tamponade, coronary artery laceration, or occlusion develop in approximately 4% of the procedures. Epicardial puncture and ablation are indicated after coronary angiogram (CAG) so as to avoid damage to the coronary arteries. Prior to the ablation, a CAG must be repeated, and fluoroscopy is often used during the puncture while the operator's hands are in the field. As a result, these procedures increase fluoroscopy time and radiation exposure for both the patient and the operator.

MediGuide (St. Jude Medical [SJM], St. Paul, MN) is a sensor-based, electromagnetic, nonfluoroscopic catheter visualization system. The system tracks dedicated sensor-embedded catheters and guidewires directly on fluoroscopy or cine-loop images acquired at the beginning of the ablation procedure.<sup>3</sup> To reduce radiation exposure during the access and mapping, the MediGuide system has been used for epicardial access and ablation in our institution. In this report, we present a patient with postmyocarditis scar-related VT who underwent an ablation procedure using this technology.

## Case report

A 55-year-old female patient with an implantable cardioverter-defibrillator for postmyocarditis scar-related VT developed an electrical storm 16 months after its implantation. After written informed consent was obtained, an electrophysiologic study was performed. Three-dimensional electroanatomic mapping (NavX

Velocity, SJM) of the left ventricle (LV) showed normal bipolar (>1.0 mV) and unipolar (>8.3 mV) endocardial voltage with no abnormal potentials. A preoperative magnetic resonance image demonstrated late gadolinium enhancement at the epicardial LV basal area, which prompted an attempt at epicardial mapping. Prior to the epicardial puncture, left and right CAG was performed, and the images were stored to the MediGuide system. A MediGuide-enabled guidewire (CPS Excel Extra Firm, 0.014 inch, SJM) equipped with a magnetic sensor at the distal end was inserted through the Y port and placed at the tip of the 17 gauge epidural needle (Figure 1A) to allow tracking on the screen without using live fluoroscopy (Figure 1B-E, Supplementary Movie, available online). The coronary arteries and the implantable cardioverter-defibrillator lead in the right ventricle apex were simultaneously visualized on the MediGuide monitor as the tip of the needle (displayed with a white marker) was safely advanced with minimum use of live radiographs. A small amount of contrast agent was injected to confirm that the needle had entered the pericardial space, and then the wire was successfully advanced into the epicardial space without use of live radiographs. The guidewire was then exchanged with 0.35 mm spring wire, and a 9F long sheath was inserted into the epicardial space. Epicardial mapping was subsequently carried out using a MediGuide-enabled decapolar catheter (Livewire, SJM) and an open-irrigated ablation catheter (Safire Duo, SJM). Low-voltage areas were detected in the LV basolateral to the inferior wall, and multiple isolated delayed potentials (iDPs) were distributed in the low-voltage area (Figure 2A). iDPs are defined as electrogram events that occur after the QRS complex and are separated by an isoelectric interval of more than or equal to 40 ms.<sup>4</sup> Pace mapping was performed at sites where iDPs were observed. Good pace match sites were distributed in a linear manner, with long stimulus-QRS (s-QRS) intervals at the sites of late iDP and short s-QRS intervals at sites of short iDP (Figure 2B). Radiofrequency (RF) ablation targeting sites with good pace match and/or iDP was started from the border area. It was noted that RF

**KEYWORDS** Epicardial ablation; Postmyocarditis; Ventricular tachycardia; Nonfluoroscopic catheter visualization system; Isolated delayed potential (Heart Rhythm Case Reports 2017;3:411–414)

Akiko Ueda has endowments from St. Jude Medical. **Address reprint requests and correspondence:** Dr Kyoko Soejima, Department of Cardiology, Kyorin University Hospital, 6-20-2 Shinkawa Mitaka City, Tokyo 181-0004, Japan. E-mail address: [skyoko@ks.kyorin-u.ac.jp](mailto:skyoko@ks.kyorin-u.ac.jp).

## KEY TEACHING POINTS

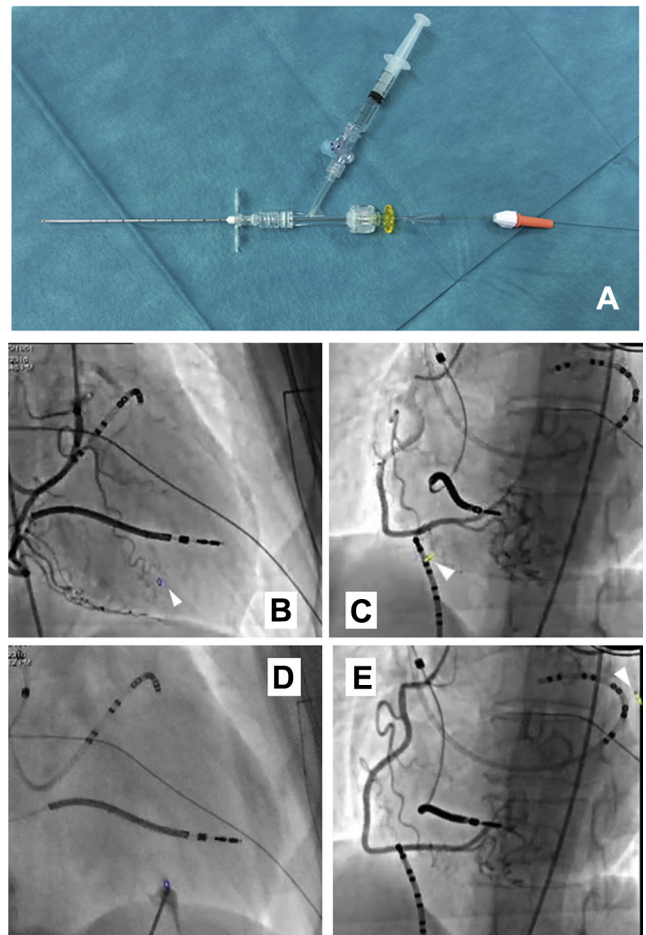
- The MediGuide system allows minimum fluoroscopy subxiphoid epicardial puncture with the guidance of preacquired CAG images.
- The MediGuide system enables simultaneous visualization of the ablation catheter and coronary angiography, yielding safe radiofrequency energy applications.
- Epicardial catheter ablation targeting isolated delayed potentials (iDPs) in postmyocarditis scar-related VT is feasible. Earlier iDP ablation could modify the VT conducting channel without ablating all iDPs.

ablation at the earlier iDPs sometimes resulted in prolongation, elimination, or dissociation of iDPs at nearby or remote areas (Figure 3A). During epicardial RF application, cine loops of the CAG were used as background images for the catheter tracking to maintain sufficient distance between the distal tip of the ablation catheter and the left circumferential artery. Epicardial mapping after the ablation demonstrated a significant reduction in the number of sites with iDP (Figure 3B), and no VT was inducible at the end of the procedure. After the ablation, a CAG was repeated and showed no coronary damage. The fluoroscopy duration and radiation dose were as follows: 1.6 minutes and 3 mGy for the epicardial access procedure; 8.7 minutes and 7 mGy for endocardial catheter placement, mapping, and ablation; 6.1 minutes and 40 mGy for CAG and drainage for irrigation saline using a pigtail catheter. The total duration and dose were 16.4 minutes and 50 mGy.

## Discussion

### Epicardial puncture and ablation using MediGuide technology

This is the first report of scar-related VT ablation using the MediGuide system for epicardial puncture, mapping, and ablation. Subxiphoid puncture was successfully performed with minimum fluoroscopy by utilizing a sensor-equipped guidewire with the guidance of acquired CAG images. In addition, a CAG image loop on the system helped to ensure safe RF application without using live radiographs. This allowed for a short fluoroscopy duration and low radiation exposure. Simultaneous visualization of catheter/needle and images of coronary arteries seems to be safer as compared to conventional side-by-side cine images. Mansour and colleagues<sup>5</sup> reported feasibility of a similar technique using a MediGuide-enabled guidewire for transseptal puncture. Although additional experience and improvements in equipment are needed before wider use, this technology appears



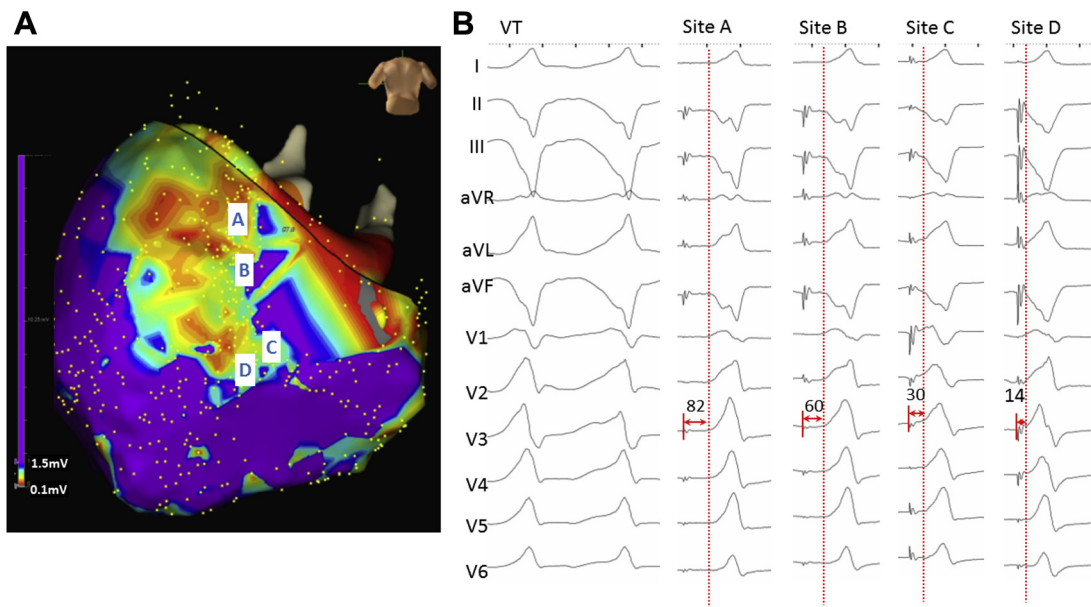
**Figure 1** Puncture system and images of MediGuide demonstrating epicardial puncture. **A:** A Y connector is attached to the epidural needle for the guidewire insertion and contrast agent injection. **B, C:** Coronary angiography images obtained with right (**B**) and left (**C**) anterior oblique are stored as background images for the MediGuide system. An end of the MediGuide-enabled guidewire set at the tip of the epidural needle is depicted in yellow and indicated with a white arrowhead. The needle was safely advanced without the use of live radiographs. **D:** A small amount of contrast agent was injected when the needle was advanced to the pericardium (live image). **E:** The wire was successfully advanced to the epicardial space without the use of live radiographs.

promising for maintaining safety and reducing radiation exposure.

### DP ablation for postmyocarditis VT

The efficacy of ablation targeting delayed potentials (DPs) has been previously reported. Arenal and colleagues<sup>6</sup> first demonstrated the benefit of VT-related late potential (LP) ablation in 2003. Recently, the efficacy of a more extensive approach eliminating all LPs, regardless of clinical VT, has been reported in ischemic, nonischemic, and arrhythmogenic right ventricular cardiomyopathy.<sup>4,7,8</sup> Similarly, Jaïs and colleagues<sup>9</sup> demonstrated substrate-based VT ablation targeting all local abnormal ventricular activity.

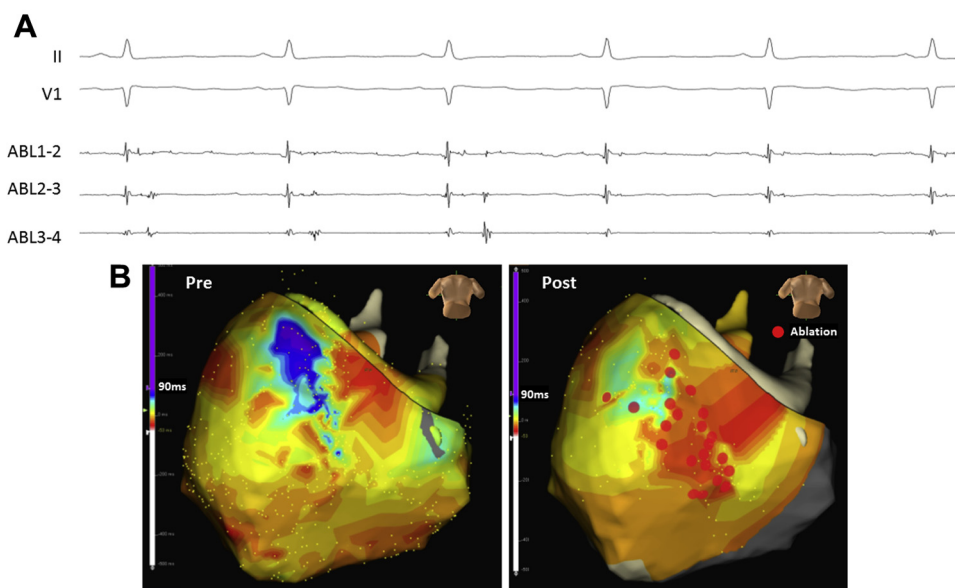
There has been a limited number of reports pertaining to postmyocarditis VT. Berte and colleagues<sup>10</sup> reported a series of postmyocarditis VT patients with epicardial-only scar.



**Figure 2** Epicardial voltage map and pace map. **A:** The epicardial voltage map (posteroanterior caudal view) during sinus rhythm demonstrates low-voltage area at the basolateral to inferior wall. Pace mapping was performed at sites A, B, C, and D. **B:** Surface electrograms of the target ventricular tachycardia (VT) and pace map at sites A to D corresponding to those in Figure 2A are shown. Note that the stimulus-QRS interval is longer at sites deep within the low-voltage area and gradually shortened toward the border area.

Epicardial local abnormal ventricular activity sites without endocardial scar were eliminated by epicardial ablation.<sup>10</sup> In the present case, endocardial electrograms were well preserved, and iDPs were recorded at limited low-voltage areas on the epicardium. This observation was consistent with the aforementioned study. It appeared that linearly distributed DPs with good pace match and sequential s-QRS intervals indicated a relation-

ship between the DPs and the clinical VT isthmus. Although entrainment could not be performed because of hemodynamic instability, sites with long s-QRS intervals seemed to be in the vicinity of the proximal or central isthmus, and sites with short s-QRS intervals seemed to be close to the VT exit. Because of the proximity of the left circumferential artery, RF was unable to be applied to the later iDPs deeper in the low-



**Figure 3** Elimination of delayed potentials and activation mapping pre- and postablation. **A:** A surface electrogram of leads II and V1, along with the intracardiac electrogram of the ablation catheter during radiofrequency (RF) energy application, are shown. The delayed potential is gradually prolonged (third beat) and finally eliminated (fourth beat) during RF delivery. **B:** A late potential map, which displays the latest activation of the electrogram during the sinus rhythm, is shown (left panel: preablation, right panel: postablation). The end of the QRS complex is used as a timing reference. Red and purple colors indicate early and late timing, respectively. Potentials with the latest timing were distributed in the low-voltage areas (see Figure 2A). Note that highly delayed potentials seen in the left map are no longer recorded after ablation at the border of the scar. RF energy was not applied to the latest area because of the proximity to the coronary artery. The ablation sites are indicated by red circles.

voltage areas. However, RF applications to iDPs at the border successfully eliminated later iDPs, suggesting an interconnection of earlier and later iDPs in the VT channel.<sup>11</sup> It is considered that ablation of the earlier iDPs modified the conduction properties of the VT channel, resulting in elimination of the VT.

## Conclusions

Epicardial catheter ablation targeting iDPs in a patient with postmyocarditis scar-related VT was successfully performed. MediGuide-guided subxiphoid puncture and epicardial mapping and ablation were demonstrated to be feasible with short fluoroscopy duration and low radiation exposure.

## Appendix

### Supplementary Data

Supplementary data associated with this article can be found in the online version at <http://dx.doi.org/10.1016/j.hrcre.2017.05.003>.

## References

1. Sosa E, Scanavacca M, d'Avila A, Pilleggi F. A new technique to perform epicardial mapping in the electrophysiology laboratory. *J Cardiovasc Electrophysiol* 1996;7:531–536.
2. Muser D, Santangeli P, Castro SA, et al. Long-term outcome after catheter ablation of ventricular tachycardia in patients with nonischemic dilated cardiomyopathy. *Circ Arrhythmia Electrophysiol* [Internet] 2016;9:e004328.
3. Piorowski C, Hindricks G. Nonfluoroscopic sensor-guided navigation of intracardiac electrophysiology catheters within prerecorded cine loops. *Circ Arrhythmia Electrophysiol* 2011;4:36–39.
4. Nogami A, Sugiyasu A, Tada H, Kurosaki K, Sakamaki M, Kowase S, Oginosawa Y, Kubota S, Usui T, Naito S. Changes in the isolated delayed component as an endpoint of catheter ablation in arrhythmogenic right ventricular cardiomyopathy: predictor for long-term success. *J Cardiovasc Electrophysiol* 2008;19:681–688.
5. Mansour M, Afzal MR, Gunda S, Pillarisetti J, Heist K, Acha MR, Heard M, Ruskin J, Lakkireddy D. Feasibility of transeptal puncture using a nonfluoroscopic catheter tracking system. *Pacing Clin Electrophysiol* 2015;38:791–796.
6. Arenal A, Glez-Torrecilla E, Ortiz M, Villacastán J, Fdez-Portales J, Sousa E, Del Castillo S, Perez de Isla L, Jimenez J, Almendral J. Ablation of electrograms with an isolated, delayed component as treatment of unmappable monomorphic ventricular tachycardias in patients with structural heart disease. *J Am Coll Cardiol* 2003;41:81–92.
7. Vergara P, Trevisi N, Ricco A, Petracca F, Baratto F, Cireddu M, Bisceglia C, Maccabelli G, Della Bella P. Late potentials abolition as an additional technique for reduction of arrhythmia recurrence in scar related ventricular tachycardia ablation. *J Cardiovasc Electrophysiol* 2012;23:621–627.
8. Arenal Á, Hernández J, Calvo D, et al. Safety, long-term results, and predictors of recurrence after complete endocardial ventricular tachycardia substrate ablation in patients with previous myocardial infarction. *Am J Cardiol* 2013;111:499–505.
9. Jaïs P, Maury P, Khairy P, et al. Elimination of local abnormal ventricular activities: a new end point for substrate modification in patients with scar-related ventricular tachycardia. *Circulation* 2012;125:2184–2196.
10. Berte B, Sacher F, Cochet H, Mahida S, Yamashita S, Lim H, Denis A, Derval N, Hocini M, Haïssaguerre M, Jaïs P. Postmyocarditis ventricular tachycardia in patients with epicardial-only scar: a specific entity requiring a specific approach. *J Cardiovasc Electrophysiol* 2015;26:42–50.
11. Tung R, Mathuria NS, Nagel R, Mandapati R, Buch EF, Bradfield JS, Vaseghi M, Boyle NG, Shivkumar K. Impact of local ablation on interconnected channels within ventricular scar mechanistic implications for substrate modification. *Circ Arrhythm Electrophysiol* 2013;6:1131–1138.