

## Letter to the Editor

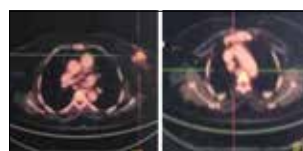
### Myoepithelial carcinoma of the breast: Case report of a rare entity and its response to chemotherapy

DOI: 10.4103/sajc.sajc\_75\_17

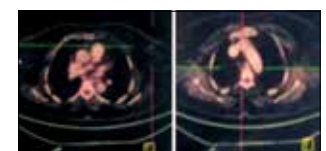Dear Editor,

Myoepithelial carcinoma refers to lesions consisting almost exclusively of tumor cells that exhibit a dual epithelial and smooth muscle differentiation.<sup>[1]</sup> These tumors arise commonly in salivary glands and very rarely in skin, soft tissue, retroperitoneum, breast, vulva, stomach, and lung.<sup>[2-7]</sup> Myoepithelial carcinoma of the breast is extremely rare, and <40 case reports have been published in English literature. Most of the reports lay emphasis on diagnosis and pathology and very few mention of the chemotherapy regimen used and its response.<sup>[8-10]</sup> Herein, we present a case of metastatic myoepithelial carcinoma of breast with differential responses to two different chemotherapy regimens.

A 57-year-old female presented with lump in her left breast for 4 months. She had undergone lumpectomy at her native place. Histopathology was reported as infiltrating carcinoma with basaloid appearance, showing focal squamous differentiation within basaloid nests along with marked myxoid stroma. Cut margins were positive. On immunohistochemistry, tumor cells expressed p63 and were negative for S100, calponin,



**Figure 1: Positron emission tomography-computed tomography image at baseline before start of therapy demonstrating lesion in left breast and right paratracheal lymph node**



**Figure 2: Positron emission tomography-computed tomography image post six cycles of paclitaxel and carboplatin chemotherapy showing near-complete metabolic resolution at left breast and complete metabolic resolution at right paratracheal lymph node**

smooth muscle actin (SMA), and CD10. C-Kit was weakly expressed. The tumor was negative for estrogen receptor (ER), partial response (PR), and Her2/neu expression. Final report was myoepithelial carcinoma of breast, intermediate grade. Three-week postsurgery, she had noticed a new lump in her breast adjacent to previous incision. Positron emission tomography-computed tomography (PET-CT) scan [Figure 1] showed multiple ill-defined nodular masses in left breast parenchyma, largest nodule measured 2.1 cm × 2 cm. A 1.6 cm × 1.5 cm heterogeneously enhancing fluorodeoxyglucose (FDG) avid right paratracheal node was seen. Also noted was complete collapse of D1 vertebral body with FDG avid lytic areas in bilateral pedicles and left transverse process.

She presented to our hospital with these reports and complaint of recent onset upper back ache. Palliative radiotherapy to C7–D2 vertebra was given. She received chemotherapy with paclitaxel 175 mg/m<sup>2</sup> and carboplatin area under the curve 5 every 3 weeks along with zoledronate. After three cycles, she had 50% reduction in size of breast lump and 70% reduction in back pain. Post six cycles, no mass was palpable in breast. She tolerated chemotherapy well. Repeat PET-CT scan done post six cycles of chemotherapy [Figure 2] revealed near-complete metabolic resolution of breast lesions and complete metabolic resolution of right paratracheal lymph node. There was sclerosis in bilateral pedicles and left transverse process of D1 vertebra. Thus, there was PR at primary and nodal sites as per RECIST criteria.

Since the patient had residual disease postcompletion of standard therapy, she was started on oral metronomic maintenance therapy along with continuation of monthly zoledronate. After 4 months of this therapy, she again noticed a lump in her left breast. CT scan showed multiple lesions in left breast parenchyma (maximum size 4.2 cm × 6.6 cm × 5.5 cm) and right paratracheal nodes. The patient was not keen

on palliative mastectomy, and hence, she was planned for palliative chemotherapy with doxorubicin (60 mg/m<sup>2</sup>) and cyclophosphamide (600 mg/m<sup>2</sup>) (AC) every 21 days. Post two cycles of chemotherapy, she had progression of disease. She also developed weakness in her left lower limb with decreased sensations and urinary retention. CT scan revealed breast lesions, T1 and T2 vertebral collapse, T9 lytic lesion with soft tissue component, and paratracheal nodes. She received palliative radiotherapy to T9–T11 spine. In view of good response in the past, she was restarted on paclitaxel and carboplatin. However, she developed Grade IV oral mucositis, febrile neutropenia, and thrombocytopenia after first cycle itself. On recovery, she was not keen for further therapy and expired 2 months later (20 months after initial diagnosis).

The WHO classification of breast tumors (4<sup>th</sup> edition) has included myoepithelial carcinoma under category of “metaplastic carcinoma of no special type.”<sup>[11]</sup> Myoepithelial carcinoma of breast is an extremely rare tumor. It is seen in women aged 25–81 years (mean, 54 years).<sup>[9,10]</sup> Commonly used myoepithelial

markers such as S100, high molecular weight cytokeratins, calponin, and SMA are neither highly sensitive or specific myoepithelial markers and were negative even in our case. The tumor expressed p63 which has been found to be highly sensitive and specific myoepithelial cell marker.<sup>[7,12,13]</sup> The tumor was negative for ER, PR, and Her2/neu as has been reported.<sup>[11]</sup> Myoepithelial cancer is treated by surgery (wide local excision/mastectomy with regional lymph node excision) and radiotherapy to prevent recurrence.<sup>[9,10]</sup> The role of chemotherapy and choice of agents has not been defined for this entity. To the best of our knowledge, we could come across only three case reports of myoepithelial cancer who had response to chemotherapy, among which two had site of primary in breast and one in vulva: a 52-year-old female with metastatic breast cancer (MBC) who had PR to paclitaxel and carboplatin;<sup>[8]</sup> a 61-year-old female with MBC who had stable disease post three cycles of paclitaxel and carboplatin,<sup>[10]</sup> and a 37-year-old female with metastatic carcinoma vulva who had complete response to the same chemotherapy regimen.<sup>[3]</sup> One case report had shown

progressive disease following neoadjuvant TAC (docetaxel, doxorubicin, cyclophosphamide) chemotherapy.<sup>[9]</sup> Our patient had PR to paclitaxel and carboplatin chemotherapy but had no response to AC chemotherapy.

We suggest multimodality treatment for this aggressive disease. The chemotherapy regimen should include platinum analogs and paclitaxel since only this regimen has been reported to have some efficacy in myoepithelial carcinoma. Since this tumor is hormone receptor negative, it may warrant treatment on the lines of triple negative breast cancer.

#### **Declaration of patient consent**

The authors certify that they have obtained all appropriate patient consent forms. In the form the patient(s) has/have given his/her/their consent for his/her/their images and other clinical information to be reported in the journal. The patients understand that their names and initials will not be published and due efforts will be made to conceal their identity, but anonymity cannot be guaranteed.

#### **Financial support and sponsorship**

Nil.

## Conflicts of interest

There are no conflicts of interest.

**Sanyo P. Dsouza, Ajit Kulkarni<sup>1</sup>, Nandini Sharma<sup>1</sup>,  
S. D. Banavali**

Department of Medical Oncology, TMH, Mumbai,

<sup>1</sup>Department of Radiation Oncology, B K L Walawalkar Hospital,  
Ratnagiri, Maharashtra, India

**Correspondence to:** Dr. S. D. Banavali,  
E-mail: banavali\_2000@yahoo.com

## References

1. Barnes L, Eveson JW, Reichart P, Sidransky D. World Health Organization Classification of Tumors. Pathology and Genetics of Head and Neck Tumors. Lyon: IARC Press; 2005.
2. Jo VY. Myoepithelial tumors: An update. *Surg Pathol Clin* 2015;8:445-66.
3. Noronha V, Cooper DL, Higgins SA, Murren JR, Kluger HM. Metastatic myoepithelial carcinoma of the vulva treated with carboplatin and paclitaxel. *Lancet Oncol* 2006;7:270-1.
4. Higashiyama M, Kodama K, Yokouchi H, Takami K, Kabuto T, Tsuji N, *et al.* Myoepithelioma of the lung: Report of two cases and review of the literature. *Lung Cancer* 1998;20:47-56.
5. Jung JH, Im S, Kang SJ, Kim GM, Han KT, Yoo J, *et al.* A cutaneous myoepithelial carcinoma arising in a papillary eccrine adenoma. *Korean J Pathol* 2011;45:644-9.
6. Tseng CE, Hsieh YH, Wei CK, Huang HY, Chi CL. Myoepithelial carcinoma of the stomach: A diagnostic pitfall. *World J Gastroenterol* 2015;21:4391-6.
7. Hornick JL, Fletcher CD. Myoepithelial tumors of soft tissue: A clinicopathologic and immunohistochemical study of 101 cases with evaluation of prognostic parameters. *Am J Surg Pathol* 2003;27:1183-96.
8. Tran PN, Zhuang L, Nangia CI, Mehta RS. Dramatic response to carboplatin, paclitaxel, and radiation in a patient with malignant myoepithelioma of the breast. *Oncologist* 2016;21:1492-4.
9. Papazian M, Kalantzis I, Galanopoulos G, Mani I, Tzaida O, Iacovidou I, *et al.* Malignant myoepithelioma of the breast: A case report and review of the literature. *Mol Clin Oncol* 2016;4:723-7.
10. Endo Y, Sugiura H, Yamashita H, Takahashi S, Yoshimoto N, Iwasa M, *et al.* Myoepithelial carcinoma of the breast treated with surgery and chemotherapy. *Case Rep Oncol Med* 2013;2013:164761.
11. Lakhani SR, Ellis IO, Schnitt SJ, Tan PH, van de Vijver MJ, editors. WHO Classification of Tumours of the Breast. Lyon, France: IARC Press; 2012. p. 120-3.
12. Pavlakis K, Zoubouli C, Liakakos T, Messini I, Keramopoulos A, Athanassiadou S, *et al.* Myoepithelial cell cocktail (p63+SMA) for the evaluation of sclerosing breast lesions. *Breast* 2006;15:705-12.
13. Barbareschi M, Pecciarini L, Cangi MG, Macrì E, Rizzo A, Viale G, *et al.* P63, a p53 homologue, is a selective nuclear marker of myoepithelial cells of the human breast. *Am J Surg Pathol* 2001;25:1054-60.

This is an open access article distributed under the terms of the Creative Commons Attribution-NonCommercial-ShareAlike 3.0 License, which allows others to remix, tweak, and build upon the work non-commercially, as long as the author is credited and the new creations are licensed under the identical terms.

**How to cite this article:** Dsouza SP, Kulkarni A, Sharma N, Banavali SD. Myoepithelial carcinoma of the breast: Case report of a rare entity and its response to chemotherapy. *South Asian J Cancer* 2017;6:185.  
© 2017 The South Asian Journal of Cancer | Published by Wolters Kluwer - Medknow