

Review Article: Collaboration with Journal of Korean Medical Association

## Recent Advance in the Surgical Treatment of Metastatic Colorectal Cancer-An English Version

Eun Jung Park and Seung Hyuk Baik

*Division of Colon and Rectal Surgery, Department of Surgery, Gangnam Severance Hospital,  
Yonsei University College of Medicine, Seoul, Korea*

### Abstract

Stage IV colorectal cancer (CRC) has heterogeneous characteristics in tumor extent and biology. The overall survival of patients with metastatic CRC has improved with the development of multimodal treatments and new chemotherapeutic drugs. Resection of metastatic CRC is performed for liver, lung, or peritoneal metastases. Conversion surgeries to resect oligometastatic lesions have been developed with tumor regression using chemotherapeutic agents. Two-stage hepatectomy has extended the surgical indications for patients with metastatic CRC. Synchronous liver and primary tumor resection can be considered in patients with adequate conditions. Local ablation with radiotherapy can be used to treat lung metastasis. In the treatment of patients with CRC with peritoneal metastasis, cytoreductive surgery with hyperthermic intraperitoneal chemotherapy can be considered. Surgical treatments should be performed in patients with symptomatic primary tumors with unresectable metastasis. However, primary tumor resection in patients with asymptomatic CRC with synchronous, unresectable metastases did not show overall survival benefits in recent studies. Therefore, the treatment of metastatic CRC is challenging due to the variable tumor extent and heterogeneous characteristics. Tailored surgical treatments and multidisciplinary approaches may improve survival and the quality of life in patients with metastatic CRC.

### Keywords

colorectal cancer, surgery, peritoneal metastasis, metastasis, chemotherapy

J Anus Rectum Colon 2022; 6(4): 213-220

### Introduction

Colorectal cancer (CRC) is the third most common cancer type and the second cause of cancer-related mortality in the analysis of global cancer statistics[1]. The overall survival of patients with CRC has improved with the development of multimodal treatments and new chemotherapeutic drugs[2-4]. In an analysis of the Surveillance, Epidemiology, and End Results (SEER) database from 2010 to 2019, age-adjusted rates for new CRC declined by 1.8% annually, whereas the 5-year survival rate showed a gradual increase[5]. This may be attributed to early detection of CRC

using colonoscopy, advanced radiologic tools, improvement of surgical techniques based on anatomical dissection, and the development of modern chemotherapeutic agents. However, 20% of patients have synchronous metastatic lesions when they are diagnosed initially. In addition, 50%-60% of patients with CRC are diagnosed with metachronous metastases[6]. Among patients with metastatic CRC (mCRC), 80% of them are unresectable[7].

mCRC is defined as a tumor that has spread to distant sites, except in the primary CRC. In the comparison of CRC stages I-III, mCRC has a poor prognosis. According to an analysis of 14 randomized clinical trials from 1997 to 2008,

Corresponding author: Seung Hyuk Baik, whitenoja@yuhs.ac

Received: August 21, 2022, Accepted: September 4, 2022

Copyright © 2022 The Japan Society of Coloproctology

the median overall survival in patients with CRC with liver metastasis was 19.1 months; lung metastasis, 24.6 months; and peritoneal metastasis, 16.3 months[8]. It is reported that increased numbers of metastatic lesions and peritoneal involvements are associated with a poor prognosis of survival. In addition, tumor subtypes based on microsatellite instability and genetic alterations in *KRAS*, *NRAS*, or *BRAF* are crucial in understanding the biologic features of primary cancer and metastatic lesions[9]. With the development of molecular targeted agents and surgical techniques, multimodal treatments of mCRC have been advanced to improve survival and increase the efficacy of treatment[10]. In the current study, we aimed to demonstrate the recent treatment strategies for mCRC in the aspects of surgery.

### **Surgical Management of Resectable mCRC**

Resection of mCRC is recommended when the metastatic lesions are technically present for complete removal. Before determining the resection of metastatic sites, the resectability and usefulness of locoregional surgical treatment for mCRC should be fully assessed with consideration of the radiologic evaluation and the patient's condition. In addition, clear surgical margins and technical assurance for complete resection of metastatic sites should be ensured before the surgery.

#### ***Liver metastasis in mCRC***

Liver metastasis is the most common metastasis in patients with mCRC. It is known that 25% of patients with CRC are diagnosed with liver metastases at the initial diagnosis and 50%-70% of patients are diagnosed with metachronous liver metastasis after resection of primary cancer[11,12]. In the treatment of patients with CRC with liver metastasis, liver resection with or without local ablation therapy can be used for curative treatment[13]. The EORTC CLOCC trial resulted in a longer progression-free survival for the radiofrequency ablation plus chemotherapy group than for the group that underwent systemic treatment[14]. In addition, liver resection for patients with mCRC with liver metastases showed improved long-term survival with the use of chemotherapy and perioperative imaging[15]. In a meta-analysis for mCRC, the overall survival after liver resection of patients with mCRC was 3.6 years, and the median 5-year survival was 38%[16]. To achieve successful outcomes, resectability and identification of metastatic liver lesions are crucial points in determining surgical treatment strategies[17]. Therefore, preoperative examinations are required to assess remnant liver volume and function. Computed tomography (CT) volumetry and liver magnetic resonance imaging are used to measure future liver remnant (FLR) volume after hepatectomy. It is known that FLR should be more than 25%-40% with sufficient blood flow to prevent post-hepatectomy liver failure[18]. However, liver function

and liver volume need to be considered because preoperative chemotherapy can deteriorate liver function. Indocyanine green clearance and the Child-Pugh score are used as methods to assess liver function. Resectability of the liver requires that the neo-remnant liver ensures sufficient hepatic arterial or portal inflow and preserves the hepatic venous flow with proper biliary drainage[19]. Previously, the number of metastatic lesions, maximal tumor size, distribution of liver lobes, tumor histologic differentiation, and the presence of extrahepatic diseases were considered as main factors to determine hepatectomy[20]. However, with the development of surgical treatments and chemotherapy, the definition of hepatectomy has been extended. Thus, multidisciplinary approaches with team discussions to decide the surgical treatment plans in patients with mCRC with liver metastases are required.

With the development of liver function assessment and surgical techniques in 2000, two-stage hepatectomy using portal vein embolization extended the range of possible surgical resection. Portal vein embolization can be combined with CRC surgery to ensure tumor regression and liver hypertrophy in patients with mCRC with bilobar liver metastases who have insufficient FLR. Thereafter, a staged hepatectomy has to be performed for the removal of metastatic lesions. The two-stage hepatectomy would allow the modulation of FLR and complete resection of multilobar liver metastases. In 2007, associating liver partition and portal vein ligation for staged hepatectomy (ALPPS) was developed to overcome the limitation of liver resection in patients with mCRC with a small FLR and multiple liver metastases. Although ALPPS has the advantage of increasing FLR volume in a short period, higher rates of postoperative complications after ALPPS were reported compared with two-stage hepatectomy. However, a randomized controlled trial (LIGRO) that compared oncologic outcomes between ALPPS and two-stage hepatectomy showed no significant difference between the two in postoperative morbidities and mortalities[21]. In addition, ALPPS showed improved survival in patients with CRC with liver metastasis and a standardized FLR of less than 30% compared with two-stage hepatectomy[22]. Therefore, appropriate patient selection and surgical techniques can ensure the performance of surgical treatments and improve survival in patients with CRC with multiple liver metastases.

It is known that 20% of patients who are diagnosed with mCRC have synchronous liver metastasis[23]. Synchronous liver metastases are defined as the presence of liver metastatic lesions at the time of diagnosis of primary CRC. The bowel-first surgery was performed classically while using palliative chemotherapy. Patients in a good condition to withstand both colon and liver procedures with high possibilities of R0 complete resection in both fields are considered suitable for simultaneous liver and CRC resection. In

addition, patients require a sufficient liver remnant volume of 25%-40% without extrahepatic disease. When complications in the primary tumors such as obstruction, perforation, and hemorrhage exist, simultaneous liver and CRC resection is avoided. Treatment strategies for CRC with liver metastasis were divided into three groups: a bowel-first approach followed by chemotherapy; a liver-first approach followed by bowel resection plus chemotherapy; and simultaneous liver and CRC resection. Simultaneous liver resection in patients with mCRC includes resection of all liver metastatic lesions and primary cancer in the same operation. Simultaneous liver and CRC resection has the advantage of avoiding two surgeries, shortening the time taken to initiate chemotherapy, and reducing the risk of cancer dissemination at a relatively low cost. However, the surgical time for simultaneous resection is longer, and postoperative surgical stress increases after the combined procedures[24]. In the assessment of postoperative complications, it was noted that the morbidity rate of patients who underwent synchronous liver resection was comparable with that of patients who underwent staged resection. In the analysis of survival, the 5-year overall survival in patients with simultaneous liver and bowel resection was no different when compared to that of bowel-first surgery[25,26]. In the analysis of the National Bowel Cancer Audit dataset, the proportion of performing simultaneous liver and bowel resections has increased gradually. Although the proportion of the classic approach, the bowel-first surgery, was the highest, the rates of simultaneous resection were increased. The analysis of long-term survival using propensity score-matching for simultaneous resections was not different compared with that of bowel-first or liver-first surgeries[25]. In addition, local therapies such as radiofrequency ablation and stereotactic body radiation therapy (SBRT) can be treatment options for resectable liver metastatic lesions[27]. In recent studies, hepatic arterial infusion and transhepatic arterial chemoembolization have been used to treat patients with mCRC with multiple liver metastases[28,29]. As a result, treatment strategies for patients with synchronous liver and CRC should be considered in conjunction with a thorough evaluation of metastatic lesions and primary tumor stages.

### ***Lung metastasis in mCRC***

The lung is the second most common metastatic site in patients with CRC after the liver. It is reported that approximately 5%-10% of patients with CRC tend to develop isolated lung metastases. Pulmonary metastasis in mCRC is caused by hematogenous dissemination of cancer. In the CRC examinations, 20%-30% of patients are detected with indeterminate lesions in CT scans, but malignant lesions among them are reported in 10%-20% of patients[30].

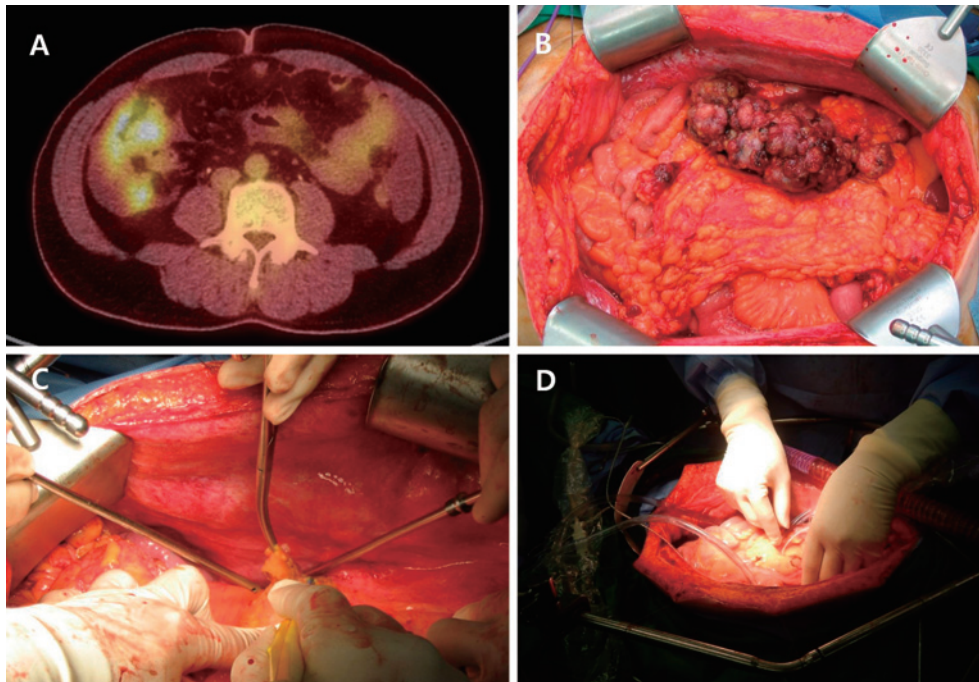
In a systematic review of surgical resection of pulmonary metastases in patients with mCRC, pulmonary metastasec-

tomy showed survival benefits with a 5-year survival rate of more than 50%[31]. In the highly selected patients, the median 5-year survival rate was 52.5%. It is known that prolonged survival after resection of lung metastatic lesions is comparable to improved oncologic outcomes of liver metastasis. Although the role of mediastinal lymphadenectomy in patients with CRC with lung metastasis is unclear, resection of lung metastasis with an adequate resection margin of 0.5-1.0 cm showed improved survival. The distribution of metastatic lesions and lymph node involvement should be considered before surgical resection. In the analysis of a population-based cancer registry, the cumulative risk of metachronous lung metastasis in patients with CRC over 5 years was 5.8%[32]. The 3-year overall survival after curative resection for CRC lung metastasis was 53.0% in patients with synchronous metastases and 59.2% in patients with metachronous metastases. In addition, lung metastasis occurred more frequently in rectal cancer than in colon cancer. Parnaby et al. (33) reported that the incidence of lung metastasis from rectal cancer was 10%-18%, whereas that from colon cancer was 5%-6%.

In the treatment of pulmonary metastasis of CRC, patients should be thoroughly evaluated for adequate indications for surgery. Moreover, the resectability of metastatic lesions and pulmonary reserve function after surgery should be assessed. Solitary pulmonary metastatic lesions can be considered for surgical resection using video-assisted thoracic surgery (VATS) or open thoracotomy metastasectomy. Currently, VATS is commonly used to treat solitary pulmonary metastasis. In a recent meta-analysis that compared open thoracotomy and VATS for pulmonary metastasectomy, no significant difference in overall and recurrence-free survival rates was noted[34]. The 5-year overall survival after a single pulmonary metastasis from CRC was reported to be 32%-62%[30]. In addition, the usefulness of SBRT for the treatment of lung metastasis is emerging. In the analysis of a large multicenter database, SBRT of oligometastatic CRC improved overall survival. In the treatment of 381 oligometastatic CRC lesions in 235 patients with CRC, patients treated with SBRT showed 2-year overall survival of 76.1% and 5-year overall survival of 35.9%, retrospectively[35]. Local therapies such as SBRT can be considered in the treatment of patients with CRC with liver or lung-limited lesions that cannot be resected curatively. With the development of modern systemic chemotherapy, the treatment of pulmonary metastasis requires multidisciplinary approaches combined with surgical resection and radiotherapy and the use of accurate diagnostic imaging tools.

### ***Peritoneal metastasis in mCRC***

Peritoneal metastasis develops in 17% of patients with CRC, and approximately 2% of patients have only one metastatic site in the peritoneum. In the Analysis and Research



**Figure 1.** Cytoreductive surgery with HIPEC. A. PET-CT image. B. Peritoneal metastatic lesions. C. Cytoreductive surgery. D. HIPEC.

in Cancer of the Digestive System (ARCAD) database, the median survival of patients with peritoneal mCRC was 16.3 (95% confidence interval, 13.5-18.8) months[36]. Among the metastatic sites, patients with peritoneal metastasis showed the worst survival and prognosis. Overall survival in patients with isolated nonperitoneal metastasis was better than that in patients with isolated peritoneal metastasis. Although most patients with CRC who are diagnosed with peritoneal metastasis are treated by palliative care with systemic chemotherapy, surgical resection for isolated peritoneal metastatic lesions has been considered in some experienced centers.

Peritoneal metastasis of mCRC is heterogeneous with diverse characteristics. To overcome the lack of treatment for peritoneal metastases, cytoreductive surgery and hyperthermic intraperitoneal chemotherapy (HIPEC) were developed[37]. Cytoreductive surgery aims to completely remove tumors involving peritoneal metastatic lesions. HIPEC is performed by the circulation of chemotherapeutic agents intraperitoneally after surgery at 41°C-42°C to eradicate microscopically remnant tumor cells with the infiltration of chemotherapeutic agents into the peritoneal-plasma barriers (Figure 1)[38,39]. According to the results of randomized trials of cytoreductive and mitomycin C-based HIPEC versus systemic chemotherapy with palliative surgery in patients with peritoneal carcinomatosis of CRC, cytoreduction followed by HIPEC improved survival by 22.3 months compared with 12.6 months of standard therapy[40,41]. In this study, HIPEC was performed with the use of 35 mg/m<sup>2</sup> of

mitomycin C mixed with 3 L of isotonic peritoneal dialysis fluid at 41°C-42°C for 90 min. As a result of the improved survival rate noted from this randomized controlled trial, cytoreductive surgery followed by HIPEC has been performed worldwide. In contrast, the PRODIGE-7 trial showed no survival benefits of HIPEC in CRC with peritoneal metastases[42]. The PRODIGE-7 was a randomized, phase 3 trial performed at 17 international centers to evaluate the oncologic benefits of HIPEC compared with cytoreductive surgery alone. In this study, HIPEC was performed for 30 min at 43°C with 2 L/m<sup>2</sup> of a dextrose solution mixed with oxaliplatin. For open HIPEC techniques, 460 mg/m<sup>2</sup> of oxaliplatin was used, and for closed techniques combined with bidirectional chemotherapy during HIPEC, 400 mg/m<sup>2</sup> of fluorouracil and 20 mg/m<sup>2</sup> of folinic acid along with 360 mg/m<sup>2</sup> of oxaliplatin were used. In this study, the median overall survival was 41.7 months for the group that underwent cytoreductive surgery with HIPEC and 41.2 months for the group that underwent cytoreductive surgery alone (p = 0.99). There was no difference in the severity of adverse events between both groups. Recent HIPEC trials using oxaliplatin showed no beneficial results for HIPEC.

The COLOPEC trial was a multicenter, randomized controlled trial to evaluate the efficacy of adjuvant HIPEC in patients with a risk of peritoneal recurrence, such as T4 stage, perforated colon cancer, or peritumoral abscess[43]. The experimental group received primary tumor resection and adjuvant HIPEC followed by systemic chemotherapy, whereas the control group received primary tumor resection



with adjuvant chemotherapy alone. In this study, the adjuvant HIPEC group was treated with oxaliplatin with bidirectional chemotherapy, which is similar to the PRODIGE-7 trial. The results showed that adjuvant HIPEC using oxaliplatin did not show a survival benefit at 18 months compared with that using systemic chemotherapy alone. The peritoneal-free survival at 18 months was 80.9% for the adjuvant HIPEC group and 76.2% for the control group ( $p = 0.28$ ). From these study results, routine adjuvant HIPEC for high risk of peritoneal metastasis is not advocated in the treatment of patients with locally advanced colon cancer.

The PROPHYLOCHIP-PRODIGE 15 trial was a randomized, phase 3 study to assess the survival benefit of second-look surgery followed by HIPEC in patients at high risk of developing CRC peritoneal metastasis. In this study, patients who had a high risk of peritoneal recurrence with synchronous or localized resection for colorectal peritoneal metastasis, resection of ovarian metastasis, or perforated tumors and received systemic chemotherapy were randomly assigned to the second-look surgery/HIPEC group or surveillance control group[44]. The PROPHYLOCHIP trial used oxaliplatin 460 mg/m<sup>2</sup>, oxaliplatin 300 mg/m<sup>2</sup> with irinotecan 200 mg/m<sup>2</sup> with 400 mg/m<sup>2</sup> of fluorouracil intravenously, or mitomycin-HIPEC. Although there were no survival benefits of second-look surgery followed by HIPEC, 41% of patients in the second-look surgery group had grade 3-4 complications such as intra-abdominal complications and hematologic adverse events. The 3-year disease-free survival was 53% for the control group and 44% for the second-look surgery with HIPEC group ( $p = 0.82$ ). Therefore, second-look surgery followed by HIPEC was not advocated in patients with a high risk of colorectal peritoneal metastases. However, there is also fair criticism from failed oncologic results of recent HIPEC trials using oxaliplatin. In particular, the PRODIGE-7 trial had several problems with the study design, with an overestimated effect size, and with the hypothesis for the primary endpoint. In addition, the development of chemotherapeutic agents during the study period and different surgical techniques used in various multicenters can result in a study bias. Moreover, the pharmacologic properties of oxaliplatin are not adequate for intraperitoneal chemotherapy. The short half-life time of oxaliplatin and its rapid absorption into the blood vessels during HIPEC indicates that it is not possible to increase the efficacy of HIPEC in the peritoneal-plasma barriers[45]. However, the role of HIPEC and the surgical role of cytoreduction should be carefully considered because recent trials showed definite prolonged survival compared with that of trials using systemic chemotherapy alone. Complete surgical resections and the development of adequate chemotherapeutic agents for use against peritoneal metastatic lesions are required to prolong survival and increase treatment efficacy in patients with CRC with peritoneal metastases.

## Management of Unresectable mCRC

### *Symptomatic CRC with unresectable metastases*

Patients with stage IV CRC who have unresectable metastases show symptoms due to the primary tumors, such as intestinal obstruction, perforation of the tumor site, or intraluminal bleeding from tumors. Recent guidelines recommend that patients with unresectable metastasis be treated by palliative systemic chemotherapy combined with molecular targeting agents. However, when patients are suffering from tumor-related symptoms, salvage surgery is considered to avoid dreadful conditions arising from tumor progression. Most cases of symptomatic primary cancer are emergent conditions, which are related to mortalities. Therefore, patients with significant bleeding, perforation, or other tumor-related symptoms should be treated by surgical treatment. Primary tumor resection or palliative stoma formation is considered. A pooled analysis of individual data from randomized trials showed that primary tumor resection in synchronous mCRC was associated with improved overall survival compared with no resection[46]. Shida et al. analyzed 770 patients with mCRC who underwent palliative primary tumor resection using propensity score-matched analysis. After adjusting for confounding factors such as age, several symptoms, metastatic organ involvement, sites of primary tumors, and carcinoembryonic antigen, overall survival in the palliative tumor resection group was better than that in the no resection group. Palliative stoma formation in patients with intestinal obstruction from CRC is useful to initiate systemic chemotherapy earlier. Palliative surgery can be an important treatment to prevent emergent conditions and to maintain chemotherapy.

### *Asymptomatic CRC with synchronous unresectable metastases*

The benefit of primary tumor resection in patients with asymptomatic CRC with synchronous unresectable metastasis is still debated. Primary tumor resection has advantages in preventing surgical mortalities, avoiding emergency situations, and reducing primary tumor-related complications. However, primary tumor resection has the disadvantage of delaying the start of chemotherapy after surgery in patients with good responses to palliative chemotherapy and impairing antitumor immunity[47,48]. In addition, the proportion of primary tumor-related complications is relatively low. In the analysis of 233 consecutive patients with mCRC with unresectable metastasis who received oxaliplatin or irinotecan-based triple drug chemotherapy, primary tumor-related complications occurred in 11% of patients[49]. Among them, only 7% of patients required operative interventions. In addition, bevacizumab-related intestinal perforation was related to 1%-2%. McCahill et al. reported that

14% of patients who received mFOLFOX6 with bevacizumab without primary tumor resection had major morbidities. Furthermore, in the time-trend analysis of primary tumor resection using the National Cancer Institute's SEER CRC registry, the overall survival improved in spite of decreased rates of primary tumor resection[50]. Since the development of modern systemic chemotherapy in the last century, there have been increased rates of chemotherapy in patients with stage IV CRC with a decreased rate of primary tumor resection. However, a population-based, propensity score-adjusted trend analysis for patients with mCRC showed that overall survival and cancer-specific survival in both patients receiving primary tumor resection and chemotherapy alone improved[51]. The hazard ratio for palliative primary tumor resection in the 1998-2009 period was less than 0.47 for overall survival. Thus, it needs to be re-evaluated for the dogma of asymptomatic primary tumor resection. In an analysis of the cancer registry of the Netherlands, patients who received primary tumor resection with systemic chemotherapy had improved survival than those who received chemotherapy alone[52]. A systematic review with meta-analysis for patients who underwent primary tumor resection showed favorable oncologic results for primary tumor resection compared with that of upfront chemotherapy alone.

A randomized controlled trial for the role of primary tumor resection was conducted globally. The Korean study (NCT01978249) compared 2-year overall survival between patients receiving primary tumor resection followed by systemic chemotherapy and those receiving upfront chemotherapy alone[53]. Although this study has limitations due to early termination and incomplete study enrollment, 2-year cancer-specific survival in the primary tumor resection group was 72.3%, which was higher than the 47.1% in the upfront chemotherapy group ( $p = 0.049$ ). However, the 2-year overall survival was not significantly different in both groups. The primary tumor-related complication rate was 19.2%, and the  $\geq$ grade 3 major complication rate of the primary tumor resection group was 3.8%.

The results of a recent randomized controlled trial for primary tumor resection for patients with CRC with asymptomatic, synchronous unresectable metastases were published. The JCOG 1007 (iPACS) trial[54] evaluated 165 patients, who were randomly assigned to one of the two groups: primary tumor resection followed by chemotherapy or upfront chemotherapy alone. In this study, the median overall survival of primary tumor resection plus chemotherapy was not significantly different compared with upfront chemotherapy alone (25.9 vs. 26.7 months;  $p = 0.69$ ). Thus, primary tumor resection in patients with CRC with unresectable synchronous metastases cannot guarantee survival benefits and is no longer the standard treatment. The JCOG 1007 trial has study limitations for sample size modification due to difficulties of study enrollment and changes in systemic chemo-

therapy during the study period as well as the advances of chemotherapeutic agents. The changes in study power in the study protocol can influence the results. Hence, the role of primary tumor resection needs to be explored in depth with further worldwide multicentered randomized controlled trials.

## Conclusion

The treatment of mCRC is challenging due to variable tumor extent and heterogeneous characteristics. The location and extent of metastatic lesions should be considered to treat patients with stage IV CRC. Adequate surgical treatments at the appropriate time can improve survival and prevent tumor-related complications. Tailored surgical treatment strategies using modern, developed chemotherapeutic agents may improve survival and the quality of life in patients with mCRC.

This article is based on a study first reported in the J Korean Med Assoc 2022; volume (65): pages (568-576)[55], Surgical treatment for metastatic colorectal cancer.

The original version is available at <https://jkma.org/journal/view.php?number=3364>.

The Editors-in-Chief of Journal of the Korean Medical Association and JMA Journal and the publisher of the original version have permitted the publication of this manuscript.

### Conflicts of Interest

There are no conflicts of interest.

### Source of Funding

This study was supported by the Basic Science Research Program through the National Research Foundation of Korea (NRF) funded by the Ministry of Science and ICT (NRF-2021R1A2C1012853 and NRF-2022R1A2C1013201).

### Author Contributions

Study conception and design: Park EJ; Acquisition of data, analysis and interpretation of data, and drafting of the article: Park EJ; Critical revision: Park EJ; Final approval of the version to be published: Baik SH.

### References

1. Sung H, Ferlay J, Siegel RL, et al. Global cancer statistics 2020: GLOBOCAN estimates of incidence and mortality worldwide for 36 cancers in 185 countries. *CA Cancer J Clin.* 2021 May; 71(3): 209-49.
2. Lee RM, Cardona K, Russell MC. Historical perspective: two decades of progress in treating metastatic colorectal cancer. *J Surg*

- Oncol. 2019 Apr; 119(5): 549-63.
3. Lee T-H, Choo JM, Kim JS, et al. Characteristics and outcomes of colorectal cancer surgery by age in a tertiary center in Korea: a retrospective review. *Ann Coloproctol.* 2022 Jun; 38(3): 244-52.
  4. Huh JW, Maeda K, Liu Z, et al. Current status of "Watch-and-Wait" rectal cancer treatment in Asia-Pacific countries. *Ann Coloproctol.* 2020 Apr; 36(2): 70-7.
  5. Sugarbaker PH. Reported impact of cytoreductive surgery and hyperthermic intraperitoneal chemotherapy on systemic toxicity. *Ann Surg Oncol.* 2008 Jun; 15(6): 1800-1; author reply 1802.
  6. Van Cutsem E, Nordlinger B, Adam R, et al. Towards a pan-European consensus on the treatment of patients with colorectal liver metastases. *Eur J Cancer.* 2006 Sep; 42(14): 2212-21.
  7. Alberts SR, Horvath WL, Sternfeld WC, et al. Oxaliplatin, fluorouracil, and leucovorin for patients with unresectable liver-only metastases from colorectal cancer: a North Central Cancer Treatment Group phase II study. *J Clin Oncol.* 2005 Dec; 23(36): 9243-9.
  8. Franko J, Shi Q, Meyers JP, et al. Prognosis of patients with peritoneal metastatic colorectal cancer given systemic therapy: an analysis of individual patient data from prospective randomised trials from the Analysis and Research in Cancers of the Digestive System (ARCAD) database. *Lancet Oncol.* 2016 Dec; 17(12): 1709-19.
  9. Hwang S, Chan DKH, Petersson F, et al. Nasal cavity metastasis from colorectal cancer represents end-stage disease and should be palliated. *Ann Coloproctol.* 2020 Apr; 36(2): 119-21.
  10. Nakamura Y, Hokuto D, Koyama F, et al. The prognosis and recurrence pattern of right- and left-sided colon cancer in stage II, stage III, and liver metastasis after curative resection. *Ann Coloproctol.* 2021 Oct; 37(5): 326-36.
  11. Engstrand J, Nilsson H, Strömberg C, et al. Colorectal cancer liver metastases - a population-based study on incidence, management and survival. *BMC Cancer.* 2018 Jan; 18(1): 78.
  12. Fong Y, Kemeny N, Paty P, et al. Treatment of colorectal cancer: hepatic metastasis. *Semin Surg Oncol.* 1996; 12(4): 219-52.
  13. Torky R, Alessa M, Kim HS, et al. Characteristics of patients presented with metastases during or after completion of chemoradiation therapy for locally advanced rectal cancer: a case series. *Ann Coloproctol.* 2021 Jun; 37(3): 186-91.
  14. Ruers T, Punt C, Van Coevorden F, et al. Radiofrequency ablation combined with systemic treatment versus systemic treatment alone in patients with non-resectable colorectal liver metastases: a randomized EORTC Intergroup phase II study (EORTC 40004). *Ann Oncol.* 2012 Oct; 23(10): 2619-26.
  15. Choti MA, Sitzmann JV, Tiburi MF, et al. Trends in long-term survival following liver resection for hepatic colorectal metastases. *Ann Surg.* 2002 Jun; 235(6): 759-66.
  16. Kanas GP, Taylor A, Primrose JN, et al. Survival after liver resection in metastatic colorectal cancer: review and meta-analysis of prognostic factors. *Clin Epidemiol.* 2012; 4: 283-301.
  17. Folprecht G. Liver metastases in colorectal cancer. *Am Soc Clin Oncol Educ Book.* 2016; 35: e186-92.
  18. Chow FC, Chok KS. Colorectal liver metastases: an update on multidisciplinary approach. *World J Hepatol.* 2019 Feb; 11(2): 150-72.
  19. Schwarz RE, Abdalla EK, Aloia TA, et al. AHPBA/SSO/SSAT sponsored consensus conference on the multidisciplinary treatment of colorectal cancer metastases. *HPB (Oxford).* 2013 Feb; 15(2): 89-90.
  20. Siriwardena AK, Mason JM, Mullamitha S, et al. Management of colorectal cancer presenting with synchronous liver metastases. *Nat Rev Clin Oncol.* 2014 Aug; 11(8): 446-59.
  21. Sandström P, Røsok BI, Sparrelid E, et al. ALPPS improves resectability compared with conventional two-stage hepatectomy in patients with advanced colorectal liver metastasis: results from a Scandinavian multicenter randomized controlled trial (LIGRO Trial). *Ann Surg.* 2018 May; 267(5): 833-40.
  22. Hasselgren K, Røsok BI, Larsen PN, et al. ALPPS improves survival compared with TSH in patients affected of CRLM: survival analysis from the randomized controlled trial LIGRO. *Ann Surg.* 2021 Mar; 273(3): 442-8.
  23. Park SH, Shin JK, Lee WY, et al. Clinical outcomes of neoadjuvant chemotherapy in colorectal cancer patients with synchronous resectable liver metastasis: a propensity score matching analysis. *Ann Coloproctol.* 2021 Aug; 37(4): 244-52.
  24. Slessor AA, Simillis C, Goldin R, et al. A meta-analysis comparing simultaneous versus delayed resections in patients with synchronous colorectal liver metastases. *Surg Oncol.* 2013 Mar; 22(1): 36-47.
  25. Vallance AE, van der Meulen J, Kuryba A, et al. The timing of liver resection in patients with colorectal cancer and synchronous liver metastases: a population-based study of current practice and survival. *Colorectal Dis.* 2018 Jun; 20(6): 486-95.
  26. Brouquet A, Mortenson MM, Vauthey JN, et al. Surgical strategies for synchronous colorectal liver metastases in 156 consecutive patients: classic, combined or reverse strategy? *J Am Coll Surg.* 2010 Jun; 210(6): 934-41.
  27. Wang X, Sofocleous CT, Erinjeri JP, et al. Margin size is an independent predictor of local tumor progression after ablation of colon cancer liver metastases. *Cardiovasc Intervent Radiol.* 2013 Feb; 36(1): 166-75.
  28. Chan DL, Alzahrani NA, Morris DL, et al. Systematic review and meta-analysis of hepatic arterial infusion chemotherapy as bridging therapy for colorectal liver metastases. *Surg Oncol.* 2015 Sep; 24(3): 162-71.
  29. Riemsma RP, Bala MM, Wolff R, et al. Transarterial (chemo)embolisation versus no intervention or placebo intervention for liver metastases. *Cochrane Database Syst Rev.* 2013 Apr; 30(4): CD009498.
  30. Chiappetta M, Salvatore L, Congedo MT, et al. Management of single pulmonary metastases from colorectal cancer: state of the art. *World J Gastrointest Oncol.* 2022 Apr; 14(4): 820-32.
  31. Pfannschmidt J, Dienemann H, Hoffmann H. Surgical resection of pulmonary metastases from colorectal cancer: a systematic review of published series. *Ann Thorac Surg.* 2007 Jul; 84(1): 324-38.
  32. Mitry E, Guiu B, Coscinea S, et al. Epidemiology, management and prognosis of colorectal cancer with lung metastases: a 30-year population-based study. *Gut.* 2010 Oct; 59(10): 1383-8.
  33. Parnaby CN, Bailey W, Balasingam A, et al. Pulmonary staging in colorectal cancer: a review. *Colorectal Dis.* 2012 Jun; 14(6): 660-70.
  34. Meng D, Fu L, Wang L, et al. Video-assisted thoracoscopic surgery versus open thoracotomy in pulmonary metastasectomy: a meta-analysis of observational studies. *Interact Cardiovasc Thorac Surg.* 2016 Feb; 22(2): 200-6.
  35. Sheikh S, Chen H, Sahgal A, et al. An analysis of a large multi-institutional database reveals important associations between treat-

- ment parameters and clinical outcomes for stereotactic body radiotherapy (SBRT) of oligometastatic colorectal cancer. *Radiother Oncol.* 2022 Feb; 167: 187-94.
36. Franko J, Shi Q, Meyers JP, et al. Prognosis of patients with peritoneal metastatic colorectal cancer given systemic therapy: an analysis of individual patient data from prospective randomised trials from the Analysis and Research in Cancers of the Digestive System (ARCAD) database. *Lancet Oncol.* 2016 Dec; 17(12): 1709-19.
  37. Kim YJ, Kim CH. Treatment for peritoneal metastasis of patients with colorectal cancer. *Ann Coloproctol.* 2021 Dec; 37(6): 425-33.
  38. Roh SJ, Park SC, Choi J, et al. Cytoreductive surgery and hyperthermic intraperitoneal chemotherapy with Mitomycin C used for colorectal peritoneal carcinomatosis. *Ann Coloproctol.* 2020 Jan; 36(1): 22-9.
  39. Sugarbaker PH, Ryan DP. Cytoreductive surgery plus hyperthermic perioperative chemotherapy to treat peritoneal metastases from colorectal cancer: standard of care or an experimental approach? *Lancet Oncol.* 2012 Aug; 13(8): e362-9.
  40. Verwaal VJ, van Ruth S, de Bree E, et al. Randomized trial of cytoreduction and hyperthermic intraperitoneal chemotherapy versus systemic chemotherapy and palliative surgery in patients with peritoneal carcinomatosis of colorectal cancer. *J Clin Oncol.* 2003 Oct; 21(20): 3737-43.
  41. Verwaal VJ, van Ruth S, Witkamp A, et al. Long-term survival of peritoneal carcinomatosis of colorectal origin. *Ann Surg Oncol.* 2005 Jan; 12(1): 65-71.
  42. Quénet F, Elias D, Roca L, et al. Cytoreductive surgery plus hyperthermic intraperitoneal chemotherapy versus cytoreductive surgery alone for colorectal peritoneal metastases (PRODIGE 7): a multicentre, randomised, open-label, phase 3 trial. *Lancet Oncol.* 2021 Feb; 22(2): 256-66.
  43. Klaver CEL, Wisselink DD, Punt CJA, et al. Adjuvant hyperthermic intraperitoneal chemotherapy in patients with locally advanced colon cancer (COLOPEC): a multicentre, open-label, randomised trial. *Lancet Gastroenterol Hepatol.* 2019 Oct; 4(10): 761-70.
  44. Goéré D, Glehen O, Quenet F, et al. Second-look surgery plus hyperthermic intraperitoneal chemotherapy versus surveillance in patients at high risk of developing colorectal peritoneal metastases (PROPHYLOCHIP-PRODIGE 15): a randomised, phase 3 study. *Lancet Oncol.* 2020 Sep; 21(9): 1147-54.
  45. Ceelen W. HIPEC with oxaliplatin for colorectal peritoneal metastasis: the end of the road? *Eur J Surg Oncol.* 2019 Mar; 45(3): 400-2.
  46. van Rooijen KL, Shi Q, Goey KKH, et al. Prognostic value of primary tumour resection in synchronous metastatic colorectal cancer: individual patient data analysis of first-line randomised trials from the ARCAD database. *Eur J Cancer.* 2018 Mar; 91: 99-106.
  47. Doah KY, Shin US, Jeon BH, et al. The impact of primary tumor resection on survival in asymptomatic colorectal cancer patients with unresectable metastases. *Ann Coloproctol.* 2021 Apr; 37(2): 94-100.
  48. Gelsomino F, Spallanzani A, Orsi G, et al. To resect or not to resect: the hamletic dilemma of primary tumor resection in patients with asymptomatic stage IV colorectal cancer. *Crit Rev Oncol Hematol.* 2018 Dec; 132: 154-60.
  49. Poultides GA, Servais EL, Saltz LB, et al. Outcome of primary tumor in patients with synchronous stage IV colorectal cancer receiving combination chemotherapy without surgery as initial treatment. *J Clin Oncol.* 2009 Jul; 27(20): 3379-84.
  50. Hu CY, Bailey CE, You YN, et al. Time trend analysis of primary tumor resection for stage IV colorectal cancer: less surgery, improved survival. *JAMA Surg.* 2015 Mar; 150(3): 245-51.
  51. Tarantino I, Warschkow R, Worni M, et al. Prognostic relevance of palliative primary tumor removal in 37,793 metastatic colorectal cancer patients: a population-based, propensity score-adjusted trend analysis. *Ann Surg.* 2015 Jul; 262(1): 112-20.
  52. Lam-Boer J, Van der Geest LG, Verhoef C, et al. Palliative resection of the primary tumor is associated with improved overall survival in incurable stage IV colorectal cancer: a nationwide population-based propensity-score adjusted study in the Netherlands. *Int J Cancer.* 2016 Nov; 139(9): 2082-94.
  53. Park EJ, Baik JH, Choi GS, et al. The role of primary tumor resection in colorectal cancer patients with asymptomatic, synchronous, unresectable metastasis: a multicenter randomized controlled trial. *Cancers (Basel).* 2020 Aug; 12(8): 2306.
  54. Kanemitsu Y, Shitara K, Mizusawa J, et al. Primary tumor resection plus chemotherapy versus chemotherapy alone for colorectal cancer patients with asymptomatic, synchronous unresectable metastases (JCOG1007; iPACS): a randomized clinical trial. *J Clin Oncol.* 2021 Apr; 39(10): 1098-107.
  55. Park EJ, Baik SH. Surgical treatment for metastatic colorectal cancer. *JKMA.* 2022 Sep; 65(9): 568-76.

Journal of the Anus, Rectum and Colon is an Open Access journal distributed under the Creative Commons Attribution-NonCommercial-NoDerivatives 4.0 International License. To view the details of this license, please visit (<https://creativecommons.org/licenses/by-nc-nd/4.0/>).