


REVIEW

The importance of myocarditis in Covid-19

Katayoun Haryalchi¹  | Sepehr Olangian-Tehrani²  |
Seyed Mohammad Asgari Galebin³  | Mandana Mansour-Ghanaie⁴ 

¹Reproductive Health Research Center, Al-zahra Hospital, School of Medicine, Guilan University of Medical Sciences, Rasht, Iran

²School of Medicine, Iran University of Medical Sciences, Tehran, Iran

³School of Medicine, Guilan University of Medical Sciences, Rasht, Iran

⁴Reproductive Health Research Center, Department of Obstetrics & Gynecology, Al-zahra Hospital, School of Medicine, Guilan University of Medical Sciences, Rasht, Iran

Correspondence

Mandana Mansour-Ghanaie, Reproductive Health Research Center, Al-zahra Hospital, Guilan University of Medical Sciences, Namjoo Street, P.O. Box 4144654839, Rasht, Iran.
Email: m_m_ghanaie@yahoo.com

Abstract

Background: The outbreak of Covid-19 is a real threat to public health. It causes cardiovascular complications such as acute myocardial injury and myocarditis. Symptoms of myocarditis vary from chest pain, tachycardia, or chest tightness. Inotropes and/or vasopressors and mechanical ventilation are the protocols for cardiogenic shock in patients with myocarditis. Some previous studies stated that the mechanism of cardiac injury is not well defined but, it can be due to direct myocardial infection, respiratory failure or hypoxemia, and indirect injury from systemic inflammatory response separately or all three factors together. The pathologic processes included direct myocardial injury by virus binding to ACE2, systemic inflammation, altered myocardial demand-supply ratio, and plaque and coronary thrombosis. There are disagreements on the usage of corticosteroids in active-infection myocarditis. As everyday new complications of Covid-19 appear, there is a need for further research to overcome them.

Aims: This narrative study aimed to assess the effect of Covid-19 on myocarditis.

KEYWORDS

Covid-19, heart, myocarditis

1 | INTRODUCTION

Nowadays Covid-19 has been known as a pandemic which caused mortality and morbidity. In addition to respiratory problems, it could be accompanied by other dangerous complications.¹ One of the important ones is cardiovascular complications. And one of the serious complications is acute myocardial injury that leads to myocarditis. Also, Acute Respiratory Distress Syndrome (ARDS) can cause acute myocardial injury followed by myocarditis. As it has been shown that cardiovascular complications are associated with more mortality rate. Overall, myocardial involvement occurs in 20%-30% of hospitalized patients with Covid-19. The prevalence of myocarditis is unknown, and the number of autopsies is limited.²⁻⁴

Maybe cardiovascular diseases and older age are risk factors for the development and severity of Covid-19. And conversely cardiovascular disease may be caused by exacerbation of Covid-19. It has been

reported that viral myocarditis created with Covid-19 can exist without clinical symptoms.⁵

Acute cardiac injury defined as elevated cardiac troponin levels and associated with higher mortality.⁶ Pathology is usually focal within myocarditis, but in addition to myocardial involvement and myocarditis there is a risk of arrhythmia, fulminant heart failure, and cardiogenic shock.⁷

Endomyocardial biopsy is the gold standard of myocarditis diagnosis.⁸ Generally, myocarditis is an inflammatory disease. It can be intensified by cytokine storm syndrome that leads to T-Lymphocyte activation and inflammatory cytokines release.⁹

Covid-19 attaches to Angiotensin-Converting Enzyme 2 (ACE2) in alveolar and myocardial tissues and causes myocardial injury.¹⁰ It has been presented that cardiac troponin levels are high in Covid-19 obviously.¹¹ It is the indicator of myocardial injury even in the non-ischemic myocardial process.¹² Also, the troponin T (TnT) prognostic

This is an open access article under the terms of the Creative Commons Attribution-NonCommercial-NoDerivs License, which permits use and distribution in any medium, provided the original work is properly cited, the use is non-commercial and no modifications or adaptations are made.

© 2022 The Authors. *Health Science Reports* published by Wiley Periodicals LLC.

accuracy can be increased by N-terminal pro-B-type natriuretic peptide (NT-proBNP) measurement.¹³ Some previous studies stated that the mechanism of cardiac injury is not well defined but it can be due to direct myocardial infection, respiratory failure or hypoxemia, indirect injury from systemic inflammatory response separately or all three factors.^{1,14} The pathologic processes included direct myocardial injury with virus binding to ACE2, systemic inflammation, altered myocardial demand-supply ratio, plaque, and coronary thrombosis^{15,16} (Figure 1).

As Covid-19 is a new problem as a pandemic and in fact, little is known about it. We decided to arrange this narrative review to assess the effect of Covid-19 on cardiovascular system and creating myocarditis, which can be both a cause of mortality and can lead to morbidity. We know there is a long way to go to understand all the side effects of the Covid-19, but we tried to highlight specially myocarditis caused by this disease by reviewing these few articles.

1.1 | Aim

This narrative study aimed to assess the effect of Covid-19 on creating myocarditis.

2 | RESULTS

2.1 | Cardiac manifestations of myocarditis in Covid-19

Some of cardiac problems included acute coronary syndrome (ACS), cardiac dysfunction, blood pressure fluctuations, arrhythmias, and

myocarditis.^{17,18} Although viral myocarditis created by Covid-19 can be asymptomatic, or mild to severe symptoms can be presented too.¹⁹ Mild chest pain, tachycardia, chest tightness or exertion and fatigue are the mild symptoms. Severe symptoms included left to right ventricular failure, increased jugular venous pressure, peripheral edema, arrhythmias, left upper quadrant pain, cardiogenic shock, and sudden death.^{15,20}

2.2 | Probable mechanisms of myocarditis during Covid-19

As it is clear, myocardial injury and damage lead to myocarditis. It can be confirmed by biventricular edema in cardiac MRI.^{7,16,21} Myocardial damage that causes myocarditis, is accompanied by cardiac enzymes rising, electrocardiographic abnormalities such as ST elevation, new-onset bundle branch block, PR depression, and QT prolongation.^{15,21,22} Ischemic myocardial damage causes myocardial infarction with increased risk of plaque rupture, thrombus formation that leads to ST elevation MI or non-ST elevation MI)due to severe hypoxemia(. As it is clear, hypoxemia makes vasoconstriction, increased myocardial demand and finally myocardial injury due to supply-demand mismatch.^{23,24}

2.3 | Myocardial damage

Myocardial injury is defined as increased cardiac troponin above the 99th percentile.²⁵ The virus initially attacks cardiac cells directly and following the inflammatory response, further damage.^{1,25} Although the mechanism of cardiac injury in Covid-19 is not well defined, acute

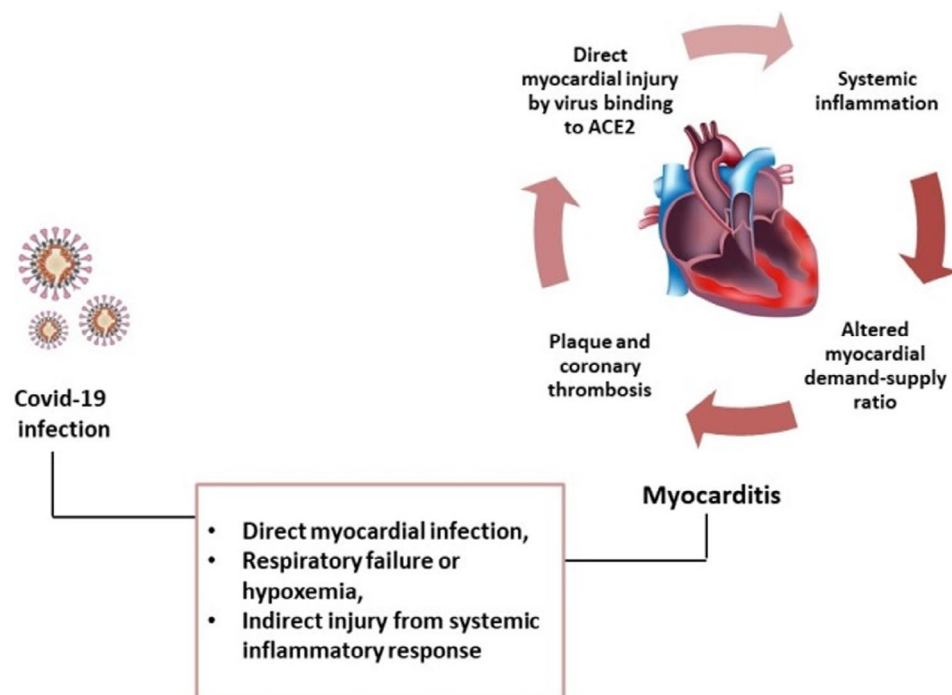


FIGURE 1 Some of the proposed mechanisms and pathologic processes of cardiac injury in Covid-19 infection

myocardial injury is the main cardiovascular complication in this pandemic. The probable mechanism is as below:

- Direct myocardial injury by binding to ACE2.
- Indirect myocardial injury by (a) overwhelming immune-inflammatory response (b) severe hypoxia from acute respiratory damage which leading to oxidative stress and increases the cardiometabolic demand and finally myocardial injury.
- Elevation of cardiac biomarkers particularly cardiac troponin (hs-troponin) and/or creatinine kinase MB that is common in Covid-19 infection.^{5,20} In Covid-19, three types of myocardial injury are included:
 - Mild increase in troponin level is the most common type (typically more than 99%).
 - Progressive type is the second one. In this type, some patients have normal or moderately increased troponin level.
 - Early moderate increase in troponin level is the third one that usually occurs in clinical myocarditis.⁶

3 | DISCUSSION

In patients with fulminant myocarditis, inotropes and/or vasopressors, and mechanical ventilation are the appropriate protocols for cardiogenic shock. For long-term treatment, mechanical circulatory support such as extracorporeal membrane oxygenation, intra-aortic balloon pump, and ventilator-assisted devices have been used. There are disagreements about the usage of corticosteroids in active-infection myocarditis. As a result, in hemodynamic stable cases, inotropes or vasopressors are the choices. Corticosteroids and intravenous immunoglobulin can be used considering the immunosuppression made by the corticosteroid usage. Furthermore, it has been reported that Tocilizumab can suppress cytokine storms and help to reduce myocardial inflammation.⁷

In a previous study, researchers used antiviral medication and immunomodulators as supportive therapy. Considering heart failure, they used balanced therapy with vasopressors, inotropes, diuretics, vasodilators, and fluids. In critically ill patients, they tried Norepinephrine and in the case of arrhythmias, they used Dopamine. Cardiogenic shock has been treated with Dobutamine and Milrinone. Although they did not use corticosteroids and intravenous immunoglobulins in the absence of ARDS for critically ill patients, they believed corticosteroids were not useful for patients with lymphocytic myocarditis. Instead, they used systemic corticosteroids for mechanically ventilated patients with ARDS. For fulminant myocarditis, clinicians administered 200 mg/day Methylprednisolone (to suppress inflammation) for 4 days and 2 g/d immunoglobulin for 4 days. They avoided corticosteroids in heart failure and prescribed Colchicine in pericarditis.¹⁹

Rali et al pointed to the role of cytokine storm myocardial damage and proposed Tocilizumab to treat this complication. They also pointed out the role of ACE2 downregulation in Covid-19. Thus, they suggested ACE2 inhibitors to control mortality.⁹

Kang et al concluded that there is no proven remedy for Covid-19, but they focused on supportive therapy. They suggested medication in the following manner:

1. Prophylactic anticoagulant therapy (to prevent thromboembolism).
2. ACE inhibitors.
3. Angiotensin receptor blockers.
4. Hydroxychloroquine/Chloroquine and Azithromycin because for their antiviral activity and immune activation property.
5. Immunosuppressive therapy. This remedy can reduce the hyper-inflammatory response.
6. Mechanical cardiopulmonary support.²³

Moreover, Mitrani et al believed in antiviral, immune-suppressive, cell-based, and anti-inflammatory therapies as the appropriate treatment of Covid-19. They noted standard care in ACS or type I MI.²

Bavishi et al declared the management of ACS according to the guidelines. But during this crisis, they followed protocols according to the clinical activity and local resource availability. Based on the antiviral properties and immunomodulatory effects of Hydroxychloroquine and Azithromycin, they recommended the combination of these anti-coagulants, antiviral, and anti-inflammatory agents. They encouraged the use of Remdesivir as an RNA inhibitor for hospitalized cases. They had a debate on ACE2 inhibitors administration because of the worsening of infection.²⁴

Goha et al showed that Chloroquine and Hydroxychloroquine had good in vitro activity against the virus. They illustrated that Remdesivir inhibited viral RNA polymerases and had chemical improvement. They showed that convalescent plasma and Tocilizumab are other treatments to reduce the severity of illness.²⁶

Anupama and Chaudhuri proposed Covid-19 management based on balancing the risk/benefit. They concluded that in ACS caused by Covid-19, asymptomatic patients who have mild to moderate increased level of troponin only needed clinical monitoring without cardiac imaging until their recovery. They did not recommend cardiovascular MRI or endomyocardial biopsy in clinically suspected myocarditis. They believed that myocardial injury should be managed by identifying the cause and supportive care. In patients with refractory shock or ventricular arrhythmias secondary to fulminant myocarditis, they recommended mechanical support with extracorporeal membrane oxygenation.⁶

Salamanca et al prescribed 1000 mg bolus of Methylprednisolone followed with Tocilizumab, Hydroxychloroquine, Azithromycin, and Lopinavir-Ritonavir for fulminant myocarditis. They reported successful treatment with temporary mechanical circulatory support in cardiogenic shock due to fulminant myocarditis.²⁷

Marban et al believed immunosuppressive regimens were most beneficial throughout the hyper-inflammation rather than the early phase. They used antiviral drugs like Lopinavir and Ritonavir as HIV protease inhibitors to decrease viral load. They illustrated that Remdesivir was also effective against Covid-19. They showed Ribavirin had a similar therapeutic effect for Covid-19 infection. And finally, they showed Favipiravir had a faster resolution of fever and cough.

They prescribed Antimalarial agents like Chloroquine and Hydroxychloroquine as Covid-19 inhibitors. They also used immunoglobulins and anti-IL6 antibodies for viral neutralization and immunomodulation. It seems that IVIG terminates the inflammation suppression and alleviates hyper-inflammation phase severity. They administered corticosteroids as well. They used cell-based therapy for skeletal myoblasts, bone marrow, and mesenchymal stem cell stimulation.¹

Kishor et al suggested ACE Inhibitors and Angiotensin Receptor Blockers increased ACE2 levels that may decompensate cardiac function due to Covid-19 infection. They were unsure about using antiviral remedies such as Chloroquine and Hydroxychloroquine or Azithromycin because of their cardiovascular complications like QT interval prolongation, Atrioventricular block, pulmonary hypertension, sick sinus syndrome, and sudden death.²²

Everaert et al assessed the usage of Hydroxychloroquine or Chloroquine with or without Azithromycin as the first-line treatment because of the risk of QT interval prolongation and subsequent arrhythmias.²⁸

Paul et al treated a case of myocarditis with 5 mg of Ramipril and 5 mg of bisoprolol.²⁹

Kow and Hasan discussed the usage of corticosteroid and IVIG in fulminant myocarditis. They were worried about a secondary infection that may occur by corticosteroids. They believed that IVIG was stronger in the treatment of myocarditis than corticosteroids. They illustrated that IVIG reduced in-hospital mortality significantly. It has been presented that IVIG decreased cardiac inflammation and down-regulation of cytokines which has a negative inotropic effect.³⁰

4 | CONCLUSION

We know that Covid-19 has confused the whole world, and myocarditis is a dangerous complication of Covid-19. There is not much information about its treatment or outcome yet. In this article, we have tried to take a brief look at 31 articles which have studied the cardiac complications of Covid-19, especially myocarditis. Because Covid-19 and its side effects as myocarditis are very new to the world there is a need for further research to overcome them.

ACKNOWLEDGMENTS

The authors thank all those who helped them writing this article.

FUNDING

None.

CONFLICT OF INTEREST

The authors report no conflict of interest regarding publication of this paper.

AUTHOR CONTRIBUTIONS

Conceptualization: Katayoun Haryalchi, Mandana Mansour-Ghanaie

Writing –Original Draft: Sepehr Olangian-Tehrani

Writing – Review and Editing: Sepehr Olangian-Tehrani, Seyed Mohammad Asgari Galebin, Mandana Mansour-Ghanaie

TRANSPARENCY STATEMENT

All the authors affirm that this manuscript is an honest, accurate, and transparent account of the study being reported, and no important aspects of the study have been omitted.

DATA AVAILABILITY STATEMENT

Related data of this project are available on request.

ORCID

Katayoun Haryalchi  <https://orcid.org/0000-0001-8012-9952>

Sepehr Olangian-Tehrani  <https://orcid.org/0000-0002-8970-9344>

Seyed Mohammad Asgari Galebin  <https://orcid.org/0000-0002-6464-197X>

Mandana Mansour-Ghanaie  <https://orcid.org/0000-0003-1503-3502>

REFERENCES

- Haryalchi K, Heidarzadeh A, Abedinzade M, Olangian-Tehrani S, Ghazanfar TS. The importance of happy hypoxemia in COVID-19. *Anesth Pain Med.* 2021;11(1):e111872.
- Mitrani R, Dabas N, Goldberger JJ. COVID-19 cardiac injury: implications for long-term surveillance and outcomes in survivors. *Heart Rhythm.* 2020;17(11):1984-1990.
- Ranard LS, Fried JA, Abdalla M, et al. Approach to acute cardiovascular complications in COVID-19 infection. *Circ Heart Fail.* 2020;13(7):e007220.
- Dweck M, Bularga A, Hahn R, et al. Global evaluation of echocardiography in patients with COVID-19. *Eur Heart J Cardiovasc Imaging.* 2020;21(9):949-958.
- Uriel N, Sayer G, Clerkin KJ. Myocardial injury in COVID-19 patients (The beginning or the end?). *J Am Coll Cardiol.* 2020;76(5):547-549.
- Anupama B, Chaudhuri D. A review of acute myocardial injury in coronavirus disease 2019. *Cureus.* 2020;12(6):e8426.
- Siripanthong B, Nazarian S, Muser D, et al. Recognizing COVID-19 related myocarditis: the possible pathophysiology and proposed guideline for diagnosis and management. *Heart Rhythm.* 2020;17(9):1463-1471.
- Ortiz A, Wiwanitkit V. Fulminant myocarditis and COVID19. *Rev Esp Cardiol.* 2020;73(10):865-866.
- Rali AS, Ranka S. Mechanisms of myocardial injury in Coronavirus Disease 2019. *Card Fail Rev.* 2020;6:e15.
- Lal S, Hayward C, Pasquale C, et al. COVID-19 and acute heart failure: screening the critically ill 11-A position statement of the cardiac society of Australia and New Zealand (CSANZ). *Heart Lung Circ.* 2020;29(7):e94-e98.
- Kunal S, Gupta K, Sharma SM, Pathak V, Mittal S, Tarke C. Cardiovascular system and COVID-19: perspectives from a developing country. *Monaldi Arch Chest Dis.* 2020;90(2):231-241.
- Imazio M, Klingel K, Kindermann I, et al. COVID-19 pandemic and troponin: indirect myocardial injury, myocardial inflammation or myocarditis? *Heart.* 2020;106(15):1127-1131.
- Calvo-Fernández A, Izquierdo A, Subirana I, Farré N, Vila J, Durán X. [Markers of myocardial injury in the prediction of short-term COVID-19 prognosis]. *Rev Esp Cardiol (English Edition).* 2020;74(7):576-583.
- Deng Q, Hu B, Zhang Y, et al. Suspected myocardial injury in patients with COVID-19: evidence from front line clinical observation in Wuhan, China. *Int J Cardiol.* 2020;33:116-121.
- Shafi AMA, Shaikh SA, Shirke MM, Iddawela S, Harky A. Cardiac manifestations in COVID-19 patients-A systematic review. *J Card Surg.* 2020;35(8):1988-2008.

16. Babapoor-Farrokhran S, Gill D, Walker J, Rasekhi RT, Bozorgnia B, Amanullah A. Myocardial injury and COVID-19: possible mechanisms. *Life Sci.* 2020;253:117723.
17. Juusela A, Nazir M, Gimovsky M. Two cases of coronavirus 2019-related cardiomyopathy in pregnancy. *Am J Obstet Gynecol MFM.* 2020;2(2):100113.
18. Mehra MR, Ruschitzka F. COVID-19 illness and heart failure. *JACC Heart Fail.* 2020;8(6):512-514.
19. Talasaz H, Kakavand H, Van Tassel B, et al. Cardiovascular complications of COVID-19: pharmacotherapy perspective. *Cardiovasc Drugs Ther.* 2020;35(2):249-259.
20. Craver R, Huber S, Sandomirsky M. Fatal eosinophilic myocarditis in a healthy 17 year old male with severe acute respiratory syndrome coronavirus 2 (SARS-CoV-2c). *Fetal Pediatr Pathol.* 2020;39:263-268.
21. Gill GS, Vlacancich R, Mehta N, Chaturvedi M, Papolos A. Spectrum of cardiac involvement in COVID-19. *Cureus.* 2020;12(6):e8638.
22. Kishor K, Marwah R, Anantharaj A, Krla S. Cardiovigilance in COVID-19. *J Pak Med Assoc.* 2020;70(Suppl 3)(5):S77-S80.
23. Kang Y, Chen T, Mui D, et al. Cardiovascular manifestations and treatment considerations in COVID-19. *Heart.* 2020;106:1132-1141.
24. Bavishi C, Bonow RO, Trivedi V, Abbott JD, Messerli FH, Bhatt DL. Special Article - Acute myocardial injury in patients hospitalized with COVID-19 infection: a review. *Prog Cardiovasc Dis.* 2020;63(5):682-689.
25. Bandyopadhyay D, Akhtar T, Hajra A, et al. COVID-19 pandemic: cardiovascular complications and future implications. *Am J Cardiovasc Drugs.* 2020;20:311-324.
26. Goha A, Mezue K, Edwards P, Nunura F, Baugh D, Madu E. COVID-19 and the heart: an update for clinicians. *Clin Cardiol.* 2020;43:1-7.
27. Salamanca J, Díez-Villanueva P, Martínez P, et al. COVID-19 "fulminant myocarditis" successfully treated with temporary mechanical circulatory support. *J Am Coll Cardiol Imaging.* 2020;13(11):2457-2459.
28. Everaert BR, Muylle J, Twickler TB. Emerging cardiological issues during the COVID-19 pandemic. *Eur J Clin Invest.* 2020 Jul;50(7):e13270.
29. Paul JF, Charles P, Richaud C, Caussin C, Diakov C. Myocarditis revealing COVID-19 infection in a young patient. *Eur Heart J Cardiovasc Imaging.* 2020;21(7):776.
30. Kow CS, Hasan SS. Glucocorticoid versus immunoglobulin in the treatment of COVID-19-associated fulminant myocarditis. *Infection.* 2020;48(5):805-806.

How to cite this article: Haryalchi K, Olangian-Tehrani S, Asgari Galebin SM, Mansour-Ghanaie M. The importance of myocarditis in Covid-19. *Health Sci Rep.* 2022;5:e488. doi:10.1002/hsr2.488