

Guidelines

Pathological examination of breast cancer samples before and after neoadjuvant therapy: recommendations from the Italian Group for the Study of Breast Pathology - Italian Society of Pathology (GIPaM-SIAPeC)

Nicola Fusco^{1,2}, Antonio Rizzo³, Leopoldo Costarelli⁴, Alfredo Santinelli⁵, Bruna Cerbelli⁶, Cristian Scatena^{7,8}, Ettore Macri⁹, Francesca Pietribiasi¹⁰, Giulia d'Amati¹¹, Anna Sapino^{12,13}, Isabella Castellano¹³

¹ Division of Pathology, IEO, European Institute of Oncology IRCCS Milan, Italy; ² Department of Oncology and Hemato-Oncology, University of Milan, Italy; ³ Division of Pathology, Humanitas Cancer Center, Catania, Italy; ⁴ Department of Pathology, San Giovanni-Addolorata Hospital, Rome Italy; ⁵ Anatomic Pathology, Azienda Ospedaliera Ospedali Riuniti Marche Nord, Pesaro, Italy; ⁶ Department of Medical-Surgical Sciences and Biotechnologies, Sapienza University of Rome, Rome, Italy; ⁷ Department of Laboratory Medicine, Pisa University Hospital, Anatomic Pathology 1 Universitaria, Pisa, Italy; ⁸ Department of Translational Research and New Technologies in Medicine and Surgery, University of Pisa, Italy; ⁹ Division of Pathology, San Martino Hospital, Belluno, Italy; ¹⁰ Division of Pathology, Santa Croce Hospital, Moncalieri (TO), Italy; ¹¹ Department of Radiological, Oncological and Pathological Sciences, <Sapienza> University of Rome, Rome, Italy; ¹² Candiolo Cancer Institute, FPO-IRCCS Candiolo, (TO), Italy; ¹³ Department of Medical Sciences, University of Turin, Italy

Received: January 17, 2022
Accepted: January 21, 2022

Correspondence

Nicola Fusco
IEO, European Institute of Oncology, University of Milan, via Giuseppe Ripamonti 435, 20141 Milan, Italy
E-mail: nicola.fusco@unimi.it

How to cite this article: Fusco N, Rizzo A, Costarelli L, et al. Pathological examination of breast cancer samples before and after neoadjuvant therapy: Recommendations from the Italian group for the study of breast pathology - Italian Society of Pathology (GIPaM-SIAPeC). *Pathologica* 2022;114:104-110. <https://doi.org/10.32074/1591-951X-747>

© Copyright by Società Italiana di Anatomia Patologica e Citopatologia Diagnostica, Divisione Italiana della International Academy of Pathology



OPEN ACCESS

This is an open access journal distributed in accordance with the CC-BY-NC-ND (Creative Commons Attribution-NonCommercial-NoDerivatives 4.0 International) license: the work can be used by mentioning the author and the license, but only for non-commercial purposes and only in the original version. For further information: <https://creativecommons.org/licenses/by-nc-nd/4.0/deed.en>

Summary

Neoadjuvant therapy (NAT) in breast cancer is administered to downstage the tumor, de-escalate surgery, and provide prognostic information that can be used to tailor subsequent adjuvant therapy. In this respect, the pathological evaluation of both pre-NAT biopsies and post-NAT surgical specimens is crucial to precisely assess the treatment response. With the increasing possibilities of NAT protocols and the rising number of eligible patients, it has become extremely important to standardize the pathological response assessment. Here, we provide an update on the recommendations of the Italian Group for the Study of Breast Pathology - the Italian Society of Pathology (GIPaM-SIAPeC) for the analysis of breast cancer samples before and after NAT.

Key words: breast cancer, neoadjuvant therapy, biomarkers, pathological response

Premise

Neoadjuvant therapy (NAT) consists of the administration of drugs and/or radiation before the surgical treatment of the tumor ¹. This therapeutic approach plays a key role in the clinical management of early or locally advanced breast cancers with unfavorable prognostic factors ²⁻⁶. For these patients, the main purposes of NAT are represented by: i) reduction of tumor burden, thus allowing for surgery (in previously inoperable tumors) or surgery de-escalation, including breast-conserving surgery (BCS) and to avoid axillary dissection; and ii) detection of prognostic information to tailor subsequent adjuvant treatment ²⁻¹¹. Up to 40% of breast cancer patients achieve a pathological complete response, i.e. lack of breast cancer in surgical samples removed after NAT ¹². It is important to precisely quantify this parameter because dif-

ferent tumor(s) may respond differently to the same treatment^{13,14}. The pathological evaluation of pre-NAT biopsies and post-NAT surgical samples is the gold standard procedure to assess treatment response^{15,16}. In this respect, pathological complete response is associated with an improved prognosis; on the other hand, the characteristics of residual tumor deposits have a significant impact on subsequent treatment and ultimately on disease-free survival.

The evaluation of pathological response is an essential phase in clinical management of patients with breast cancer treated with NAT. The role of the pathologist starts with histopathological analysis of tumor biopsies along with biomarkers testing in potentially eligible patients and continues with assessment and characterization of pathological response and biomarkers status on the surgical sample after NAT.

Pathological evaluation before neoadjuvant therapy

Goal: To define the histological and biological characteristics of the tumor, allowing for establishment of the appropriate treatment protocol (Fig. 1).

CHECK-IN OF THE BIOPSY SAMPLES AND MACROSCOPIC EXAMINATION

The check-in criteria, as well as the methods for the macroscopic examination of pre-NAT biopsies, are the same as those for standard breast biopsies, as defined by standard operating procedures (SOPs)¹⁷⁻²⁰. A crucial point is represented by the information provided in the request form for the pathology laboratory. Here, the clinician should clearly state that the patient is potentially eligible for NAT.

Specific information on the neoplasm(s) should also be reported:

- 1 localization (by imaging support, if possible);
- 2 size (two dimensions) and number of neoplastic foci;
- 3 presence of microcalcifications;
- 4 the number of tissue cores taken (it is desirable to take at least 2 cores per cm of tumor for a maximum of 6 total cores).

HISTOLOGICAL EXAMINATION

The histological analysis of pre-NAT biopsies should provide all the information to tailor treatment.

Therefore, the pathology report should include:

- 1 histological type according to the latest WHO Classification of Breast Tumors^{21,22};
- 2 nuclear grade or grading according to the Notting-

- ham Grading System²³;
- 3 presence of ductal in situ carcinoma (DCIS);
- 4 the B-classification for histopathological categorization according to EUSOMA, European Society of Breast Cancer Specialists²⁴;
- 5 estrogen receptor (ER), progesterone receptor (PgR), Ki67, and HER2 status²⁵.
- 6 additional useful information can be provided:
- 7 presence and percentage of tumor-infiltrating lymphocytes (TILs), particularly in HER2+ and triple-negative breast cancer (TNBC);
- 8 tumor cellularity;
- 9 presence of lymph-vascular invasion (LVI);
- 10 presence of tumor necrosis;
- 11 characteristics of the DCIS (e.g. pattern, nuclear grade).

Pathological evaluation after neoadjuvant therapy

Goal: To define the presence and degree of pathological response along with the biological characteristics of any residual tumor (Fig. 1).

CHECK-IN OF THE SURGICAL SAMPLES

The check-in criteria are the same as those for standard surgical samples, as defined by SOPs¹⁷⁻¹⁹.

In the request form for the pathology laboratory, the clinician should report specific data:

- 1 NAT protocol adopted;
- 2 clinical staging before and after the treatment;
- 3 pre-NAT diagnosis and biomarkers status;
- 4 size and location of any residual lesion and/or presence of metastatic lymph nodes;
- 5 location and type of marks on the tumor (i.e. surgical clips, charcoal, gel);
- 6 presence of microcalcifications;
- 7 orientation of the surgical sample.

MACROSCOPIC EXAMINATION

Breast samples

The surgical material should be managed according to ministerial guidelines regarding the traceability, collection, transport, and storage of cells and tissues for diagnostic investigations of Pathological Anatomy Laboratories^{18,26-28}. In particular, the cold ischemic time (i.e. time from the post-surgical tissue cooling for storage/transportation to the start of formalin fixation of the specimen) and formalin fixation should be monitored. The macroscopic examination and sampling should be carried out only after the consistency has been double-checked, following SOPs. It is essential to macroscopi-

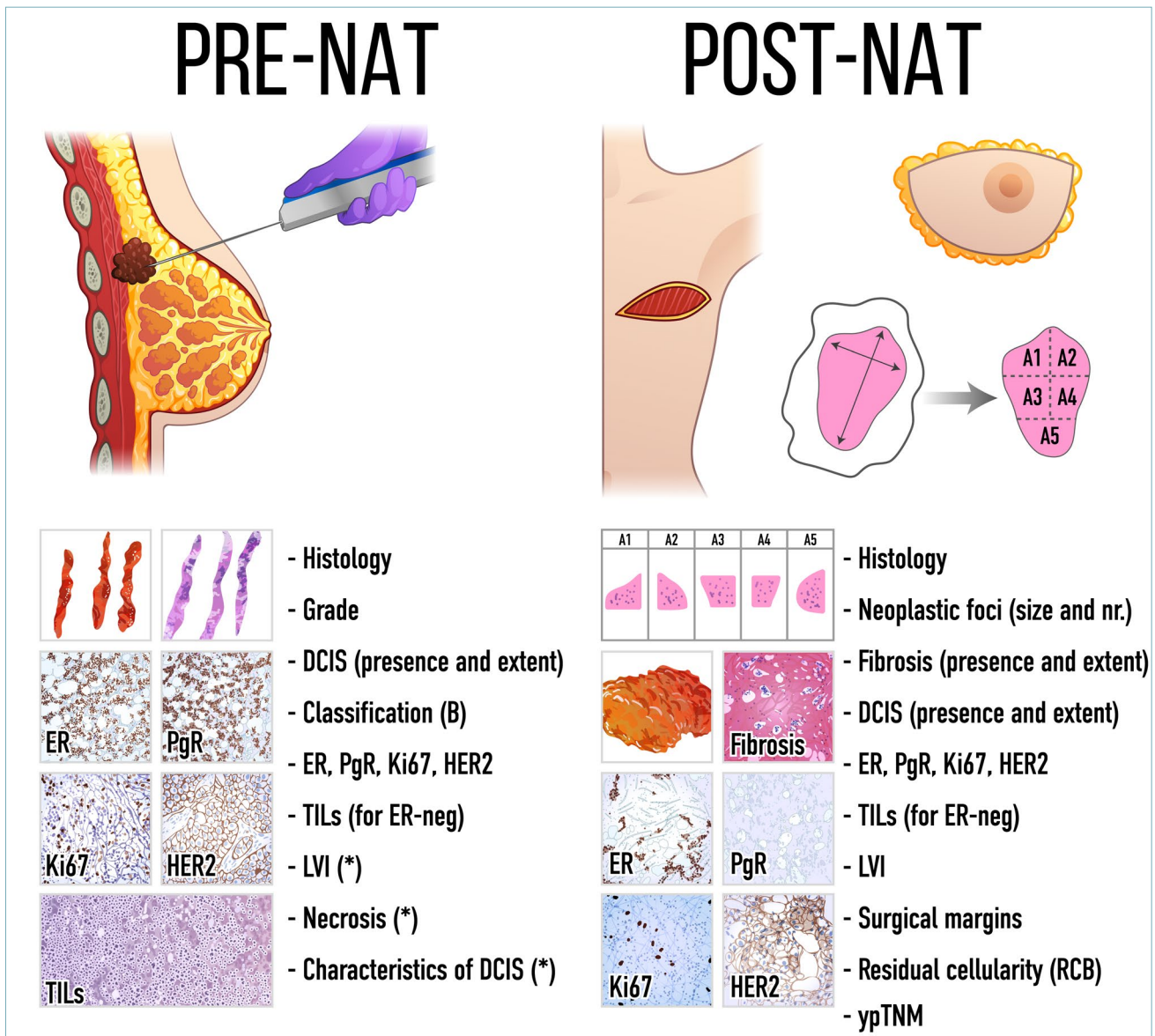


Figure 1. Schematic representation of the different tasks for the pathological handling of pre- and post-NAT breast cancer samples. NAT, neoadjuvant therapy; DCIS, ductal carcinoma in situ; ER, estrogen receptor; PgR, progesterone receptor; TILs, tumor-infiltrating lymphocytes; neg, negative; LVI, lymphovascular invasion.

cally identify and describe the extension of the tumor bed and possibly the number of any residual neoplastic foci^{15,29}. X-ray of the surgical specimen may be of help because tumor microcalcifications are not eliminated by chemotherapy³⁰. It is advisable to carry out sampling with the help of radiograms and/or pre- and post-therapy magnetic resonance imaging (MRI) data. The residual disease may macroscopically appear as a nodular sclerotic area or as multiple foci within an edematous and/or sclerotic area. All lesions should be described, mapped, measured, and sampled; if the sur-

gical sample is small, it should be wholly included and analyzed. The identification of the tumor bed and the evaluation of its extent might be challenging, appearing as an area with poorly defined contours, of generally decreased consistency, centrally of edematous and / or fibrous appearance³¹. Extensive sampling and mapping of the area are required, using standard sections or macro-sections, providing a correlation with imaging features, and recording the topography of the samples within the tumor bed^{29,32}. In case the tumor bed has not been completely analyzed after initial examination,

it is recommended to carry out additional sampling^{12,33}. In the case of BCS, the surgical margins should be carefully examined and sampled. If present, the nipple-areola complex should always be examined. For cT4b tumors, the skin should be analyzed and included (with multiple samples for cT4b).

Axillary lymph nodes

Axillary lymph nodes (ALN) may develop NAT-induced alterations, with possible numerical reduction and/or fibrotic involution³⁴. For this analysis, it is recommended to follow SOPs³⁵⁻³⁷. The eventual presence of marks on pre-NAT pathologic lymph nodes in case of targeted axillary dissection (TAD) should be reported by the clinician in the request form for the pathology laboratory³⁴. This procedure consists of the selective localization and removal of marked nodes³⁸.

SENTINEL LYMPH NODE

The sentinel lymph node(s) (SLN) procedure after NAT is standard practice, irrespective of the clinical status of the lymph nodes^{14,39,40}. It should be noted, however, that the rate of false-negative results is significant, ranging from 5% to 16% using double and single marking of the nodes, respectively⁴¹. For this reason, it is advised to examine the SLN on formalin-fixed paraffin-embedded (FFPE) samples⁴². Molecular examination using the One-Step Nucleic Acid Amplification (OSNA) method is not recommended because this assay is not designed to identify minimal lymph node involvement and does not give any information on histology^{43,44}. Data regarding presence and type of residual disease (e.g. macrometastasis, micrometastasis, isolated tumor cells), presence and extent of extranodal extension of the metastasis, presence, and extent of fibrosis should be provided in the report because they are relevant for the evaluation of the pathological response according to different classification systems⁴⁵⁻⁴⁸.

HISTOLOGICAL EXAMINATION

Breast samples

On microscopic examination, the tumor bed may present as an area of vascularized hyalinization, with deposits of foamy macrophages, lymphocytes, and hemosiderin-laden macrophages, in absence of normal ductal and lobular structures. Edema, necrosis, and calcifications may be present. In cases of complete absence of pathological response, the report is made following the standard recommendations for non-NAT samples.

In cases of partial pathological response, the pathology report should include:

- 1 histological type;
- 2 size and possibly the number of residual cancer foci;
- 3 presence of fibrosis;
- 4 presence of LVI, which might be the only residual disease in some cases;
- 5 presence, extent, and features of any DCIS component;
- 6 status of the surgical margins;
- 7 pathological staging according to the most recent TNM edition;
- 8 residual tumor cellularity according to different classification systems⁴⁵⁻⁴⁸;
- 9 pathologic staging according to the latest TNM edition.

Re-testing of ER, PgR, Ki-67, and HER2 status is recommended in case of TNBC or an equivocal result on pre-NAT core biopsy, pre-NAT biopsy performed in another Institution, heterogeneous tumor, or multiple tumors with different morphology, and absence of pathological response. Additional useful information includes TILs in HER2+ or TNBC, presence of perineural invasion, and grade. In particular, cytotoxic therapy can induce cellular and nuclear atypia; therefore, assessment of post-NAT tumor grade can be performed only if pretreatment biopsy samples are available for comparison⁴⁹.

In cases of pathological complete response, the pathology report should include:

- 1 presence and amount of fibrosis;
- 2 presence and features of any DCIS component;
- 3 status of the surgical margins;
- 4 pathologic staging according to the latest TNM edition.

Axillary lymph nodes

In lymph nodes, regression areas occur with fibrosis in which foamy macrophages and/or hemosiderin-laden macrophages may be present^{44,50-52}. Immunohistochemical staining for cytokeratins might help the identification of any residual lymph node disease. The following information should be reported:

- 1 the number of lymph nodes examined;
- 2 the number of lymph nodes with residual disease and extent of residual disease (e.g. macrometastases, micrometastases, isolated tumor cells);
- 3 the presence and the extent of extracapsular invasion;
- 4 the presence of lymph nodes with fibrosis in the absence of residual disease;
- 5 pathologic staging according to the latest TNM edition.

Final remarks

With the steady increase in the number of patients eligible for NAT, it is more and more important to harmonize how tumor response is assessed by pathologists^{15,16}. Macroscopic evaluation of surgical samples in the post-NAT setting, the extent of sampling for histology, and microscopic examination require a different approach compared to that after primary surgery. Pathologists must be fully aware of the recommended procedures for an accurate assessment of tumor response to NAT, including the evaluation of all the relevant parameters that correlate with long-term prognosis and inform the subsequent adjuvant interventions. Another important aspect that warrants particular attention is the role of BCS in these patients^{4,53,54}. Indeed, this approach leads not only better overall prognosis, but also to improvement of the esthetic result, reduction of psychological burden, lower incidence of post-surgical complications, reduction in time of execution of the intervention (and anesthesia), cost-effectiveness for the National Health System, and ultimately improving the health-related quality of life of breast cancer survivors^{7,8,55-59}. In the NAT setting, close collaboration of pathologists, oncologists, surgeons, and radiologists within the multidisciplinary team is essential to ensure the best possible management of breast cancer patients.

CONFLICT OF INTEREST

The Authors declare no conflict of interest.

References

- Redden MH, Fuhrman GM. Neoadjuvant chemotherapy in the treatment of breast cancer. *Surg Clin North Am* 2013;93:493-499. <https://doi.org/10.1016/j.suc.2013.01.006>
- National Comprehensive Cancer Network. NCCN Clinical Practice Guidelines in Oncology - Breast Cancer Version 4.2020.
- Greenwell K, Hussain L, Lee D, et al. Complete pathologic response rate to neoadjuvant chemotherapy increases with increasing HER2/CEP17 ratio in HER2 overexpressing breast cancer: analysis of the National Cancer Database (NCDB). *Breast cancer research and treatment* 2020;181:249-254. <https://doi.org/10.1007/s10549-020-05599-1>
- Franceschini G, Di Leone A, Natale M, et al. Conservative surgery after neoadjuvant chemotherapy in patients with operable breast cancer. *Ann Ital Chir* 2018;89:290.
- Curigliano G, Burstein HJ, Winer EP, et al. De-escalating and escalating treatments for early-stage breast cancer: the St. Gallen International Expert Consensus Conference on the Primary Therapy of Early Breast Cancer 2017. *Ann Oncol* 2017;28:1700-1712. <https://doi.org/10.1093/annonc/mdx308>
- Labrosse J, Osdoit M, Hamy A-S, et al. Adjuvant chemotherapy for breast cancer after preoperative chemotherapy: A propensity score matched analysis. *PLOS ONE* 2020;15:e0234173. <https://doi.org/10.1371/journal.pone.0234173>
- Bartsch R, Bergen E, Galid A. Current concepts and future directions in neoadjuvant chemotherapy of breast cancer. *Memo* 2018;11:199-203. <https://doi.org/10.1007/s12254-018-0421-1>
- Invernizzi M, Kim J, Fusco N. Editorial: Quality of life in breast cancer patients and survivors. *Frontiers in Oncology* 2020;10:620574. <https://doi.org/10.3389/fonc.2020.620574>
- Dieci MV, Radosevic-Robin N, Fineberg S, et al. Update on tumor-infiltrating lymphocytes (TILs) in breast cancer, including recommendations to assess TILs in residual disease after neoadjuvant therapy and in carcinoma in situ: a report of the International Immuno-Oncology Biomarker Working Group on Breast Cancer. *Semin Cancer Biol* 2018;52:16-25. <https://doi.org/10.1016/j.semcancer.2017.10.003>
- Hamy AS, Lam GT, Laas E, et al. Lymphovascular invasion after neoadjuvant chemotherapy is strongly associated with poor prognosis in breast carcinoma. *Breast Cancer Res Treat* 2018;169:295-304. <https://doi.org/10.1007/s10549-017-4610-0>
- Invernizzi M, Corti C, Lopez G, et al. Lymphovascular invasion and extranodal tumour extension are risk indicators of breast cancer related lymphoedema: an observational retrospective study with long-term follow-up. *BMC cancer* 2018;18:935. <https://doi.org/10.1186/s12885-018-4851-2>
- Korde LA, Somerfield MR, Carey LA, et al. Neoadjuvant chemotherapy, endocrine therapy, and targeted therapy for breast cancer: ASCO Guideline. *J Clin Oncol* 2021;Jco2003399. <https://doi.org/10.1200/jco.20.03399>
- Yau C, Osdoit M, van der Noordaa M, et al. Residual cancer burden after neoadjuvant chemotherapy and long-term survival outcomes in breast cancer: a multicentre pooled analysis of 5161 patients. *Lancet Oncol* 2022;23:149-160. [https://doi.org/10.1016/S1470-2045\(21\)00589-1](https://doi.org/10.1016/S1470-2045(21)00589-1). Epub 2021 Dec 11.
- Cerbelli B, Botticelli A, Pisano A, et al. Breast cancer subtypes affect the nodal response after neoadjuvant chemotherapy in locally advanced breast cancer: Are we ready to endorse axillary conservation? *Breast J* 2019;25:273-277. <https://doi.org/10.1111/tbj.13206>
- Viale G, Fusco N. Pathology after neoadjuvant treatment - How to assess residual disease. *Breast* 2021;S0960-9776(21)00990-5. <https://doi.org/10.1016/j.breast.2021.11.009>
- Guerini-Rocco E, Botti G, Foschini MP, et al. Role and evaluation of pathologic response in early breast cancer specimens after neoadjuvant therapy: consensus statement. *Tumori* 2021;3008916211062642. <https://doi.org/10.1177/03008916211062642>
- Angerilli V, Galuppini F, Pagni F, et al. The role of the pathologist in the next-generation era of tumor molecular characterization. 2021;11:339. <https://doi.org/10.3390/diagnostics11020339>
- Berrino E, Annaratone L, Miglio U, et al. Cold formalin fixation guarantees DNA Integrity in formalin fixed paraffin embedded tissues: premises for a better quality of diagnostic and experimental pathology with a specific impact on breast cancer. *Fron Oncol* 2020;10:173. <https://doi.org/10.3389/fonc.2020.00173>
- Fusco N, Ragazzi M, Sajjadi E, et al. Assessment of estrogen receptor low positive status in breast cancer: implications for pathologists and oncologists. *Histol Histopathol* 2021;36:1235-1245. <https://doi.org/10.14670/hh-18-376>
- Lester SC. *Manual of surgical pathology* Philadelphia: Elsevier Saunders 2010.
- WHO Classification of Tumours Editorial Board. *Breast Tumours: WHO Classification of Tumours* 2019. 5th ed. Vol. 2. Lyon: IARC Press 2019.
- Cserni G. Histological type and typing of breast carcinomas and the WHO classification changes over time. *Pathologica* 2020;112:25-41. <https://doi.org/10.32074/1591-951x-120>

- 23 Rakha EA, Reis-Filho JS, Baehner F, et al. Breast cancer prognostic classification in the molecular era: the role of histological grade. *Breast cancer research: BCR* 2010;12:207. <https://doi.org/10.1186/bcr2607>
- 24 Cardoso F, Cataliotti L, Costa A, et al. European Breast Cancer Conference manifesto on breast centres/units. *Eur J Cancer* 2017;72:244-250. <https://doi.org/10.1016/j.ejca.2016.10.023>
- 25 Goldhirsch A, Winer EP, Coates AS, et al. Personalizing the treatment of women with early breast cancer: highlights of the St Gallen International Expert Consensus on the primary therapy of early breast cancer 2013. *Ann Oncol* 2013;24:2206-2223. <https://doi.org/10.1093/annonc/mdt303>
- 26 Bussolati G, Annaratone L, Maletta F. The pre-analytical phase in surgical pathology. *Recent Results Cancer Res* 2015;199:1-13. https://doi.org/10.1007/978-3-319-13957-9_1
- 27 Allison KH, Hammond MEH, Dowsett M, et al. Estrogen and Progesterone Receptor Testing in Breast Cancer: ASCO/CAP Guideline Update. *J Clin Oncol* 2020;38:1346-1366. <https://doi.org/10.1200/jco.19.02309>
- 28 Costarelli L, Rizzo A, Bortol M, et al. Pre-analytics, a national survey of Senonetwork Italia breast centers: Much still to do ahead. *European Journal of Surgical Oncology* 2021;47:240-244. <https://doi.org/10.1016/j.ejso.2020.08.029>
- 29 Bossuyt V, Provenzano E, Symmans WF, et al. Recommendations for standardized pathological characterization of residual disease for neoadjuvant clinical trials of breast cancer by the BIG-NABCG collaboration. *Ann Oncol* 2015;26:1280-1291. <https://doi.org/10.1093/annonc/mdv161>
- 30 Guerini-Rocco E, Fusco N. Premalignant and preinvasive lesions of the breast. In: Veronesi U, Goldhirsh A, Veronesi P, et al., eds. *Breast cancer: innovations in research and management*. Springer International Publishing 2017, Vol. 1, pp. 103-120.
- 31 Cortazar P, Geyer CE. Pathological complete response in neoadjuvant treatment of breast cancer. *Ann Surg Oncol* 2015;22:1441-1446. <https://doi.org/10.1245/s10434-015-4404-8>
- 32 Potter DA, Herrera-Ponzanelli CA, Hinojosa D, et al. Recent advances in neoadjuvant therapy for breast cancer. *Fac Rev* 2021;10:2. <https://doi.org/10.12703/r/10-2>
- 33 Viale G. Characterization and clinical impact of residual disease after neoadjuvant chemotherapy. *Breast* 2013;22:S88-S91. <https://doi.org/10.1016/j.breast.2013.07.016>
- 34 Man V, Kwong A. Different strategies in marking axillary lymph nodes in breast cancer patients undergoing neoadjuvant medical treatment: a systematic review. *Breast Cancer Res Treat* 2021;186:607-615. <https://doi.org/10.1007/s10549-021-06118-6>
- 35 Fitzgibbons P, Connolly J, Bose S, Pathologists, C.o.A. Protocol for the examination of resection specimens from patients with invasive carcinoma of the breast. *College of American Pathologists. Version: Breast Invasive Resection 2020;4.4.0.*
- 36 Michelotti A, Invernizzi M, Lopez G, et al. Tackling the diversity of breast cancer related lymphedema: perspectives on diagnosis, risk assessment, and clinical management. *Breast* 2019;44:15-23. <https://doi.org/10.1016/j.breast.2018.12.009>
- 37 Racz JM, Caudle AS. Sentinel node lymph node surgery after neoadjuvant therapy: principles and techniques. *Ann Surg Oncol* 2019;26:3040-3045. <https://doi.org/10.1245/s10434-019-07591-6>
- 38 Caudle AS, Yang WT, Krishnamurthy S, et al. Improved Axillary evaluation following neoadjuvant therapy for patients with node-positive breast cancer using selective evaluation of clipped nodes: implementation of targeted axillary dissection. *J Clin Oncol* 2016;34:1072-1078. <https://doi.org/10.1200/jco.2015.64.0094>
- 39 Geng C, Chen X, Pan X, et al. The Feasibility and accuracy of sentinel lymph node biopsy in initially clinically node-negative breast cancer after neoadjuvant chemotherapy: a systematic review and meta-analysis. *PLoS One* 2016;11:e0162605. <https://doi.org/10.1371/journal.pone.0162605>
- 40 Fu J-F, Chen H-L, Yang J, et al. Feasibility and accuracy of sentinel lymph node biopsy in clinically node-positive breast cancer after neoadjuvant chemotherapy: a meta-analysis. *PLoS One* 2014;9:e105316. <https://doi.org/10.1371/journal.pone.0105316>
- 41 Boileau JF, Poirier B, Basik M, et al. Sentinel node biopsy after neoadjuvant chemotherapy in biopsy-proven node-positive breast cancer: the SN FNAC study. *J Clin Oncol* 2015;33:258-264. <https://doi.org/10.1200/jco.2014.55.7827>
- 42 Wapnir IL, Khan A. Current strategies for the management of locoregional breast cancer recurrence. *Oncology (Williston Park)* 2019;33:19-25.
- 43 Shigematsu H, Ozaki S, Yasui D, et al. Comparison of CK-IHC assay on serial frozen sections, the OSNA assay, and in combination for intraoperative evaluation of SLN metastases in breast cancer. *Breast Cancer* 2018;25:191-197. <https://doi.org/10.1007/s12282-017-0811-y>
- 44 Gandhi A, Coles C, Makris A, et al. Axillary surgery following neoadjuvant chemotherapy - Multidisciplinary guidance from the Association of Breast Surgery, Faculty of Clinical Oncology of the Royal College of Radiologists, UK Breast Cancer Group, National Coordinating Committee for Breast Pathology and British Society of Breast Radiology. *Clin Oncol (R Coll Radiol)* 2019;31:664-668. <https://doi.org/10.1016/j.clon.2019.05.021>
- 45 Gooch J, King TA, Eaton A, et al. The extent of extracapsular extension may influence the need for axillary lymph node dissection in patients with T1-T2 breast cancer. *Ann Surg Oncol* 2014;21:2897-2903. <https://doi.org/10.1245/s10434-014-3752-0>
- 46 Nottegar A, Veronese N, Senthil M, et al. Extra-nodal extension of sentinel lymph node metastasis is a marker of poor prognosis in breast cancer patients: a systematic review and an exploratory meta-analysis. *Eur J Surg Oncol* 2016;42:919-925. <https://doi.org/10.1016/j.ejso.2016.02.259>
- 47 Pinder SE, Rakha EA, Purdie CA, et al. Macroscopic handling and reporting of breast cancer specimens pre- and post-neoadjuvant chemotherapy treatment: review of pathological issues and suggested approaches. *Histopathology* 2015;67:279-293. <https://doi.org/10.1111/his.12649>
- 48 MD Anderson Cancer Center - Breast Cancer Residual Cancer Burden Calculator, Pathologic Evaluation of RCB in Breast Specimens. Available online: <https://www.mdanderson.org/for-physicians/clinical-tools-resources/clinical-calculators/residual-cancer-burden.html> (accessed on 27/09/2021).
- 49 Penault-Llorca F, Radosevic-Robin N. Biomarkers of residual disease after neoadjuvant therapy for breast cancer. *Nat Rev Clin Oncol* 2016;13:487-503. <https://doi.org/10.1038/nrclinonc.2016.1>
- 50 The American Society of Breast Surgeons, Consensus Guideline on the Management of the Axilla in Patients With Invasive/In-Situ Breast Cancer. 2019.
- 51 Moo TA, Edelweiss M, Hajiyeva S, et al. Is low-volume disease in the sentinel node after neoadjuvant chemotherapy an indication for axillary dissection? *Ann Surg Oncol* 2018;25:1488-1494. <https://doi.org/10.1245/s10434-018-6429-2>
- 52 Cavalcante FP, Millen EC, Zerwes FP, et al. Role of Axillary surgery after neoadjuvant chemotherapy. *JCO Glob Oncol* 2020;6:238-241. <https://doi.org/10.1200/jgo.19.00351>
- 53 Blundo C, Giroda M, Fusco N, et al. Early Breast Cancers during pregnancy treated with breast-conserving surgery in the first trimester of gestation: A feasibility study. *Front Oncol* 2021;11:723693. <https://doi.org/10.3389/fonc.2021.723693>
- 54 Schaeffgen B, Funk A, Sinn HP, et al. Does conventional specimen radiography after neoadjuvant chemotherapy of breast cancer help

- to reduce the rate of second surgeries? *Breast Cancer Res Treat* 2022;191:589-598. <https://doi.org/10.1007/s10549-021-06466-3>
- ⁵⁵ Choi M, Park YH, Ahn JS, et al. Evaluation of pathologic complete response in breast cancer patients treated with neoadjuvant chemotherapy: experience in a single institution over a 10-year period. *J Pathol Transl Med* 2017;51:69-78. <https://doi.org/10.4132/jptm.2016.10.05>
- ⁵⁶ Invernizzi M, de Sire A, Venetis K, et al. Quality of Life interventions in breast cancer survivors: state of the art in targeted rehabilitation strategies. *Anticancer Agents Med Chem* 2022;22:801-810. <https://doi.org/10.2174/1871520621666210609095602>
- ⁵⁷ Sunilkumar MM, Finni CG, Lijimol AS, et al. Health-related suffering and palliative care in breast cancer. *Curr Breast Cancer Rep* 2021;1-6. <https://doi.org/10.1007/s12609-021-00431-1>
- ⁵⁸ Nardin S, Mora E, Varughese FM, et al. Breast cancer survivorship, quality of life, and late toxicities. *Front Oncol* 2020;10:864. <https://doi.org/10.3389/fonc.2020.00864>
- ⁵⁹ Madigan LI, Dinh P, Graham JD. Neoadjuvant endocrine therapy in locally advanced estrogen or progesterone receptor-positive breast cancer: determining the optimal endocrine agent and treatment duration in postmenopausal women-a literature review and proposed guidelines. *Breast Cancer Res* 2020;22:77. <https://doi.org/10.1186/s13058-020-01314-6>