


CASE REPORT

Ventricular tachycardia storm originating from interventricular septum successfully treated with surgical cryoablation with electroanatomic and electrophysiological mapping before dual valve replacement

Iwanari Kawamura MD¹  | Seiji Fukamizu MD, PhD¹ | Satoshi Miyazawa MD¹ |
Rintaro Hojo MD¹ | Fusahiko Ito MD² | Masazumi Watanabe MD² |
Mitsuhiro Nishizaki MD, PhD³ | Harumizu Sakurada MD, PhD⁴ |
Masayasu Hiraoka MD, PhD, FHRS⁵

¹Department of Cardiology, Tokyo Metropolitan Hiroo Hospital, Tokyo, Japan

²Department of Cardiovascular Surgery, Tokyo Metropolitan Hiroo Hospital, Tokyo, Japan

³Odawara Cardiovascular Hospital, Kanagawa, Japan

⁴Tokyo Metropolitan Health and Medical Treatment Corporation Ohkubo Hospital, Tokyo, Japan

⁵Tokyo Medical and Dental, University, Tokyo, Japan

Correspondence

Iwanari Kawamura, Department of Cardiology, Tokyo Metropolitan Hiroo Hospital, Tokyo, Japan.
Email: iwanari_k0829@yahoo.co.jp

Abstract

A 58-year-old man with dilated cardiomyopathy was admitted with heart failure. He had a history of two catheter ablation procedures for ventricular tachycardia (VT) originating from the intraventricular septum (IVS). Before dual valve replacement (DVR), he suffered a VT storm. An electrophysiological study revealed an extended low-voltage area at the IVS with the exit of the induced VT at the anterior side. Radiofrequency application was performed at the VT exit as a landmark for surgical cryoablation (SA). During the DVR, SA was performed at the IVS using this landmark. After SA, the patient had no ventricular tachyarrhythmia.

KEYWORDS

catheter ablation, electrical storm, nonischemic cardiomyopathy, surgical cryoablation, ventricular tachycardia

1 | INTRODUCTION

Catheter ablation has proved effective for treating ventricular tachycardia (VT). However, after dual valve replacement (DVR), neither the atrial transeptal nor the retrograde aortic approach to the left ventricular endocardium for catheter ablation is feasible. We report a case of successful surgical cryoablation (SA) of a VT storm originating from the intraventricular septum (IVS), guided by preoperative electrophysiological mapping.

2 | CASE REPORT

A 58-year-old man diagnosed with dilated cardiomyopathy was admitted to our hospital due to heart failure. He had previously

undergone catheter ablations twice for sustained VT originating from IVS. A cardiac resynchronization therapy defibrillator (CRT-D) had been implanted for his heart failure and complete atrial-ventricular block between the first and second sessions. DVR was planned for his valvular disease. However, before the operation, he suffered a VT storm that was terminated using antitachycardia pacing of the CRT-D. We decided to perform an electrophysiological study (EPS) and modify the substrate using SA during surgery.

After obtaining informed consent from the patient, the EPS was performed. The voltage map under ventricular pacing showed an extended low-voltage area (LVA) at the IVS and delayed potentials were obtained at the posteroseptum. Clinical VT (right bundle branch block, inferior axis, cycle length 540 ms) was easily induced using catheter stimulation. A perfect pacemap for the clinical VT was

This is an open access article under the terms of the Creative Commons Attribution-NonCommercial License, which permits use, distribution and reproduction in any medium, provided the original work is properly cited and is not used for commercial purposes.

© 2017 The Authors. *Journal of Arrhythmia* published by John Wiley & Sons Australia, Ltd on behalf of the Japanese Heart Rhythm Society.

obtained at the anteroseptum (pink tag in Figure). At these points, the mid-diastolic potential was obtained during VT; however, the postpacing interval could not be evaluated due to the termination of VT during pacing. The latency of S-QRS was longer in the mid-LVA than in the anterior edge of LVA, so the VT circuit was thought to be from the mid-LVA to the edge of anterior side (Figure 1). Radiofrequency was applied at the exit of the VT as a landmark for the SA.

SA was performed 5 days after the EPS via midline sternotomy while on pump. Before the operation, the surgeon was informed that the target region was the extended LVA at the IVS and VT exit at the anteroseptum using a 3D mapping system, which was constructed during EPS. During the operation, the marking RF point was easily visible to the surgeon and LVA was also distinguished from another area. After removing the native aortic valve, cryotherapy was applied from ascending aorta to the target areas using the Cardiac Cryosurgical System (CCS-200; Frigitronics, USA) with two differential types of cryoablation probes. Cryotherapy was applied three times for 120 seconds, achieving a minimum temperature of -60°C , before the replacement of aortic valve (Figure 2).

He was discharged 26 days after surgery, VT-free. No ventricular tachyarrhythmia has been observed for 9 months.

3 | DISCUSSION

Patients with nonischemic cardiomyopathy (NICM), especially dilated cardiomyopathy, have a high prevalence of VT recurrence after catheter ablation.¹ In patients with NICM and VT that is refractory to conventional therapies, SA guided by preoperative electrophysiological mapping may be useful.² Liang et al³ showed that the VT-free survival rate after 1 year was 72.5% in patients refractory to radiofrequency catheter ablation who underwent SA. In their cohort, 6 of 20 patients had an electrical storm, and only one had recurrent VT storm. In patients who suffer from refractory VTs, epicardial evaluation needs to be considered. However, in this case, LVA was oriented at the IVS and the exit of the VT circuit was thought to be the anterior side of IVS. Thus, the epicardium was not evaluated in this session.

After DVR, transcatheter ethanol ablation and direct percutaneous left ventricular puncture are reported in patients.^{4,5} However, direct percutaneous left ventricular puncture has a relatively high risk of complications, and transcatheter ethanol ablation requires anatomical accessibility. In our case, SA treatment for a VT storm originating in the IVS was useful. SA needs to be considered when a patient suffers sustained VT prior to surgery.

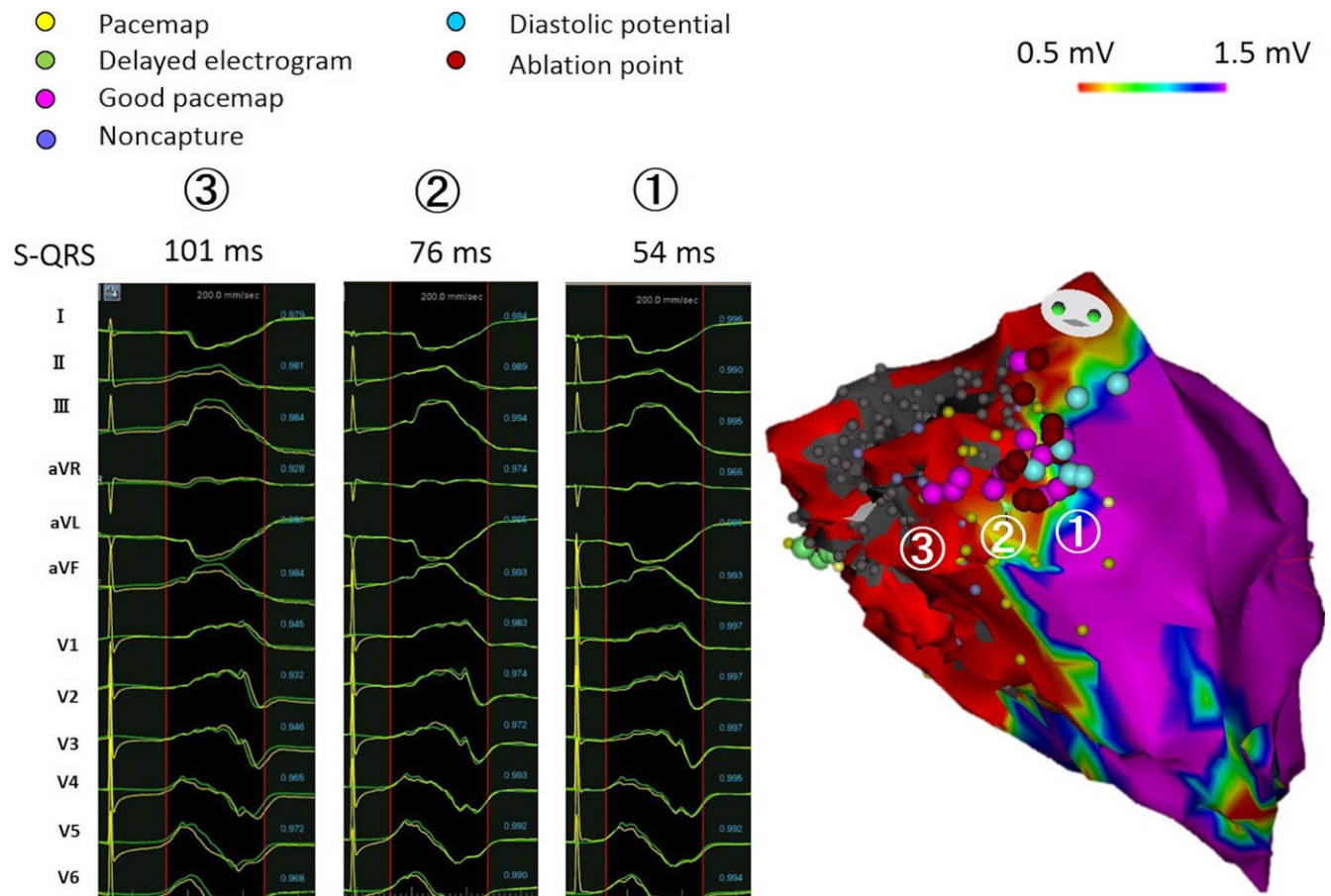


FIGURE 1 The voltage map shows an extended low-voltage area at intraventricular septum. The clinical VT exit was thought to be at the anterior side of the intraventricular septum

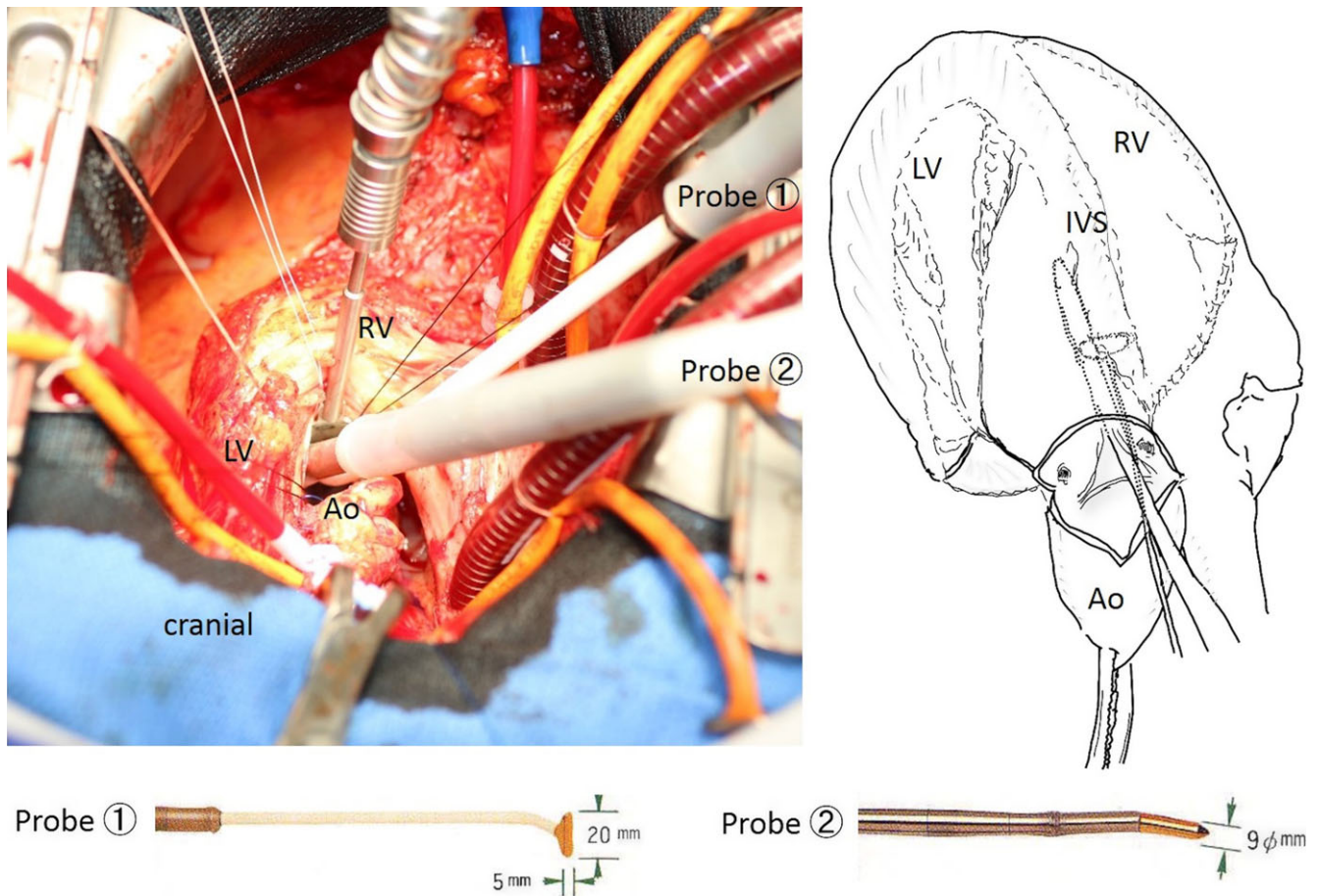


FIGURE 2 Surgical cryoablation (2 min, -60°C) during DVR with midline sternotomy using two types of cryoablation probes

4 | CONCLUSION

We report a case of a patient with an electrical VT storm that originated in the IVS before double valve replacement. SA guided by preoperative electroanatomic and electrophysiological mapping suppressed VT recurrence.

CONFLICT OF INTERESTS

Authors declare no conflict of interests for this article.

ORCID

Iwanari Kawamura  <http://orcid.org/0000-0002-6431-9278>

REFERENCES

- Goya M, Fukunaga M, Hiroshima K, et al. Long-term outcomes of catheter ablation of ventricular tachycardia in patients with structural heart disease. *J Arrhythm*. 2015;31:22–8.
- Anter E, Hutchinson MD, Deo R, et al. Surgical ablation of refractory ventricular tachycardia in patients with nonischemic cardiomyopathy. *Circ Arrhythm Electrophysiol*. 2011;4:494–500.
- Liang JJ, Betensky BP, Muser D, et al. Long-term outcome of surgical cryoablation for refractory ventricular tachycardia in patients with non-ischemic cardiomyopathy. *Europace*. 2017; 1–12.
- Baldinger SH, Kumar S, Enriquez AD, et al. Options for ventricular tachycardia ablation after double valve replacement. *Heart Rhythm Case Rep*. 2015;1:163–6.
- Hsieh CHC, Thomas SP, Ross DL, et al. Direct transthoracic access to the left ventricle for catheter ablation of ventricular tachycardia. *Circ Arrhythm Electrophysiol*. 2010;3:178–85.

How to cite this article: Kawamura I, Fukamizu S, Miyazawa S, et al. Ventricular tachycardia storm originating from interventricular septum successfully treated with surgical cryoablation with electroanatomic and electrophysiological mapping before dual valve replacement. *J Arrhythmia*. 2018;34:71–73. <https://doi.org/10.1002/joa3.12020>