



Progressive increases in creatine kinase activity in an anorexic cat with necrotising myopathy

Joyce LY Chow¹ , Amy Lam¹ and G Diane Shelton²

Journal of Feline Medicine and Surgery Open Reports
1–4

© The Author(s) 2021

Article reuse guidelines:

sagepub.com/journals-permissions

DOI: 10.1177/20551169211031790

journals.sagepub.com/home/jfmsopenreports

This paper was handled and processed by the European Editorial Office (ISFM) for publication in *JFMS Open Reports*



Abstract

Case summary A 5-year-old castrated male domestic shorthair cat with weight loss and reduced appetite was evaluated for increased and progressively rising creatine kinase (CK) activity. The cat had recently been diagnosed with hepatic lipidosis. Muscle biopsy and histopathology revealed mild myonecrosis and phagocytosis without obvious inflammatory cell infiltrates. Resolution of necrotising myopathy was observed after a short course of anti-inflammatory prednisolone and nutritional supplementation.

Relevance and novel information This is the first report of a necrotising myopathy in a cat associated with progressively increasing CK activity and decreased appetite. Anorexia in cats has been associated with increased CK activity, but an underlying cause of this CK elevation has only been postulated. Here we document muscle necrosis and muscle stiffness in a cat with anorexia.

Keywords: Myopathy; myonecrosis; necrotising myopathy; creatine kinase; muscle degeneration

Accepted: 21 June 2021

Introduction

Necrotising myopathy (NM) is characterised by myonecrosis, with or without phagocytosis. NM has been diagnosed in people with hypothyroidism, muscular dystrophies, after exposure to myotoxins and as a newly described autoimmune myopathy.^{1–5} NM is a rare clinical diagnosis in small animal medicine but might be under-recognised as muscle biopsies are not a routine diagnostic test.

Cats with myopathy typically have generalised paresis and creatine kinase (CK) activity is variably increased.⁶ Other presenting signs include exercise intolerance, muscle atrophy or hypertrophy, stiff gait and ventroflexion of the neck.⁶ Postural reactions and spinal reflexes are typically normal.⁶ In contrast, increased CK activity does not always indicate primary myopathy because modest-to-marked increases in CK activity can be observed as a non-specific finding in unwell and anorexic cats.^{7,8} High serum CK activity in anorexic cats is postulated to be the result of muscle catabolism rather than muscle necrosis or inflammation.^{7,8} Other artefactual or non-inflammatory myopathic reasons for the elevation of CK include traumatic venepuncture,

haemolysis or hyperbilirubinaemia, iatrogenic muscle trauma and prolonged recumbency.^{7,8} Cats with myopathy often demonstrate non-specific clinical signs and, as CK increases can be variable, a muscle biopsy is required for definitive diagnosis and to direct treatment.

Case description

A 5-year-old castrated male domestic shorthair cat was presented to the referring veterinarian after 3 weeks of marked weight loss (from 9 kg to 7 kg) and reduced appetite. Physical examination was unremarkable. Weakness, reluctance to walk or abnormal gait were not identified on examination. Diagnostic tests performed at the referring veterinary hospital included serial complete blood count (CBC); serial biochemical profiles, including CK

¹Small Animal Specialist Hospital, Sydney, NSW, Australia

²Department of Pathology, School of Medicine, University of California San Diego, La Jolla, CA, USA

Corresponding author:

Joyce LY Chow BVSc, MANZCVS, Small Animal Specialist Hospital, 1 Richardson Place, North Ryde, NSW 2113, Australia
Email: joyce.chow@sashvets.com



Creative Commons Non Commercial CC BY-NC: This article is distributed under the terms of the Creative Commons

Attribution-NonCommercial 4.0 License (<https://creativecommons.org/licenses/by-nc/4.0/>) which permits non-commercial use, reproduction and distribution of the work without further permission provided the original work is attributed as specified on the SAGE and Open Access pages (<https://us.sagepub.com/en-us/nam/open-access-at-sage>).

activity; urinalysis (UA); urine culture; in-house feline leukaemia virus (FeLV) antigen/feline immunodeficiency virus (FIV) antibody testing; toxoplasma IgG and IgM titre (Tasmanian Government Animal Health Laboratory); serial abdominal ultrasound; CT of the thorax and abdomen; exploratory laparotomy; and histopathology of biopsies collected from liver, pancreas, stomach, duodenum, jejunum, ileum, mesenteric lymph node, peritoneal fat and urinary bladder. A fresh liver sample and bile were submitted for aerobic and anaerobic culture. A cystotomy was performed to remove calcium oxalate cystoliths.

Serial CBCs were unremarkable. The main abnormalities noted on the serum biochemical profile included mild elevations in alanine transferase activity (ALT; 104 U/l; reference interval [RI] 1–80) and CK activity (343 U/l [RI <261]). UA revealed a specific gravity of 1.006 and marked haematuria. Urine culture was negative. FeLV antigen/FIV antibody testing and toxoplasma antibody titre were negative. An abdominal ultrasound showed a diffusely hyperechoic liver, an area of hyperechoic fat adjacent to the left kidney and the presence of cystoliths. CT of the chest and abdomen revealed abnormal retroperitoneal fat adjacent to the left kidney. There was mild consolidation of the left cranial lung lobe, most consistent with atelectasis. Liver culture identified a single organism, *Serratia marcescens*, suspected to be a contaminant. The bile culture was negative. Histopathology of the liver, pancreas, gastrointestinal tract, bladder and peritoneum fat revealed diffuse hepatic lipidosis, pancreatic islet amyloidosis, minimal lymphocytic gastritis, mild intestinal villous stunting and mild cystitis.

Over 3 weeks of hospitalisation, the cat received intravenous fluid therapy, multiple antibiotics (marbofloxacin 3.5 mg/kg q24h PO, clindamycin 10.7 mg/kg q12h PO, doxycycline 3.5 mg/kg q12h PO, metronidazole 13.3 mg/kg q12h PO), analgesia (buprenorphine 0.02 mg/kg transmucosal route, gabapentin 3.5 mg/kg q12h PO), anti-nausea and antiemetic (ondansetron 2 mg q12h PO, maropitant 1 mg/kg q24h PO), L-carnitine (42 mg/kg q24h PO), taurine (35 mg/kg q24h PO), vitamin E (1.4 IU/kg PO q24h), S-adenosylmethionine (90 mg/kg q24h PO) and dantrolene (0.35 mg/kg q24h PO). An oesophageal feeding tube was placed uneventfully. The cat remained anorectic with progressive weight loss post-exploratory laparotomy. A definitive cause of the cat's weight loss and decreased appetite was not identified. Hepatic lipidosis was likely due to a negative energy balance caused by anorexia. Serum CK activity progressively increased from 343 U/l on admission to the referring veterinary hospital to 2677 U/l on day 9, 13010 U/l on day 15 and to 8092 U/l on day 17 of hospitalisation (RI <261 U/l). The cat was referred for investigation of progressive increases in CK activity and persistent lethargy.

On presentation (day 22) to the Small Animal Specialist Hospital, Sydney, the cat weighed 7 kg, with a

body condition score of 7/9. The cat had a stiff gait with no obvious ataxia or paresis on examination. Spinal reflexes were within normal limits. The remainder of the physical examination was unremarkable. A repeat serum biochemical profile showed CK of 15,081 U/l (RI 64–4000), AST 291 U/l (RI 2–62) and ALT 166 U/l (RI 19–100). The provisional diagnosis was a primary myopathy and muscle biopsies (fixed and unfixed chilled samples) were collected under general anaesthesia from the right quadriceps and right triceps muscles for histopathology and submitted to the Comparative Neuromuscular Laboratory, University of California in San Diego by a courier service. Pathological diagnosis was an early or mild NM with phagocytosis (Figure 1). Infectious organisms, storage products and inflammation were not identified.

Prednisolone was administered (5 mg PO q24h) and all the other medications were discontinued. The cat was fed a balanced diet via an oesophageal tube to address anorexia and to treat hepatic lipidosis. The cat's appetite and mobility improved within 48 h. It was discharged 8 days after the muscle biopsy procedure. CK activity at the time of discharge was 2855 U/l (RI 64–400). Treatment with anti-inflammatory doses of prednisolone was continued for 5 weeks. CK activity normalised 6 weeks after muscle biopsy collection (2021 U/l [RI 64–400]). The dose of prednisolone was slowly reduced over 6 months. At the 6-month recheck, CK activity was 347 U/l (RI 64–400). At the time of writing (24 months

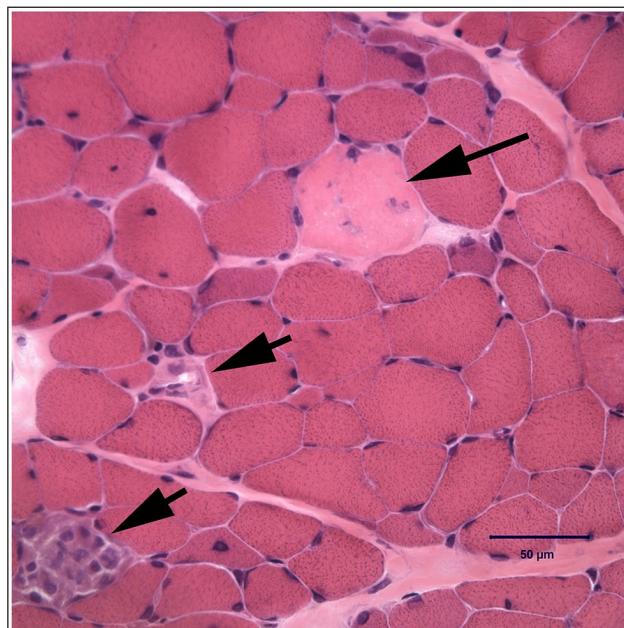


Figure 1 Haematoxylin and eosin-stained cryosection of the triceps muscle from a cat with progressively increasing creatine kinase activity. Pathological changes include light staining necrotic (long-tailed arrow) and necrotic fibres undergoing phagocytosis (short-tailed arrows). Bar = 50 μm

following muscle biopsy), the cat remained clinically well with no recurrence of abnormal CK activity.

Discussion

The original presenting clinical signs to the referring veterinarian were for weight loss and decreased appetite. As far as could be determined, there were no clinical signs of a myopathy reported, including weakness, stiff and stilted gait, or reluctance to jump. Serum CK activity was mildly elevated on the first biochemical analysis and increased progressively over the 3-week period of hospitalisation, despite various supportive treatments. Exploratory laparotomy and tissue biopsies revealed a diagnosis of hepatic lipidosis. Weight loss and anorexia continued and the cat was referred. At the referral hospital there was evidence of a stilted gait, consistent with a myopathy, along with further elevated CK activity. Muscle biopsies collected at this time revealed a mild NM consistent with CK elevation. Despite extensive investigation, the primary cause of anorexia remained unclear. NM in this cat was thought to be a consequence rather than the cause of anorexia.

CK activity is a specific enzyme marker of myofibre damage and frequently used in the diagnosis of muscle diseases.⁹ CK activity is increased in necrotising, inflammatory and dystrophic myopathies, and is usually normal or only mildly increased in non-inflammatory muscle diseases. In addition, as previously reported, CK activities in cats may serve as a marker for assessing and monitoring nutritional status and may be increased in skeletal muscle catabolic states.⁸

Necrotic fibres are pale staining hyaline fibres, faintly coloured with routine staining (Figure 1), and represent a degenerative change. The necrotic fibres frequently undergo phagocytosis. In this cat, histopathology of the quadriceps and triceps muscles revealed mild myonecrosis and phagocytosis. Histopathology did not identify storage products such as glycogen, polysaccharides or neutral triglycerides that would suggest a metabolic aetiology. The pathological changes in the muscle biopsies were not consistent with a form of muscular dystrophy or other specific myopathy. The history of cachexia in this cat, and reports of the effect of anorexia in cats on CK activity, made this degenerative myopathy likely associated with the nutritional status of the cat. In a previous case series, lipidosis was reported in four cats with CK activities ranging from 2529 to 10,361 IU/l, and in 57 cats in a second large series.^{7,8} This case report documents degenerative changes (myonecrosis) in the muscles of an anorexic cat with elevated CK activity.

The rapid response to anti-inflammatory dosages of prednisone, discontinuation of other medications and nutritional supplementation supports the association of anorexia and muscle necrosis. The cat's appetite and mobility improved within 48 h. CK activity at the time

of discharge was decreased to 2855 IU/l (RI 64–400) and normalised by 6 weeks after evaluation.

In human medicine, one form of NM is considered an idiopathic inflammatory myopathy rather than degenerative myopathy.^{2–5,10} Histologically, NM is characterised by myonecrosis, phagocytosis and minimal inflammatory changes.^{2–5,10} The aetiology and pathophysiology are not fully understood, and this form of NM is often associated with different autoantibodies (anti-signal recognition particle antibodies, anti-hydroxymethylglutaryl CoA reductase and anti-synthetase antibodies), connective tissue disease, malignancy, viral infections (eg, HIV), use of statins and trauma.^{3,4,10} Retrospective studies show that the majority of people with immune-mediated NM require two or more immunotherapeutic agents and relapses were common when the corticosteroid dose was reduced.^{3,4} Although we cannot exclude the possibility of immune-mediated NM in this cat, given the relatively low dose of corticosteroid used, and the fact that this cat has been off prednisolone for >2 years without relapse, a diagnosis of a degenerative myopathy was considered most likely.

There is also the potential for toxic or drug-induced myopathy. The actual incidence of drug-induced myopathy in people and veterinary medicine is unclear and is often a diagnosis of exclusion.¹¹ The clinical manifestations of myotoxicity are variable and not necessarily related to a single or multiple pharmaceutical agents.^{12,13} Substances reported to be associated with NM include cholesterol-lowering drugs (HMG-CoA reductase inhibitors [statins]), fibrates, epsilon aminocaproic acid and alcohol.^{11–13} The cat had not received any medication known to cause NM in human medicine; however, given that myonecrosis resolved after discontinuing multiple drugs, it is possible that a combination of decreased appetite and polypharmacy may have resulted in the myonecrosis.

Conclusions

To our knowledge, this is the first reported case documenting progressively increasing CK activity in a cat with anorexia, weight loss, hepatic lipidosis and muscle stiffness. Muscle biopsy documented myonecrosis and ruled out inflammatory, metabolic and other congenital structural myopathies. Discontinuation of a wide range of medications, nutritional support and a return of normal appetite, in addition to treatment with anti-inflammatory doses of prednisolone, resulted in a good clinical outcome in this cat. This case report provides evidence that myonecrosis could be a potential consequence of abnormal nutritional status and anorexia in a cat.

Conflict of interest The authors declared no potential conflicts of interest with respect to the research, authorship, and/or publication of this article.

Funding The authors received no financial support for the research, authorship, and/or publication of this article.

Ethical approval The work described in this manuscript involved the use of non-experimental (owned or unowned) animals. Established internationally recognised high standards ('best practice') of veterinary clinical care for the individual patient were always followed and/or this work involved the use of cadavers. Ethical approval from a committee was therefore not specifically required for publication in JFMS Open Reports. Although not required, where ethical approval was still obtained, it is stated in the manuscript.

Informed consent Informed consent (verbal or written) was obtained from the owner or legal custodian of all animal(s) described in this work (experimental or non-experimental animals, including cadavers) for all procedure(s) undertaken (prospective or retrospective studies). For any animals or people individually identifiable within this publication, informed consent for their use in the publication (verbal or written) was obtained from the people involved.

ORCID iD Joyce LY Chow  <https://orcid.org/0000-0002-2483-4718>

References

- 1 Shelton GD. **Rhabdomyolysis, myoglobinuria, and necrotizing myopathies.** *Vet Clin North Am Small Anim Pract* 2004; 34: 1469–1482.
- 2 Dalakas MC. **Pathophysiology of inflammatory and autoimmune myopathies.** *Press Medicale* 2011; 40: e237–e247.
- 3 Ashton C, Junckerstorff R, Bundell C, et al. **Treatment and outcomes in necrotising autoimmune myopathy: an Australian perspective.** *Neuromuscul Disord* 2016; 26: 734–740.
- 4 Kassardjian CD, Lennon VA, Alfugham NB, et al. **Clinical features and treatment outcomes of necrotizing autoimmune myopathy.** *JAMA Neurol* 2015; 72: 996–1003.
- 5 Liang E and Rastegar M. **Immune-mediated necrotising myopathy: a rare cause of hyperCKaemia.** *BMJ Case Rep* 2018; 2018. DOI: 10.1136/bcr-2017-223870.
- 6 Volk HA, Shihab N and Matiasek K. **Neuromuscular disorders in the cat: clinical approach to weakness.** *J Feline Med Surg* 2011; 13: 837–849.
- 7 Aroch I, Keidar I, Himelstein A, et al. **Diagnostic and prognostic value of serum creatine-kinase activity in ill cats: a retrospective study of 601 cases.** *J Feline Med Surg* 2010; 12: 466–475.
- 8 Fascetti AJ, Mauldin GE and Mauldin GN. **Correlation between serum creatine kinase activities and anorexia in cats.** *J Vet Intern Med* 1997; 11: 9–13.
- 9 Shelton GD. **Routine and specialized laboratory testing for the diagnosis of neuromuscular diseases in dogs and cats.** *Vet Clin Pathol* 2010; 39: 278–295.
- 10 Day JA and Limaye V. **Immune-mediated necrotising myopathy: a critical review of current concepts.** *Semin Arthritis Rheum* 2019; 49: 420–429.
- 11 Pasnoor M, Barohn RJ and Dimachkie MM. **Toxic myopathies.** *Curr Opin Neurol* 2018; 31: 575–582.
- 12 Bronner IM, Hoogendijk JE, Wintzen AR, et al. **Necrotising myopathy, an unusual presentation of a steroid-responsive myopathy.** *J Neurol* 2003; 250: 480–485.
- 13 Dalakas MC. **Toxic and drug-induced myopathies.** *J Neurol Neurosurg Psychiatry* 2009; 80: 832–838.