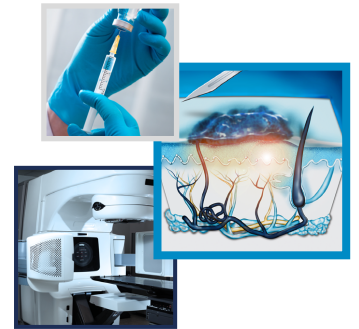



Application of CO₂ laser evaporation in locally advanced melanoma

Otis M Vrieling¹, Schelto Kruijff¹, Barbara L van Leeuwen^{*1} & Jan LN Roodenburg²

¹Department of Surgery, Division of Surgical Oncology, University of Groningen, University Medical Center Groningen, Groningen, The Netherlands

²Department of Oral & Maxillofacial Surgery, University of Groningen, University Medical Center Groningen, Groningen, The Netherlands

*Author for correspondence: Tel.: +315 0361 2317; b.l.van.leeuwen@umcg.nl

Aim: This study aims to investigate the role of CO₂ laser evaporation in the treatment of melanoma patients with satellite or in-transit metastases. **Materials & methods:** Patients who underwent CO₂ laser evaporation were retrospectively included between November 2002 and August 2018. The Sharplan 40C CO₂ laser was used with a high pulse wave mode. Data concerning patient and tumor characteristics, CO₂ laser evaporation and subsequent therapies were collected. **Results:** A total of 26 patients were included. Median duration of local control was 5.5 months. The median number of lesions evaporated per treatment was three (1–16); patients received a median of three (1–19) treatments. **Conclusion:** In a selected group of melanoma patients with satellite or in-transit metastases, CO₂ laser evaporation should be considered as treatment for local control.

First draft submitted: 2 November 2018; Accepted for publication: 18 February 2019; Published online: 18 April 2019

Keywords: CO₂ laser • in-transit • melanoma • metastases • satellite

The incidence rate of cutaneous melanoma is still increasing worldwide, in the USA, an estimate of 91,270 patients will be diagnosed with melanoma in 2018 and approximately 9320 will die from the disease in the same year [1]. When the disease is detected in an early stage and confined to its primary location, cure rates are high [2]. However, metastases are frequently seen.

Locoregional metastases such as cutaneous or subcutaneous metastases are thought to be caused by lymphatic dissemination. Melanoma cells are trapped within the lymphatic vessels and spread between the primary melanoma site and the draining regional lymph nodes [3–5]. Locoregional metastases are historically classified into satellite metastases (<2 cm of the primary tumor) and in-transit metastases (≥2 cm of the primary tumor). Despite this distinction, in clinical practice they are not considered as different entities for treatment or prognosis [2,6].

A substantial number of patients (4–10%) develop satellite or in-transit metastases approximately 16–18 months after local initial excision of the primary tumor [3–5]. Risk factors for the development of satellite or in-transit metastases are Breslow thickness, ulceration, a primary tumor on the lower extremity and a positive sentinel lymph node biopsy [4,5]. Diagnosis is usually clinical since the (sub)cutaneous metastases are often palpable or visible in the skin, thus easy to recognize [7]. Due to ulceration, bleeding, infection and pain, satellite and in-transit metastases can have a significant impact on the patients' quality of life.

The treatment of satellite or in-transit metastases is a challenge, mainly due to the great variation in clinical presentation and the unpredictable behavior of the disease. The appearance can range from very few small (sub)cutaneous lesions to large numbers of bulky lesions distributed over an extremity, the head and neck region or trunk. When satellite or in-transit metastases are limited, surgical resection is the preferred treatment [7–9]. However, in some cases, this is not feasible. In patients with satellite or in-transit metastases located in the head and neck region, a surgical resection can be severely mutilating. Furthermore, in patients with extensive disease distributed over an extremity, surgical resection can be technically challenging, too invasive or might even be impossible. Hyperthermic isolated limb perfusion (HILP) and isolated limb infusion (ILI) are alternative treatment options.

However, both procedures are associated with morbidity and regional toxicity and are therefore not always suitable in patients with multiple comorbidities.

Locoregional metastases are present in Stage III as well as Stage IV disease. In recent years, several novel and successful systemic treatments have been developed with improvement of survival; however, locoregional control cannot always be achieved [10–12]. Growing evidence suggests that concurrent systemic and locoregional therapy enhances efficacy [13,14].

CO₂ laser evaporation is a simple and effective treatment option for satellite or in-transit metastases that can be performed under local or regional anesthesia and can be repeated if new lesions develop [15–18]. Previous research has shown that in selected patients, adequate local control can be achieved with low morbidity rates [18]. The CO₂ laser evaporation might be an attractive treatment alternative in the above-mentioned situations. In this study, we aimed to investigate the role of CO₂ laser evaporation in the treatment of patients with satellite or in-transit metastases, in the era of effective systemic therapy.

Materials & methods

Study design & population

A retrospective study was conducted at the Department of Surgical Oncology of the University Medical Center Groningen (UMCG). The UMCG is a university hospital and tertiary referral center in the northern part of the Netherlands. Melanoma patients with satellite or in-transit metastases, who underwent CO₂ laser evaporation between November 2002 and August 2018, were included in the database. Patients with both American Joint Committee on Cancer Stage III and IV disease were included.

Baseline demographic information was obtained from digital files stored in the electronic database of the hospital including patients' age, gender, medical history, American Society of Anesthesiologists score and primary melanoma characteristics.

Most patients underwent initial treatment of the primary melanoma in hospitals elsewhere and were referred to the UMCG for further treatment. Patients received various combinations of treatment modalities before and/or after laser therapy. Data concerning the duration of each therapy as well as the indication to change therapy were collected. The duration of therapy was defined as the time from the start of a therapy until the start of a subsequent therapy or death of the patient.

Data concerning the CO₂ laser evaporation were retrieved retrospectively and included the number of laser treatments, the number of lesions treated per session, the location of satellite or in-transit metastases and complications.

CO₂ laser evaporation

Lesions with a diameter ≤ 10 mm were deemed eligible for treatment with CO₂ laser evaporation (Figure 1). All patients were treated under local anesthesia at an outpatient clinic by the same expert physician. The Sharplan 40C CO₂ laser was used, with a handpiece or a micromanipulator together with an operation microscope (Zeiss Opmi 1). The treatment was carried out by moving a slightly defocused CO₂ laser spot over the lesion. The spot size was adjusted to the size of the lesion and differed from 0.5–4 mm. Multiple pulses were given until the lesion was completely evaporated. A high pulse wave mode with an output power of 5–10 W was used. The operation microscope with a connected scanning device was especially useful in the head and neck area, achieving a more accurate treatment with minimal collateral damage. The laser beam was used in focus, and the size of the treated area could be programmed from 1–6 mm. By using the laser in focus, there was less carbonization and the results could therefore be better assessed. Postoperatively, the wounds were dressed with Vaseline gauze for 7–14 days. Each lesion was completely evaporated during one CO₂ laser sessions. However, in case of numerous lesions, more CO₂ laser sessions were required. The interval of treatment sessions depended on the number of lesions and recurrence. In some patients, one session was enough, whereas other patients were seen every month.

Statistical analyses

IBM SPSS Statistics, version 22, was used for descriptive statistics. Continuous variables were described as mean with standard deviation or median with interquartile range, and categorical variables as count (n) with percentage (%).

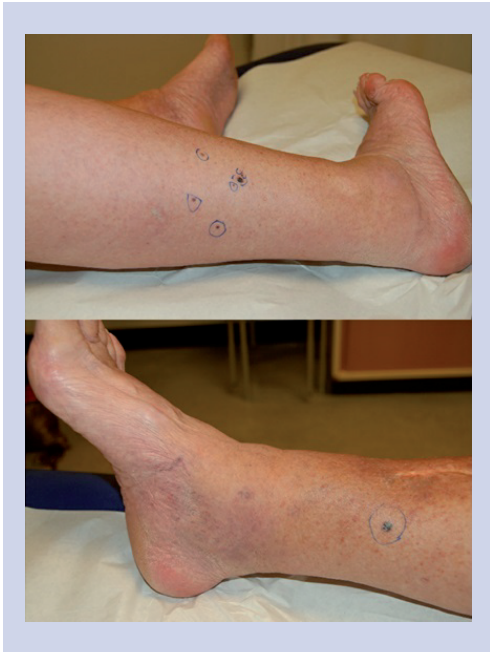

Figure 1. Melanoma patient with in-transit metastases eligible for CO₂ laser therapy.

Ethical approval

The Medical Ethical Committee granted dispensation according to the Dutch law regarding patient based medical research obligation (METc registration no. 2017003). The data were retrospectively collected in an electronic database and processed according to the Declaration of Helsinki [19].

Results

Patient & melanoma characteristics

A total of 26 patients (female $n = 15$; male $n = 11$) were treated with CO₂ laser evaporation for satellite or in-transit metastases between November 2002 and August 2018. Baseline patient and melanoma characteristics are summarized in Table 1. The median age at initial treatment for satellite or in-transit metastases was 71 year (range = 42–88). The primary melanoma was located on the lower extremity in 77% of patients, the head and neck in 15% of patients, and trunk in 8% of patients. Median overall Breslow thickness of the primary melanoma was 3.3 mm (range = 1.5–8.0). In one patient the Breslow thickness was >1 mm; however, the exact Breslow thickness was unknown. Superficial spreading melanoma was the most common histological subtype (58%).

CO₂ laser evaporation

The CO₂ laser evaporation was performed for satellite or in-transit metastases located on the lower extremity in 20 patients (77%), head and neck in five patients (19%) and trunk in one patient (4%). The median number of lesions treated during one CO₂ laser evaporation session was 3 (range = 1 to 16). There were two complications, including delayed wound healing and the development of an ulcer in a patient with chronic venous insufficiency. For almost all lesions, one treatment was enough to evaporate the lesion. Multiple treatment sessions were indicated due to the development of new lesions in the same region, with a median number of three treatment sessions per patient. The median duration of local control with CO₂ laser evaporation was 5.5 months (range = 0.5 to 63; Table 2). Reasons for termination of CO₂ laser evaporation were local progression in 17 patients (65%), distant metastases in eight patients (31%) and lymph node metastases in two patients (7%). Local progression included progression in number (>15) or size (>10 mm), or the development of subcutaneous lesions. In one patient, CO₂ laser evaporation is currently still performed. The median time of survival after initial treatment of the satellite or in-transit metastases was 45 months (Table 2).

Follow-up

The timelines for all individual patients, from the start of CO₂ laser evaporation for satellite or in-transit metastases, are presented in a swimmers plot (Figure 2). Each colored bar represents the duration of a therapy, from start of one

Table 1. Baseline patient and tumor characteristics.

Characteristics	Number (%) and median (range)
Gender	
– Male	11 (42.3)
– Female	15 (57.7)
Age, years [†]	71 (42–88)
Location of primary lesion	
– Lower extremity	20 (76.9)
– Upper extremity	0 (0.0)
– Head and neck	4 (15.4)
– Trunk	2 (7.7)
Histologic typing	
– Superficial spreading	15 (57.7)
– Nodular	7 (26.9)
– Nevoid	1 (3.8)
– Acral lentiginous	1 (3.8)
– Unable to classify	1 (3.8)
– Unknown primary	1 (3.8)
Breslow thickness, mm	3.3 (1.5–8.0)
T stage	
– T1 (<1.00 mm)	0 (0.0)
– T2 (1.01–2.00 mm)	7 (26.9)
– T3 (2.01–4.00 mm)	11 (42.3)
– T4 (>4.00 mm)	6 (23.1)
– Unknown primary	1 (3.8)
– Unknown	1 (3.8)
Ulceration	
– Yes	7 (26.9)
– No	18 (69.2)
– Unknown primary	1 (3.8)
AJCC stage	
– IIIB	12 (46.2)
– IIIC	13 (50.0)
– IV	1 (3.8)

[†] Age at initial treatment satellite/in-transit metastases.
AJCC: American Joint Committee on Cancer.

therapy until the start of a subsequent therapy. The median duration of CO₂ laser evaporation was 5.5 months. In six patients (24%) CO₂ laser evaporation was combined with another treatment, including systemic treatment in three patients, local treatment in two patients and palliative care in one patient. After CO₂ laser evaporation, 21 (81%) patients received an additional treatment modality during follow-up, including radiotherapy (33%), systemic treatment (19%) or additional surgical interventions, including local treatment (24%), HILP or ILI (19%), or a lymph node dissection (5%) due to locoregional progression of disease. At the end of follow-up, six of the 26 patients were alive.

Discussion

This retrospective study shows that CO₂ laser evaporation is an attractive treatment option for a selected group of melanoma patients with satellite or in-transit metastases. The CO₂ laser evaporation has shown to be efficient and effective, and can be performed under local anesthesia in an outpatient clinic setting with low morbidity and complication rates. Even in the era of effective systemic treatment, CO₂ laser evaporation is a good palliative treatment option, aiming to stabilize disease and maintain quality of life. Based on the results of this study, we propose a treatment algorithm which will be discussed below (Figure 3).

Table 2. Details of CO₂ laser evaporation.

Characteristics	Number (%) and median (range)
Location satellite/in-transit metastases	
– Lower extremity	20 (76.9)
– Upper extremity	0 (0.0)
– Head and neck	5 (19.2)
– Trunk	1 (3.8)
Number of laser treatments	3 (1–19)
Number of lesions per session	3 (1–16)
Complications	
– Yes	2 (7.7)
– No	24 (92.3)
Reason for termination of therapy	
– Local progression [†]	17 (65.4)
– Lymph node metastases	2 (6.9)
– Distant metastases	8 (30.8)
– Complications	0 (0.0)
– Unknown	2 (6.9)
Duration of local control, months	5.5 (0.5–63.0)
Survival, months [‡]	45.0 (5.0–124.0)

[†]Local progression included progression in number (>15) or size (> 10 mm), or the development of subcutaneous lesions.
[‡]Since initial treatment for satellite/in-transit metastases.

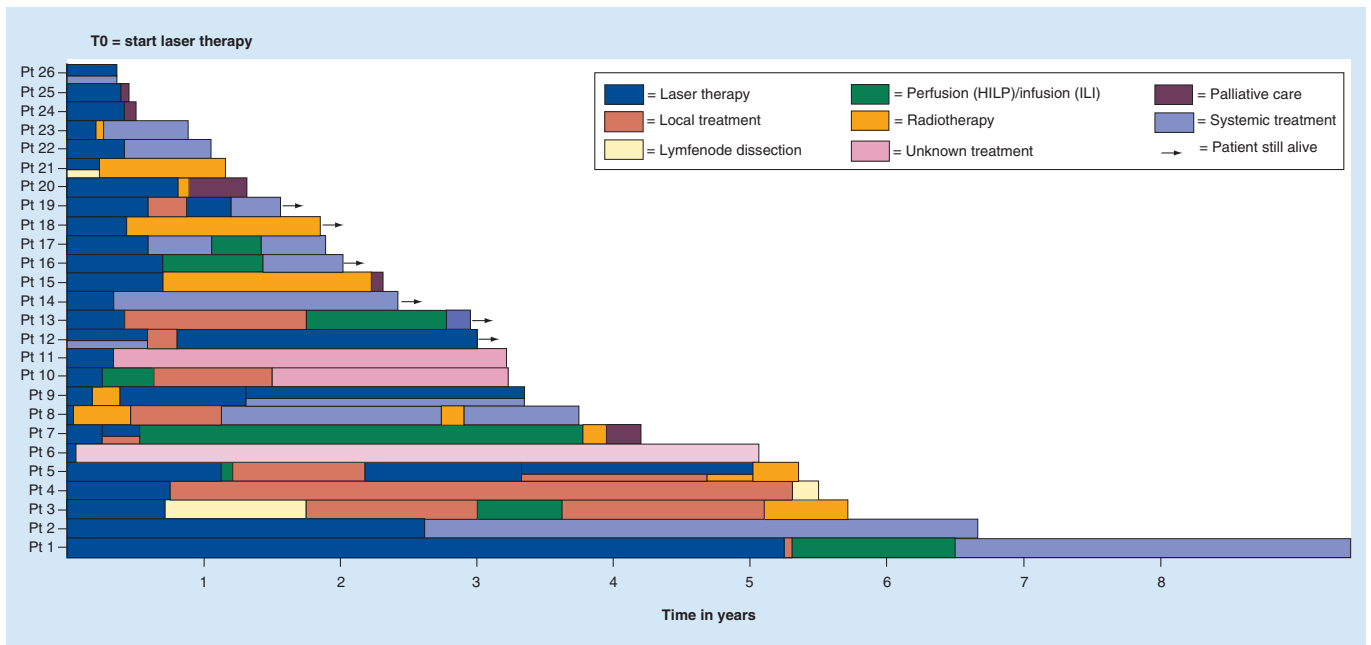


Figure 2. Swimmers plot of the course of disease and treatment history of all individual patients with satellite or in-transit metastases.

At the time of diagnosis of satellite or in-transit metastases, the risk of occult nodal or distant metastases is substantial; therefore, all patients should be carefully staged. The diagnostic tool of preference in stage III melanoma patients for the detection of metastases is a fluorine-18 labeled fluorodeoxyglucose positron emission tomography (¹⁸F-FDG PET) [20]. Combined with a diagnostic CT scan, it can reach a sensitivity of 86% and specificity of 91% for the detection of melanoma metastases [21]. Based on the stage of the disease, a patient-tailored treatment plan can be made.

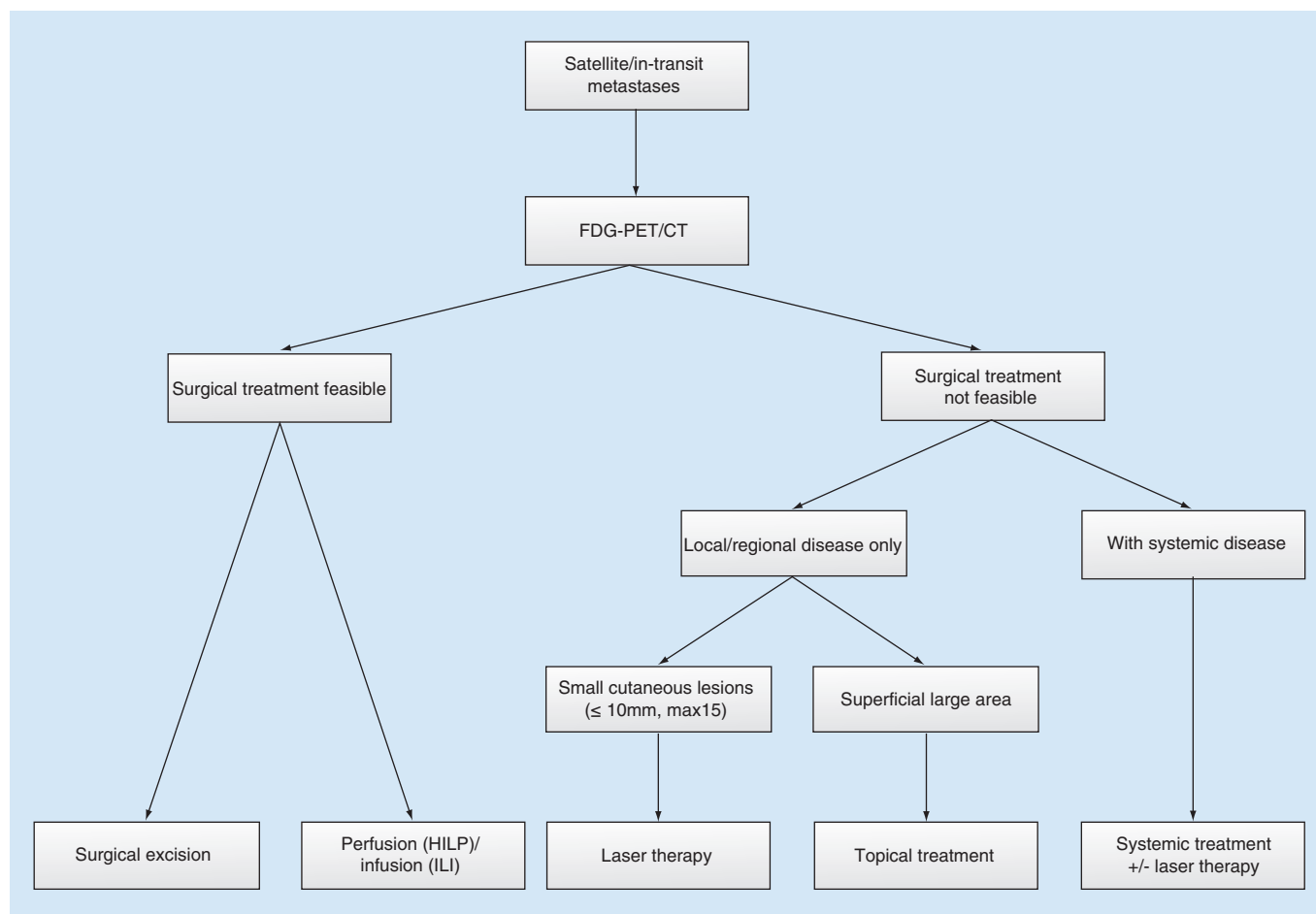


Figure 3. Treatment flow-chart for patients with satellite or in-transit metastases.

CT: Computed tomography; FDG-PET: Fludeoxyglucose-positron emission tomography; HILP: Hyperthermic isolation limb perfusion; ILI: Isolated limb perfusion.

For patients with satellite or in-transit metastases without distant disease, surgical excision is the treatment of choice, if technically feasible [7–9]. When the satellite or in-transit metastases are not amenable to surgical resection, either HILP or ILI is suggested if the disease is limited to an extremity. However, both procedures are invasive, require general anesthesia, hospital admission for at least several days, and may be associated with morbidity and regional toxicity [22]. In addition, HILP is not appropriate in patients with multiple comorbidities. In this study, HILP or ILI was not feasible in three patients (patient 15, 20 and 25) and CO₂ laser evaporation was performed without complications. Locoregional control was achieved during respectively 10, 8 and 4 months after which treatment was changed to another modality due to progression of disease.

Surgery can be mutilating in recurrent disease, especially when satellite or in-transit metastases are located in the head and neck region. Topical and intralesional therapies are alternative treatment modalities in these patients in addition to CO₂ laser evaporation. Imiquimod 5% cream (Aldara®) and topical diphencyprone are approved for the treatment of warts, solar keratosis, superficial basal cell carcinoma and alopecia areata but have also been reported for the treatment of melanoma metastases [23–27]. Both are inexpensive, simple to apply and easily accessible; however, the effect is limited to superficial lesions. Imiquimod has been combined with intralesional IL-2 in the treatment of subcutaneous lesions [23,24,28,29]. Regression of lesions has been reported in up to 50% of patients for Imiquimod and 84% for diphencyprone [7,23,27]. Side effects are usually mild and include flu-like symptoms and local reaction such as erythema and erosions, but severe blistering has been seen in some cases [24,25].

Talimogene Laherarepvec (T-VEC) is an oncolytic immunotherapy, derived from herpes simplex virus type I and is approved for the treatment of stage IIIB, IIIC and IV M1a disease [30,31]. It causes death of tumor cells and initiates

an antitumor immune response after administration via intralesional injection [7]. An overall response rate of 26.4% has been seen with mild adverse events including fatigue, chills and pyrexia [32]. However, T-VEC is costly and there are several important management considerations [30]. Another intralesional therapy is electrochemotherapy (ECT), which consist of injection of a chemotherapeutic drugs followed by application of electrical pulses to the tumor [33–35]. A systematic review by Aguado-Romeo *et al.* [33] showed that ECT appears to be an effective procedure for the local treatment of satellite or in-transit melanoma metastases; however, the level of evidence is low. Besides topical and intralesional therapies, radiotherapy is used in the treatment of metastatic melanoma. However, there is a limited role for radiotherapy as first-line management of satellite or in-transit metastases [8]. Especially wide-field radiation is not indicated in the view of considerable morbidity [29].

Ablation of satellite or in-transit metastases can be performed using laser or electrocautery [36]. Electrocautery is a simple technique used in several clinics with a small scientific basis in melanoma patients. Furthermore, we believe that electrocautery may cause more collateral damage compared with CO₂ laser. Previous studies have shown that CO₂ laser evaporation can be used for cutaneous and superficial subcutaneous melanoma metastases with a maximum diameter of 5–20 mm [15–18]. In our study, lesions ≤ 10 mm were deemed eligible for CO₂ laser evaporation. In larger lesions, more infiltration is usually present and a significant defect is created without the certainty that the lesion is completely evaporated, especially in the deeper skin layers, with the risk of local recurrence, infection and wound problems. The number of lesions treated during one CO₂ laser evaporation session in our study (median = 3; range = 1–16) was less than in previous studies (median = 6–20; range = 1–450) [16,18,37,38]. The CO₂ laser evaporation was performed under local anesthesia in our study, whereas in other studies the procedure was performed under local or regional anesthesia depending on the amount and location of the lesions. The use of local anesthesia limits the number of lesions that can be treated during one procedure; however, the advantage is that the procedure will only take 10–15 min. For a superficial large area with satellite or in-transit metastases or confluent lesions, CO₂ laser evaporation is not appropriate and a topical therapy might be a better treatment modality. However, for small (≤ 10 mm), numerous (0–15) lesions CO₂ laser evaporation is more suitable.

Growing evidence suggests that concurrent systemic and locoregional treatment synergizes antitumor effects in patients with stage IV disease. Locoregional treatment of metastases is thought to cause an immune mediated phenomenon resulting in the regression of tumors outside the scope of the localized treatment. This so-called abscopal effect is reported in melanoma patients treated with radiotherapy and in patients treated with CO₂ laser evaporation with remission of untreated deposits [39–41]. Previous studies have shown promising results combining immune checkpoint blockade (ipilimumab) with either radiotherapy, ECT, T-VEC or imiquimod [14,42–44]. In our study, in three patients (patient 9, 12 and 26) systemic treatment was combined with CO₂ laser evaporation. One of these patients developed in-transit metastases located at the lower eyelid and cheeks during systemic treatment causing symptoms, which were successfully treated with CO₂ laser evaporation. Combined CO₂ laser evaporation and systemic therapy might synergize the immunotherapeutic effects.

There are several limitations of this study that need to be addressed. First of all, the retrospective nature of this study; not all tumor factors (e.g., lesion size) were available for analyses, furthermore, as in most retrospective studies there are some missing data. The CO₂ laser therapy was combined with systemic treatment in some patients, making assessment of the value of CO₂ laser therapy difficult. However, this was the case in only three patients.

Conclusion

There are several treatment modalities that can be used for the treatment of satellite or in-transit melanoma metastases, including CO₂ laser evaporation. The AI treatment modalities have their own advantages and disadvantages as described above. The CO₂ laser evaporation results in rapid removal of lesions. There is minimal collateral damage of surrounding tissue, easily managed wound care, minimal complications and good cosmetic results. In a selected group of melanoma patients with satellite or in-transit metastases, CO₂ laser evaporation should be considered as treatment for local control when surgical resection is not amenable.

Future perspective

Developments in systemic therapy, including immunotherapy, are currently changing the standard of care of melanoma patients. Not only in recent years, but also in the future, systemic therapy will play a more important role in the treatment of melanoma patients. Despite this, there will remain a group of patients who will benefit from simple, local therapy with good cosmetic outcome and few complications, aiming for a good quality of life. Since the long-term results of systemic therapy are still unknown, future research should be aimed at determining

whether the combination of systemic therapy and local therapy (e.g., CO₂ laser evaporation) improves not only locoregional control but also survival.

Summary points

- A substantial number of melanoma patients develop satellite or in-transit metastases, which can have a significant impact on the patients' quality of life due to ulceration, bleeding, infection and pain.
- Treatment of satellite and in-transit metastases can be a challenge due to the variation in clinical presentation and the unpredictable behavior of the disease. Surgical resection is, if possible, the preferred treatment.
- In extensive disease, metastases located at the head and neck region or in patients with multiple comorbidities, surgical resection might be mutilating, too invasive or even be impossible and alternative treatment options should be used.
- There are various modalities for the treatment of melanoma satellite or in-transit metastases including topical therapies (e.g., Imiquimod, topical diphencyprone), intralesional therapies (e.g., talimogene laherarepvec [T-VEC], electrochemotherapy), radiotherapy and CO₂ laser evaporation.
- The CO₂ laser evaporation results in rapid removal of lesions with minimal collateral damage of surrounding tissue, easily managed wound care and minimal complications, and should be considered as treatment for local control in a selected group of melanoma patients with satellite or in-transit metastases.
- It is to be determined whether combined systemic and local therapy by means of CO₂ laser evaporation improves not only locoregional control but also survival.

Financial & competing interests disclosure

The authors have no relevant affiliations or financial involvement with any organization or entity with a financial interest in or financial conflict with the subject matter or materials discussed in the manuscript. This includes employment, consultancies, honoraria, stock ownership or options, expert testimony, grants or patents received or pending, or royalties.

No writing assistance was utilized in the production of this manuscript.

Ethical conduct of research

The authors state that they have obtained appropriate institutional review board approval or have followed the principles outlined in the Declaration of Helsinki for all human or animal experimental investigations. Data collection by chart review was approved by the institutional review board of the University Medical Center Groningen.

Open access

This work is licensed under the Attribution-NonCommercial-NoDerivatives 4.0 Unported License. To view a copy of this license, visit <http://creativecommons.org/licenses/by-nc-nd/4.0/>

References

Papers of special note have been highlighted as: • of interest; •• of considerable interest

1. Siegel RL, Miller KD, Jemal A. Cancer statistics, 2018. *CA Cancer J. Clin.* 68(1), 7–30 (2018).
2. Balch CM, Buzaid AC, Soong SJ *et al.* Final version of the American Joint Committee on Cancer staging system for cutaneous melanoma. *J. Clin. Oncol.* 19(16), 3635–3648 (2001).
3. Read RL, Haydu L, Saw RP *et al.* In-transit melanoma metastases: Incidence, prognosis, and the role of lymphadenectomy. *Ann. Surg. Oncol.* 22(2), 475–481 (2015).
4. Stucky CC, Gray RJ, Dueck AC *et al.* Risk factors associated with local and in-transit recurrence of cutaneous melanoma. *Am. J. Surg.* 200(6), 770–774; discussion 774–775 (2010).
5. Pawlik TM, Ross MI, Johnson MM *et al.* Predictors and natural history of in-transit melanoma after sentinel lymphadenectomy. *Ann. Surg. Oncol.* 12(8), 587–596 (2005).
6. Balch CM, Soong SJ, Gershenwald JE *et al.* Prognostic factors analysis of 17,600 melanoma patients: validation of the American Joint Committee on Cancer melanoma staging system. *J. Clin. Oncol.* 19(16), 3622–3634 (2001).
7. Testori A, Ribero S, Bataille V. Diagnosis and treatment of in-transit melanoma metastases. *Eur. J. Surg. Oncol.* 43(3), 544–560 (2017)
- **Describes different treatment modalities for melanoma metastases.**
8. Hoekstra HJ. The european approach to in-transit melanoma lesions. *Int. J. Hyperthermia* 24(3), 227–237 (2008).
9. Bagge AS, Ben-Shabat I, Belgrano V, Olofsson Bagge R. Health-related quality of life for patients who have in-transit melanoma metastases treated with isolated limb perfusion. *Ann. Surg. Oncol.* 23(6), 2062–2069 (2016).

10. Long GV, Grob JJ, Nathan P *et al.* Factors predictive of response, disease progression, and overall survival after dabrafenib and trametinib combination treatment: a pooled analysis of individual patient data from randomised trials. *Lancet Oncol.* 17(12), 1743–1754 (2016).
11. Hodi FS, Chesney J, Pavlick AC *et al.* Combined nivolumab and ipilimumab versus ipilimumab alone in patients with advanced melanoma: 2-year overall survival outcomes in a multicentre, randomised, controlled, Phase 2 trial. *Lancet Oncol.* 17(11), 1558–1568 (2016).
12. Puzanov I, Amaravadi RK, McArthur GA *et al.* Long-term outcome in BRAF(V600E) melanoma patients treated with vemurafenib: patterns of disease progression and clinical management of limited progression. *Eur. J. Cancer* 51(11), 1435–1443 (2015).
13. Heppt MV, Eigentler TK, Kahler KC *et al.* Immune checkpoint blockade with concurrent electrochemotherapy in advanced melanoma: a retrospective multicenter analysis. *Cancer Immunol. Immunother.* 65(8), 951–959 (2016).
14. Theurich S, Rothschild SI, Hoffmann M *et al.* Local tumor treatment in combination with systemic ipilimumab immunotherapy prolongs overall survival in patients with advanced malignant melanoma. *Cancer Immunol. Res.* 4(9), 744–754 (2016).
15. Waters RA, Clement RM, Thomas JM. Carbon dioxide laser ablation of cutaneous metastases from malignant melanoma. *Br. J. Surg.* 78(4), 493–494 (1991).
16. Hill S, Thomas JM. Use of the carbon dioxide laser to manage cutaneous metastases from malignant melanoma. *Br. J. Surg.* 83(4), 509–512 (1996).
17. Lingam MK, McKay AJ. Carbon dioxide laser ablation as an alternative treatment for cutaneous metastases from malignant melanoma. *Br. J. Surg.* 82(10), 1346–1348 (1995).
18. van Jarwaarde JA, Wessels R, Nieweg OE, Wouters MW, van der Hage JA. CO₂ laser treatment for regional cutaneous malignant melanoma metastases. *Dermatol. Surg.* 41(1), 78–82 (2015).
- **Describes outcome of CO₂ laser treatment of melanoma metastases.**
19. World Medical Association. World Medical Association Declaration of Helsinki: Ethical principles for medical research involving human subjects. *JAMA* 310(20), 2191–2194 (2013).
20. Bastiaannet E, Oyen WJ, Meijer S *et al.* Impact of [18F]fluorodeoxyglucose positron emission tomography on surgical management of melanoma patients. *Br. J. Surg.* 93(2), 243–249 (2006).
21. Xing Y, Bronstein Y, Ross MI *et al.* Contemporary diagnostic imaging modalities for the staging and surveillance of melanoma patients: a meta-analysis. *J. Natl Cancer Inst.* 103(2), 129–142 (2011).
22. Dosssett LA, Ben-Shabat I, Olofsson Bagge R, Zager JS. Clinical response and regional toxicity following isolated limb infusion compared with isolated limb perfusion for in-transit melanoma. *Ann. Surg. Oncol.* 23(7), 2330–2335 (2016).
23. Turza K, Dengel LT, Harris RC *et al.* Effectiveness of imiquimod limited to dermal melanoma metastases, with simultaneous resistance of subcutaneous metastasis. *J. Cutan. Pathol.* 37(1), 94–98 (2010).
24. Bong AB, Bonnekoh B, Franke I, Schon M, Ulrich J, Gollnick H. Imiquimod, a topical immune response modifier, in the treatment of cutaneous metastases of malignant melanoma. *Dermatology* 205(2), 135–138 (2002).
25. Yeung C, Petrella TM, Wright FC, Abadir W, Look Hong NJ. Topical immunotherapy with diphencyprone (DPCP) for in-transit and unresectable cutaneous melanoma lesions: an inaugural canadian series. *Expert Rev. Clin. Immunol.* 13(4), 383–388 (2017).
26. Gibbons IL, Sonagli M, Bertolli E, Macedo MP, Pinto CAL, Duprat Neto JP. Diphencyprone as a therapeutic option in cutaneous metastasis of melanoma. *An. Bras. Dermatol.* 93(2), 299–301 (2018).
27. Damian DL, Saw RP, Thompson JF. Topical immunotherapy with diphencyprone for in transit and cutaneously metastatic melanoma. *J. Surg. Oncol.* 109(4), 308–313 (2014).
28. Ugurel S, Wagner A, Pfohler C, Tilgen W, Reinhold U. Topical imiquimod eradicates skin metastases of malignant melanoma but fails to prevent rapid lymphogenous metastatic spread. *Br. J. Dermatol.* 147(3), 621–624 (2002).
29. Sloot S, Rashid OM, Sarnaik AA, Zager JS. Developments in intralesional therapy for metastatic melanoma. *Cancer Control* 23(1), 12–20 (2016).
- **Describes different treatment modalities for melanoma metastases.**
30. Bommareddy PK, Patel A, Hossain S, Kaufman HL. Talimogene laherparepvec (T-VEC) and other oncolytic viruses for the treatment of melanoma. *Am. J. Clin. Dermatol.* 8(1), 1–15 (2017).
31. Grigg C, Blake Z, Gartrell R, Sacher A, Taback B, Saenger Y. Talimogene laherparepvec (T-vec) for the treatment of melanoma and other cancers. *Semin. Oncol.* 43(6), 638–646 (2016).
32. Andtbacka RH, Kaufman HL, Collichio F *et al.* Talimogene laherparepvec improves durable response rate in patients with advanced melanoma. *J. Clin. Oncol.* 33(25), 2780–2788 (2015).
33. Aguado-Romeo MJ, Benot-Lopez S, Romero-Tabares A. Electrochemotherapy for the treatment of unresectable locoregionally advanced cutaneous melanoma: a systematic review. *Actas Dermosifiliogr.* 108(2), 91–97 (2017).
34. Kunte C, Letule V, Gehl J *et al.* Electrochemotherapy in the treatment of metastatic malignant melanoma: a prospective cohort study by InspECT. *Br. J. Dermatol.* 176(6), 1475–1485 (2017).
35. Wichtowski M, Murawa D. Electrochemotherapy in the treatment of melanoma. *Contemp. Oncol. (Pozn).* 22(1), 8–13 (2018).

36. Thompson JF. Local and regional therapies for melanoma: many arrows in the quiver. *J. Surg. Oncol.* 109(4), 295 (2014)
37. Kandamany N, Mahaffey P. Carbon dioxide laser ablation as first-line management of in-transit cutaneous malignant melanoma metastases. *Lasers Med. Sci.* 24(3), 411–414 (2009).
- **Describes outcome of CO₂ laser treatment of melanoma metastases.**
38. Gibson SC, Byrne DS, McKay AJ. Ten-year experience of carbon dioxide laser ablation as treatment for cutaneous recurrence of malignant melanoma. *Br. J. Surg.* 91(7), 893–895 (2004).
- **Describes outcome of CO₂ laser treatment of melanoma metastases.**
39. Oni G, Monk BM. Spontaneous regression of subcutaneous in-transit malignant melanoma deposits of the lower leg after treatment with the carbon dioxide laser. *Clin. Exp. Dermatol.* 34(8), e650–e652 (2009).
40. Grimaldi AM, Simeone E, Giannarelli D *et al.* Abscopal effects of radiotherapy on advanced melanoma patients who progressed after ipilimumab immunotherapy. *Oncoimmunology* 3, e28780 (2014).
41. Demaria S, Ng B, Devitt ML *et al.* Ionizing radiation inhibition of distant untreated tumors (abscopal effect) is immune mediated. *Int. J. Radiat. Oncol. Biol. Phys.* 58(3), 862–870 (2004).
42. Joseph RW, Cappel M, Tzou K *et al.* Treatment of in-transit and metastatic melanoma in two patients treated with ipilimumab and topical imiquimod. *Melanoma Res.* 26(4), 409–412 (2016).
43. Barker CA, Postow MA, Khan SA *et al.* Concurrent radiotherapy and ipilimumab immunotherapy for patients with melanoma. *Cancer Immunol. Res.* 1(2), 92–98 (2013).
44. Puzanov I, Milhem MM, Minor D *et al.* Talimogene laherparepvec in combination with ipilimumab in previously untreated, unresectable stage IIIB-IV melanoma. *J. Clin. Oncol.* 34(22), 2619–2626 (2016).