


## CASE REPORT

# Multi-tissue cytogenetic analysis for the diagnosis of mosaic Down syndrome: A case report

Wilberg A. Moncada Arita<sup>1</sup> | Eduardo Smelin Perdomo Domínguez<sup>1</sup> |  
Astrid Yohaly Rivera Caballero<sup>1</sup> | Nelson A. Espinoza-Moreno<sup>1</sup> |  
Mauricio E. Zavala Galeano<sup>1</sup> | Barbara R. DuPont<sup>2</sup> | Héctor M. Ramos-Zaldívar<sup>1,3</sup> 

<sup>1</sup>GIMUNICAH, Faculty of Medicine, Universidad Católica de Honduras, San Pedro Sula, Honduras

<sup>2</sup>Greenwood Genetic Center, Greenwood, South Carolina, USA

<sup>3</sup>Faculty of Medicine, Doctoral Program in Medical Sciences, Pontificia Universidad Católica de Chile, Santiago de Chile, Chile

## Correspondence

Héctor M. Ramos-Zaldívar, Faculty of Medicine, Doctoral Program in Medical Sciences, Pontificia Universidad Católica de Chile, Santiago de Chile, Chile.

Emails: hramos@unicah.edu; hmramos@uc.cl

## Funding information

The study was funded by Universidad Católica de Honduras

## Abstract

Less than one percent of individuals with Down syndrome exhibit mosaicism, a biological phenomenon that describes an individual who has two or more genetically distinct cell lines. The percentage of mosaicism in different tissues can impact the presence of clinical findings and hinder cytogenetic diagnosis. We report a case of mosaicism for trisomy 21 diagnosed after multi-tissue cytogenetic analysis of peripheral blood and buccal mucosa, associated with significant intellectual disability, dysmorphic facial features, congenital heart defects, macropenis, and imperforate anus.

## KEYWORDS

buccal smear, chromosome disorders, cytogenetics, Down syndrome, macropenis, mosaicism, trisomy 21

## 1 | INTRODUCTION

Down syndrome (DS, OMIM 190685; ORPHA870) is the most common aneuploidy associated with intellectual disability caused by a microscopically demonstrable chromosomal aberration. It involves a triplicate state (trisomy) of all or a critical portion of chromosome 21, occurring at a frequency of 1/800 newborns worldwide.<sup>1</sup> The majority of individuals (95%) with DS have complete trisomy for chromosome 21.<sup>2</sup> Some individuals (4%) with DS have Robertsonian translocations that involve chromosome 21.<sup>2</sup> Less than one percent of individuals with Down syndrome exhibit mosaicism,<sup>2</sup> which can be categorized into

a branch of medicine dealing with diseases of very low prevalence, usually known as *rare diseases* and referred to by our team as *eidikology*.<sup>3</sup>

Mosaicism is a biological phenomenon, which describes an individual who has developed from a single fertilized egg and has two or more genetically distinct cell lines.<sup>4</sup> The criterion of being formed from a single fertilized egg differentiates mosaicism from the related phenomenon of chimerism, which refers to an individual comprised of multiple cell lineages derived from distinct fertilized eggs.<sup>4</sup> The individuals with trisomy 21 mosaicism have two genetically distinct cell lines.<sup>5</sup> In contrast to most children with non-mosaic DS, individuals with

This is an open access article under the terms of the Creative Commons Attribution-NonCommercial License, which permits use, distribution and reproduction in any medium, provided the original work is properly cited and is not used for commercial purposes.

© 2022 The Authors. *Clinical Case Reports* published by John Wiley & Sons Ltd.

mosaic DS exhibit considerable tissue-specific differences in the proportion of cells with trisomy 21. Furthermore, children with mosaic DS have a better overall 1-year survival rate than those with non-mosaic DS (97.5% compared to 93%).<sup>6,7</sup>

There is significant variability in the clinical presentation of mosaic DS. It can range from showing no clinical features to having a phenotype with clinical manifestations of non-mosaic DS. The percentage of trisomic cells from different tissues, depending on their corresponding embryological layer of origin, may contribute to the existing variability in the phenotype of this syndrome.

The association between the percentage of mosaicism and the severity of the phenotype has not been very well elucidated. Papavassiliou et al.<sup>8</sup> reported a significant inverse correlation between the percentage of trisomic cells obtained in the buccal samples and the IQ scores of mosaicism for trisomy 21 individuals. In addition, the presence of congenital heart disease was significantly correlated with the proportion of trisomic lymphocytes.<sup>8</sup> We report a case of mosaicism for trisomy 21 that deviates from these findings. Peripheral blood cytogenetic analysis revealed a single cell out of fifty with an additional copy of chromosome 21, which was not sufficient for diagnosis. Further analysis on buccal mucosa cells detected low-level mosaicism by fluorescence in situ hybridization (FISH) associated with significant intellectual disability, dysmorphic facial features of Down syndrome, patent foramen ovale (PFO), mild systolic pulmonary artery hypertension, tricuspid and pulmonary artery regurgitation, macropenis, and imperforate anus.

## 2 | CASE PRESENTATION

We report the case of a Honduran 12-year-old mestizo (combined European and Amerindian descent) boy born to non-consanguineous parents. He is the second of three children conceived by a 31-year-old mother and a 31-year-old father. He has no relevant prenatal history, and his family history is unremarkable. There was no known exposure to teratogenic drugs, infections, or radiation. Birth was via cesarean delivery due to a previous cesarean section, with a birth weight of 3.49 kg, birth length of 50 cm, and head circumference of 36 cm. In his initial evaluation, the patient presented joint laxity, upslanting palpebral fissures, bilateral epicanthal fold, protruding tongue, single transverse palmar crease, clinodactyly of the fifth finger, round face, wide and flat nasal bridge, prominent low-set ears, macropenis, straight and fine hair, decreased gastrointestinal motility, and an imperforate anus that was surgically corrected within the first 72 hours.

The patient started crawling at the age of 7 months and walked when he was 11 months. Regarding speech and language development, word usage began at the age of 8 months; however, he gradually lost them. At the age of 5 years, a pediatric neurologist diagnosed an autism spectrum disorder after assessing the communication deficits. The patient's speech was delayed, and he only knew about 10 words and 1 or 2 two-word phrases. The Preschool Language Scale 3, Spanish Edition, was attempted. However, the patient was unable to participate in the testing environment. Therefore, his communication skills were assessed using the Rossetti Infant Toddler Language Scale (RITLS), revealing profound delays in gesture, play, language comprehension, and language expression. His communication skills consisted of vocalizations, one-word utterances, and gestures, which were equivalent to the language level of an 18-month-old child. He did not communicate well for his age and was inconsistent in identifying numbers and letters. He started forming phrases at the age of 9 years. He exhibited difficulty staying on task and required frequent redirection to task. He also exhibited limited eye contact when requesting. The patient has received speech therapy since the age of three. Nevertheless, he continued with difficulties when forming sentences, omitting articles, conjunctions, prepositions, and showing difficulty in the pronunciation of phonemes.

Several psychometric tests were applied to assess his psychological development and personality. The Scribble test showed a withdrawn and self-absorbed nature, but as a temporary state influenced by the environment. According to the Blob Tree test, some indicators of emotional immaturity were perceived since he tends to have a passive-aggressive behavior. Family drawing test revealed high appreciation for the mother figure. The House–Tree–Person test was performed. The patient showed stress, defensiveness, introversion, need for security, impulsivity, immaturity, and emotional dependence. Intellectual level was initially assessed at the age of 7 years by the Wechsler Preschool and Primary Scale of Intelligence—III (WPPSI-III) revealing an intellectual quotient of 78, indicative of borderline intelligence. The verbal intellectual quotient of 56 demonstrates significant difficulties in his verbal abilities. A performance intellectual quotient of 85 was reported. Later at the age of 12 years, a Wechsler Intelligence Scale for Children-IV (WISC-IV) test reported an intellectual quotient of 47, indicative of extremely low intelligence. A very low verbal comprehension index of 55 (0.1 percentile), a very low visual spatial index of 59 (0.3 percentile), a very low working memory index of 59 (0.3 percentile), and a very low processing speed index of 50 (<0.1 percentile) were reported.

Transthoracic echocardiography revealed a PFO of 3 mm, mild tricuspid, and pulmonary valve regurgitation,

with an increased pulmonary artery systolic pressure of 35 mmHg. The left ventricular ejection fraction was normal, with 66% as measured using the Simpson method. The electroencephalographic study was within normal limits. There was no presence of focal abnormalities, interhemispheric asymmetries, or epileptiform activity. An ophthalmological evaluation revealed esotropia and nystagmus with a refractory correction in the right eye of  $-1$  diopter and in the left eye of  $-1.25$  diopter.

Audiometry reported bilateral hearing within normal limits. A lumbosacral spine X-ray showed no evidence of spine malformations. Ultrasound imaging of the abdomen was performed demonstrating a normal appearance of the liver, spleen, and pancreas. Gallbladder walls with no evidence of thickening or gallstones were visualized. Both kidneys were normal in size and position, and the urinary bladder had no filling defects. Normal aorta and retroperitoneum were observed. No cysts, masses, or free fluid were identified. Additional laboratory analyses showed glucose, creatinine, bilirubin, and transaminases within normal ranges.

Cytogenetic analyses performed on the patient are listed in Table 1. An initial G-band chromosome analysis at the age of 1 revealed a normal 46, XY karyotype. At the age of 5, a normal whole genome chromosome SNP microarray analysis was reported. No significant DNA copy number changes or copy neutral regions within the 2.695 million region-specific SNP and structural targets were detected.

When the patient was first assessed by our team at the age of 10, clinical evaluation was suggestive of DS. Therefore, we decided to perform another peripheral blood karyotype using high-resolution G-banding analysis to test for chromosomal numerical alterations in a higher number of metaphase cells. In this analysis, one cell out of 50 was found to have an additional copy of chromosome 21. This was not sufficient to constitute an abnormal result, but clinical suspicion of low-level mosaicism suggested the need for additional fluorescence in situ hybridization studies. FISH analysis revealed an abnormal result from interphase nuclei on buccal swab slides (Figure 1). Three red signals were observed on 78 of 501(15.57%)

interphase nuclei. This was consistent with low-level mosaicism for trisomy 21.

### 3 | METHODS

#### 3.1 | Cytogenetic analysis

A total of 20 cells in metaphase were analyzed through conventional G-band chromosomal analysis. High-resolution G-banding chromosome analysis was performed on 50 cells from a peripheral blood specimen.

#### 3.2 | Chromosome microarray

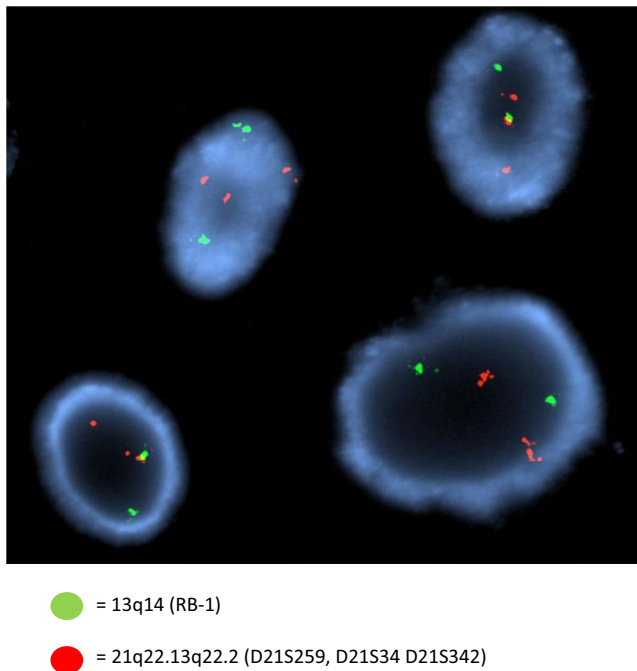
SNP microarray analysis was performed using the Affymetrix Cytoscan HD platform, which uses over 743,000 SNP probes and 1,953,000 NPCN probes with a median spacing of 0.66 kb. 250 ng of total genomic DNA extracted from lymphocytes was digested with Nspl and then ligated to Nspl adaptors, respectively, and amplified using Titanium Taq with a GeneAmp PCR System 9700. PCR products were purified using AMPure beads and quantified using NanoDrop 8000. Purified DNA was fragmented, labeled, and hybridized to the Affymetrix Cytoscan HD Genechip. Data were analyzed using Chromosome Analysis Suite. The analysis is based on human genome version 37.2HG19.

#### 3.3 | Fluorescence in situ hybridization

Fluorescence in situ hybridization with a panel of probes (Abbott/Vysis) specific for detection of chromosome trisomies for 13 and 21 was performed on buccal swab slides. The individual probe set was validated by Greenwood Genetic Center Cytogenetics Laboratory by determining specificity, sensitivity, accuracy, and precision. FISH was performed using the AneuVysion (LSI 13 and 21) Multicolor Probe Panel (Vysis #33-161075). The AneuVysion kit is intended for use as an adjunct to

**TABLE 1** Proband cytogenetic analyses

Genetic test	Patient age (years)	Result
Conventional G-banding karyotype	1	Normal 46, XY
Chromosome microarray SNP	5	arr (1-22) x2, (XY) x1
High-resolution G-banding karyotype	10	Normal 46, XY
FISH	10	nuc ish 21q22.13q22.2(D21S259, D21S341, D21S342)x3[78/500]



**FIGURE 1** Fluorescence in situ hybridization with a panel of probes specific for the detection of chromosome trisomies for 13 and 21 performed on buccal swab slides. The LSI 13/21 probe hybridizes to the D21S259, D21S34, and D21S342 regions within 21q22.13-q22.2 and to the RB-1 region at 13q14. Three red signals were observed on 78 of 501 interphase nuclei, consistent with mosaicism for trisomy 21. These are interphase nuclei signals where the DNA is extended. The RB-1 probe covers 440 kb, and the chromosome 21 probes cover 200 kb. Additional signals correspond to the spreading of the probes signal across a larger nuclear region

standard cytogenetic metaphase analysis for enumerating chromosomes 13 and 21. The LSI 13/21 probe hybridizes to the D21S259, D21S34, and D21S342 regions within 21q22.13-q22.2 and to the RB-1 region at 13q14. The RB-1 probe covers 440 kb, and the chromosome 21 probes cover 200 kb.

## 4 | DISCUSSION

We described a patient with mosaic DS diagnosed through FISH analysis of buccal mucosa cells, following a normal karyotype and normal whole genome microarray of peripheral blood cells. This case exhibited intellectual disability, asymptomatic cardiovascular abnormalities (PFO, mild systolic pulmonary artery hypertension, and tricuspid and pulmonary artery insufficiencies), dysmorphic facial features, macropenis, and imperforate anus.

There are two additional reports of mosaic DS diagnosis, which describe a multi-tissue approach including both peripheral blood lymphocytes and buccal smear cells. The phenotypic characteristics of these cases,

including this report, are presented in Table 2. Leon et al.<sup>9</sup> described the case of a 1-day-old baby girl with subtle features of DS and low-level mosaicism (8%–13% in blood and 31% in buccal mucosa). Unlike our patient, this case did not show signs of urogenital abnormalities. Unfortunately, a comparison on intellectual and language development cannot be made due to the age at the moment of the report. Paoloni-Giacobino et al.<sup>10</sup> reported the case of a 14-year-old girl with low-level mosaicism (2% in blood and 11% in buccal mucosa). The main finding in this case, besides a flat occipital bridge and minor microcephaly, was language impairment with an IQ within the normal range (IQ = 95). No urogenital abnormalities were described. It is worth noting that another report by Papavassiliou et al. included 49 cases that provided both blood and buccal mucosa specimens within the analysis of 107 individuals with mosaicism for trisomy 21. However, the specific phenotypes for these 49 patients were not detailed.

Gastrointestinal and urogenital malformations are common in DS. Bermudez et al.<sup>11</sup> found a 5% prevalence of congenital malformations in DS patients, 25% of which correspond to imperforate anus. In mosaic probands, Papavassiliou et al.<sup>8</sup> found 1% having this trait. An unexpected finding in the clinical presentation of our patient is macropenis. It is well known that patients with DS have a high incidence of abnormalities in sexual development. In boys, described defects vary from ambiguous genitalia, cryptorchidism, micropenis, small testes, and low sperm count to scant development of axillary hair and beard.<sup>12</sup> To our knowledge, macropenis has never been reported as part of the clinical presentation in mosaic DS.

The proportion of germline/gonadal cells having a trisomic imbalance in cases of mosaicism might be variable, which would explain a spectrum of urogenital phenotypes.<sup>5</sup> This is supported by a higher rate of fertile male patients with mosaicism for trisomy 21 when compared to complete trisomy 21. Zhu et al. reported that 7% of adults with mosaic Down syndrome had a child, compared to 1% of non-mosaic trisomic probands in a register-based cohort in Denmark.<sup>5,13</sup> For this reason, the proportion of trisomic imbalance opens the possibility for the development of morphological abnormalities related to penile overgrowth that would otherwise be unexpected. We believe that further research will be needed to elucidate the link between mosaicism for trisomy 21 and the occurrence of macropenis.

Intellectual disability has been significantly associated with the proportion of trisomic cells identified in buccal mucosa tissue.<sup>8</sup> Even though mosaic individuals show better intellectual development compared with non-mosaic trisomy 21, lower IQ scores are correlated with higher

**TABLE 2** Phenotypic characteristics of three mosaic DS cases diagnosed through analysis of both peripheral lymphocytes and buccal smear cells

Authors and Reference Number	This case report	Leon et al. <sup>9</sup>	Paoloni-Giacobino et al. <sup>10</sup>
Percentage trisomy blood	2	8–13	2
Percentage trisomy buccal mucosa	15.57	31	11–13
Hypotonia	–	+	–
Clinodactyly	+	+	–
Epicanthal fold	+	+	–
Upslanting palpebral fissures	+	+	–
Protruding tongue	+	–	–
Single transverse palmar crease	+	–	–
Adducted thumbs	–	+	–
Round face	+	–	–
Wide and flat nasal bridge	+	+	–
Anteverted nares	–	+	–
Long philtrum	–	+	–
Low-set ears	+	+	–
Small ears	–	+	–
Prominent ears	+	–	–
Micrognathia	–	+	–
Flat occipital bridge	–	–	+
Small forehead	–	+	–
Microcephaly	–	–	+
Straight and fine hair	+	–	–
Excess nuchal fold	–	+	–
Decreased gastrointestinal motility	+	–	–
Imperforate anus	+	–	–
Joint laxity	+	–	–
Phalangeal hypoplasia	–	+	–
Congenital heart abnormalities	+	+	–
Cutis marmorata	–	+	–
Intellectual disability	+	?	–
Language impairment	+	?	+
Macropenis	+	–	–

Note: +, present; –, absent; ?, not tested.

percentages of mosaicism in patients with this form of diagnostic presentation.<sup>8</sup> However, Giacobino et al. describe a patient with 13% of mosaicism in buccal mucosa cells exhibiting a normal intellectual development and specific language impairment as an isolated feature of mosaic DS.<sup>10</sup> By contrast, our patient showed a 15.57% (78 of 501) of trisomic cells in the buccal swab sample and had an extremely low IQ score of 47 by the age of 12. This shows a discrepancy between the possible ectodermal origin of the disease and the associated intellectual development. This phenomenon of clinical and embryological inconsistency also occurs more evidently in some forms of epilepsy, where mosaicism can affect specific areas of the brain rather than the entire central nervous system.<sup>14</sup>

A proposed hypothesis in the context of mosaic DS might be that trisomic cells are distributed unevenly in tissues of the same embryonic origin.

A correlation between the percentage of trisomic cells in peripheral blood and congenital heart defects has been previously described.<sup>8</sup> Leon et al.<sup>9</sup> reported a case with 8–13% mosaicism in peripheral blood associated with patent ductus arteriosus and PFO. Yokoyama et al.<sup>15</sup> described a patient with 90.5% of trisomic cells in myocardium with multiple heart defects and low-level mosaicism in peripheral blood. However, our patient did not exhibit mosaicism in peripheral blood, even though multiple cardiovascular findings were present. Although these abnormalities could be correlated with

the clinical presentation, it is also relevant to note that a PFO is present in approximately 25% of the adult population worldwide.<sup>16</sup>

In conclusion, we suggest a multi-tissue approach in patients with high suspicion of mosaic DS. Cytogenetic analysis of skin, peripheral blood, and buccal mucosa cells should be considered. FISH analysis in buccal mucosa cells aids in the detection of low-level mosaicism, especially in patients following a normal G-band karyotype and peripheral blood microarray. Although there have been previous reports of a direct correlation between the proportion of trisomic cells and clinical manifestations of mosaic DS, our case showed that low-level mosaicism can also result in evident clinical findings that can lead to a high suspicion of mosaicism for trisomy 21, even when faced with a negative karyotype.

### ACKNOWLEDGEMENTS

The authors acknowledge Universidad Católica de Honduras for support and funding; Dr. Charles Schwartz and the Greenwood Genetic Center for their collaboration with cytogenetic analysis; Dr. Manuel Barahona for collaboration in the interpretation of radiological images; Dr. Doris Canales de Reynaud for collaboration in psychometric analysis; Dr. Luis Cruz and Dr. Luis Leiva for collaboration during echocardiographic studies; Dr. Carlos A. Gámez-Fernández for collaboration in ophthalmological data; Dr. Edwin Francisco Herrera-Paz for collaboration in genetic counseling; Dr. Alvaro Mayorga for collaboration in physical examination; Ernesto Tomás Dox-Cruz for assistance in manuscript editing; and Dr. Jaime Núñez for his collaboration with the English language revision. The authors acknowledge ANID BECAS/DOCTORADO NACIONAL 21211334. The authors would also like to thank the patient and his family for their collaboration and contribution.

### CONFLICT OF INTEREST

The authors declare that they have no conflict of interest.

### AUTHOR CONTRIBUTIONS

WAMA, HMRZ, MEZG and NAEM were directly involved in the management of the case. WAMA, ESPD, AYRC, NAEM and HMRZ prepared the manuscript. BRD performed FISH and chromosome microarray analysis. All authors approved the content of the manuscript and confirmed the accuracy or integrity of every part of the work.

### ETHICAL APPROVAL

Written informed consent was obtained from the patient's legal representative. Reporting of this clinical case was approved by the Catholic University of Honduras IRB.

### CONSENT

Written informed consent was obtained from the patient's legal representative.

### DATA AVAILABILITY STATEMENT

None.

### ORCID

Héctor M. Ramos-Zaldívar  <https://orcid.org/0000-0002-0612-8289>

### REFERENCES

1. Bull MJ. Down syndrome. *N Engl J Med*. 2020;382(24):2344-2352. doi:10.1056/NEJMra1706537
2. Sherman SL, Allen EG, Bean LH, Freeman SB. Epidemiology of Down syndrome. *Ment Retard Dev Disabil Res Rev*. 2007;13(3):221-227. doi:10.1002/mrdd.20157
3. Ramos-Zaldívar HM. Eidikology: proposition for a new terminology for the science of rare diseases. *Postgrad Med J*. 2019;95(1125):406. doi:10.1136/postgradmedj-2019-136590
4. Biesecker LG, Spinner NB. A genomic view of mosaicism and human disease. *Nat Rev Genet*. 2013;14(5):307-320. doi:10.1038/nrg3424
5. Papavassiliou P, Charalsawadi C, Rafferty K, Jackson-Cook C. Mosaicism for trisomy 21: a review. *Am J Med Genet A*. 2015;167A(1):26-39. doi:10.1002/ajmg.a.36861
6. Shin M, Siffel C, Correa A. Survival of children with mosaic Down syndrome. *Am J Med Genet A*. 2010;152A(3):800-801. doi:10.1002/ajmg.a.33295
7. Rasmussen SA, Wong L-Y, Correa A, Gambrell D, Friedman JM. Survival in infants with Down syndrome, Metropolitan Atlanta, 1979-1998. *J Pediatr*. 2006;148(6):806-812. doi:10.1016/j.jpeds.2006.01.010
8. Papavassiliou P, York TP, Gursoy N, et al. The phenotype of persons having mosaicism for trisomy 21/Down syndrome reflects the percentage of trisomic cells present in different tissues. *Am J Med Genet A*. 2009;149A(4):573-583. doi:10.1002/ajmg.a.32729
9. Leon E, Zou YS, Milunsky JM. Mosaic Down syndrome in a patient with low-level mosaicism detected by microarray. *Am J Med Genet A*. 2010;152A(12):3154-3156. doi:10.1002/ajmg.a.33739
10. Paoloni-Giacobino A, Lemieux N, Lemyre E, Lespinasse J. Specific language impairment as the prominent feature in a patient with a low-level trisomy 21 mosaicism. *J Intellect Disabil Res*. 2007;51(Pt 5):401-405. doi:10.1111/j.1365-2788.2006.00912.x
11. Bermudez BEB, de Oliveira CM, de Lima Cat MN, Magdalena NIR, Celli A. Gastrointestinal disorders in Down syndrome. *Am J Med Genet A*. 2019;179(8):1426-1431. doi:10.1002/ajmg.a.61258
12. Hsiang YH, Berkovitz GD, Bland GL, Migeon CJ, Warren AC. Gonadal function in patients with Down syndrome. *Am J Med Genet*. 1987;27(2):449-458. doi:10.1002/ajmg.1320270223
13. Zhu JL, Hasle H, Correa A, et al. Survival among people with Down syndrome: a nationwide population-based study in Denmark. *Genet Med*. 2013;15(1):64-69. doi:10.1038/gim.2012.93

14. Winawer MR, Griffin NG, Samanamud J, et al. Somatic SLC35A2 variants in the brain are associated with intractable neocortical epilepsy. *Ann Neurol*. 2018;83(6):1133-1146. doi:10.1002/ana.25243
15. Yokoyama Y, Narahara K, Kamada M, Tsuji K, Seino Y. Tissue-specific mosaicism for trisomy 21 and congenital heart disease. *J Pediatr*. 1992;121(1):80-82. doi:10.1016/s0022-3476(05)82547-8
16. Homma S, Messé SR, Rundek T, et al. Patent foramen ovale. *Nat Rev Dis Prim*. 2016;2:15086. doi:10.1038/nrdp.2015.86

**How to cite this article:** Moncada Arita WA, Perdomo Domínguez ES, Rivera Caballero AY, et al. Multi-tissue cytogenetic analysis for the diagnosis of mosaic Down syndrome: A case report. *Clin Case Rep*. 2022;10:e05604. doi:[10.1002/ccr3.5604](https://doi.org/10.1002/ccr3.5604)