

Poorly Cohesive Cell Carcinoma of the Gallbladder with Signet Rings and Neuroendocrine-Like Morphology: A Rare Incidental Histopathological Diagnosis with Lessons to Learn

Authors' Contribution:
Study Design A
Data Collection B
Statistical Analysis C
Data Interpretation D
Manuscript Preparation E
Literature Search F
Funds Collection G

ADEF 1 **Ali Al Khader**
E 2 **Esra Nsour**
F 3 **Ahmad Alrubaye**
F 1 **Mohamad Al-Saghbini**

1 Faculty of Medicine, Al-Balqa Applied University, Al-Salt, Jordan
2 Department of Pathology, Al Hussein Salt Hospital, Al-Salt, Jordan
3 Department of General Surgery, Al Hussein Salt Hospital, Al-Salt, Jordan

Corresponding Author: Ali Al Khader, e-mail: ali.alkhader@bau.edu.jo
Conflict of interest: None declared

Patient: Male, 46
Final Diagnosis: Poorly cohesive cell carcinoma of the gallbladder
Symptoms: Abdominal pain
Medication: —
Clinical Procedure: Surgery and chemotherapy
Specialty: Pathology

Objective: Rare disease





Background: Poorly cohesive cell carcinoma of the gallbladder is extremely rare.

Case Report: Here we present a case of a 46-year-old male with the clinical diagnosis of acute cholecystitis. The ultrasound showed gallbladder wall thickening and multiple stones. Cholecystectomy was performed, and the gross examination revealed linitis plastica-like thickening of the gallbladder wall. The microscopic examination revealed diffuse infiltration by a poorly differentiated tumor with signet rings. Another component with insular growth pattern and salt-and-pepper nuclei was present. Immunohistochemical findings were consistent with poorly cohesive cell carcinoma of the gallbladder. Imaging studies revealed regional lymph nodes involvement, in addition to peritoneal and liver metastases. The patient was given chemotherapy, and there was no evidence of disease progression at 4 months post-operation.

Conclusions: This case supported that all cholecystectomy specimens must be examined. In addition, although poorly cohesive cell carcinoma was reported to be aggressive, the present case showed a protracted clinical course; this pointed to the need for early clinicoradiological suspicion. This is the first case of poorly cohesive cell carcinoma of the gallbladder with a neuroendocrine-like morphology that mimics mixed adenoneuroendocrine carcinoma. Immunohistochemistry is invaluable in such a scenario.

MeSH Keywords: Carcinoma, Neuroendocrine • Carcinoma, Signet Ring Cell • Gallbladder

Full-text PDF: <https://www.amjcaserep.com/abstract/index/idArt/919095>

 965   4  19



Background

Gallbladder carcinoma is relatively common among malignant neoplasms of the biliary tract [1]. It shows a female predominance and significantly varies geographically [2]. Although conventional adenocarcinoma is the most common histologic subtype of gallbladder cancer [3], signet ring carcinoma is extremely rare with few cases reported in literature [4]. According to the World Health Organization (WHO) 2010, signet ring carcinoma of the gallbladder is classified as poorly cohesive cell carcinoma (with or without signet rings) [5]. These tumors are highly aggressive. Most of the reported cases had advanced stage and a median survival of less than 4 months [5]. Histologically, these tumors are characterized by cordlike or individual cell pattern of growth. Infiltration into the stroma is characteristic. Only less than half of the cases show focal high-grade dysplasia of the overlying epithelium. Signet cell morphology (sometimes very focal) is always present [5], and mucin can be focally seen [6]. Here we present a case of a 46-year-old male with poorly cohesive cell carcinoma of the gallbladder diagnosed after laparoscopic cholecystectomy for acute cholecystitis. The clinical presentation and the peculiar gross and histomorphological characteristics of the tumor in our case add to the very limited data available on this entity.

Case Report

This 46-year-old male had a 5-year history of intermittent epigastric and right upper quadrant abdominal pain, increasing after fatty meals. One week prior to the operation, he complained of continuous severe right upper quadrant pain. Abdominal ultrasound revealed multiple gallbladder stones and thickening

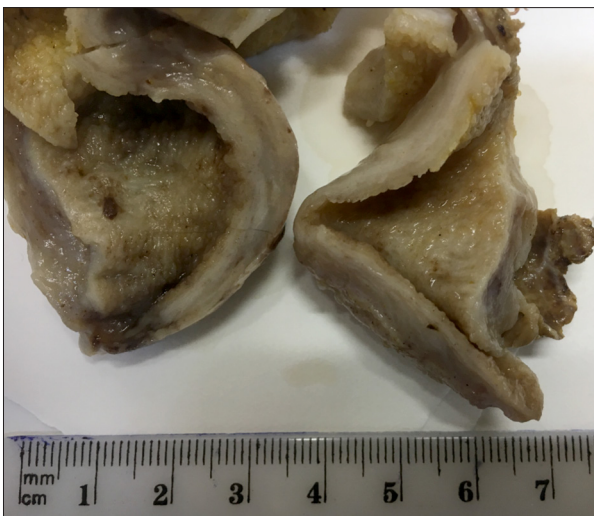


Figure 1. Linitis plastica appearance of the gallbladder.

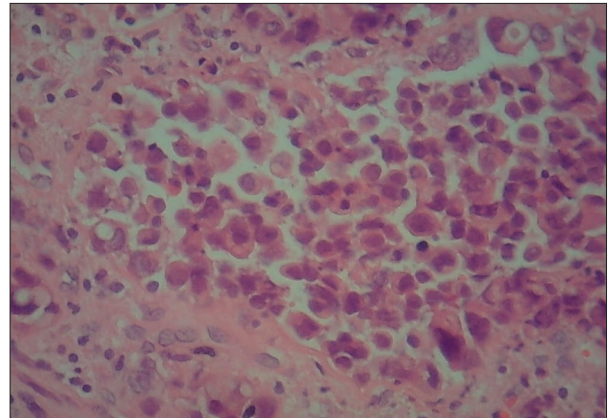


Figure 2. Many signet ring cells diffusely infiltrating the gallbladder wall are seen (hematoxylin and eosin staining, 400 \times).

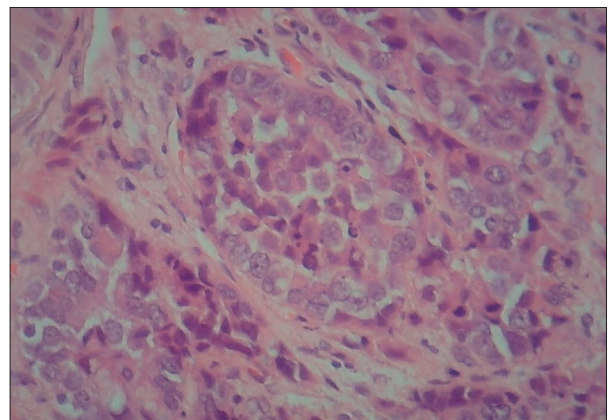


Figure 3. Tightly packed nests with peripheral palisading and salt-and-pepper appearance of the nuclei (hematoxylin and eosin staining, 400 \times).

of the gallbladder wall. The clinical diagnosis was acute cholecystitis and laparoscopic cholecystectomy was performed.

Gross examination revealed diffuse rigidity and thickening of the gallbladder wall akin to linitis plastica (Figure 1). Microscopic examination showed mucosal infiltration by a poorly differentiated tumor showing diffuse and insular growth patterns. The adjacent epithelium was unremarkable with no evidence of dysplasia. Many signet ring cells diffusely infiltrating the gallbladder wall were seen (Figure 2). In addition to this individual-cell pattern, tightly packed nests of tumor cells (insular pattern) constituted almost 50% of the tumor. The cells in these nests showed salt-and-pepper nuclei and peripheral palisading (Figure 3). The tumor nests also appeared infiltrating the wall layers and perforating the visceral peritoneum. Lymphovascular invasion was identified. Further examination of the cystic duct margin showed stromal invasion by the malignant tumor. In addition, 1 nearby lymph node was harvested and was positive for malignancy. Immunohistochemical staining was performed

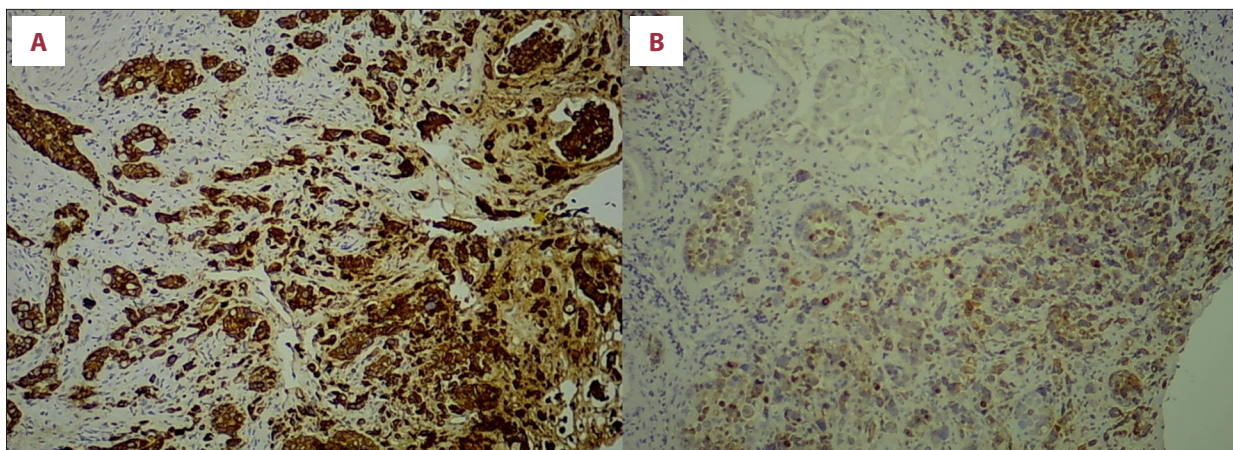


Figure 4. Both tumor components are diffusely positive for cytokeratin 7 (A) and MUC1 (B).

for cytokeratin 7, cytokeratin 20, MUC1, MUC2, CA19.9, synaptophysin, chromogranin, neuron-specific enolase (NSE), and CD56. Both tumor components showed diffuse positivity for cytokeratin 7 and MUC1 (Figure 4). Synaptophysin, chromogranin, NSE, CD56, cytokeratin 20, and MUC2 were negative. CA19.9 was positive in the tumor nests with a weaker staining intensity in the signet ring cells. The case was signed out as poorly cohesive cell carcinoma of the gallbladder with signet rings. Imaging studies revealed regional lymph nodes involvement, in addition to peritoneal and liver metastases. The patient was given chemotherapy, and there was no evidence of disease progression at 4 months post-operation. Written informed consent was obtained from the patient for publication of this case report and accompanying images.

Discussion

Although gallbladder cancer is the most common biliary malignancy, poorly cohesive cell type is extremely rare. Cholelithiasis is an independent risk factor for gallbladder carcinoma and it is a common associated finding as in our case [3]. Poorly cohesive cell carcinoma of the gallbladder has an aggressive behavior. The present case showed invasion of the cystic duct and metastases to the liver, peritoneum and regional lymph nodes. A similar behavior was also reported by Bazan et al. They also reported pleural and subcutaneous metastases [7]. Metastatic poorly cohesive cell carcinoma of the gallbladder was also reported by Krunic et al. [8], Karabulut et al. [9], Minami et al. [10], Mondal [11], Pavić et al. [12], Czystczon and Alatassi [13] and Pudasainin et al. [14]. In a report by Ohno et al. [15], the gallbladder tumor was complicated by pulmonary thrombotic microangiopathy. The advanced stage at presentation may be caused in part by the clinical overlap with benign conditions, which may delay the diagnosis of most cases [11]. The unexpected histopathological diagnosis of our case supports that all cholecystectomy specimens must

be examined. In addition, the tumor grossly resembled linitis plastica and no discrete mass was noted. This was comparable to the reports by Agarwal et al. [4], Czystczon and Alatassi [13], Ahmad and Qureshi [16], and Padhiari et al. [17]. On the other hand, many reported cases presented as discrete masses in a background of diffuse or focal wall thickening [9,11,14,18]. Metastatic signet ring carcinoma of stomach or colon origin must be ruled out. The tumor in our case was positive for cytokeratin 7, MUC1, and CA19.9, while it was negative for cytokeratin 20 and MUC2. These immunohistochemical findings were consistent with a gallbladder origin [7]. A peculiar histomorphological finding in our case was the presence of an insular pattern of growth with peripheral palisading and salt-and-pepper nuclei. This component constituted almost half of the tumor, which was morphologically suggestive of mixed adenoneuroendocrine carcinoma [19]. Interestingly, these foci were negative for synaptophysin, chromogranin, NSE and CD56, while they were positive for cytokeratin, so mixed adenoneuroendocrine carcinoma was excluded.

Conclusions

All cholecystectomy specimens must be examined. In addition, poorly cohesive cell carcinoma must be suspected in any metastatic poorly differentiated carcinoma. Although this type was reported to be aggressive, our case demonstrated a protracted clinical course, which makes the early clinicoradiological suspicion necessary. Moreover, this is the first case of poorly cohesive cell carcinoma of the gallbladder with neuroendocrine-like morphology. This mimicry with mixed adenoneuroendocrine carcinoma must be put in mind and immunohistochemical staining is necessary.

Name of Department and Institution where work was done

Faculty of Medicine, Al-Balqa Applied University, Al-Salt, Jordan

Conflict of interest

None.

References:

1. Misra S, Chaturvedi A, Misra NC, Sharma ID: Carcinoma of the gallbladder. *Lancet Oncol*, 2003; 4: 167–76
2. Hundal R, Shaffer EA: Gallbladder cancer: Epidemiology and outcome. *Clin Epidemiol*, 2014; 6: 99–109
3. Donohue JH, Stewart AK, Menck HR: The National Cancer Data Base report on carcinoma of the gallbladder, 1989–1995. *Cancer*, 1998; 83: 2618–28
4. Agarwal S, Pandey P, Durgapal P, Krishna M: Linitis plastica like primary signet ring cell carcinoma of the gallbladder – an extremely rare variant. *Pathologica*, 2016; 108: 169–74
5. Tuncel D, Roa JC, Araya JC et al: Poorly cohesive cell (diffuse-infiltrative/signet ring cell) carcinomas of the gallbladder: Clinicopathological analysis of 24 cases identified in 628 gallbladder carcinomas. *Hum Pathol*, 2017; 60: 24–31
6. Dursun N, Escalona OT, Roa JC et al: Mucinous carcinomas of the gallbladder: Clinicopathologic analysis of 15 cases identified in 606 carcinomas. *Arch Pathol Lab Med*, 2012; 136: 1347–58
7. Bazan F, Sanchez J, Aguilar G et al: Metastatic gallbladder adenocarcinoma with signet-ring cells: A case report. *J Med Case Rep*, 2011; 5: 458
8. Kronic AL, Chen HM, Lopatka K: Signet-ring cell carcinoma of the gallbladder with skin metastasis. *Australas J Dermatol*, 2007; 48: 187–89
9. Karabulut Z, Yildirim Y, Abaci I et al: Signet-ring cell carcinoma of gallbladder: A case report. *Adv Ther*, 2008; 25: 520–23
10. Minami Y, Nagano Y, Ueda M: [A case of resected signet ring cell carcinoma arising from the gallbladder.] *Nihon Gekakei Rengo Gakkaishi*, 2009; 34: 631–35 [in Japanese]
11. Mondal SK: Signet ring cell carcinoma of gallbladder with celiac lymph node metastasis in a young man. *J Cancer Res Ther*, 2010; 6: 379–81
12. Pavić I, Marusić Z, Mijić A et al: A case of signet ring cell carcinoma of the gall bladder: Immunohistochemistry and differential diagnosis. *Acta Clin Croat*, 2010; 49: 159–62
13. Czyszczon IA, Alatassi H: Signet ring cell carcinoma of the gallbladder in a 22-year-old man: A case report and review of the literature. *Int J Surg Pathol*, 2010; 18: 358–62
14. Pudasaini S, Subedi N, Prasad KBR et al: Signet ring cell carcinoma of the gall bladder: A case report. *Nepal Med Coll J*, 2011; 13: 308–10
15. Ohno Y, Kumagi T, Kuroda T et al: Signet-ring cell carcinoma of the gallbladder complicated by pulmonary tumor thrombotic microangiopathy. *Intern Med*, 2014; 53: 1125–29
16. Ahmad Z, Qureshi A: Primary signet ring cell carcinoma of gall bladder: Report of an extremely rare histological type of primary gall bladder carcinoma. *BMJ Case Rep*, 2010; 10: 1136–39
17. Padhiari RK, Ahmed N, Praveen GP et al: Extreme rare case of primary signet ring cell carcinoma of gall bladder – case report. *Cancer and Clinical Oncology*, 2014; 3: 25–29
18. Ahmed GN, Mandal PK, Chatterjee S, Das S: Signet ring cell carcinoma of the gallbladder: Report of a case and review of the literature. *Cer San D (J Surg Arts)*, 2014; 7: 48–51
19. Azad S, Shukla D, Garg A et al: Mixed adenoneuroendocrine carcinoma of the gallbladder, histopathological features. *Indian J Pathol Microbiol*, 2015; 58: 543–45