

# Video-Assisted Thoracoscopic Surgery for Drainage of Dorsal Paravertebral Abscess



Raju Vaishya, M.S., M.Ch., F.R.C.S., Vipul Vijay, M.S., D.N.B., Dip. SICOT, and Amit K. Agarwal, M.S., D.N.B., M.Ch.

**Abstract:** Tuberculosis of the spine is the second most common extrapulmonary presentation of the disease and is associated with significant morbidity. The drainage of the abscess may be needed in patients who fail to respond to medical treatment and present with a significant or deteriorating neurologic status. The dorsal spine gives a unique opportunity for decompression alone as it is supported by the rib cage, decreasing the chances of collapse. Drainage of the abscess in the dorsal spine usually needs an open thoracotomy. Open thoracotomy is associated with increased blood loss, pain, and increased postoperative rehabilitation period. Video-assisted thoracoscopic surgery (VATS) is an excellent alternative for decompression of dorsal paraspinal abscess with significantly decreased blood loss, soft tissue dissection, scarring, and hospital stay. Overall, this leads to significantly decreased postoperative morbidity and faster recovery. The purpose of this article was to describe the indications and procedure of VATS for drainage of dorsal spine paravertebral abscess.

**T**uberculosis (TB) is making a global comeback because of large population migration and the recently increased population of immune-compromised people due to HIV etc.<sup>1</sup> The spine is the second most common site for extrapulmonary tubercular involvement.<sup>2</sup> Although medical therapy alone is considered the gold standard in most cases, it alone may not be adequate in special situations. These special situations include patients with deteriorating neurologic status, poor response to treatment, multidrug-resistant TB, etc. In these cases, surgical decompression of the cold abscess along with debridement may help improve the response to chemotherapy and improve prognosis. Open anterior decompression and bone grafting has provided excellent results in dorsal spine TB, but it may be associated with a higher risk of morbidity due to thoracotomy.<sup>3</sup>

Video-assisted thoracoscopic surgery (VATS) could provide a solution to this problem, with much lesser

complication rates and morbidity. The VATS can help decompress the dorsal spine in situations where there is a large cold abscess. Because the dorsal spine is supported by ribs, decompression alone without fixation can give good results in selected patients. The VATS helps in decompressing the pressure effect of the cold abscess, provides a sample for drug sensitivity testing and is associated with much lesser postoperative morbidity. Kapoor et al.<sup>4</sup> have reported good functional outcomes with much lesser morbidity as compared with open thoracotomy.

An ideal patient for VATS is one with dorsal spine tuberculosis with a large cold abscess that is not responding to antitubercular therapy (Fig 1). This cold abscess may be causing a mass effect on the cord leading to pain or development of neurologic symptoms. The relative contra-indications are the presence of severe lung adhesions, pectus excavatum, inability to bear single lung ventilation, and coagulopathy. Patients with multiple-level disease and a prolonged disease course are not ideal candidates for VATS decompression as the soft tissue abscess is difficult to delineate.<sup>5</sup>

We describe here the technique of VATS for the decompression of cold abscess in the dorsal spine.

## Technique

### Anaesthesia

VATS requires an experienced anesthesia team that can manage the patient with a single lung ventilation.

*From the Department of Orthopaedics, Joint Replacement & Arthroscopy, Indraprastha Apollo Hospital, New Delhi, India.*

*The authors report that they have no conflicts of interest in the authorship and publication of this article.*

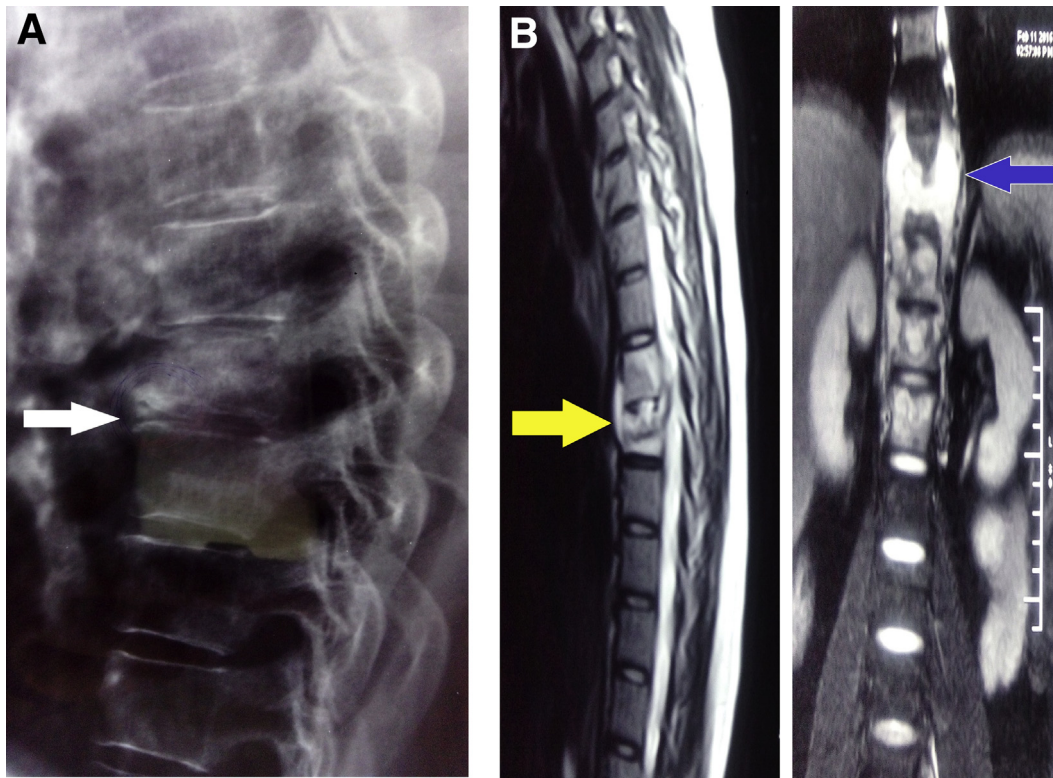
*Received November 24, 2016; accepted March 30, 2017.*

*Address correspondence to Vipul Vijay, M.S., D.N.B., Dip. SICOT, Department of Orthopaedics, Joint Replacement & Arthroscopy, Indraprastha Apollo Hospital, New Delhi 110076, India. E-mail: [dr\\_vipulvijay@yahoo.com](mailto:dr_vipulvijay@yahoo.com)*

*© 2017 by the Arthroscopy Association of North America*

*2212-6287/161173/\$36.00*

*<http://dx.doi.org/10.1016/j.eats.2017.03.035>*



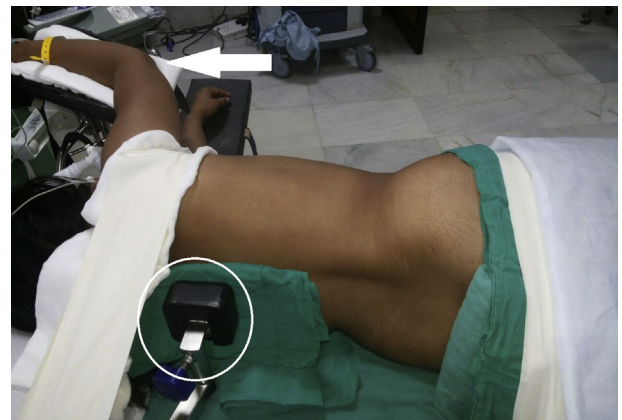**Fig 1.** (A) Lateral dorsal spine radiograph revealing decreased disc space at D8-D9 (white arrow). (B) Magnetic resonance imaging showing prevertebral abscess with epidural extension (yellow arrow) and paravertebral abscess (blue arrow) compressing the cord. Partial collapse of D9 vertebra is also seen.

The patient is given general anesthesia using a double lumen tube. This helps in decompressing the lung on the side of the pathology. Careful intraoperative and postoperative monitoring of the patients is needed, and the anesthesia team should be able to manage the hemodynamic shifts that can occur with the use of single lung ventilation.

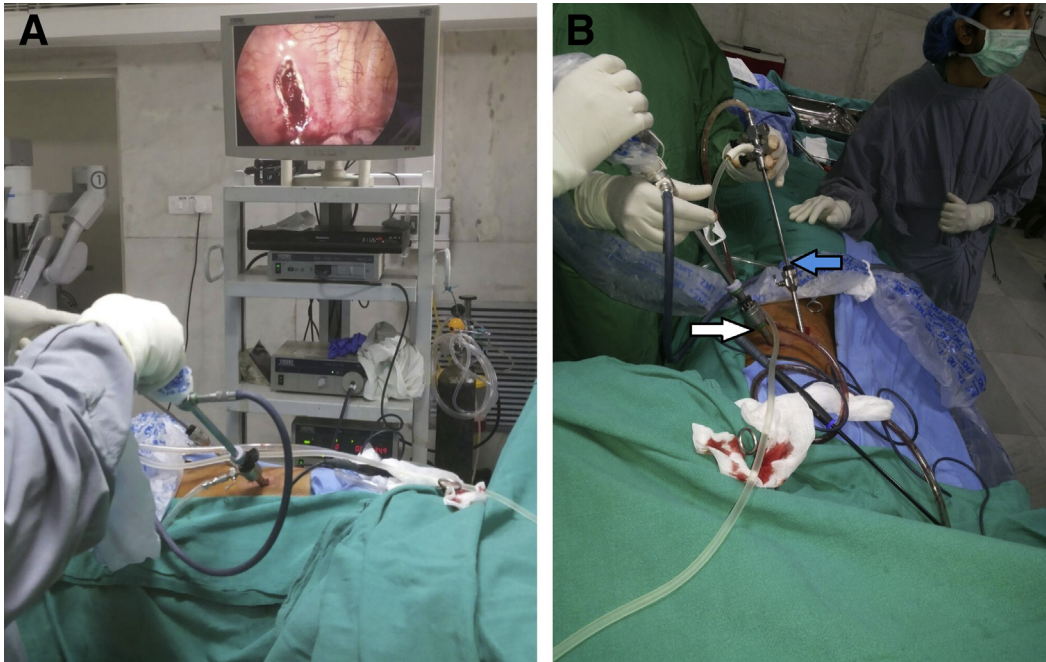
### Patient Positioning

The patient is placed in the lateral decubitus position (Fig 2). The left/right lateral position is decided by the location of abscess in preoperative magnetic resonance imaging. The side that has the maximum volume of the paravertebral abscess is kept up. The surgical table is flexed to the maximum in the middle so that the ribs and the intercostal spaces are opened for easy access to the lungs through the wider intercostal spaces. The breaking of the table in the middle also helps in bringing the hips down so that the manipulation of the instruments becomes easier. The neck needs to be supported so that the spine is kept straight. The upper limbs are supported adequately on an overhead arm board with good padding on the bony prominences to avoid neuropraxia. The hips and knees are flexed at 90° to prevent any neuropraxic injury in the lower limb. A pillow is kept between the two legs. The bending of the knees and hips helps in

prevention of log rolling of the patient and also helps in stabilizing the position. Moreover, additional supports are added in the middle thoracic spine and pubic symphysis area for further stabilization of the position (Fig 2). An adequate padding of all the bony prominences is important to avoid pressure-related complications.



**Fig 2.** Patient in the lateral decubitus position with the break in the operating table to open up the intercostal space. The arm is supported on a soft support protecting the bony prominences (white arrow). A padded post (circle) is applied at the posterior aspect of the thorax to support the patient.



**Fig 3.** (A) The final operating room set up with the console near the anterior chest wall opposite to the surgeon. (B) The final set up on the surgeon side with the thoracoscope in the viewing portal (white arrow) and the suction cannula in the working portal (blue arrow). The scrub nurse is standing on the foot end of the patient for ease of transfer of instruments.

### Operating Room Setup

After confirming stable positioning of the patient, the operating surgeon and assistant stand along the anterior chest wall of the patient. The thoracoscopy console system (including a monitor, light source, ultrasonic coagulator) is positioned on the opposite site. The OR staff is assisting in the surgery usually stands at the foot end of the patient alongside the console, to provide an unhindered view of the console to the surgeon and for the ease of transfer of instruments (Fig 3).

### Equipment

The VATS can be performed with the usual fiber optic light source and an imaging system attached to a camera used in arthroscopy. The additional equipment required are the instruments used in laparoscopy. The normal thoracoscope used is a 10-mm (30°-45°) scope (Karl Storz, El Segundo, CA). An ultrasonic dissector-coagulator (Harmonic Scalpel; Ethicon, Bridgewater, NJ) is used in the surgery along with long dissectors, graspers, and punch forceps (BD CareFusion, Franklin Lakes, NJ) (Fig 4). Further, special trocar sleeves are used with blunt tip obturator (Endopath, Ethicon Endosurgery, Cincinnati, OH) for maintaining the portals after creation for ready access (Fig 5). We use carbon dioxide insufflation of the lung in this procedure as it further helps in decompression and collapse of the lung and makes the visualization of the paravertebral abscess easier. The pressure is kept under 8 mm Hg, and

a close watch on the hemodynamic status is needed because of the nonyielding nature of the chest wall as compared to the abdomen.

### Port Placement

The placement of portals is one of the most important steps in achieving the ease of visualization and adequate decompression of the abscess. As in arthroscopy, VATS requires excellent triangulation skills for the ideal management of lesions. The triangulation in the thoracoscopic surgeries is made difficult because of the presence of unyielding chest wall, almost fixed intercostal space, the presence of heart, and in some cases because of the presence of severe deformities.

The lateral aspect of the chest wall, in the cases undergoing thoracoscopic surgeries, can be divided between the working zone and the viewing zone. The working and viewing zones for thoracoscopy are interchangeable and are decided by the site of pathology. While dealing with a spinal pathology, it is easier to view the pathology by keeping the viewing zone posterior to the midaxillary line and the working zone anterior to the midaxillary line (Fig 6). It is better to keep the viewing portal directly above the involved spinal segment.


The accessory working portals are evenly placed cephalad and caudad to the viewing portal. This even placement of the working portals around the viewing portal is important for good triangulation at the site of the pathology.



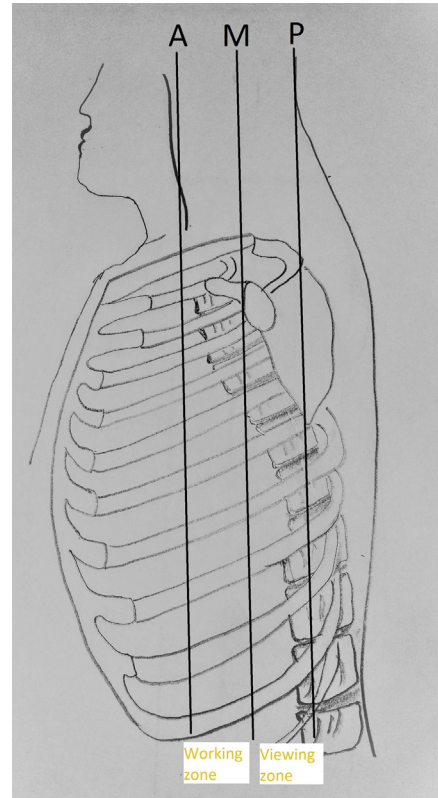
**Fig 4.** Instruments used in thoracoscopy. (D, dissector; G, grasping forceps for tissue biopsy; P, hook electrode probe; T, 0° thoracoscope.)

### General Tips for Portal Creation

After identification of the site of portal creation, a 1- to 1.5-cm incision is given in the desired intercostal space posterior to the midaxillary line. The site of skin incision may be infiltrated with a local anesthetic and epinephrine combination before the incision. This site should be along the upper border of the rib to avoid the intercostal neurovascular bundle.



**Fig 5.** The trocars with cannula that are used for creation of ports during thoracoscopy.



**Fig 6.** A diagrammatic representation of the patient positioning with the viewing and working field depicted. The working field is between the anterior axillary line (A) and the midaxillary line (M). The viewing field is between the midaxillary line (M) and the posterior axillary line (P).

After the skin incision, a closed hemostat is inserted through the intercostal musculature and parietal pleura. The tips of the hemostat are opened to adequately widen the portal site. The gloved finger of the surgeon is then finally inserted. This finger is used for the identification of any intrapleural adhesions. The presence of adhesions may warrant a change in the portal site. After ruling out any intrapleural adhesions, the trocar is finally inserted. After creation of the first viewing portal, all other portals are created under direct vision.

There are certain structures that are at risk at the time of portal creation. The intercostal neurovascular bundle is at risk at every intercostal level, and hence care must be taken to create the portal at the upper border of the rib. During the creation of portals below the T7 vertebra, special caution is needed to avoid inadvertent diaphragm perforation. Similarly, far anterior portals risk the internal mammary artery and mediastinal structures and hence require careful creation.

The easiest access to the spine is at the level of D5-T10 as these vertebrae are centrally located in the cavity. The vertebral levels D11-L1 require special maneuver as they require the mobilization of the diaphragm. The

head end of the operating table can be elevated to assist abdominal structures to fall caudad and ease diaphragm retraction. The clear visualization of D12-L1 may sometimes require the release of the pulmonary ligament.

### First Portal

Because the pathology in this case was localized to the D8-D9 intervertebral disc, the first portal is made in the seventh intercostal space in line with the anterior axillary line. A thorough diagnostic thoracoscopy was performed to identify the extent of the paraspinal abscess (Fig 7).

### Second and Third Portal

After the creation of the first portal, the endoscope is inserted, and the remaining portals are created under direct vision. The second portal is created just posterior to the midaxillary line (Fig 7). This second portal is created one intercostal space below the first portal. Additional portals may be made as per the requirement of the procedure. In the present case, a third portal was created in line with the first portal in the eighth intercostal space.

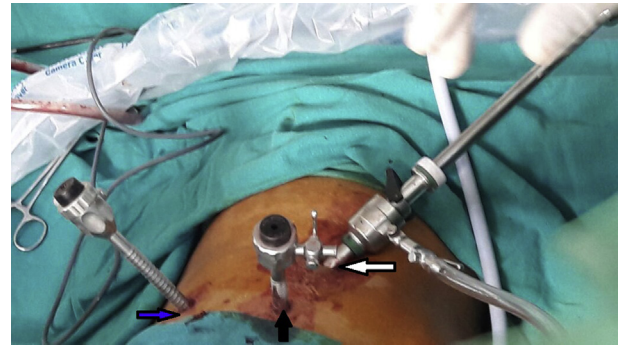
Additional portals may be created, if needed, during the surgery. One of these portals is the viewing portal and the second is the instrument portal, which can be switched between each other.

Because we had to address a spinal pathology, the thoracoscope was switched and inserted in the second portal (behind the midaxillary line). The first and the third portal created act as the working portals.

### Abscess Drainage

After creation of the portals, a diagnostic thoracoscopy is performed, and the site of the abscess is identified. The abscess is delineated for its extent, both anteroposteriorly and mediolaterally (Fig 8A). Any adhesions, if present, are freed by blunt dissection. After complete delineation of the abscess, electrocautery is used to cut the parietal pleura over the abscess. Usually, because of the presence of pus and debris under tension, it usually gushes out under pressure as soon as the parietal pleura is cut (Fig 8B). It is important to probe the cavity completely and in all directions to break the adhesions inside the cavity and release all the pus and caseous material. The cavity needs to be probed, and the electrocautery tip can be used for breaking the adhesions.

The sample collected can be sent for culture sensitivity and stains. A thorough debridement of the cavity needs to be done. This diseased tissue is sent for histopathologic examination. A thorough lavage of the cavity is also performed to help in removal of any further tissue debris and remove any remnant pus in the cavity (Video 1).



**Fig 7.** Portal placement. The first portal is made in the seventh to eighth intercostal space in line with the anterior axillary line (white arrow). The second portal is placed in line with the midaxillary line (black arrow). An additional portal has been created here in line with the postaxillary line for suction (blue arrow). The patient is in the left lateral decubitus position.

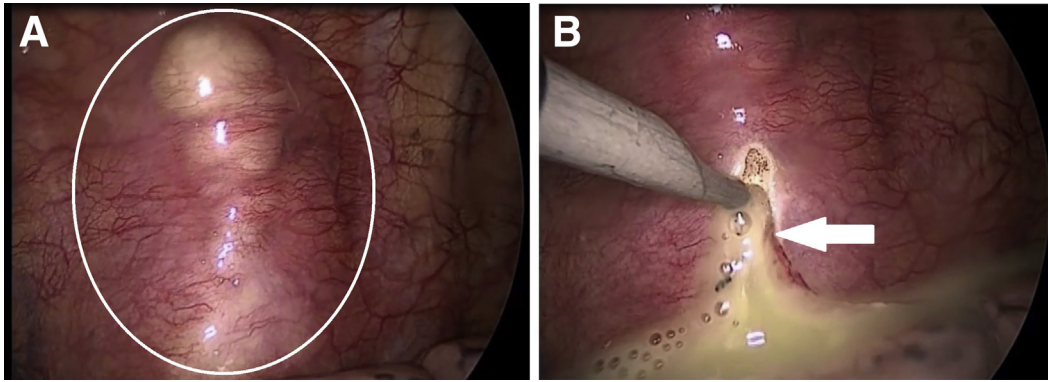
### Postoperative Care

After the adequate decompression and debridement of the cavity, a chest tube is inserted through one of the portals. The inflation of the lung is visualized under direct vision to look for any area of persistent atelectasis post lung inflation. The chest tube is secured to the skin with a suture for later removal (Fig 9). The chest musculature and the subcutaneous tissues are closed with absorbable sutures. The patient is allowed to sit up as per comfort as soon as the patient is conscious and the chest tube is removed when the collection is less than 100 mL in 24 hours. The patient can be discharged on the third postoperative day after the removal of the drain. Antitubercular therapy is continued as per protocol, and the patient is additionally given Taylor's brace for additional support to the dorsal spine.

### Discussion

Tuberculosis of the spine is the most common extra-skeletal form of tuberculosis seen. The presence of a tubercular lesion in the dorsal spine is more likely to be symptomatic because of the narrow neural canal. Conservative means of treatment including rest and antitubercular therapy remain the mainstay for the management of these lesions. If the patient fails a trial of the medical treatment (no symptomatic improvement, worsening neurologic signs, etc.), he or she may need decompression. Because tuberculous infection is mainly located in the anterior aspect of the vertebra, any approach that provides an anterior decompression is considered ideal. Open thoracotomy had been used in the past for anterior decompression of the dorsal spine, but it was associated with an increased incidence of complications.<sup>6</sup>

The VATS is a comparatively less morbid alternative to the open thoracotomy for decompression and biopsy



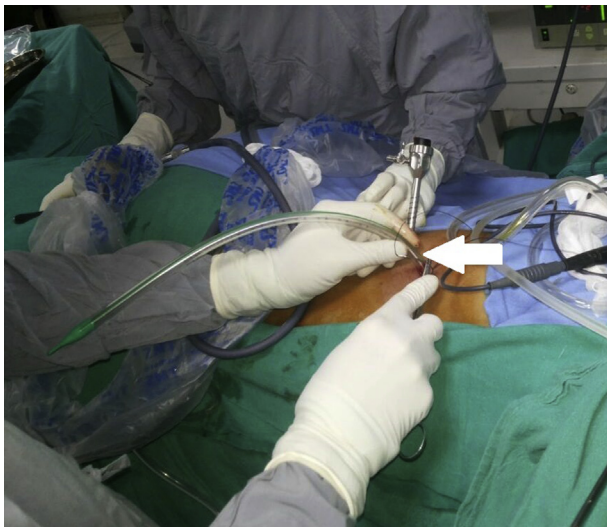
**Fig 8.** (A) The abscess cavity tracking along the rib and distending the parietal pleura (white circle). (B) The drainage of abscess cavity with pus being drained under pressure (white arrow). The patient is in left lateral decubitus position. The viewing portal is the posterior portal in line with the posterior axillary line, and the working portal is the anterior portal in line with the anterior axillary line.

of the tubercular lesions of the dorsal spine. It offers less postoperative pain, faster recovery, lesser chances of pneumonia, and comparatively shorter hospital stay, among others (Table 1).<sup>4,5</sup> The reason for decreased postoperative morbidity in VATS as compared to thoracotomy is the smaller incision and retraction needed for adequate visualization. There is also much less soft tissue and muscle division. This in turn leads to the earlier return of pulmonary function and shoulder range of motion.<sup>7</sup> Moreover, the surgical scars are usually 1.5 to 2 cm at the site of the ports and are more cosmetic than a large open thoracotomy scar. Isolated decompression without fixation can be a treatment option in single level dorsal spine tuberculosis as the dorsal spine is supported by the bony rib cage, which provides protection against collapse. Another advantage with VATS is that it gives access to

the anterior aspect of the dorsal vertebra and helps in debridement and decompression right where the epicenter of the disease is. Also, it allows much faster rehabilitation and lesser morbidity as compared with open thoracotomy.

Although the advantages of VATS for dorsal spine abscess drainage and decompression are many, there are certain relative contraindications for its use. These include patients with severe pulmonary hypertension, inability to tolerate single-lung ventilation, and presence of dense pleural adhesions. The patients who have undergone previous major thoracic or esophageal surgeries like tumor resections etc. are also difficult candidates for VATS.

There are certain complications associated with VATS such as a persistent air leak, infection, bleeding, and the possibility of conversion of the surgery to an open thoracotomy. Persistent air leak is one of the most frequently reported complications of VATS, incidence ranging from 0.9% to 4.7%.<sup>8</sup> Persistent air leak is usually seen in patients undergoing VATS for lung parenchymal lesions. In the decompression of paravertebral abscess, the persistent air leak is rare and may occur in cases with severe adhesions.<sup>4</sup> Bleeding-related



**Fig 9.** The closure of the portals at the end of the procedure. The intercostal drainage tube is inserted in the viewing portal and the portal closed over it (white arrow).

**Table 1.** Salient Features of VATS

| Advantages                    | Disadvantages   |
|-------------------------------|---|
| Lesser pain                   | Unsuitable for patients with dense pleural adhesions                                  |
| Shorter hospital stay         | Unsuitable for candidates unfit for single-lung ventilation                           |
| Faster postoperative recovery | Need for special instruments (thoracoscope etc.)                                      |
| Lesser blood loss             | Difficulty in accessing lower dorsal lesion (D11-L1) because of vicinity of diaphragm |
| Less soft tissue dissection   | Learning curve  |
| No need for removal of ribs   |   |
| Little scarring               |   |

**Table 2.** Pearls and Pitfalls

## Pearls

1. The surgeon must carefully select ideal candidate for surgery.
2. The viewing field and the working field in spinal pathologies is opposite of lung parenchymal pathologies.
3. The position of the portals should be individualized for each case depending on spinal level accessed.
4. Care should be taken during portal creation to ensure it is at the upper border of intercostal space, to protect neurovascular bundle.
5. Blunt finger dissection is performed after port creation to identify and break adhesions.
6. Head-end elevation of table may assist visualization below D11-L1.

## Pitfalls

1. A portal too anterior may risk injury to internal mammary artery and mediastinal structures.
2. Port creation below T7 vertebra may lead to perforation of diaphragm.
3. Excessive bleeding may obscure vision and necessitate open thoracotomy.

complications have also been rarely reported, and VATS has been described to provide excellent visualization. In cases where VATS is used for thoracic spine decompression, bleeding may occur from the port site, especially in patients with coagulation defects.<sup>8</sup> Infections after VATS have been reported with an incidence ranging from 0.4% to 1.9%, but most of these cases are treatable with antibiotics.<sup>8</sup> In a series of VATS-assisted drainage of the abscess, Kapoor et al. reported an incidence of 10 cases of 30 patients who had port site infection. All these patients were found to have superficial wound infections that were treated with oral antibiotics, and all healed by secondary intention.<sup>4</sup> The overall incidence of complications with VATS has been reported to be low, and when combined with the decreased postoperative morbidity, it can be considered safe and efficacious in the management of dorsal paravertebral abscesses. The key to an acceptable surgical outcome following VATS is identifying the right candidate after ruling out the major contraindications to its use as already mentioned.

Even though there are reported complications, the overall complication rates are low.<sup>4,5</sup> This surgery takes less than an hour to perform, and there is minimal blood loss.<sup>6</sup> The rehabilitation is much faster, and almost all the patients can walk with the help of a brace the very next day of surgery. The visual analog scale scores associated with the disease are much less as compared with open thoracotomy, and the overall consumption of analgesics is drastically decreased. This

further translated into much lesser opioid/nonopioid analgesic-related side effects.

Guerado et al.<sup>9</sup> reported that although open decompression of spondylodiscitis is still the standard procedure, minimally invasive techniques like VATS have good results when used early in the disease course. Similarly, Singh et al.<sup>10</sup> in their series of patients treated with VATS for tubercular spondylitis reported good outcomes, with decreased blood loss and postoperative morbidity. The VATS is a safer and less cumbersome alternative to open thoracotomy, both to the patient and the surgeon. There are certain pearls and pitfalls associated with the procedure which can help the operating surgeon to achieve a good view and easy dissection (Table 2). In isolated, single-lesion dorsal spine tuberculosis with a large paraspinal abscess and minimal pleural adhesions, and which is not responding to conservative therapy, VATS and decompression and debridement of the lesion is a valid option with much lesser side effects and faster recovery time.

## References

1. Vijay V, Vaishya R. Isolated C-C joint tuberculosis—A diagnostic dilemma. *Foot (Edinb)* 2015;25:182-186.
2. Tuli SM, Srivastava TP, Varma BP, Sinha GP. Tuberculosis of spine. *Acta Orthop Scand* 1967;38:445-458.
3. Ikard RW. Methods and complications of anterior exposure of the thoracic and lumbar spine. *Arch Surg* 2006;141:1025-1034.
4. Kapoor S, Kapoor S, Agrawal M, Aggarwal P, Jain BK Jr. Thoracoscopic decompression in Pott's spine and its long-term follow-up. *Int Orthop* 2012;36:331-337.
5. Lü G, Wang B, Li J, Liu W, Cheng I. Anterior debridement and reconstruction via thoracoscopy-assisted mini-open approach for the treatment of thoracic spinal tuberculosis: Minimum 5-year follow-up. *Eur Spine J* 2012;21:463-469.
6. Kim SJ, Sohn MJ, Ryoo JY, Kim YS, Whang CJ. Clinical analysis of video-assisted thoracoscopic spinal surgery in the thoracic or thoracolumbar spinal pathologies. *J Korean Neurosurg Soc* 2007;42:293-299.
7. Newton PO, Marks M, Faro F, et al. Use of video assisted thoracoscopic surgery to reduce perioperative morbidity in scoliosis surgery. *Spine (Phila Pa 1976)* 2003;28:S249-S254.
8. Imperatori A, Rotolo N, Gatti M, et al. Peri-operative complications of video-assisted thoracoscopic surgery (VATS). *Int J Surg* 2008;6:S78-S81 (suppl 1).
9. Guerado E, Cerván AM. Surgical treatment of spondylodiscitis. An update. *Int Orthop* 2012;36:413-420.
10. Singh R, Gogna P, Parshad S, Karwasra RK, Karwasra PK, Kaur K. Video-assisted thoracic surgery for tubercular spondylitis. *Minim Invasive Surg* 2014;2014:963497.