




Sporotrichosis Mimicking Rosacea Lesions: A Case Report

You-shu Hong , Lun-fei Liu , Hong-hua Hu 

Department of Dermatology, the Fourth Affiliated Hospital of School of Medicine, and International School of Medicine, International Institutes of Medicine, Zhejiang University, Yiwu, 322000, People's Republic of China

Correspondence: Lun-fei Liu; You-shu Hong, Email 2197055@zju.edu.cn; 8021028@zju.edu.cn

Abstract: Sporotrichosis is a subacute or chronic infectious disease caused by sporothrix. It is mainly caused by Sporothrix inoculation after accidental skin injury during human labor. The clinical manifestations of sporotrichosis are variable, ranging from nodules, plaques, ulcers, verrucous lesions, and subcutaneous masses. Some reports indicate that sporotrichosis can mimic psoriasis-like lesions. We herein report a case of sporotrichosis mimicking rosacea lesions. In addition, the patient had a history of nasal trauma, and we believe that the patient was inoculated with Sporothrix after the nasal skin was damaged during labor activities. The patient was given itraconazole 200 mg orally daily for 3 months, which effectively resolved the rash.

Keywords: sporotrichosis, sporothrix, rosacea, itraconazole, histopathological

Introduction

Sporotrichosis is a rare skin disease that is a subacute or chronic infectious disease caused by sporothrix. In recent years, reports of sporotrichosis have gradually increased. It is mainly prevalent in tropical and subtropical regions. Mainly in the northeast region in China. Inoculation of sporothrix after accidental skin trauma is the main cause of sporotrichosis. Farmers are the susceptible population of sporotrichosis. Because farmers are more prone to skin wounds, and easier to contact with the soil, hay, crops, etc. The main types of sporotrichosis include lymphocutaneous sporotrichosis (LCS), fixed cutaneous sporotrichosis (FCS) and systemic sporotrichosis. The rash has various forms, such as papules, nodules, plaques, ulcers, verrucous lesions and subcutaneous masses. Patients' own factors such as immunosuppression status, drug use (glucocorticoids, antibiotics, biological agents, etc.), diabetes and other underlying diseases are the reasons for patients to be more susceptible to sporothrix infection. The clinical manifestations of sporotrichosis are variable, leading to the inability to quickly and accurately diagnose in clinical practice. It should be paid attention to in clinical work.

Case Report

A 63-year-old Chinese farmer presented with a history of papules and pustules on the nose for more than 1 month. There was no fever, no cough, no joint pain or other symptoms. The patient had a trauma of nasal skin, and no history of hypertension, diabetes or other diseases. Nationality: Chinese Han, height: 172 cm, weight: 67 kg, BMI: 22.67 kg/m². Analysis the patient's medical history and system examination found no abnormalities. The patient was treated with antibiotics at a local hospital, but the symptoms did not improve. A further physical examination showed papules and pustules with an erythematous base on the nose, which were partially ulcerated and covered with yellow crusts (Figure 1a). The head and neck and axillary lymph nodes were not palpable or enlarged.

Histopathological examination was performed (Figure 2a) which found epidermal pseudoepithelioma-like hyperplasia with diffuse intradermal infiltration of inflammatory cells including neutrophils, histiocytes, and plasma cells. Tissue cultures showed Sporothrix growth (Figure 2b And c). We believe that the patient was inoculated with sporothrix after the nasal skin was damaged during labor activities. Therefore, the patient was diagnosed with sporotrichosis and receive itraconazole 200 mg orally daily for 3 months. After treatment, the skin lesions gradually improved. (Figure 1b).

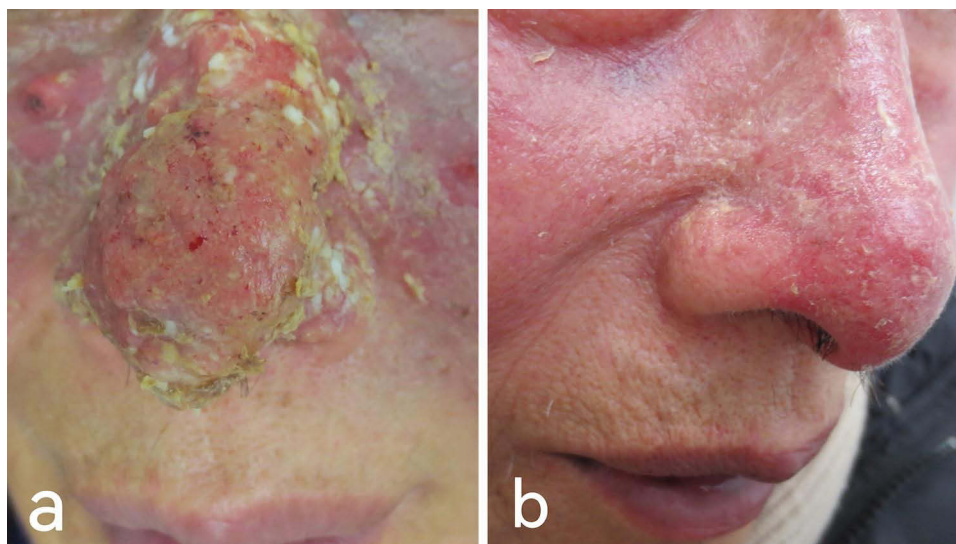


Figure 1 (a) Papules and pustules with an erythematous base on the nose. (b) After treatment.

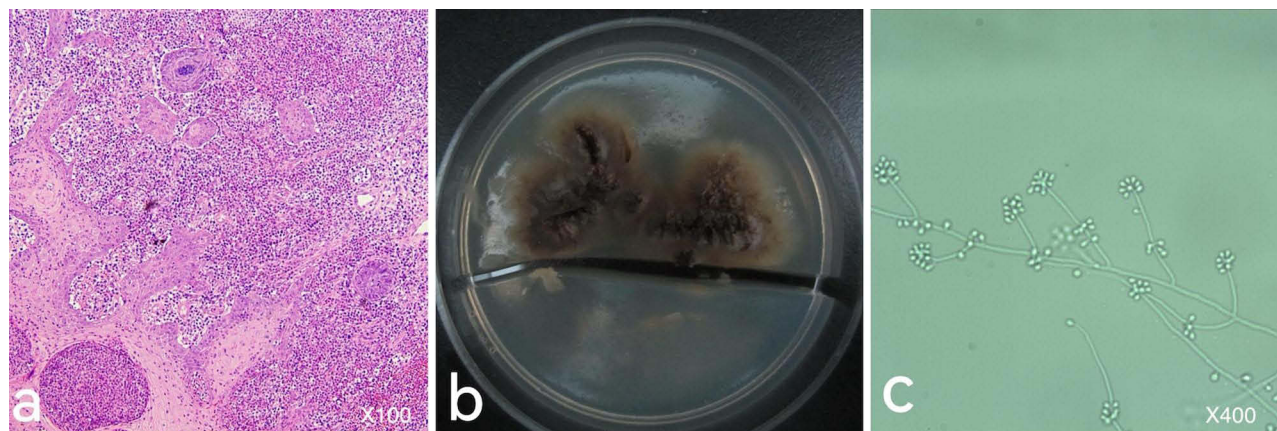


Figure 2 (a) Original magnification $\times 100$. Hematoxylin-eosin–stained sections reveal epidermal pseudoepithelioma-like hyperplasia with diffuse intradermal infiltration of inflammatory cells (neutrophils, histiocytes, and plasma cells). (b) Tissue fungal cultures showed *Sporothrix* growth. (c) Original magnification $\times 400$. Structures typical of *Sporothrix*.

Discussion

Sporotrichosis is a subacute or chronic infectious disease caused by *sporothrix*. It is a global disease prevalent in tropical and subtropical regions. In Latin America, it is considered to be the most common subcutaneous mycosis.¹ In terms of molecular biology, *sporothrix* contains 51 species. Among them, four species were mainly associated with human and animal infections, including *sporothrix brasiliensis*, *sporothrix schenckii*, *sporothrix globosa*, and *sporothrix luriei*.² The main species in China is *sporothrix globosa*.³ In human, *sporothrix* infection is mainly caused by skin inoculation following accidental trauma during gardening work, sports or outdoor activities. The most common infections are lymphocutaneous sporotrichosis (LCS) and fixed cutaneous sporotrichosis (FCS).⁴ Rare systemic sporotrichosis may manifest as arthritis, pneumonia, or meningitis, and it is more common in immunocompromised individuals, such as those with human immunodeficiency virus.⁵ The clinical manifestations of sporotrichosis are variable, ranging from nodules, plaques, ulcers, verrucous lesions, and subcutaneous masses. Some reports indicate that sporotrichosis can mimic psoriasis-like lesions.⁶ For instance a patient with an initial diagnosis of nasal rosacea, who was unsuccessfully treated with tetracycline, was subsequently diagnosed with sporotrichosis through tissue fungal culture.⁷ This

sporotrichosis, which mimics rosacea lesions, is uncommon. In addition, sporotrichosis should to be differentiated from skin tuberculosis, syphilis gumma, pyoderma, skin leishmaniasis, and skin tumors.

Clinically, sporotrichosis mimicking rosacea lesions is uncommon. Biopsy is necessary to determine the pattern of the inflammatory response. Rosacea will show perivascular and perifollicular lymphohistiocytic infiltration, and non-caseating epithelioid granulomas around the hair follicle may occur in cases with severe inflammation. The main feature of skin tuberculosis is the formation of typical tuberculosis nodules by epithelial cells and multinucleated giant cells with caseous necrosis in the center. Histologically, chromoblastosis histologically is characterized by thickened walls and brown crusty cells with dark fungal growth in culture.

Because the causative microbe can be not be easily identified on histological examination, tissue culture or pus culture is the standard diagnostic method for sporotrichosis. When present in tissue culture, *Sporothrix* are stained with periodate-Schiff or Grocott methyamine silver and appear as budding yeast. When etiological cultures or smears are negative, PCR (polymerase chain reaction) may be considered to assist in diagnosis.

Potassium iodide, itraconazole, terbinafine, and amphotericin B can be used to treat sporotrichosis, with varying outcomes. In most studies, oral itraconazole is the preferred treatment, with doses ranging from 100 to 400 mg/day for 3–6 months depending on the severity of the disease.¹ Other treatments include thermotherapy, electrosurgery, and cryotherapy.

Conclusion

Sporotrichosis is a rare skin disease with variable clinical manifestations. We report here a case of sporotrichosis mimicking rosacea lesions. The patient was inoculated with *Sporothrix* after the nasal skin was damaged during labor activities. In the differential diagnosis of skin diseases associated with microbial infection, histopathological examination is often not accurate. Tissue or pus culture is necessary.

Statement of Ethics

According to the current ethical standards in China, the case report in this manuscript require ethical approval. Our study was approved by the ethical committee of the Fourth Affiliated Hospital of Zhejiang University School of Medicine. Approval No.: K2023030.

Written informed consent was obtained from the patient for the photography and publication of his medical case details, including any accompanying images. A copy of the consent form is available upon request.

Disclosure

The authors report no conflicts of interest in this work.

References

1. Orofino-Costa R, Macedo PM, Rodrigues AM, Bernardes-Engemann AR. Sporotrichosis: an update on epidemiology, etiopathogenesis, laboratory and clinical therapeutics. *Anais brasileiros de dermatologia*. 2017;92(5):606–620. doi:10.1590/abd1806-4841.2017279
2. Wilhelm de Beer Z, Duong TA, Wingfield MJ. The divorce of sporothrix and ophiostoma: solution to a problematic relationship. *Stud Mycol*. 2016;83:165–191. doi:10.1016/j.simyco.2016.07.001
3. Zhang Y, Hagen F, Stielow B, et al. Phylogeography and evolutionary patterns in *Sporothrix* spanning more than 14,000 human and animal case reports. *Persoonia*. 2015;35:1–20. doi:10.3767/003158515X687416
4. Estrada-Castañón R, Chávez-López G, Estrada-Chávez G, Bonifaz A. Report of 73 cases of cutaneous sporotrichosis in Mexico. *Anais brasileiros de dermatologia*. 2018;93(6):907–909. doi:10.1590/abd1806-4841.20187726
5. Silva-Vergara ML, Maneira FR, DeOliveira RM, Santos CT, Etchebere RM, Adad SJ. Multifocal sporotrichosis with meningeal involvement in a patient with AIDS. *Med Mycol*. 2005;43(2):187–190. doi:10.1080/13693780500035904
6. Bajoghli A, Fisher C, Cardis MA. A micaceous plaque on the elbow of an older adult. *JAMA dermatol*. 2020;156(8):913–914. doi:10.1001/jamadermatol.2020.1960
7. Martins-Costa GM, Bonamigo RR. Facial verrucous sporotrichosis in an adult during treatment for rosacea. *Int J Dermatol*. 2014;53:e80–e157. doi:10.1111/j.1365-4632.2012.05688.x

Clinical, Cosmetic and Investigational Dermatology

Dovepress

Publish your work in this journal

Clinical, Cosmetic and Investigational Dermatology is an international, peer-reviewed, open access, online journal that focuses on the latest clinical and experimental research in all aspects of skin disease and cosmetic interventions. This journal is indexed on CAS. The manuscript management system is completely online and includes a very quick and fair peer-review system, which is all easy to use. Visit <http://www.dovepress.com/testimonials.php> to read real quotes from published authors.

Submit your manuscript here: <https://www.dovepress.com/clinical-cosmetic-and-investigational-dermatology-journal>