

# Posterior dislocation of hip with ipsilateral intertrochanteric fracture: A report of two cases

Rehan Ul Haq, Jaswant Kumar<sup>1</sup>, IK Dhammi, Anil K Jain

## ABSTRACT

Posterior dislocations of the hip are known to be associated with fractures of the femoral head, neck, shaft, or posterior acetabular wall. However, its association with ipsilateral intertrochanteric fracture has only been anecdotally described in the English literature. We report two such cases managed by open reduction (OR) of the hip and internal fixation (IF) of the intertrochanteric fracture. The first case was a 26-year-old male who was managed by OR of the hip with IF of the intertrochanteric fracture with a dynamic hip screw and had a good functional result at 1-year followup. The second case was a 36-year-old female who was also managed by OR of the hip with IF of the head fragments with Herbert screw and IF of the intertrochanteric fracture with a dynamic condylar screw. The patient had a fair, functional result at 1-year followup. With the increase in high energy trauma, these fracture patterns have become more common, and there is an urgent need to review the existing classifications so that these fractures are better categorized, and treatment guidelines defined.

**Key words:** Classification, intertrochanteric fracture, open reduction internal fixation, posterior dislocation hip

**MeSH terms:** Hip dislocation, intertrochanteric fractures, orthopaedic equipment, classification

## INTRODUCTION

Posterior dislocation of the hip is a common injury, and its incidence is increasing due to high energy trauma especially road traffic accidents. Fractures that are commonly associated with posterior dislocation of hip are the fractures of femoral head, neck, shaft, or posterior acetabular wall.<sup>1-4</sup> The most commonly used classification of this injury is the Thompson and Epstein and its subset the Pipkin classification.<sup>2,5</sup> However, these classifications do not include posterior dislocation of the hip associated with ipsilateral intertrochanteric fracture or other complex fracture patterns. We report two cases of irreducible posterior dislocation of the hip with ipsilateral intertrochanteric fracture managed by open reduction and

internal fixation (ORIF). The cases are being reported not only because of their rarity but also to emphasize that with increase in high energy trauma these fracture patterns would be more common and there is a need to review the existing classifications so that these fractures are better categorized and treatment guidelines defined. The possible mechanism of injury is discussed. Both the patients consented to their data being used for publication.

## CASE REPORTS

### Case 1

A 26-year-old male patient was referred to the Orthopaedics emergency of our hospital after 5 days following a road traffic accident. The patient was traveling in a sport utility vehicle moving at a high speed when it hit another vehicle coming from opposite side. The vehicle first decelerated and then suddenly turned. The patient was initially treated at a hospital where primary management and stabilization was done. However, because the treating surgeons were

Department of Orthopaedics, University College of Medical Sciences and Guru Teg Bahadur Hospital, <sup>1</sup>Department of Orthopedic, Maulana Azad Medical College and LN Hospital, New Delhi, India

**Address for correspondence:** Dr. Rehan Ul Haq,  
Department of Orthopaedics, University College of Medical Sciences and  
Guru Teg Bahadur Hospital, Dilshad Garden, New Delhi - 110 095, India.  
E-mail: docrehan@rediffmail.com

Access this article online	
Quick Response Code:	Website: www.ijoonline.com
	DOI: 10.4103/0019-5413.189614

This is an open access article distributed under the terms of the Creative Commons Attribution-NonCommercial-ShareAlike 3.0 License, which allows others to remix, tweak, and build upon the work non-commercially, as long as the author is credited and the new creations are licensed under the identical terms.

**For reprints contact:** reprints@medknow.com

**How to cite this article:** Ul Haq R, Kumar J, Dhammi IK, Jain AK. Posterior dislocation of hip with ipsilateral intertrochanteric fracture: A report of two cases. Indian J Orthop 2016;50:571-6.

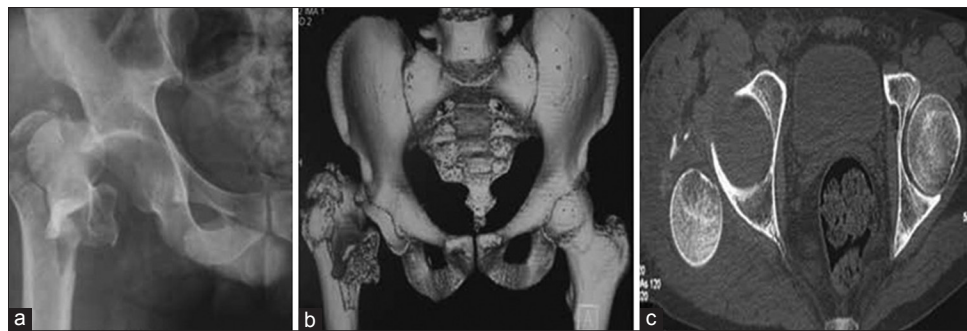
not able to formulate a treatment plan for the hip injury, they referred the patient to our hospital.

On clinical examination, the patient was unable to bear weight on his right lower limb. The limb was short externally rotated and the hip region was swollen and painful. There was a shortening of 3 cm. Active straight leg raising was not possible. There was no sciatic nerve injury or vascular deficit.

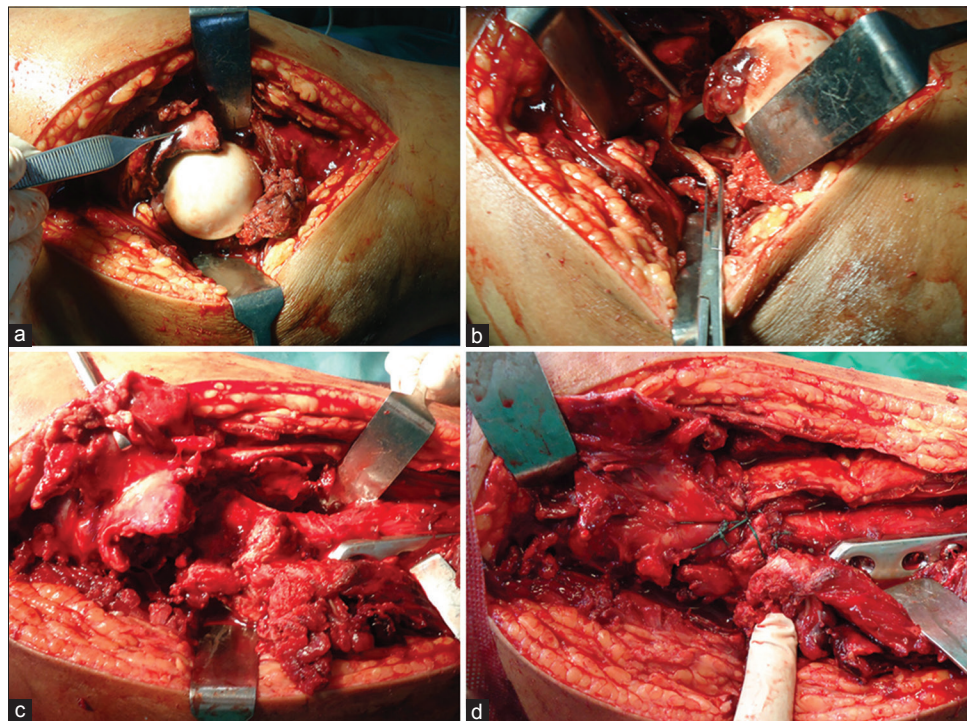
Plain radiographs were inadequate to define the exact pattern of the fracture [Figure 1a]. Computed tomography (CT) scan of the involved hip with three-dimensional (3D) reconstruction demonstrated that the patient had a posterior dislocation of the hip with an intertrochanteric fracture of the proximal femur [Figure 1b and c]. The posterior

acetabular wall, the femoral head, neck and shaft were surprisingly intact.

As 5 days had elapsed since the injury, prognosis was discussed with the patient and relatives, and an informed written consent was taken from the patient. It was planned to proceed with ORIF. However, a backup plan of uncemented bipolar hemiarthroplasty was also kept. The hip was exposed through Gibson's approach in lateral position. The femoral head was found to be lying under the gluteus maximus [Figure 2a]. It had buttonholed through a small rent in the posterior capsule and the short external rotators [Figure 2b]. The greater trochanter had avulsed with the abductors attached to it [Figure 2c]. The rent in the posterior capsule was enlarged, and the femoral head



**Figure 1:** (a) Plain radiograph anteroposterior view of the hip joint showing posterior dislocation of the right hip with a proximal femoral fracture. However, it is inadequate to define the exact pattern of the fracture (b-c) Computed tomography scan of the involved hip with three-dimensional reconstruction and axial image showing posterior dislocation of the hip with an intertrochanteric fracture of the proximal femur



**Figure 2:** Intraoperative photographs showing – (a) The femoral head lying under the gluteus maximus; (b) After buttonholing through a small rent in the posterior capsule and the short external rotators (c) The greater trochanter is seen avulsed with the abductors attached to it (d) Intertrochanteric fracture was reduced and fixed with a dynamic hip screw and greater trochanter with the abductors anchored to it using number 5 ethibond suture

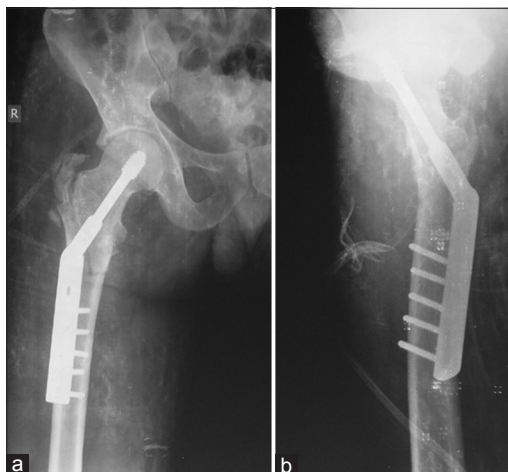reduced in the acetabulum using a Schanz pin as a joy stick. The intertrochanteric fracture was then reduced and fixed with a dynamic hip screw and plate. The greater trochanter with the abductors was anchored using number 5 ethibond suture [Figure 2d]. The rent in the posterior capsule and short external rotators was repaired with absorbable sutures. Following this, the muscles, subcutaneous tissue, and skin were closed in layers.

The postoperative period was uneventful. The patient was allowed mobilization with axillary crutches after 2 days. Sutures were removed at 2 weeks. Crutches were gradually discarded between 6 and 12 weeks once patient could bear weight on the extremity. Postoperative anteroposterior and lateral radiographs showed good reduction and fixation [Figure 3a and b]. An abduction brace was maintained for 6 weeks to allow the abductors to heal. At 6 and 12 months followup, the radiographs showed sound union with no

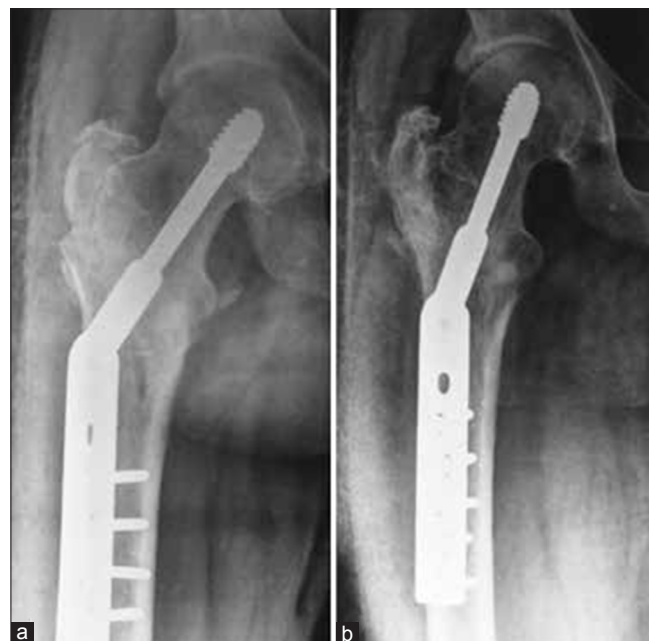evidence of avascular necrosis of the head of the femur [Figure 4a and b]. The patient had a painless hip with a Harris hip score of 86, which is considered as a good hip function.

## Case 2

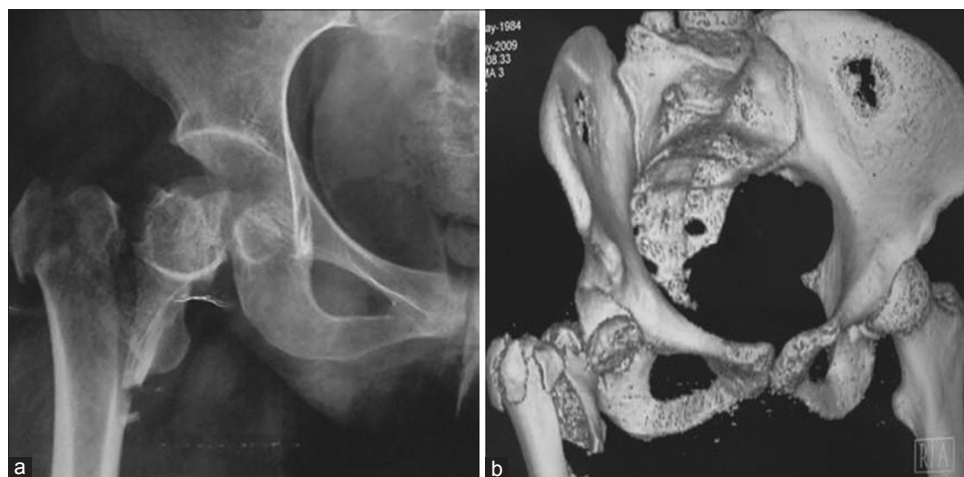A 36-year-old female reported to us 1-day after a road traffic accident, with complaints of pain and swelling over the right hip and left upper limb. The patient was unable to move her right lower limb. There was a shortening of 4 cm. There was no pelvis or spine injury. There was no neurovascular deficit in both upper and lower limbs. The exact mechanism of injury could not be elicited as all persons in the vehicle were sleeping when the accident took place.



**Figure 3:** (a and b) Postoperative anteroposterior and lateral radiographs showing good reduction and fixation



**Figure 4:** (a and b) Radiographs at 6 and 12 months followup, showing sound union with no evidence of avascular necrosis of femoral head



**Figure 5:** (a) Plain radiograph of hemipelvis with right hip joint showing posterior dislocation with fracture of femoral head and intertrochanteric region; however the exact pattern is not clear (b) Computed tomography scan of the involved hip with three-dimensional reconstruction, showing posterior dislocation of the hip with fracture of the femoral head and unstable intertrochanteric fracture



Again like the first case plain radiograph of the pelvis with both hip joints was inadequate to define the exact pattern of the fracture [Figure 5a]. CT scan with 3D reconstruction showed posterior dislocation of the hip with a fracture of the femoral head and unstable intertrochanteric fracture [Figure 5b]. Radiographs of shoulder and elbow region revealed fracture of surgical neck of the humerus and open grade II undisplaced fracture olecranon.

After informed consent, the patient was operated in a lateral position using Gibson's approach with the plan of ORIF. There was rent in a posterior capsule through which part of the head fragment (about two-third) had displaced posteriorly and was lying under gluteus maximus. Another large fragment (about one-third) with minimal soft tissue attachment was lying within the acetabular cavity. One long K-wire was put in each fragment and used as a joy stick to reduce the fragments. They were fixed with a Herbert screw, and then the hip joint was reduced. The intertrochanteric fracture was fixed with a 95° dynamic condylar screw. Wound was closed in layers [Figure 6].

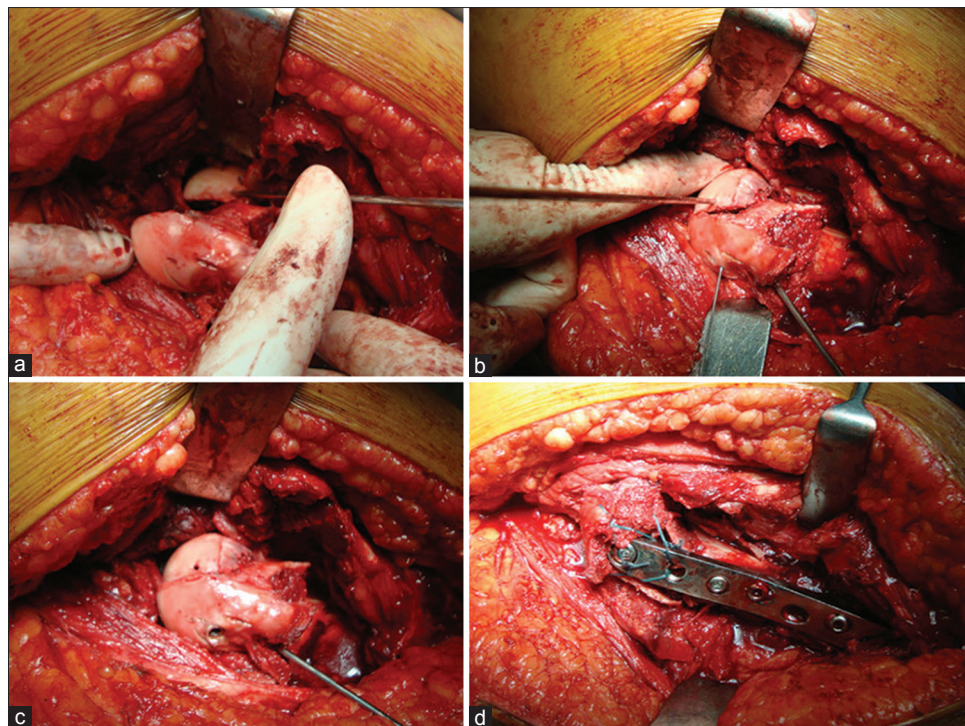
The patient was allowed in bed exercises; however, weight bearing was delayed as the patient could not be mobilized with a walker due to upper extremity injuries. At 12 months,

followup radiograph showed fracture union with a Harris hip score of 72 which denotes fair functional outcome.

## DISCUSSION

Posterior dislocations of hip are often associated with fractures of the femoral head, neck, shaft, or posterior acetabular wall.<sup>1-4</sup> Posterior dislocation of the hip with associated ipsilateral intertrochanteric fracture has been very infrequently described [Table 1].<sup>6-9</sup> Rarely, it has also been described with anterior or inferior hip dislocation [Table 1].<sup>10,11</sup>

Pure posterior dislocation of the hip without fractures of head, neck or acetabulum occurs when longitudinal compression forces occur along the shaft of the femur while the hip is in adducted position. According to Fernandes<sup>12</sup> in combination injuries, this is the first event which occurs. Once the head has dislocated, it gets fixed with the tight periosteum of the ilium, and further adduction causes fracture of neck femur. In our patients, the above-mentioned mechanism does not provide the answer because the neck of the femur was intact. We believed that in our patients, first longitudinal compression force, while the hip must have been flexed and adducted, would have produced posterior dislocation of the hip. Following this a rotational force, which



**Figure 6:** Intraoperative photographs showing – (a) Part of the head fragment (about two-third) displaced posteriorly, lying under gluteus maximus and another large fragment (about one-third) lying within the acetabular cavity; (b) One long K-wire in each fragments is used as joy stick to reduce the fragments; (c) Fragments are fixed with a Herbert screw and hip joint reduced; (d) The intertrochanteric fracture was fixed with a 95° dynamic condylar screw

**Table 1: Literature of case reports of dislocation of hip with ipsilateral intertrochanteric fracture**

Author	Pattern of injury	Intervention	Outcome
Barquet and Mussio (1983) <sup>6</sup>	Fracture dislocation of the femoral head with associated trochanteric and shaft fracture	OR of the hip dislocation and IF of the trochanteric and shaft fracture	Good fracture healing at 27 weeks with no evidence of AVN
Singh <i>et al.</i> (2006) <sup>10</sup>	Inferior dislocation of hip with ipsilateral intertrochanteric fracture	Closed reduction of the hip dislocation followed by IF of intertrochanteric fracture with DHS	No AVN at 2.5 years followup
Agarwal <i>et al.</i> (2008) <sup>7</sup>	Posterior dislocation hip with ipsilateral comminuted intertrochanteric fracture	OR of the hip dislocation followed by IF of intertrochanteric fracture with DCS	Painless hip at 1-year with no signs of AVN
Alexa <i>et al.</i> (2009) <sup>8</sup>	Posterior dislocation hip with ipsilateral intertrochanteric fracture	OR of the hip dislocation followed by IF of intertrochanteric fracture with DHS	
Radulescu <i>et al.</i> (2013) <sup>11</sup>	Anterior dislocation hip with ipsilateral intertrochanteric fracture	OR of the hip dislocation followed by IF of intertrochanteric fracture with DHS	Good functional outcome at 6 months
Yousefi <i>et al.</i> (2013) <sup>9</sup>	Posterior dislocation hip with posterior acetabular wall fracture and ipsilateral intertrochanteric fracture	ORIF with reconstruction plate of the posterior acetabular wall fracture and DHS for intertrochanteric fracture	No AVN at 8 months followup

DHS=Dynamic hip screw, DCS=Dynamic condylar screw, AVN=Avascular necrosis, OR=Open reduction, IF= internal fixation

would have come into force once the vehicle started turning would have resulted in an intertrochanteric fracture. Other possible mechanism could be a direct lateral force over the trochanter region once the hip had dislocated. Similar mechanism of injury has been proposed by Yousefi *et al.*<sup>9</sup>

The Thompson and Epstein classification is the most common classification used for posterior fracture dislocation of the hip.<sup>5</sup> However, this classification and its subgroups the Pipkin classification only include fractures of the posterior acetabular walls, femoral head, or neck.<sup>2</sup> They do not include other proximal fractures patterns such as intertrochanteric fractures, greater trochanter/lesser trochanter fracture, etc., which have a bearing on the diagnosis and management. With the increase in high energy trauma accident, there would be an increase in the incidence of these unclassified fractures. Therefore, we believe that the Thompson and Epstein/Pipkin classification must be modified so that these injuries can be better categories and the treatment guidelines better defined.

Management of such injury is always a difficult decision especially when the patients reports late. The first challenge is to understand the exact pattern of injury to formulate a surgical plan. High quality CT scan with 3D reconstruction is an invaluable tool in such cases. The next challenge is to achieve adequate reduction and stable fixation. As the dislocation is posterior, the major fracture fragments can be found posteriorly. Hence, the posterior approach with the patient in lateral position is helpful. In our cases, once the head was reduced the intertrochanteric fracture was fixed without changing patient position. Because of the complexity of the fracture pattern all possible IF tools must be available that may be required depending upon the fracture pattern. If adequate reduction or stabilization is not possible, the possibility of primary prosthetic replacement

must always be explained to the patient. Long term followup is essential for the diagnosis of avascular necrosis which is always a possibility especially during first 2 years.

## CONCLUSION

We describe two rare cases of posterior dislocation of the hip with associated intertrochanteric fractures managed by ORIF. We believe that with the increase in the incidence of fractures due to high energy trauma, the pattern of fractures associated with posterior dislocation of the hip is becoming more diverse. Thompson and Epstein/Pipkin classification needs to be modified to include these fracture patterns to allow better categorization of such fractures so that standardized treatment guidelines can be formulated.

## Financial support and sponsorship

Nil.

## Conflicts of interest

There are no conflicts of interest.

## REFERENCES

1. Dehne E, Immermann EW. Dislocation of the hip combined with fracture of the shaft of the femur on the same side. *J Bone Joint Surg Am* 1951;33-A: 731-45.
2. Pipkin G. Treatment of grade IV fracture-dislocation of the hip. *J Bone Joint Surg Am* 1957;39-A: 1027-42.
3. Klasen HJ, Binnendijk B. Fracture of the neck of the femur associated with posterior dislocation of the hip. *J Bone Joint Surg Br* 1984;66:45-8.
4. Hougaard K, Thomsen PB. Traumatic posterior fracture-dislocation of the hip with fracture of the femoral head or neck, or both. *J Bone Joint Surg Am* 1988;70:233-9.
5. Thompson VP, Epstein HC. Traumatic dislocation of the hip;

- a survey of two hundred and four cases covering a period of twenty-one years. *J Bone Joint Surg Am* 1951;33-A:746-78.
6. Barquet A, Mussio A. Fracture-dislocation of the femoral head with associated ipsilateral trochanteric and shaft fracture of the femur. *Arch Orthop Trauma Surg* 1983;102:61-3.
  7. Agarwal R, Rai A, Saraf S, Singh S, Singh A. An unusual pattern of posterior dislocation of hip associated with comminuted trochanteric fracture. *Internet J Orthop Surg* 2008;9.
  8. Alexa O, Puha B, Veliceasa B, Paduraru D. Posterior dislocation of the hip associated with ipsilateral trochanteric fracture – A very rare case. *Chirurgia (Bucur)* 2009;104:761-4.
  9. Yousefi A, Ashraf H, Mashhadinezhad A, Birjandinejad A. Posterior hip dislocation associated with posterior wall acetabular fracture and ipsilateral intertrochanteric fracture: A very rare case report. *Trauma Mon* 2013;17:409-11.
  10. Singh R, Sharma SC, Goel T. Traumatic inferior hip dislocation in an adult with ipsilateral trochanteric fracture. *J Orthop Trauma* 2006;20:220-2.
  11. Radulescu R, Badila A, Japie I, Papuc A, Manolescu R. Anterior dislocation of the hip associated with intertrochanteric fracture of the femur – Case presentation. *J Med Life* 2013;6:336-9.
  12. Fernandes A. Traumatic posterior dislocation of hip joint with a fracture of the head and neck of the femur on the same side: A case report. *Injury* 1981;12:487-90.