

# Ecthyma gangrenosum and severe neutropenic sepsis caused by *Staphylococcus aureus* infection in a previously healthy child: a case report

Journal of International Medical Research

2022, Vol. 50(9) 1–8

© The Author(s) 2022

Article reuse guidelines:

[sagepub.com/journals-permissions](https://sagepub.com/journals-permissions)

DOI: 10.1177/03000605221126882

[journals.sagepub.com/home/imr](https://journals.sagepub.com/home/imr)Xinjuan Zhang and Yanping Yu 

## Abstract

Ecthyma gangrenosum (EG) is a potentially lethal skin infection mainly caused by *Pseudomonas aeruginosa*, but other causative pathogens have also been reported. EG usually occurs locally and often arises in immunocompromised patients. The fatality rate can be extremely high if a systemic infection leading to sepsis occurs. EG and severe sepsis caused by *Staphylococcus aureus* infection are extremely rare in healthy children. However, upon occurrence, disease progression can be rapid, and the mortality rate is high. This current case report describes a previously healthy child with no underlying diseases who developed EG in the facial and perianal regions following *S. aureus* infection. The infection rapidly progressed to sepsis, septic shock, and persistent severe neutropenia. The patient also developed drug-resistant bacterial infections that spread rapidly and resulted in multiorgan failure. The patient was treated with antibiotics, but she died of organ failure despite extracorporeal membrane oxygenation support. EG caused by *S. aureus* has the potential to progress rapidly, leading to septic shock and severe neutropenia. Patients should be identified at an early stage and promptly treated with antibiotics. However, the improvement of neutropenia and prevention of secondary infections remain the focus of our research.

## Keywords

Ecthyma gangrenosum, *Staphylococcus aureus*, sepsis, septic shock, severe neutropenia, case report

Date received: 14 June 2022; accepted: 30 August 2022

Department of Pediatric Intensive Care Unit, Affiliated to Hangzhou First People's Hospital, Zhejiang University School of Medicine, Hangzhou, China

## Corresponding author:

Yanping Yu, Department of Pediatric Intensive Care Unit, Affiliated to Hangzhou First People's Hospital, Zhejiang University School of Medicine, 261 Huansha Road, Shangcheng District, Hangzhou, Zhejiang Province 310006, China.

Email: [yyp757605@163.com](mailto:yyp757605@163.com)



Creative Commons Non Commercial CC BY-NC: This article is distributed under the terms of the Creative Commons Attribution-NonCommercial 4.0 License (<https://creativecommons.org/licenses/by-nc/4.0/>) which permits non-commercial use, reproduction and distribution of the work without further permission provided the original work is attributed as specified on the SAGE and Open Access pages (<https://us.sagepub.com/en-us/nam/open-access-at-sage>).

## Introduction

Ecthyma gangrenosum (EG) is a serious and potentially lethal skin infection caused predominantly by *Pseudomonas aeruginosa* and less commonly by other opportunistic pathogens. EG often occurs in immunocompromised patients for several reasons, such as chemotherapy, human immunodeficiency virus infections, and neutropenia, but it rarely affects healthy people. However, extremely high fatality rates can occur following progression to systemic infection and sepsis.<sup>1-3</sup> Currently, to the best of our knowledge, no reports of severe sepsis with persistent neutropenia attributable to EG caused by *Staphylococcus aureus* infection have been described in healthy children.

In this study, we report the case of *S. aureus* infection in a previously healthy child that led to EG and subsequent systemic infection, causing sepsis and severe persistent neutropenia. The condition developed rapidly, and a drug-resistant opportunistic bacterial infection occurred, leading to death despite treatment. We hope that the findings of this case report enhance the clinical treatment of similar cases in the future. The reporting of this study conforms to CARE guidelines.<sup>4</sup>

## Case report

A 16-month-old girl was admitted to the general pediatric ward of our hospital (Hangzhou First People's Hospital, Hangzhou, China), as she presented with a fever and a 9-day-long rash. The child had reportedly developed a fever after eating shrimp 9 days before presentation, with the highest body temperature measuring 40.1°C. The fever was irregular, and during periods of high body temperature, the patient developed chills with a red rash all over her body, itching, swelling of the face and lower extremities, and swollen and chapped lips. The patient had no additional symptoms

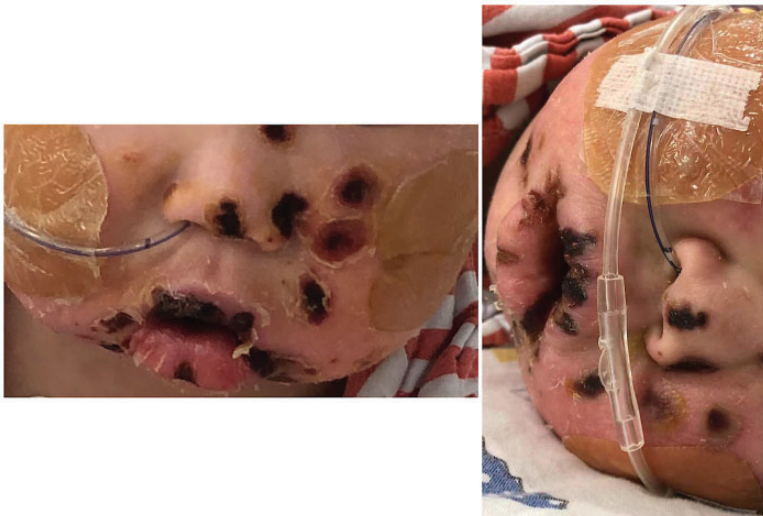
such as coughing, shortness of breath, wheezing, joint swelling or pain, or frequent or urgent urination. Routine blood test results and inflammatory markers levels, including C-reactive protein (CRP) and procalcitonin (PCT) levels, were normal as determined in the outpatient clinic of The First People's Hospital of Lin'an District (Hangzhou, China). The initial diagnosis was an acute upper respiratory tract infection and food allergy, and the patient was administered Chinese herbal medicine and the anti-allergy drug 5 mg/day loratadine for 3 days. When her condition did not improve, she was admitted to the pediatric ward of The First People's Hospital of Lin'an District (Hangzhou, China) under the suspicion of Kawasaki disease.

The patient had been immunocompetent in the past, and she underwent fiberoptic bronchoscopy because of peanut aspiration half a month prior to presentation. After admission to the local hospital, her routine blood test results were normal, and the blood culture test revealed negative results. However, chest radiography indicated bronchitis, and the patient was administered azithromycin combined with 1 to 2 mg/kg/day methylprednisolone intravenously for 3 days and then shifted to oral prednisone tablets. During treatment, the patient's body temperature was normal for 4 days, and the rash and swelling on her face and calves subsided. The fever returned on day 8 after the patient caught a cold, and it was accompanied by nasal congestion with no obvious cough. On the ninth day, an increase in the severity of rashes was observed, and the swelling on her face, feet, and calves worsened. Chapped swollen lips with hemorrhagic exudate were also observed. The patient was subsequently transferred to the general pediatric ward of our hospital for further diagnosis and treatment. The results of physical examination on admission were as follows: body temperature, 38.9°C; pulse rate, 140 beats/

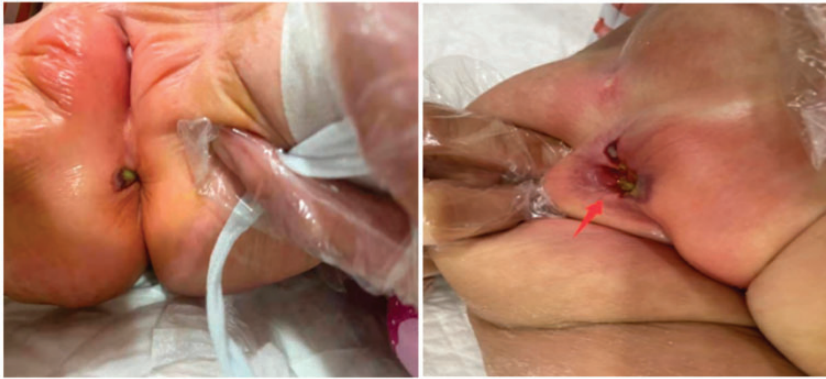min; respiration rate, 36 breaths/min; blood pressure, 88/50 mmHg; itchy, scattered red maculopapular rashes mainly on the face; hyperpigmentation on the trunk and extremities; scaling, swollen and chapped lips; absence of strawberry tongue; normal cardiac and lung auscultation; soft abdomen; liver at 3 cm below the ribs with normal hardness and no pain upon touch; and swollen limbs without peeling of the skin. The supplementary blood examination results were as follows: white blood cell count,  $5.3 \times 10^9/L$ ; neutrophil percentage, 28%; neutrophil count,  $1.8 \times 10^9/L$ ; and CRP level, 7.26 mg/L. Our initial diagnosis was erythema multiforme and incomplete Kawasaki disease; therefore, low-dose glucocorticoid treatment was continued.

On the second day following admission, she developed eschars on her face (Figure 1), and the routine blood test results were as follows: white blood cell count,  $0.7 \times 10^9/L$ ; neutrophil%, 11.9%; neutrophil count,  $0.1 \times 10^9/L$ ; CRP level, 323.2 mg/L; PCT level, 89.6 ng/dL; interleukin-6 level, 24,443.03 pg/dL; and interleukin-10 level, 11,188.10 pg/dL. These results suggested

that the patient had developed a severe infection. After being diagnosed with sepsis and severe neutropenia with EG, the patient was transferred to the pediatric intensive care unit. The girl was further treated with meropenem and vancomycin after collecting blood cultures. She subsequently developed septic shock along with hypotension, a prolonged capillary refill time, hyperlactatemia, metabolic acidosis, and electrolyte imbalance. The symptoms of septic shock improved after fluid resuscitation, treatment with anti-infective and vasoactive agents, and intravenous administration of human immunoglobulin. During this treatment, ecthyma was found on the perianal skin of the patient (Figure 2). Blood, sputum, and skin pustule were sent for bacterial culture tests. Considering the long turnaround time of the bacterial culture tests, we also submitted the samples for metagenomic next-generation sequencing (mNGS), the results of which suggested *S. aureus* infection (Table 1). We later received negative test results for sputum and blood cultures. *S. aureus* infection was confirmed after



**Figure 1.** Ecthyma gangrenosum in the facial area of the patient.



**Figure 2.** Ecthyma gangrenosum in the perianal area of the patient.

**Table 1.** Metagenomic next-generation sequencing results and list of detected bacteria.

Type <sup>a</sup>	Genus			Species		
	Chinese name	Latin name	Mapped reads <sup>b</sup>	Chinese name	Latin name	Mapped reads
G+	葡萄球菌属	<i>Staphylococcus</i>	849	金黄色葡萄球菌	<i>Staphylococcus aureus</i>	466
				松鼠葡萄球菌	<i>Staphylococcus sciuri</i>	17

Sample collection date: 02/26/2021 Sample ID: 20B6391406.

<sup>a</sup>G+, gram-positive.

<sup>b</sup>The number of well-aligned sequences of this microorganism detected at the genus and species levels.

receiving positive results for pustule culture (Table 2).

Because the patient had severe neutropenia and she was prone to secondary opportunistic infections, we did not change the antibiotics and continued antimicrobial treatment with meropenem combined with vancomycin. Additionally, the patient received a subcutaneous injection of recombinant human granulocyte colony-stimulating factor (G-CSF) to stimulate granulocyte growth. Experienced dermatologists and anorectal surgeons assisted with skin and perianal care. Because of the immaturity of the perianal abscess, it was not excised or drained. Over the course of the patient's treatment, we continuously monitored changes in her routine blood

tests and the levels of CRP, PCT, cytokines, and other inflammatory markers. Her blood test results revealed severe neutropenia, in which the neutrophil level ranged from 0 to  $0.2 \times 10^9/L$ . After 4 days of treatment, we noted decreases in her peak body temperature, facial swelling, and inflammatory indicators and an extension of the fever intervals (Table 2). Because of the possibility of severe neutropenia, protective isolation was taken, and the child was placed in a single ward with regular air disinfection, enhanced oral and skin care, and enhanced hand hygiene for medical staff. However, on the fifth day after admission, the patient's temperature and inflammatory markers increased again. Urine, sputum, and pus culture results revealed a

**Table 2.** Laboratory data during the acute phase.

Parameters	Day 1	Day 2	Day 3	Day 4	Day 5	Day 6	Day 7	Day 8	Day 9	Day 10
Leukocytes ( $\times 10^9/L$ )	5.3	0.7	1.4	6.3	7.5	6.4	2.2	0.8	1.7	0.6
Neutrophil (%)	28	11.9	5.8	0.5	2.0	0	0	1.7	0.5	2.3
Neutrophil count ( $\times 10^9/L$ )	1.5	0.1	0.1	0	0.2	0	0	0	0	0
Hemoglobin (g/L)	100	91	81	101	112	105	96	104	100	85
Platelet ( $\times 10^9/L$ )	336	346	152	48	21	11	24	51	73	9
C-reactive protein (mg/L)	7.26	323.2	241.9	208.5	68.6	80	93.8	186.8	251.1	222.2
Procalcitonin (ng/mL)	0.34	89.6	100	79.27	39.45	80	6.91	5.32	3.67	7.07
Interleukin-6 (pg/mL)		24443.03					156.89	3177		3177
Interleukin-10 (pg/mL)		11188.10					19.62	360.49		
Plasma lactic acid (mmol/L)		4.87	0.99					1.48		
Sputum culture								CRAB		
Pustule culture					MSSA				CRAB	
mNGS			MSSA							CRAB
Blood culture									CRAB	
Urine culture							CRAB			

mNGS, metagenomic next-generation sequencing; MSSA, methicillin-susceptible *Staphylococcus aureus*; CRAB, carbapenem-resistant *Acinetobacter baumannii*.

carbapenem-resistant *Acinetobacter baumannii* infection. On the eighth day, following the results of a drug susceptibility test and multi-disciplinary team discussion, the antibiotics were changed to tigecycline combined with daptomycin and voriconazole for antimicrobial and antifungal treatment, respectively. However, septic shock recurred, and the patient was treated with fluid resuscitation and vasoactive drugs. Because of the limited treatment options in general hospitals and the worsening of her condition, the patient was transferred to the pediatric intensive care unit of Provincial Children's Hospital. The patient experienced multiorgan failure and underwent tracheal intubation, ventilator auxiliary support, and extracorporeal membrane oxygenation circulatory support. However, her blood pressure remained low, and she died 1 day after hospital transfer.

Ethical approval was not required for this case report because no intervention or changes were made to the clinical course of events. Written informed consent was obtained from the patient's parents for publication of this case report and any accompanying images. All treatments are

performed with the informed consent of the patient's parents.

## Discussion

EG is a rare and potentially deadly disease, and its manifestations are typical of most skin conditions. The pathogens enter the body through abrasions or breaks in the skin or *via* hematogenous transmission, after which they colonize the middle and outer layers of the vascular walls, leading to vasculitis. The clinical presentation of EG includes painless red circular macular lesions that can quickly develop into pustules or hematomas accompanied by visible necrotic ulcerations, central eschars, and a red halo surrounding the ulcers. The lesions can appear anywhere on the body, and they mostly arise in the anogenital and axillary regions, with the buttocks and perineal regions being the most common sites (57%), followed by the extremities (30%), trunk (6%), and face (6%).<sup>1,2,5</sup>

EG usually occurs in immunocompromised patients. It is typically caused by chemotherapy, human immunodeficiency virus infection, neutropenia, defective neutrophil

function, agammaglobulinemia, or other factors, but it has also been occasionally reported in healthy individuals.<sup>6</sup> In the case of systemic infections, the associated mortality rate can be extremely high.<sup>1,2</sup> EG is clinically important because it has potentially lethal consequences and it is an indicator for underlying diseases requiring prompt clinical diagnosis and treatment.<sup>7</sup> EG is commonly caused by *Pseudomonas aeruginosa*; however, other pathogens have also been reported, including methicillin-resistant *S. aureus*, *Streptococcus pyogenes*, and fungi.<sup>8,9</sup> To the best of our knowledge, there have been no reports of *S. aureus* infection leading to EG and sepsis with persistent severe neutropenia in healthy children.

In this case, the route of *S. aureus* infection is unknown, and infection may have occurred through damaged skin or mucous membranes. The principal manifestation of the patient was EG caused by *S. aureus*. This led to a systemic infection with sepsis, septic shock, and persistent severe neutropenia. Despite initial improvement in her condition after treatment initiation, her condition worsened after 5 days because of carbapenem-resistant *A. baumannii* infection, which was detected in blood, pus, and sputum cultures. Although we changed the course of antibiotics, she experienced septic shock and multiorgan failure, and extracorporeal membrane oxygenation support failed to resuscitate her.

In our patient, EG was considered only when the patient went into septic shock. Therefore, because of the failure to promptly diagnose EG, the appropriate course of antibiotics could not be determined in time. Additionally, given that *S. aureus* is not a common pathogenic cause of EG, we should have promptly performed a pathogenic examination to guide antibiotic treatment. Because the positivity rate of blood cultures for the etiological detection of EG is low, partial pus cultures of skin lesions

could be used to improve the overall detection rate. The time required for culture results was not conducive to a rapid diagnosis and treatment of the disease. Therefore, blood samples were sent for mNGS, and *S. aureus* infection was detected within 12 to 48 hours. Because of its speed and accuracy, related studies found that mNGS can identify pathogens in patients with severe infections at an early stage and guide the use of antimicrobials.<sup>10</sup> However, a limitation of mNGS is that there is currently no international unified standard that can be used as a reference to detect an etiology.

Our patient presented with persistent severe neutropenia throughout the course of the disease. Although we administered potent antibiotics and used G-CSF to stimulate the growth of granulocytes, the patient remained severely neutrophil-deficient and displayed no improvement, and bone biopsy revealed bone marrow suppression. Song *et al.* suggested that neutropenia is caused by toxins released by *S. aureus* that affect neutrophil function.<sup>11</sup> In cases of persistent severe neutropenia, the infection is more likely to spread and cause fatality. Studies revealed that neutropenia at the time of EG diagnosis is the most important prognostic factor for death.<sup>12</sup> We initially considered the possibility of a congenital immunodeficiency and evaluated the patient to eliminate other severe neutropenia-causing disorders. Laboratory tests for immune, blood, and genetic disorders were negative, and the results of genetic sequencing did not suggest congenital immunodeficiency. Several reports indicated that many patients who die from sepsis have unresolved opportunistic infections.<sup>13,14</sup> Pediatric patients who die from sepsis display immunosuppressive features similar to those observed in adults with sepsis.<sup>15,16</sup> Therefore, immunosuppression might be a major driver of sepsis-related morbidity and mortality.

The child was previously healthy, and she had no evidence of immunodeficiency. It may be possible that the overproduction of toxins (toxic shock syndrome toxin 1 and/or staphylococcal enterotoxin B) resulting from *S. aureus* infection led to neutrophil dysfunction, a cytokine storm, immune system dysfunction, and immunosuppression. This in turn may have caused the patient's susceptibility to opportunistic bacterial infections and promoted the development of multiorgan failure.<sup>11</sup>

There are no specific treatment guidelines for severe neutropenia-induced sepsis. To date, no studies have demonstrated differences in sepsis and septic shock treatment between neutropenic and non-neutropenic patients despite the higher mortality rate observed in neutropenic children. There is also controversy regarding the use of G-CSF in children with neutropenia. A study reported that G-CSF can stimulate granulocyte growth in EG caused by neutropenia.<sup>17</sup> However, Lee *et al.* found that although G-CSF treatment shortened the recovery time in children, it was associated with higher mortality and secondary sepsis rates; therefore, it is not recommended for routine use in children with neutropenia.<sup>18</sup> In terms of antimicrobial therapy in high-risk patients with neutropenia and septic shock, studies recommended the use of combination antibiotic therapy.<sup>19</sup> Other meta-analyses illustrated that outside neutropenic populations, the use of antibiotic de-escalation and specific targeted therapy has been successful in patients with sepsis with no adverse effect on mortality.<sup>20</sup> However, data on the applicability and safety of this approach in patients with neutropenia are limited. Future studies should focus on investigating whether antibiotic de-escalation and targeted therapy in neutropenic patients can improve outcomes or slow the emergence of antimicrobial resistance.<sup>16</sup>

In conclusion, EG caused by *S. aureus* can progress rapidly, causing septic shock and severe neutropenia. Early culture testing of lesions, blood, and other specimens should be performed to identify both the causative agents and antibiotic treatment options. The specimens can also be sent for mNGS to identify potential pathogens as early as possible. Determination of treatment modules for sepsis and severe neutropenia, prevention of secondary infections, and improvement of survival rates remain as key challenges of our current research.

### Acknowledgements

We would like to thank Editage (www.editage.cn) for the English language editing.

### Author contributions

YPY designed the work and drafted the manuscript. XJZ collected studies and made a major contribution to manuscript writing. Both authors read and approved the final manuscript.

### Availability of data and materials

The datasets used and/or analyzed during the current study are available from the corresponding author on reasonable request.

### Declaration of conflicting interests

The authors declare that there is no conflict of interest.

### Funding

This research received no specific grant from any funding agency in the public, commercial, or not-for-profit sectors.

### ORCID iD

Yanping Yu  <https://orcid.org/0000-0001-9006-8479>

### References

1. Zomorodi A and Wald ER. Ecthyma gangrenosum: Considerations in a previously

- healthy child. *Pediatr Infect Dis J* 2002; 21: 1161–1164.
2. Goolamali SI, Fogo A, Killian L, et al. Ecthyma gangrenosum: An important feature of pseudomonal sepsis in a previously well child. *Clin Exp Dermatol* 2009; 34: e180–e182.
  3. Abdou A and Hassam B. Ecthyma gangrenosum. *Pan Afr Med J* 2018; 30: 95.
  4. Gagnier JJ, Kienle G, Altman DG, et al. The CARE guidelines: consensus-based clinical case reporting guideline development. *Headache* 2013; 53: 1541–1547.
  5. Vaiman M, Lasarovitch T, Heller L, et al. Ecthyma gangrenosum versus ecthyma-like lesions: Should we separate these conditions? *Acta Dermatovenerol Alp Pannonica Adriat* 2015; 24: 69–72.
  6. Biscaye S, Demonchy D, Afanetti M, et al. Ecthyma gangrenosum, a skin manifestation of *Pseudomonas aeruginosa* sepsis in a previously healthy child: A case report. *Medicine (Baltimore)* 2017; 96: e5507.
  7. Cohen N, Capua T, Bilavsky E, et al. Ecthyma gangrenosum skin lesions in previously healthy children. *Acta Paediatr* 2015; 104: e134–e138.
  8. Santhaseelan RG and Muralidhar V. Non-pseudomonal ecthyma gangrenosum caused by methicillin-resistant *Staphylococcus aureus* (MRSA) in a chronic alcoholic patient. *BMJ Case Rep* 2017; 2017: bcr2017220983.
  9. Weifeng L, Zixuan L, Jun L, et al. A case of streptococcus-associated toxic shock syndrome with multiple ecthyma gangrenosum as the main manifestation. *Chin J Dermatol* 2021; 08: 729–730.
  10. Xie Y, Du J, Jin W, et al. Next generation sequencing for diagnosis of severe pneumonia: China, 2010–2018. *J Infect* 2019; 78: 158–169.
  11. Song SS, Matiz C, Tom WL, et al. Ecthyma gangrenosum-like lesions secondary to methicillin-sensitive *Staphylococcus aureus* in an immunocompetent child. *Pediatr Dermatol* 2015; 32: e259–e262.
  12. Martínez-Longoria CA, Rosales-Solis GM, Ocampo-Garza J, et al. Ecthyma gangrenosum: A report of eight cases. *An Bras Dermatol* 2017; 92: 698–700.
  13. Torgersen C, Moser P, Luckner G, et al. Macroscopic postmortem findings in 235 surgical intensive care patients with sepsis. *Anesth Analg* 2009; 108: 1841–1847.
  14. Otto GP, Sossdorf M, Claus RA, et al. The late phase of sepsis is characterized by an increased microbiological burden and death rate. *Crit Care* 2011; 15: R183.
  15. Hotchkiss RS, Monneret G and Payen D. Sepsis-induced immunosuppression: From cellular dysfunctions to immunotherapy. *Nat Rev Immunol* 2013; 13: 862–874.
  16. Wong HR. Genome-wide expression profiling in pediatric septic shock. *Pediatr Res* 2013; 73: 564–569.
  17. Mongkolrattanothai K and Dien Bard J. Sepsis in children with febrile neutropenia. *J Appl Lab Med* 2019; 3: 530–533.
  18. Lee JA, Sauer B, Tuminski W, et al. Effectiveness of granulocyte colony-stimulating factor in hospitalized infants with neutropenia. *Am J Perinatol* 2017; 34: 458–464.
  19. Bassetti M, Vena A, Croxatto A, et al. How to manage *Pseudomonas aeruginosa* infections. *Drugs Context* 2018; 7: 212527.
  20. Guo Y, Gao W, Yang H, et al. De-escalation of empiric antibiotics in patients with severe sepsis or septic shock: A meta-analysis. *Heart Lung* 2016; 45: 454–459.