

# Early Esophageal Squamous Cell Carcinoma on Varix Treated With Endoscopic Submucosal Dissection After Variceal Banding

Yasutoshi Shiratori, MD<sup>1</sup>, Takashi Ikeya, MD<sup>1</sup>, and Kenji Nakamura, MD<sup>1</sup>

<sup>1</sup>Division of Gastroenterology, St. Luke's International Hospital, Tokyo, Japan

## ABSTRACT

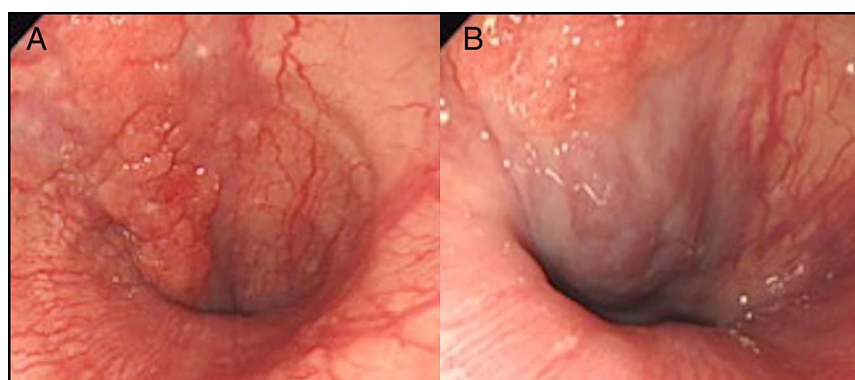
Endoscopic submucosal dissection (ESD) is known as a representative therapy for the early esophageal carcinoma, but an underlying varix is an obstacle to perform ESD. Patients with alcoholic cirrhosis may develop esophageal varix and esophageal squamous cell carcinoma at the same time. We report a case of early esophageal squamous cell carcinoma just above the esophageal varix. We performed the combination therapy of variceal banding and ESD. The number of reports about the combination therapy and optimal time to perform variceal banding before ESD is not sufficient.

## INTRODUCTION

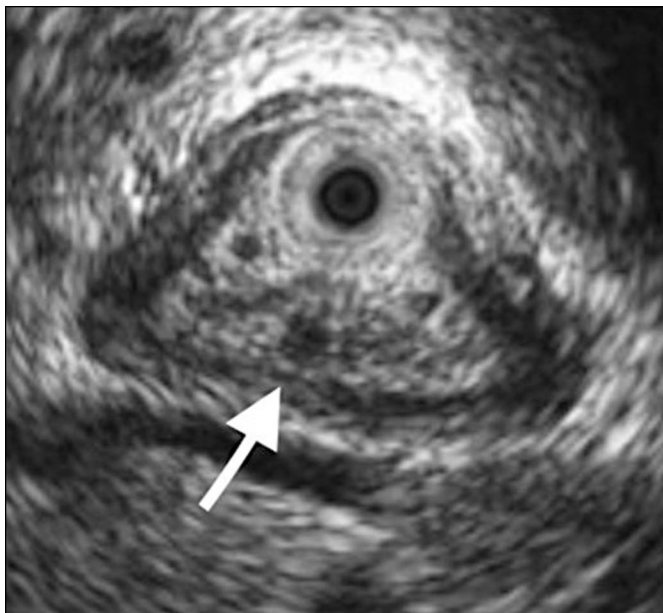
An underlying varix is an obstacle to endoscopic submucosal dissection (ESD) for an early malignant esophageal lesion. Patients with alcoholic cirrhosis may develop esophageal varices and esophageal squamous cell carcinoma.<sup>1</sup> Previous case reports have described the combination of variceal banding and ESD as a useful strategy to prevent ESD-associated bleeding; however, the number of reports is insufficient for this combination strategy to be an established treatment.<sup>2-4</sup> Furthermore, the optimal time to perform variceal banding before ESD is unclear.

## CASE REPORT

A 70-year-old man with a history of consuming large amounts of alcohol underwent upper gastrointestinal endoscopic screening. A reddening protruded lesion, approximately 3 cm in size, was recognized on the lower esophagus just above the esophageal varices (Figure 1). The demarcation line of the lesion was clear and recognized as a brownish area by narrow-band

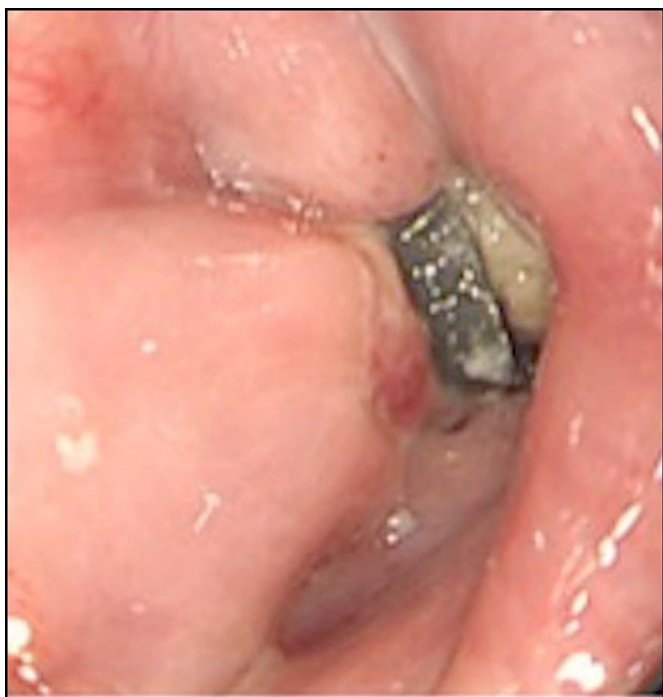

**Figure 1.** Upper endoscopy showing (A) a 3-cm reddening protruded lesion in the lower esophagus and (B) varices running just beneath the lesion.

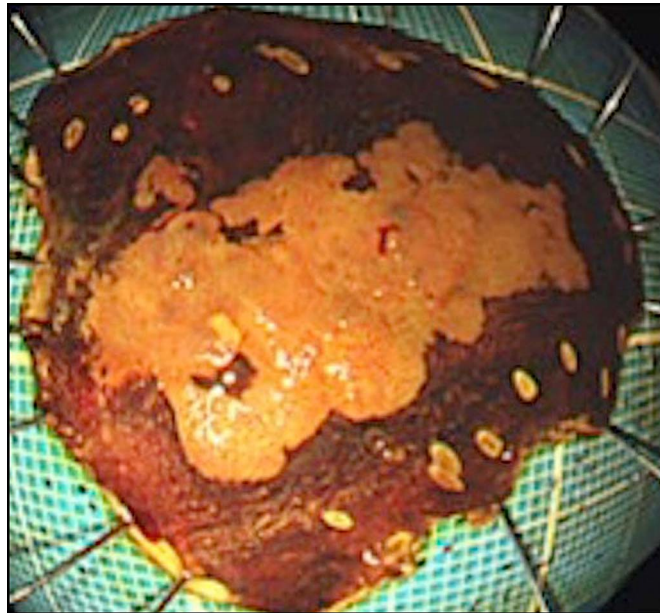


**Figure 2.** Endoscopic ultrasonography revealed an esophageal varix just beneath the tumor.

imaging. A biopsy revealed squamous cell carcinoma. Endoscopic ultrasonography revealed a penetrating varix that was 2 cm on the anal side and running just beneath the lesion (Figure 2). Computed tomography revealed no metastasis. Although endoscopic resection of the lesion was considered appropriate, we first considered the management of varices to avoid bleeding during the endoscopic resection. Endoscopic variceal banding was performed on 2 cm anal side of



**Figure 3.** Banding was performed 2 cm on the anal side of the tumor. Varix changed from blue to white color after banding.

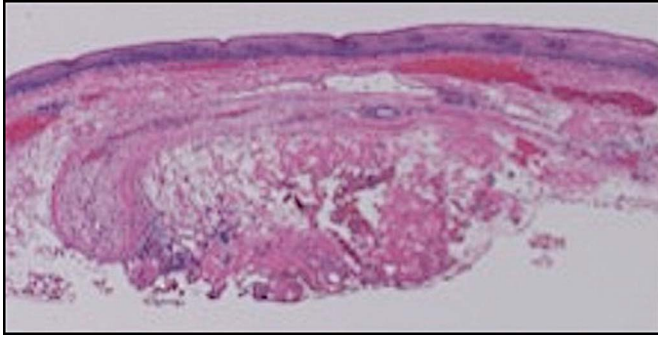


**Figure 4.** En bloc resection was achieved. Marking on the anal side of the tumor was not performed considering bleeding risk.

the lesion to cover the penetrating varix, which was confirmed in advance by endoscopic ultrasonography. Banding was performed a week before the ESD using a band-ligator device (MD-48710 EVL Device; Sumitomo Bakelite, Tokyo, Japan). After 1 week, the varices changed from blue to white (Figure 3). The anal side of the lesion was not marked before the ESD because of a bleeding risk. ESD was performed using a dual knife (Olympus, Tokyo, Japan). First, because the anal side was expected to be highly fibrotic due to the influence of banding, endoscopic cutting and dissection were initiated from the oral side. The prominent blood vessel was not found in the submucosal layer. Next, endoscopic dissection of the anal side was performed at the end of the treatment. Although significant fibrosis was observed on the anal side, en bloc resection of the lesion was achieved without significant bleeding (Figure 4). The patient was discharged 4 days after the ESD. Histopathological examination revealed a squamous cell carcinoma invading the muscularis mucosa, without lymphatic vessel and venous invasion. The horizontal margin was negative. In terms of fibrosis, the acidophilic fiber component and inflammation were identified in the submucosal layer when stained with hematoxylin-eosin (Figure 5).

## DISCUSSION

For the management of esophageal varices before ESD, sclerotherapy can be performed instead of banding, but the possibility of esophageal carcinoma development from sclerotherapy has also been reported and has not been well established.<sup>5-8</sup> We report a case in which a combination of variceal banding and ESD was effective in preventing ESD-associated bleeding. Although a few cases have been reported about this combination therapy, there



**Figure 5.** Histopathological examination revealed the acidophilic fiber component in the submucosal layer when stained with hematoxylin-eosin.

have been no reports for the optimal timing of variceal banding.<sup>2-4</sup> We tried to balance the risk of bleeding from ESD with the risk of causing fibrosis from banding. If we performed ESD immediately after banding, the risk of bleeding will be considered high. We experimentally performed banding a week before ESD in this patient, but significant fibrosis was observed around the band. In case the varix was still not deflated despite the first banding, we were going to perform rebanding at that time. Thus, a shorter interval between banding and ESD may be more appropriate. To our knowledge, this is the first report to describe the optimal time to perform variceal banding before ESD.

## DISCLOSURES

**Author contributions:** All authors contributed equally to manuscript creation. K. Nakamura is the article guarantor.

**Financial disclosure:** None to report.

Informed consent was obtained for this case report.

Received April 10, 2019; Accepted June 26, 2019

## REFERENCES

1. Hsu WH, Kuo CH, Wu IC, Lu CY, Wu DC, Hu HM. Superficial esophageal squamous cell carcinoma over esophageal varices treated by endoscopic submucosal dissection. *Gastrointest Endosc.* 2014;79:833-4.
2. Jovani M, Anderloni A, Carrara S, et al. Circumferential endoscopic submucosal dissection of a squamous cell carcinoma in a cirrhotic patient with esophageal varices. *Gastrointest Endosc.* 2015;82:963-4; discussion 964.
3. Kunzli HT, Weusten BL. Endoscopic resection of early esophageal neoplasia in patients with esophageal varices: How to succeed while preventing the bleed. *Endoscopy.* 2014;46(suppl 1):E631-2.
4. Tsou YK, Liu CY, Fu KI, et al. Endoscopic submucosal dissection of superficial esophageal neoplasms is feasible and not riskier for patients with liver cirrhosis. *Dig Dis Sci.* 2016;61:3565-71.
5. Inoue H, Endo M, Takeshita K, et al. Endoscopic resection of carcinoma in situ of the esophagus accompanied by esophageal varices. *Surg Endosc.* 1991;5:182-4.
6. Kokudo N, Sanjo K, Umekita N, Harihara Y, Tada Y, Idezuki Y. Squamous cell carcinoma after endoscopic injection sclerotherapy for esophageal varices. *Am J Gastroenterol.* 1990;85:861-4.
7. Macias Rodriguez MA, Soria de la Cruz MJ, Iglesias Arrabal M, et al. Esophageal carcinoma after the endoscopic sclerotherapy of varices. *Rev Esp Enferm Dig.* 1992;82:43-6. [Spanish.]
8. Sakata K, Ishida M, Hiraishi H, et al. Adenosquamous carcinoma of the esophagus after endoscopic variceal sclerotherapy: A case report and review of the literature. *Gastrointest Endosc.* 1998;47:294-9.

**Copyright:** © 2019 The Author(s). Published by Wolters Kluwer Health, Inc. on behalf of The American College of Gastroenterology. This is an open-access article distributed under the terms of the Creative Commons Attribution-Non Commercial-No Derivatives License 4.0 (CCBY-NC-ND), where it is permissible to download and share the work provided it is properly cited. The work cannot be changed in any way or used commercially without permission from the journal.