

## Usefulness of a forward-viewing echoendoscope in endoscopic ultrasound-guided recanalization for complete obstruction of the esophagus after chemoradiotherapy for esophageal cancer

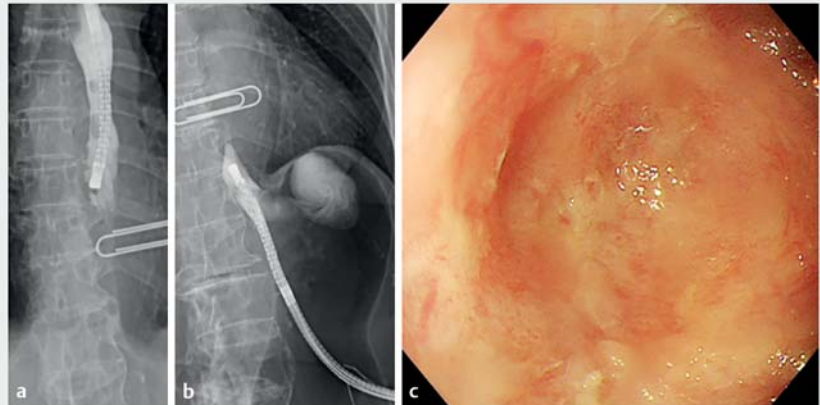


► **Fig. 1** Photograph of forward-viewing echoendoscope.

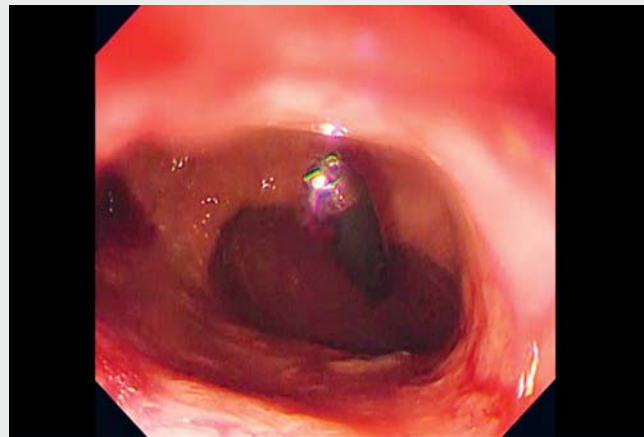
Complete obstruction of the esophagus after chemoradiotherapy for esophageal cancer is very rare and extremely difficult to treat. We report a recanalization using the rendezvous technique with endoscopic ultrasound (EUS) using a forward-viewing echoendoscope (TGF-UC260J; Olympus Medical) (► **Fig. 1**).

A 78-year-old woman developed complete obstruction of the lower esophagus after chemoradiotherapy for esophageal cancer (► **Fig. 2**) and was fed via percutaneous endoscopic gastrostomy for 7 years. The patient strongly desired to resume oral intake with minimally invasive treatment, so endoscopic treatment was performed. First, a thin endoscope was inserted through the gastrostomy route and advanced in a retrograde manner to the site of the esophageal obstruction (► **Video 1**). A forward-viewing echoendoscope was then inserted orally and advanced to the obstruction site.

Injection of saline solution into the esophagus through the retrograde scope made it possible to recognize the esophageal lumen on the anal side of the obstruction by EUS (► **Fig. 3**). The esophageal lumen on the anal side of the obstruction was punctured with a 19G needle under EUS guidance, and the puncture needle was confirmed, by



► **Fig. 2** Complete obstruction of the esophagus after chemoradiotherapy for esophageal cancer: **a, b** fluoroscopic images; **c** endoscopic image.

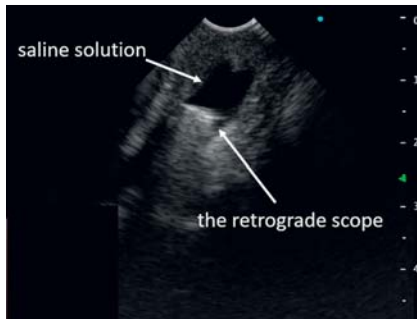


► **Video 1** Use of a forward-viewing echoendoscope in endoscopic ultrasound-guided recanalization of complete obstruction of the esophagus after chemoradiotherapy for esophageal cancer.

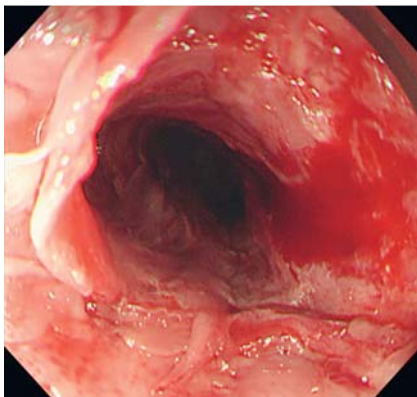
fluoroscopic contrast and also through the retrograde endoscope, to be in the esophageal lumen. A guidewire was placed in the esophagus on the anal side of the obstruction and a balloon catheter was used to dilate the obstruction site, allowing passage of the scope (► **Fig. 4**).

A total of four balloon dilations and one local steroid injection were required to maintain patency.

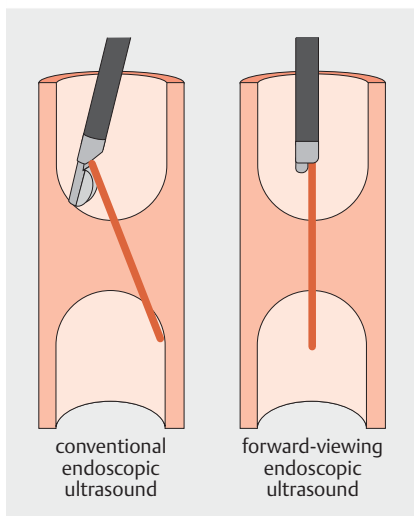
There have been several reports of treatment of complete esophageal obstruction using the EUS rendezvous technique [1, 2], but none has used forward-viewing



► **Fig. 3** Endoscopic ultrasonogram showing saline solution injected from the retrograde scope into the esophageal lumen on the anal side of the obstruction.



► **Fig. 4** Endoscopic image after balloon dilation of the site of the obstruction to 10 mm.



► **Fig. 5** Schematic images showing the angle of advancement of the needle from a conventional echoendoscope and a forward-viewing echoendoscope.

EUS. When puncturing the esophagus, which is a linear organ, forward-viewing EUS is safe and easy given the angle of the needle advanced from the scope, and the risk of perforation is low because the needle can be aimed at the center of the scar site for puncture and dilation (► **Fig. 5**).

Endoscopy\_UCTN\_Code\_TTT\_1AO\_2AN

### Competing interests

The authors declare that they have no conflict of interest.

### The authors

**Ikuhiro Kobori**<sup>1</sup>, **Yasumi Katayama**<sup>2</sup>, **Fuki Hayakawa**<sup>1</sup>, **Masaru Kuwada**<sup>1</sup>, **Yoshinori Gytoku**<sup>1</sup>, **Yumi Kusano**<sup>1</sup>, **Masaya Tamano**<sup>1</sup>

- 1 Department of Gastroenterology, Dokkyo Medical University Saitama Medical Center, Saitama, Japan
- 2 Endoscopy Center, Dokkyo Medical University Saitama Medical Center, Saitama, Japan

### Corresponding author

**Ikuhiro Kobori, MD**

Department of Gastroenterology, Dokkyo Medical University Saitama Medical Center, 2-1-50 Minami-koshigaya, Koshigaya City, Saitama 343-8555, Japan  
viva.s.a.410@gmail.com

### References

- [1] Gornals JB, Consiglieri C, Castelli JM et al. Treatment of complete esophageal stenosis using endoscopic ultrasound-guided puncture: a novel technique for access to the distal lumen. *Endoscopy* 2014; 46: E2–E3. doi:10.1055/s-0033-1358932

- [2] Martínez-Moreno B, Medina-Prado L, Baile-Maxía S et al. Endoscopic ultrasound-guided recanalization of complete pharyngoesophageal stenosis. *Endoscopy* 2021; 53: E309–E310. doi:10.1055/a-1270-6704

### Bibliography

*Endoscopy* 2022; 54: E1053–E1054

DOI 10.1055/a-1899-8301

ISSN 0013-726X

published online 25.8.2022

© 2022. The Author(s).

This is an open access article published by Thieme under the terms of the Creative Commons Attribution-NonDerivative-NonCommercial License, permitting copying and reproduction so long as the original work is given appropriate credit. Contents may not be used for commercial purposes, or adapted, remixed, transformed or built upon. (<https://creativecommons.org/licenses/by-nc-nd/4.0/>)

Georg Thieme Verlag KG, Rüdigerstraße 14, 70469 Stuttgart, Germany



### ENDOSCOPY E-VIDEOS

<https://eref.thieme.de/e-videos>



*Endoscopy E-Videos* is an open access online section, reporting on interesting cases

and new techniques in gastroenterological endoscopy. All papers include a high quality video and all contributions are freely accessible online. Processing charges apply (currently EUR 375), discounts and waivers acc. to HINARI are available.

This section has its own submission website at

<https://mc.manuscriptcentral.com/e-videos>