

# MRI Evaluation of Mullerian Duct Anomalies: Practical Classification by the New ASRM System

Mahasen S Al Najar<sup>1</sup>, Nosaiba T Al Ryalat<sup>1</sup>, Jaffer S Sadaqah<sup>1</sup>, Rawand Y Husami<sup>1</sup>,  
Karem H Alzoubi<sup>1,2,3</sup>

<sup>1</sup>Department of Diagnostic Radiology, The University of Jordan Hospital, Amman, Jordan; <sup>2</sup>Department of Pharmacy Practice and Pharmacotherapeutics, University of Sharjah, Sharjah, United Arab Emirates; <sup>3</sup>Department of Clinical Pharmacy, Jordan University of Science and Technology, Irbid, Jordan

Correspondence: Mahasen S Al Najar, Department of Diagnostic Radiology, The University of Jordan Hospital, P. O. Box 13046, Queen Rania Street, Amman, 11942, Jordan, Fax +96265353388, Email m.najar@ju.edu.jo

**Objective:** To describe variable mullerian duct anomalies using magnetic resonance imaging (MRI) and to classify these anomalies according to the available classification systems, namely the American Fertility Society (AFS) system, the European Society of Human Reproduction and Embryology (ESHRE) system, and the new American Society for Reproductive Medicine (ASRM) system.

**Design:** Retrospective chart review.

**Subjects:** The pelvic MRI studies and the clinical records of 64 females with mullerian congenital anomalies were retrospectively reviewed between January 2010 and December 2021. The mean age was 22 years (age range 2–63 years).

**Main Outcome Measures:** Detailed imaging findings were recorded, and the resulting mullerian anomalies were then classified according to the three classification systems of interest.

**Results:** Variable mullerian anomalies were found among patients with multiple frequencies. Mullerian agenesis and hypoplasia were found in 12 patients (19%) and 16 patients (25%), respectively. Uterus didelphys was found in 5 patients (8%). Twelve (19%) patients had septate uterus, while 8 (12.5%) had a bicornuate anomaly. Unicornuate uterus was present in 7 patients (11%). Isolated vaginal anomaly was diagnosed in 4 patients (6%). Renal/urinary tract imaging was available for 27 (42%) patients, and accompanying urinary tract anomalies were noted in 10 of them (37%). Few ovarian and other extra-renal anomalies were observed.

**Conclusion:** MRI could efficiently delineate the mullerian anomalies regardless of their complexity. Most of these anomalies were more efficaciously categorized by the ESHRE and the new ASRM systems, compared to the originally widely used AFS system. The new ASRM classification was found to be more practical as it is a modification of the original AFS system, using drawings with clear descriptions instead of symbols. This is particularly helpful in the radiological era, saving time and effort.

**Keywords:** mullerian duct anomalies, classification system, renal agenesis, uterus, pelvic MRI

## Introduction

Mullerian duct anomalies are common and may drastically affect the reproductive health of women. Variable prevalence estimates are available in the literature; nonetheless, according to the meta-analysis done by Chan et al, a prevalence of 5.5% in the general population was reported, detecting a higher prevalence amongst infertile women (8.0%) and even higher in patients with miscarriages (ranging 13.3–24.5%).<sup>1</sup>

Embryologically, two paired mesonephric (wolffian) ducts and paramesonephric (mullerian or female genital) ducts are present at 6 weeks of gestation. Thenceforth, bidirectional growth of the mullerian ducts accompanied by simultaneous regression of the mesonephric ducts will occur due to the absence of the mullerian inhibiting factor in the female fetus.<sup>2</sup> This is accompanied by midline migration and fusion of these ducts with ultimate resorption of the intervening septum, resulting in the development of the uterus and proximal 2/3 of the vagina. Interruption of any of these processes will result in a certain mullerian anomaly according to the stage of development.

Detailed delineation of these mullerian anomalies can be achieved using MR imaging with its multi-planar reformatting abilities. This provides the benefit of non-invasively highlighting clear anatomic details of the uterus and its zonal anatomy, in addition to easily delineating the external fundal contour which is pivotal in differentiating between two major anomaly classes of septate and bicornuate/didelphys uterus.

Several classification systems of the mullerian anomalies exist, but the system of the American Fertility Society (AFS) (later titled the American Society for Reproductive Medicine; ASRM) is the most widely used by virtue of its simplicity.<sup>3</sup> It is a revision of the system first created by Buttram and Gibbons in 1979.<sup>4</sup> However, this system has its limitations pertaining to its inability to classify complex anomalies involving different portions of the mullerian duct and the obstructive cervical and vaginal anomalies. A more recent system was introduced by the working group of the European Society of Human Reproduction and Embryology (ESHRE) and the European Society for Gynecological Endoscopy (ESGE),<sup>5</sup> although it is not widely accepted and was criticized for its over-diagnosis of septate uterus, which may result in unwarranted treatment.<sup>6</sup> Very recently, by the end of the year 2021, the ASRM presented their new classification (ASRM mullerian anomalies classification 2021),<sup>7</sup> which is a modification and expansion of the original AFS system.

In this study, we present variable mullerian anomalies found in our cohort, based on MRI evaluation of these patients, including associated anomalies, particularly urinary tract anomalies. Categorization of these anomalies was done according to the widely used AFS and the other two more recent systems, ie, ESHRE and ASRM 2021, to determine the most appropriate one to be used in radiological practice.

## Methods

The protocol of the current study was approved by the institutional review board of The University of Jordan, Amman, Jordan. Due to the retrospective nature of the study and the fact that data were obtained anonymously, the IRB waived the need for an informed consent. This study complies with the Declaration of Helsinki. In the current research, the pelvic MRI studies and the clinical records of 64 females with mullerian congenital anomalies between January 2010 and December 2021 were retrospectively reviewed. The mean age recorded was 22 years (age range 2–63 years). They had variable clinical indications including amenorrhea, infertility, cyclic hematuria, cyclic abdominal pain, urogenital sinus/cloaca anomalies, and one case of post-menopausal bleeding. Incidental cases for a pelvic MRI exam (done for other reasons) were also found.

MRI studies were performed on a 3 T scanner (Siemens Verio) with a body array coil using the following sequences: T2-weighted fast SE imaging in the sagittal, axial, and coronal planes. Additionally, oblique coronal T2W sequence oriented parallel to the long uterine axis was used when needed (TR/TE, 4000–6000/85–110 milliseconds; field of view (FOV), 240–260 mm, matrix 320 × 320, slice thickness 4 mm, interslice gap 0.4–0.5, number of signal averages 2) and axial T1-weighted spin echo imaging with and without fat saturation (TR/TE, 730/12 milliseconds, FOV 250 mm, matrix 320 × 320, slice thickness 4 mm with interslice gap of 0.5, averages 2). Axial STIR images were also included in the pelvic protocol (TR/TE, 4000/30–60 milliseconds, FOV 250 mm, matrix 256 × 256, gap 0.4–0.6, slice thickness 4 mm, averages 1–2).

Additional coronal T2-weighted images with a large field of view was done for some patients to visualize the kidneys, since not all patients had a clear referral regarding a mullerian congenital anomaly. Other imaging modalities such as ultrasound and CT were available for a subset of patients, that helped in the diagnosis of other associated anomalies particularly urinary tract anomalies.

Detailed imaging findings were recorded for each patient. This was accomplished by a single radiologist with 11 years of expertise in women's imaging, who was blinded to patient's data and data from other imaging modalities. Differentiation between septate and bicornuate uterus was done as follows: Septate uterus is diagnosed if an external fundal cleft/indentation of less than 1 cm is found on the coronal uterine plane (calculated by drawing a line between the tops of both uterine horns, and the perpendicular distance from this line to the lowest point of the indentation is measured), and if internal fundal indentation towards the endometrium measures >1 cm (calculated by drawing a line between both tubal ostia and measuring the distance from this line to the top of myometrial or fibrous septum toward the endometrial cavity) together with an angle of the leading edge of the septum of <90°. On the other hand, more than 1 cm

indentation of the external fundal contour is needed to diagnose a bicornuate/didelphys anomaly.<sup>7,8</sup> Other ways of calculation are available in the literature, which are particularly useful in equivocal cases. If the intercornual distance is  $<4$  cm, it is usually septate compared to  $>4$  cm seen more commonly in a bicornuate uterus. Likewise, if the intercornual angle is  $<75^\circ$ , it is suggestive of a septate uterus as opposed to an angle  $>105^\circ$ , that would be more suggestive of a bicornuate uterus.<sup>2</sup> The septate uterus was further stratified into partial, if the septum does not reach the external cervical os, or complete, if it reaches the external os resulting in two separate cervical canals (septate or duplicated cervixes).<sup>9,10</sup> The evaluation of hypoplastic/infantile uterus depended on the small size of the uterus, which showed either a uterine body:cervix ratio of 1:1 or 1:2 and on the thinned endometrial stripe with poor zonal anatomy.

The resulting anomalies were then stratified according to the most widely used classification system of the AFS (used since 1988), the ESHRE, and the new ASRM classification systems, to ensure a compatible and applicable system in terms of a radiological point of view (as shown in [Supplementary Table 1](#)).

Associated anomalies particularly of the urinary system, the presence of hematometra, hematocolpos, special findings regarding the ovaries, and other pelvic pathologies were also taken note of.

## Results

Variable congenital mullerian anomalies were found at different frequencies. A total of 12 cases (19%) of mullerian agenesis were described, with an age range of 2–20 years. Two young children aged 2 and 4 years were diagnosed with mullerian anomalies, which was incidentally discovered during pelvic MRI work-up for urogenital sinus anomaly accompanying OHVIRA syndrome and for precocious puberty, respectively.

In three cases out of the 12 diagnosed, agenesis was confined either to the cervix, to the cervix and vagina, or to the fundus. The rest of the nine patients showed complete mullerian agenesis, ie, Mayer–Rokitansky–Kuster–Hauser syndrome, four of which showed a mullerian remnant, two with a solitary non-cavitary remnant, one with a solitary cavitary remnant, and one with bilateral cavitary and non-cavitary remnants.

Sixteen cases were diagnosed with hypoplastic/infantile uterus (25%), with the age range of 14–36 years. Uterus didelphys was diagnosed in 5 patients (8%) with ages ranging 2–24 years. All had an associated vaginal anomaly as follows: two had a longitudinal vaginal septum and obstructed hemi-vagina, one had a longitudinal vaginal septum down to the introitus, one with an incomplete longitudinal vaginal septum with a common distal vagina joining the urethra (urogenital sinus anomaly), and one with an obstructive mid-transverse septum.

Twelve patients (19%) had a septate uterus (12–48 years); 9 of them had a partially septate uterus, one with an associated mid-transverse vaginal septum. The remaining three patients had a complete septate uterus. One patient had a complete septate uterus with double cervixes and a dilated vagina that connected distally to the urinary bladder, ie, urogenital sinus anomaly. The second one had a complete septate uterus and cervix with a normal vagina. The third one had a complete septate uterus, cervix, and vagina down to the introitus.

Unicornuate uterus was present in seven cases (11%) with age range 14–63 years. Two had a solitary functioning horn, while three had non-communicating cavitary horns. A further case had a rudimentary horn, and another one had a communicating cavitary horn. The latter one had evidence of endometrial carcinoma within the main functioning horn, which was responsible for post-menopausal bleeding in this patient.

Eight cases (12.5%) were found to have bicornuate uterus (12–45 years). Seven patients had bicornuate unicollis anomaly, one of them showing an elongated non-canalized cervix with secondary hematometra of both horns. The eighth case had a bicornuate bicollis anomaly with distal cervical agenesis resulting in severe hematometra of both horns and cervixes.

Isolated vaginal anomalies were found in four patients (6%) in the age range of 10–16 years. All showed associated hematometra. Two patients had an atretic mid- and distal vagina, the third had distal cervical agenesis with complete vaginal atresia, and the fourth had a low transverse septum. All these anomalies are presented in [Supplementary Table 1](#) for all patients, along with their classification according to the three concerned systems.

Accompanying urinary tract anomalies were noted in a subset of patients. Renal/urinary tract imaging was available for 27 (42%) patients, either by ultrasound, CT, or MRI. The anomalies were found in 10 out of 27 patients (37%) and were distributed as follows: two cases of a single right kidney in association with Mayer–Rokitansky syndrome (one of them also had a neurogenic bladder); horseshoe kidney in a case with hypoplastic/infantile uterus; an absent right kidney

was found in three cases with uterus didelphys, two of them in association with OHVIRA (obstructed hemivagina and ipsilateral renal agenesis) syndrome while the third one showed medullary nephrocalcinosis as well; a fourth didelphys case had severe bilateral hydronephrosis with ectopic insertion of the left ureter into the urinary bladder; a single kidney was seen in a case of complete septate uterus, which was also associated with a urogenital sinus anomaly; and an absent right kidney was seen in two cases with a unicornuate uterus, which was ipsilateral to the side of absent or rudimentary horn ([Supplementary Table 2](#)).

Ovarian abnormalities were found in association with hypoplastic/infantile uterus (12 out of 16 cases). Seven of them showed small ovaries for age. In 5 other patients, no ovaries were identified in the pelvis or lower abdominal region; of these, 3 had an XX karyotype and one XO (Turner syndrome).

Limited ovarian anomalies were detected among the other müllerian anomalies. No gonads were found in one case with Mayer–Rokitansky syndrome in a patient with a normal XX karyotype. An ectopic left ovary was seen in the left anterolateral aspect of the pelvis just behind the abdominal wall in another two cases with Mayer–Rokitansky syndrome. Bilateral ovarian endometriosis was seen in a case with a partial septate uterus, and a right ovarian endometrioma was noted in another patient with a partial septate uterus, which was associated with a mid-transverse vaginal septum. One case, with a unicornuate uterus with non-communicating right cavity horn, had the left ovary located more anteriorly above the normal left horn. Bilateral ovarian dermoids were seen in a case with a bicornuate unicollis uterus.

A few coincident anomalies were diagnosed. Cloaca was diagnosed in two cases of didelphys: one of them had a single dilated vagina with a mid-transverse septum, and the other had an incomplete longitudinal vaginal septum with the common distal vagina joining the urethra. A urogenital sinus anomaly was found in a case of combined OHVIRA syndrome and congenital adrenal hyperplasia (formerly reported<sup>11</sup>) and also in a second case with a complete septate uterus who was diagnosed with Fraser syndrome (cryptophthalmos-syndactyly syndrome).

Wolfram syndrome (diabetes insipidus, diabetes mellitus, optic atrophy, and deafness; DIDMOAD) was diagnosed in one patient with an infantile uterus. Sacral lipomyelomeningocele was found in a patient with a unicornuate uterus. A hypoplastic thumb and radius was found in a case of müllerian agenesis. Endometrial cancer was diagnosed in a patient with a unicornuate uterus arising within the dominant horn ([Supplementary Table 2](#)).

## Discussion

MRI is widely used in the evaluation of congenital müllerian anomalies. The sensitivity and specificity of MRI in correctly categorizing these anomalies are differently reported and reach about 100% to 28.6% and 100% to 66%, respectively.<sup>12</sup> The high sensitivity is explained by MRI's ability to demonstrate excellent intrauterine zonal anatomy and present clear delineation of the outer fundal contour, which is crucial to differentiate between the two major categories of a septate and bicornuate uterus. Furthermore, MRI distinctly defines the entire pelvic anatomy allowing for pinpointing other associated anomalies, particularly those of the urinary system. Furthermore, it helps in identifying other causes of amenorrhea, such as androgen insensitivity syndrome, as it can confirm the presence of rudimentary ectopic testes and the absence of uterus and ovaries.<sup>13,14</sup>

Various müllerian anomalies exist, which result from failure of formation of the müllerian ducts (complete or incomplete) or from fusion/absorption defects of these ducts. Several classification systems are available for these anomalies. The most widely used system is of the American Fertility Society (AFS) (now named the American Society for Reproductive Medicine), which was published in 1988,<sup>3</sup> revising the work done by Buttram and Gibbons in 1979.<sup>4</sup> The basis of their classification is the uterine anatomy since these anomalies are considered aberrations from the normal anatomy. It is user-friendly as it uses simplified descriptions and iconic drawings of the different categories. Furthermore, this classification appears to correlate with the patients' prognoses – mainly pregnancy outcome – and dictates the appropriate therapeutic intervention, which in most cases aims to restore normal anatomy.<sup>15</sup> Nonetheless, a few drawbacks do exist for this classification system. Certain congenital anomalies cannot be allocated within the main categories or subcategories of the AFS system. Some anomalies with a different clinical presentation and different surgical management are included in one class, eg, class 1. Also, the obstructive anomalies resulting from vaginal or cervical agenesis/dysgenesis associated with a functional uterus are not clearly represented. Additionally, complex anomalies resulting from unusual combinations of uterine/cervical/vaginal anomalies, that require complex surgical treatment, are likewise not categorized.<sup>15,16</sup> The system does not provide accurate measurement methods to reliably differentiate between a septate, arcuate, and bicornuate uterus either.<sup>10</sup>

A more recently published classification system was introduced in 2013 by a working group from the European Society of Human Reproduction and Embryology (ESHRE) and the European Society for Gynecological Endoscopy (ESGE)<sup>5</sup> that is related to the clinical management of female genital anomalies. It is based on uterine anatomy as basic characteristic but used uterine anatomical deviations deriving from the same embryological origin as secondary characteristics for patient grouping, which allows inclusion of more variable anomalies including unusual ones. It incorporates seven main classes, which are further classified into subclasses, expressing clinically significant anatomical variations. Their criteria to diagnose septate and bicorporeal uterus depended on the measurements of the uterine wall thickness (calculated by the average thickness of the anterior and posterior wall at its thickest portion). If uterus has normal outline and internal fundal indentation is >50% of the uterine wall thickness, then septate uterus is diagnosed. If uterus has abnormal fundal outline with external fundal indentation >50% of the uterine wall thickness at the midline, bicorporeal uterus is diagnosed that can be partial or complete.<sup>5,17</sup> Cervical and vaginal anomalies were classified separately into clinically significant subclasses. This allows easier classification of complex anomalies involving different parts of the genital tract (uterus, cervix, and vagina), regardless of the aberrant anomaly. This could not be done with the AFS system. A further advantage of the ESHRE system over the AFS system is that it promotes the description of associated non-mullerian anomalies such as urinary tract anomalies that consequently impact the management of these patients. In a study evaluating this classification system,<sup>16</sup> 38 out of 39 types of anomalies could be classified comprehensively, which were published in the literature using liberal and subjective description and could not be properly classified using AFS system. On the other hand, Ludwin et al had made a comparison between the ESHRE and AFS systems and concluded that the use of the former had led to relative over-diagnosis of septate uterus, which may lead to unnecessary overtreatment.<sup>6</sup>

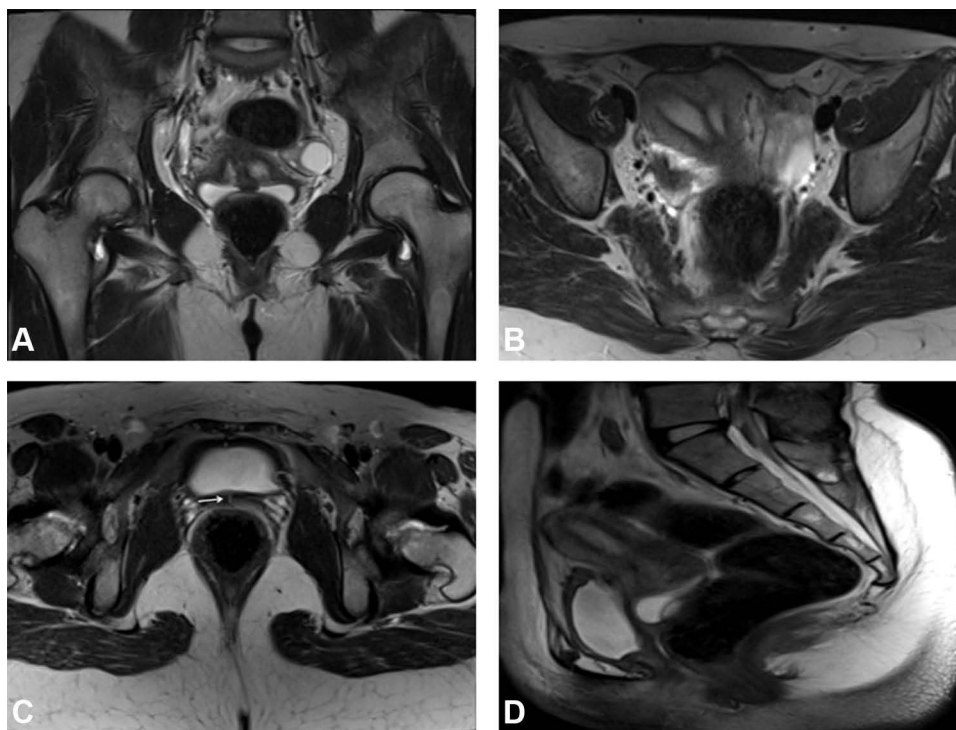
Late in 2021, the American Society for Reproductive Medicine<sup>7</sup> presented a new classification for mullerian anomalies based on the iconic AFS classification. The categories were modified and expanded with the addition of three groups: longitudinal vaginal septum, transverse vaginal septum, and complex anomalies, resulting in nine categories. Updated line drawings were maintained to effectively represent the anomalies for better understanding and recognition. They further included detailed descriptive terms of the anomalies instead of using symbolic terms like the ones used in the ESHRE system, and even suggested other descriptions for the anomalies while emphasizing the most used one. The new system included most of the anomalies that were described but pointed out its incompleteness, similar to the other systems, as a consequence of the possibility of the unlimited number of variations. And, as such, the system can be updated to include new anomalies. A recognizable feature of this system is that it has an interactive educational tool incorporating clinical presentation, diagnosis, and treatment of mullerian anomalies. This provides a comprehensive overview for every health care provider concerned about these anomalies, regardless of his/her specialty, helping raise awareness and education to promote better patient care.

Although the new ASRM system did not include a category for non-mullerian associated anomalies, it strongly recommended renal imaging in the presence of mullerian agenesis or obstructive anomalies. According to them, the rationale behind this is a result of difficulty faced in determining the incidence of associated anomalies from the literature, which is related to the poor quality of the medical literature, due to unavailability of advanced imaging techniques at the time of publication of some of them, infrequent occurrences of mullerian anomalies, and scarce studies reporting associated anomalies in non-syndromic cases.

The most common anomaly found in our study was septate uterus (19%), which results from failure of resorption of the connecting tissue between the two fused mullerian ducts, partially or completely. This is less than the reported prevalence of this anomaly reaching 55%<sup>18,19</sup> and 48%.<sup>20</sup> However, in one study, the reported prevalence was much lower, reported at 7%.<sup>21</sup> Arcuate uterus is considered the mildest form of failure of mullerian septum resorption, but, as it has no adverse clinical outcomes, it is considered a normal variant and consequently was not accounted for in our study. However, it must be differentiated from septate uterus by evaluating the depth of the fundal myometrium protruding into the uterine cavity which should measure less than 1 cm in length with an obtuse angle >90° compared to >1 cm length and < 90° in septate uterus.<sup>7,9</sup> Complete septate uterus was diagnosed in three patients, and only one of them (8%) had a concomitant completely septate vagina as well. This is close to the reported 5% incidence of longitudinal vaginal septum in women with septate uterus compared to the higher incidence of didelphys and bicornuate anomalies.<sup>2</sup>

The partially septate uteri found in our patients were clearly categorized in all three systems except for one, which could only be classified by the ESHRE system. Two patients with a complete septate uterus and a normal vagina were classified by the original AFS and ESHRE systems, but were not described in the new ASRM system (Figure 1). The





**Figure 1** Case of complete septate uterus with urogenital sinus anomaly presenting with cyclic hematuria, categorized by AFS and ESHRE systems. **(A)** Coronal T2W image demonstrating duplicated cervixes. **(B and C)** Axial T2W images showing complete septate uterus and the narrow connection (arrow) between the vagina and the urinary bladder. **(D)** Sagittal T2W image showing the dilated proximal vagina with non-visualization of its distal portion. A Gartner duct cyst is seen at its posterior wall.

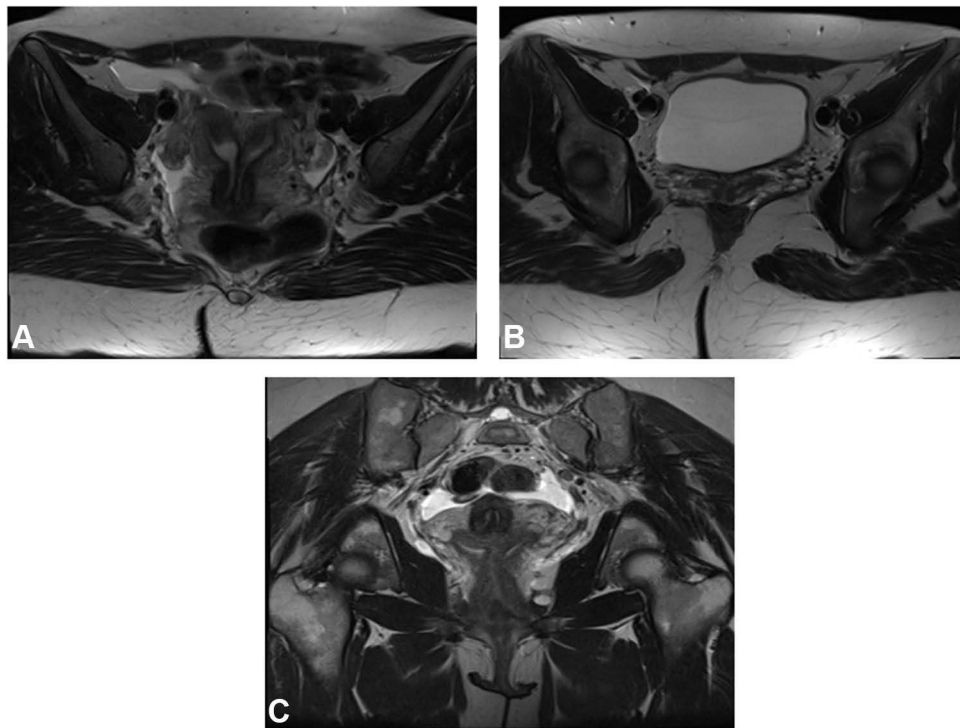
case with complete septate uterus and complete septate vagina was classified by the ESHRE and ASRM systems but not by the AFS system (Figure 2).

Equally common was müllerian agenesis (19%). It results from the failure of development of the müllerian ducts, resulting in complete absence of the uterus, cervix, and proximal vagina in its most severe form, also known as Mayer–Rokitansky–Kuster–Hauser syndrome. Its prevalence is noticeably high amongst our patients. This is similar to the result from a study by Bernadette et al who reported a prevalence of 24%,<sup>21</sup> although it is different from other published data that reported a lower prevalence of 5–10%<sup>18</sup> and 4%.<sup>22</sup> Müllerian agenesis is less commonly segmental as was found in three cases of our series, but in the majority it involved the whole müllerian duct. Only four patients with complete agenesis showed the presence of remnants (33%), three of them with unilateral and one with bilateral remnants. This is contradictory to the reported frequency of associated remnants by Wang et al,<sup>23</sup> who found remnants in 78% of their series of 92 patients, the vast majority of them with bilateral remnants. Similarly, Hong et al<sup>24</sup> and Oppelt et al<sup>25</sup> reported bilateral remnants in 98.5% and 84.2% in their large cohorts, respectively. However, these varied results cannot be relied on due to the large difference in number of cases between our and their cohorts.

The twelve cases could be successfully categorized according to the ESHRE and ASRM systems except for one with fundal agenesis. The four cases with remnants were considered not classified by the original AFS system due to the lack of description/drawings of these remnants.

Bicornuate uterus results from incomplete fusion of the müllerian ducts resulting in two separate symmetric uterine cornua, that appear fused at the lower and/or mid-uterine segments. There will be two endometrial cavities communicating with each other with a single cervix (bicornuate unicollis). However, there might be non-degeneration of the fused segments of the lower uterus and cervix resulting in two separate uterine cavities and duplicated cervixes (bicornuate bicollis). A longitudinal vaginal septum may even be present and is reported in about 25% of these cases.<sup>8</sup>

The bicornuate anomaly showed almost an equal frequency in our study (12.5%) compared to the published literature,<sup>2,18</sup> although it was also reported to represent 17% of anomalies.<sup>20</sup> Seven cases showed the bicornuate unicollis variant; all of them were clearly described in the three systems, apart from the case with an elongated non-canalized



**Figure 2** Case of complete septate uterus and vagina down to introitus, categorized by ASRM and ESHRE systems. (A and B) Axial T2W images showing the complete septate uterus and vagina. (C) Coronal T2W image showing the septate cervix and the two vaginae.

cervix and secondary hematometra of both horns that could only be categorized using the ESHRE system. A solitary case had a bicornuate bicollis anomaly with distal cervical agenesis resulting in severe bilateral hematometra, which could only be classified by ESHRE system (Figure 3).

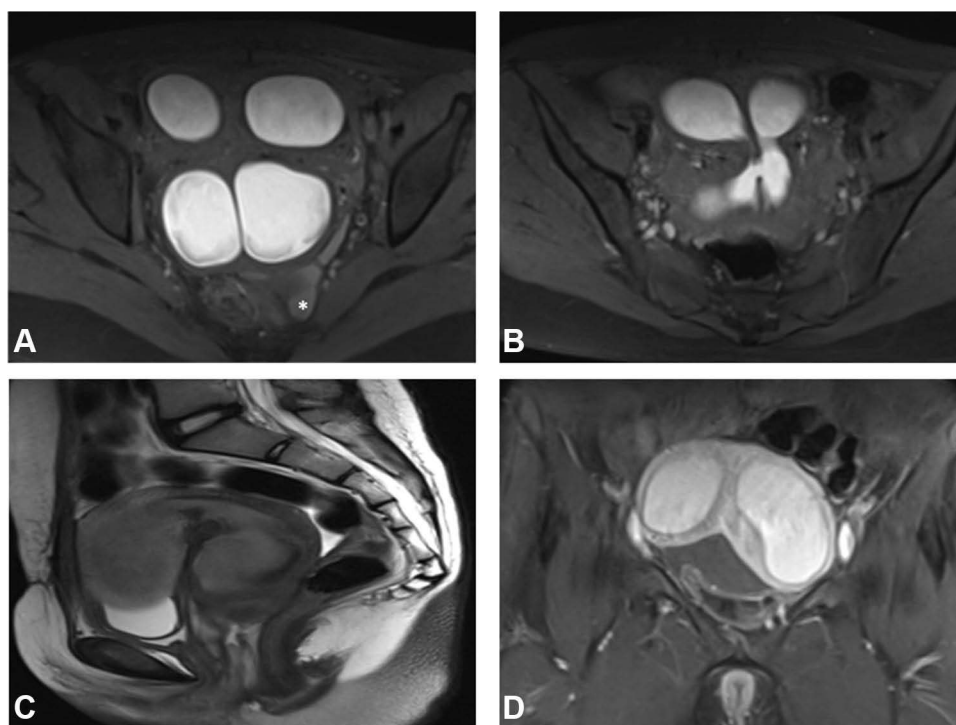
Uterus didelphys results from non-fusion of the müllerian ducts giving rise to widely divergent uterine horns with two separate endometrial cavities and two cervixes. It is different from a bicornuate uterus as there is no fusion at all between the uterine horns and cervixes, although minor cervical fusion, particularly inferiorly, might be present. A concomitant longitudinal vaginal septum of variable length is seen more commonly (75%) compared to a bicornuate uterus (25%).<sup>2,8</sup>

The didelphys anomaly was also similar in frequency amongst our patients (8%), compared to the reported literature values of 5%<sup>18</sup> and 10%.<sup>20</sup> All of our five patients had an associated vaginal anomaly – two of them with an obstructed hemi-vagina, the OHVIRA syndrome (obstructed hemivagina with ipsilateral renal agenesis). The original AFS system did not address such associated vaginal anomalies, while the new ASRM classification described such variants within the uterus didelphys category, excluding the case with a transverse vaginal septum. A clear correlating category for all of them was identified in the ESHRE system.

Agenesis or incomplete development of one of the müllerian ducts results in a unicornuate uterus. This is usually associated with a rudimentary horn, which may or may not contain an endometrium (cavitary). If it is cavitary, it may be communicating or non-communicating with the endometrial cavity of the normally developing contralateral horn.

The prevalence of this anomaly amongst our patients was almost half the reported, 11% compared to 20%.<sup>18,19</sup> Nevertheless, similar to the published literature, the isolated horn was found in one-third of the patients, while the majority had variable degrees of a rudimentary uterine horn with or without a cavity. The unicornuate uterus was seen more commonly on the left side in our study, contrary to the reported right-sided laterality, which was unexplained according to them.<sup>20</sup> All these seven cases had a correlating category in the three classifying systems.

Isolated vaginal anomaly was the least common anomaly in our cohort (6%). Partial or complete vaginal atresia was the dominant anomaly (75%), and one case (25%) showed a low transverse septum. Vaginal atresia is estimated to occur in 1 in 5000–10,000 live female births.<sup>26</sup> Isolated atresia is extremely rare and is more commonly part of a complex



**Figure 3** Case of bicornuate bicollis with distal cervical obstruction, categorized only by ESHRE system. (A and B) Axial T1 fat sat images demonstrating marked hematometra and hemoperitoneum (\*) with communication between both cervical canals. (C) Sagittal T2W image showing hematometra of the uterine body and cervix. Note the normal vagina. (D) Coronal contrasted T1 fat sat image demonstrating the deep fundal cleft.

anomaly.<sup>26,27</sup> Transverse vaginal septum is even less common than atresia and is reported to occur in 1 in 70,000 females,<sup>26,28</sup> which is concordant with our findings. It results from anomalous fusion between the müllerian duct and the urogenital sinus. It can occur at any level along the vagina, but most commonly occurs in the proximal third.<sup>2</sup> It can also be found in association with other müllerian anomalies but most commonly with uterus didelphys, as was found in our two cases of OHVIRA syndrome.

The cases with vaginal atresia were clearly described in the three systems, while the one with an isolated transverse septum did not have a description in the original AFS system.

Hypoplastic/infantile uterus was encountered in 25% of cases (16 patients), and all presented with amenorrhea. The definition of a hypoplastic uterus is variable and is not well addressed in the literature, and the term is sometimes interchangeably used with infantile uterus. One author defined hypoplastic uterus as small-for-age uterus with low T2 signal intensity and diminished zonal anatomy even if an endometrial stripe is present.<sup>19</sup> Another author added – in addition to this definition – a small uterus with normal body:cervix ratio of 2:1, reduced intercornual distance of <2 cm, and reduced endometrial/myometrial width (normal is 1:3.6).<sup>21</sup>

Uterine hypoplasia was classified as category I in the AFS system together with agenesis, but no separate drawing or clear definition was provided. The new ASRM system even removed the term from its classification without clarification. In contrast, the ESHRE system specified a subclass named infantile uterus under the main class of dysmorphic uterus (class Ib) and defined it as a narrow uterine cavity without lateral wall thickening with an inverse ratio of 1/3 uterine body and 2/3 cervix.<sup>5</sup>

The majority of these patients had either small ovaries or non-visualized ovaries. Unfortunately, hormonal assay and karyotyping were done only for a few patients. Hypogonadism was found in some patients with small ovaries, and a normal female karyotype was found in three patients with absent ovaries, while XO karyotype was present in a fourth case. We think that it is important to perform a hormonal assay for all patients with hypoplastic/infantile uterus to check for the possibility of hypogonadism, rather than just considering it as a pure developmental müllerian anomaly, and, in cases of absent ovaries, to perform karyotyping as well.



The incidence of associated mal-positioned or ectopic ovaries was scarce in our study (3 cases; 5%) contrary to the reported literature (17%).<sup>29</sup> Two of these (17%) were in association with the MRKH syndrome without remnants, located in the left anterolateral aspect of the pelvis just behind the anterior abdominal wall. This is similar to the finding by Allen et al<sup>29</sup> but contradicts the findings of Preibsch,<sup>30</sup> Wang et al,<sup>23</sup> and Wang et al<sup>31</sup> who reported a much higher incidence of 41.6%, 38%, and 28% among their MRKH syndrome patients, respectively. The third case was seen in association with a unicornuate uterus (14%) with the ectopic ovary being located above the normal horn; this again is different from other reports in the literature in terms of incidence and ovarian location.<sup>20,29</sup>

The incidence of ovarian endometrioma was very low amongst our patients (3%) and was found only in two cases with partial septate uterus. This is concordant with the study that did not find a difference in the frequency of endometriosis by laparoscopy between infertile patients with non-obstructive mullerian anomalies and the control group.<sup>32</sup> However, there was increased prevalence of endometriosis amongst those with a unicornuate uterus.

Likewise, Ugur et al<sup>33</sup> have not found significant difference in the frequency of endometriosis between patients with mullerian anomalies and the control group without anomalies. Rather, the obstructive mullerian anomalies showed a higher association with endometriosis compared to the non-obstructive anomalies. On the other hand, Nawroth et al<sup>34</sup> found a higher incidence of endometriosis in their patients with septate uteri compared to the infertile control group without anomalies.

The association between renal anomalies and mullerian anomalies is well known. In one study, 30% of patients with mullerian anomalies showed an absent kidney; the majority were in association with uterus didelphys (63%) and less often with uterine agenesis (15%).<sup>35</sup> In a cohort of 115 patients with MRKH syndrome, 27.8% showed accompanying renal or ureteral malformation, the majority of them (18%) showing unilateral renal agenesis. Furthermore, they found that in cases with uterine remnants, the single kidney was located ipsilateral to them.<sup>30</sup> Similar findings in a larger cohort of MRKH patients were reported: approximately 30% of patients had renal malformations, and the majority of them had renal agenesis.<sup>25</sup>

Likewise, Heinonen reported unilateral agenesis in 38% of cases with unicornuate uterus which was always ipsilateral to the rudimentary horn.<sup>20</sup> Other less frequent urinary tract anomalies were reported, including pelvic kidneys, horseshoe kidney, renal malrotation, multicystic dysplastic kidney, and lower ureteric remnants, which are most commonly seen together with renal agenesis and mostly inserting ectopically into the vagina.<sup>25,30,35</sup>

The present findings were compatible with these reports, although urinary tract imaging was only available for 27 patients. Urinary tract anomalies were present in 37% of cases, with unilateral renal agenesis being the most common renal anomaly (80%), which was seen in association with almost all types of mullerian anomalies. A few other urinary anomalies were also found amongst our patients ([Supplementary Table 2](#)).

Few coincident anomalies were diagnosed. Cloaca was diagnosed in two cases, and urogenital sinus anomaly was found in another two cases. Two syndromes were encountered: Fraser syndrome in a case of septate uterus and Wolfram syndrome in a patient with an infantile uterus. Other isolated anomalies were also encountered. Endometrial cancer was diagnosed in a case with unicornuate uterus, arising within the dominant horn. The literature contained very few case reports describing the association of mullerian anomalies with non-renal anomalies, skeletal and cardiac malformations.<sup>36,37</sup>

Seven cases of mullerian anomalies were “not described” in the new ASRM system. Nevertheless, we found it much more reliable for the radiology practice because it is an advanced modification of the known widely used AFS system using clear descriptions and iconic representations that can mirror the MR images, making for rapid, easy, and confident diagnosis of the anomaly. This is contrary to the ESHRE system that used new terms like bicorporeal, used new measurement methods regarding myometrial thickness, and depended on symbolic classification making it not user-friendly in our radiology practice.

Few limitations are encountered in this study. One limitation is the retrospective nature of the study, which, having selected already diagnosed patients, could introduce selection bias. This may impact the prevalence rates and render prevalence comparisons with prospective studies unreliable. Another possible limitation is the small sample size, which results in a small number of available cases for each abnormality. Therefore, the performance of the classification systems on these limited cases is not necessarily representative of its the performance in general, as the sample used

might have been easier or harder to diagnose than average. Furthermore, since the ease of use and practicality of each system was based on the opinion and experience of the examiners, it is not necessarily applicable to all examiners.

## Conclusions

Variable müllerian anomalies are present that can be complex and are frequently accompanied by urinary tract anomalies, and, in a minority, other non-urinary malformations may exist. These can be adequately and successfully delineated by MRI and subsequently classified according to the available systems.

The new ASRM classification system appears very functional and truly represents a robust modification of the original AFS system and undoubtedly could replace it. However, it could not incorporate some of the cases presented in this study. On the other hand, the ESHRE classification system could categorize all our cases, including the cases with uterine hypoplasia (except for one, which could not be classified by the ASRM system either). Both systems evidently pointed out that complete classification of all müllerian anomalies would be impossible, and more variations will be encountered in the future.

Nevertheless, we found the new ASRM classification more practical as it appears simpler and more user-friendly as it uses drawings with clear descriptions rather than symbols, yielding a view of the whole anomaly at a glance. This is, without hesitation, very useful in the radiological era, allowing us to equate the MRI images of the patient with the provided anomaly drawing, saving time and effort at the time of reporting.

## Data Sharing Statement

Data are available via e-mail request from the corresponding author.

## Disclosure

Authors have no conflict of interest.

## References

1. Chan YY, Jayaprakasan K, Zamora J, Thornton JG, Raine-Fenning N, Coomarasamy A. The prevalence of congenital uterine anomalies in unselected and high-risk populations: a systematic review. *Hum Reprod Update*. 2011;17(6):761–771. doi:10.1093/humupd/dmr028
2. Marcal L, Nothaft MA, Coelho F, Volpato R, Iyer R. Müllerian duct anomalies: MR imaging. *Abdom Imaging*. 2011;36(6):756–764. doi:10.1007/s00261-010-9681-x
3. Adhesions AD. The American Fertility Society classifications of adnexal adhesions, distal tubal occlusion, tubal occlusion secondary to tubal ligation, tubal pregnancies, müllerian anomalies and intrauterine adhesions. *Fertil Steril*. 1988;49(6):944–955. doi:10.1016/S0015-0282(16)59942-7
4. Buttram VC Jr., Gibbons WE. Müllerian anomalies: a proposed classification. (An analysis of 144 cases). *Fertil Steril*. 1979;32(1):40–46. doi:10.1016/S0015-0282(16)44114-2
5. Grimbizis GF, Gordts S, Di Spiezio Sardo A, et al. The ESHRE/ESGE consensus on the classification of female genital tract congenital anomalies. *Hum Reprod*. 2013;28(8):2032–2044. doi:10.1093/humrep/det098
6. Ludwin A, Ludwin I. Comparison of the ESHRE-ESGE and ASRM classifications of Müllerian duct anomalies in everyday practice. *Hum Reprod*. 2015;30(3):569–580. doi:10.1093/humrep/deu344
7. Pfeifer SM, Attaran M, Goldstein J, et al. ASRM müllerian anomalies classification 2021. *Fertil Steril*. 2021;116(5):1238–1252. doi:10.1016/j.fertnstert.2021.09.025
8. Robbins JB, Broadwell C, Chow LC, Parry JP, Sadowski EA. Müllerian duct anomalies: embryological development, classification, and MRI assessment. *J Magn Reson Imaging*. 2015;41(1):1–12. doi:10.1002/jmri.24771
9. Pfeifer S, Butts S, Dumesic D. Uterine septum: a guideline. *Fertil Steril*. 2016;106(3):530–540. doi:10.1016/j.fertnstert.2016.05.014
10. Olpin JD, Moeni A, Willmore RJ, Heilbrun ME. MR imaging of Müllerian fusion anomalies. *Magn Reson Imaging Clin N Am*. 2017;25(3):563–575. doi:10.1016/j.mric.2017.03.008
11. Al-Najar MS, Saleem MM, Alassaf AA, et al. Congenital adrenal hyperplasia and ohvira syndrome: first report of unique combination in a child. *AAACE Clin Case Rep*. 2015;1(2):e136–40. doi:10.4158/EP14524.CR
12. Deutch TD, Abuhamad AZ. The role of 3-dimensional ultrasonography and magnetic resonance imaging in the diagnosis of müllerian duct anomalies: a review of the literature. *J Ultrasound Med*. 2008;27(3):413–423. doi:10.7863/jum.2008.27.3.413
13. Church DG, Vancil JM, Vasanawala SS. Magnetic resonance imaging for uterine and vaginal anomalies. *Curr Opin Obstet Gynecol*. 2009;21(5):379–389. doi:10.1097/GCO.0b013e3283307c3e
14. Mueller GC, Hussain HK, Smith YR, et al. Müllerian duct anomalies: comparison of MRI diagnosis and clinical diagnosis. *AJR Am J Roentgenol*. 2007;189(6):1294–1302. doi:10.2214/AJR.07.2494
15. Grimbizis GF, Campo MDR. Congenital malformations of the female genital tract: the need for a new classification system. *Fertil Steril*. 2010;94(2):401–407. doi:10.1016/j.fertnstert.2010.02.030

16. Sardo DS, Campo AR, Gordts S, et al. The comprehensiveness of the ESHRE/ESGE classification of female genital tract congenital anomalies: a systematic review of cases not classified by the AFS system. *Hum Reprod.* 2015;30(5):1046–1058. doi:10.1093/humrep/dev061
17. Grimbizis GF, Campo R. Clinical approach for the classification of congenital uterine malformations. *Gynecol Surg.* 2012;9(2):119–129. doi:10.1007/s10397-011-0724-2
18. Troiano RN, McCarthy SM. Mullerian duct anomalies: imaging and clinical issues. *Radiology.* 2004;233(1):19–34. doi:10.1148/radiol.2331020777
19. Troiano RN. Magnetic resonance imaging of mullerian duct anomalies of the uterus. *Top Magn Reson Imaging.* 2003;14(4):269–279. doi:10.1097/0002142-200308000-00002
20. Heinonen PK. Unicornuate uterus and rudimentary horn. *Fertil Steril.* 1997;68(2):224–230. doi:10.1016/S0015-0282(97)81506-3
21. Carrington BM, Hricak H, Nuruddin RN, Secaf E, Laros RK Jr., Hill EC. Müllerian duct anomalies: MR imaging evaluation. *Radiology.* 1990;176(3):715–720. doi:10.1148/radiology.176.3.2202012
22. Acien P. Incidence of Müllerian defects in fertile and infertile women. *Hum Reprod.* 1997;12(7):1372–1376. doi:10.1093/oxfordjournals.humrep.a019588
23. Wang Y, Lu J, Zhu L, et al. Evaluation of Mayer-Rokitansky-Küster-Hauser syndrome with magnetic resonance imaging: three patterns of uterine remnants and related anatomical features and clinical settings. *Eur Radiol.* 2017;27(12):5215–5224. doi:10.1007/s00330-017-4919-4
24. Pan HX, Luo GN. Phenotypic and clinical aspects of Mayer-Rokitansky-Küster-Hauser syndrome in a Chinese population: an analysis of 594 patients. *Fertil Steril.* 2016;106(5):1190–1194. doi:10.1016/j.fertnstert.2016.06.007
25. Oppelt PG, Lermann J, Strick R, et al. Malformations in a cohort of 284 women with Mayer-Rokitansky-Küster-Hauser syndrome (MRKH). *Reprod Biol Endocrinol.* 2012;10(1):57. doi:10.1186/1477-7827-10-57
26. Saxena AK, Elizabeth Paton RA. Vaginal Atresia; 2021. Available from: <https://emedicine.medscape.com/article/954110-overview>. Accessed October 27, 2022.
27. Angotti R, Molinaro F, Bulotta AL, et al. Isolated vaginal agenesis associated with multiple gastrointestinal anomalies: a case report. *J Neonatal Surg.* 2016;5(3):32. doi:10.21699/jns.v5i3.326
28. Rathod S, Dash B, Mahapatra PC, Nayak AK. Vaginal atresia in a case of Fraser syndrome. *J Obstet Gynaecol India.* 2014;64(Suppl 1):95–99. doi:10.1007/s13224-012-0331-9
29. Allen JW, Cardall S, Kittijarukhajorn M, Siegel CL. Incidence of ovarian maldescent in women with mullerian duct anomalies: evaluation by MRI. *AJR Am J Roentgenol.* 2012;198(4):W381–385. doi:10.2214/AJR.11.6595
30. Preibsch H, Rall K, Wietek BM, et al. Clinical value of magnetic resonance imaging in patients with Mayer-Rokitansky-Küster-Hauser (MRKH) syndrome: diagnosis of associated malformations, uterine rudiments and intrauterine endometrium. *Eur Radiol.* 2014;24(7):1621–1627. doi:10.1007/s00330-014-3156-3
31. Wang Y, Lu J, Zhu L, et al. Increased incidence of abnormally located ovary in patients with Mayer-Rokitansky-Küster-Hauser syndrome: a retrospective analysis with magnetic resonance imaging. *Abdom Radiol.* 2018;43(11):3142–3146. doi:10.1007/s00261-018-1575-3
32. Fedele L, Bianchi S, Di Nola G, Franchi D, Candiani GB. Endometriosis and nonobstructive müllerian anomalies. *Obstet Gynecol.* 1992;79(4):515–517.
33. Uğur M, Turan C, Mungan T, et al. Endometriosis in association with müllerian anomalies. *Gynecol Obstet Invest.* 1995;40(4):261–264. doi:10.1159/000292349
34. Nawroth F, Rahimi G, Nawroth C, Foth D, Ludwig M, Schmidt T. Is there an association between septate uterus and endometriosis? *Hum Reprod.* 2006;21(2):542–544. doi:10.1093/humrep/dei344
35. Hall-Craggs MA, Kirkham A, Creighton SM. Renal and urological abnormalities occurring with Mullerian anomalies. *J Pediatr Urol.* 2013;9(1):27–32. doi:10.1016/j.jpuro.2011.11.003
36. Goryaeva M, Sykes MC, Lau B, West S. Unusual association between cardiac, skeletal, urogenital and renal abnormalities. *BMJ Case Rep.* 2016;2016:32.
37. Kumar S, Sharma S. MURCS (Müllerian duct aplasia-renal agenesis-cervicothoracic somite dysplasia): a rare cause of primary amenorrhoea. *Oxf Med Case Rep.* 2016;2016(4):73–75. doi:10.1093/omcr/omw022

## Publish your work in this journal

The Journal of Multidisciplinary Healthcare is an international, peer-reviewed open-access journal that aims to represent and publish research in healthcare areas delivered by practitioners of different disciplines. This includes studies and reviews conducted by multidisciplinary teams as well as research which evaluates the results or conduct of such teams or healthcare processes in general. The journal covers a very wide range of areas and welcomes submissions from practitioners at all levels, from all over the world. The manuscript management system is completely online and includes a very quick and fair peer-review system. Visit <http://www.dovepress.com/testimonials.php> to read real quotes from published authors.

Submit your manuscript here: <https://www.dovepress.com/journal-of-inflammation-research-journal>