



Macular edema in Cogan-Reese syndrome

Hugo Bouvarel^{a,*}, Pascale Hamard^b, Emilie Agard^a, Jérémy Billant^a, Hussam El Chehab^a, Corinne Dot^a

^a Hôpital d'Instruction des Armées Desgenettes, 108 Boulevard Pinel, 69003, Lyon, France

^b Centre Hospitalier National d'Ophthalmologie des Quinze-Vingts, 28 Rue de Charenton, 75012, Paris, France

ARTICLE INFO

Keywords:

Iridocorneal endothelial syndrome
Glaucoma
Macular edema
Case report

ABSTRACT

Purpose: Iridocorneo-endothelial (ICE) syndrome is known as a rare spectrum causing glaucoma, corneal and iris damages. Retinal complications are uncommon.

Observations: We report the case of a middle-aged woman suffering from a Cogan-Reese Syndrome (CRS) with refractory ocular hypertension (OHT) who presented a cystoid macular edema (CME) during follow up.

Conclusions and Importance: We suspect the CME to be inflammatory linked to the pathophysiological hypotheses of the CRS. The CME was successfully treated with topical nonsteroidal anti-inflammatory drugs (NSAID). No consensus is available on its duration. A recurrence happened when treatment was stopped, its reintroduction was successful.

1. Introduction

Cogan-Reese syndrome (CRS) is one of the three subtypes of iridocorneo-endothelial (ICE) syndrome with Chandler syndrome and essential iris atrophy. It was initially described in 1969.¹ ICE syndrome is a rare unilateral diagnostic usually observed in middle-aged woman. As the acronym suggests, it involves three ocular tissues (the corneal endothelium, the iridocorneal angle and the iris) but in different ways according to its subtype. Sick endothelial cells acting like epithelial cells² proliferate in a collagenous membrane to the iridocorneal angle.³

In Cogan-Reese syndrome, the iridocorneal angle is predominantly affected. This diagnosis is highly suspected when small round pigmented peduncles are observed on the anterior iris surface associated with ocular hypertension (OHT).⁴ OHT is often refractory to medical medications and requires therapeutic escalation.

Macular edema is not common in this syndrome. To our knowledge, only three cases have been reported in literature, occurring during ICE syndrome. We report the case of a treated macular edema, occurring four years after the CRS diagnosis.

2. Case report

A 39 years old woman with no medical history was referred because of blurred vision in her right eye (RE) which started a few weeks ago. At

baseline, best corrected visual acuity was 20/32 and 20/20 respectively in RE and left eye (LE). Intra-ocular pressure was 52 mmHg in the RE and 13 mmHg in the LE. Slit lamp examination of the RE showed conjunctival hyperemia, mild stromal edema, deep and quiet anterior chamber and clear lens. The most significant observation was peripheral iris lesions localized in the temporal inferior iris quadrant and iridocorneal angle during gonioscopy (Fig. 1a & b). The fundus examination reported an asymmetrical cup/disc ratio (0.8 RE/0.2 LE). UBM ultrasound did not show any sign of iris or ciliary mass. Left eye examination was normal. Specular microscopy helped to diagnose the CRS revealing clear nuclei surrounded by dark cytoplasm combined with low endothelial cellular density around 763 cells/mm².

Maximum hypotensive therapy with combination of topical dorzolamide, timolol, apraclonidine and general acetazolamide and mannitol allowed intraocular pressure management in emergency. The follow up was remarkable by a refractory OHT which required surgical procedures: trabeculectomy, then Ahmed tube (Fig. 1c) and finally micropulse transscleral diode laser photocoagulation which allowed oral acetazolamide to be stopped 6 months later.

Cystoid macular edema (CME) was diagnosed 13 months after the latest procedure and 3 months after stopping acetazolamide (Fig. 2a). Topical dorzolamide and timolol were left. No intraocular inflammatory sign was observed. Visual acuity was unchanged decreasing progressively since the CRS diagnosis according to the visual field defects. OCT

* Corresponding author.

E-mail addresses: hugo.bouvarel@chu-lyon.fr (H. Bouvarel), pascale-hamard@quinze-vingts.fr (P. Hamard), emilie.agard@intradef.gouv.fr (E. Agard), jeremy.billant@intradef.gouv.fr (J. Billant), hussam.el-chehab@intradef.gouv.fr (H. El Chehab), corinnedot.pro@hotmail.fr (C. Dot).

<https://doi.org/10.1016/j.ajoc.2022.101318>

Received 14 December 2020; Received in revised form 19 June 2021; Accepted 20 January 2022

Available online 26 January 2022

2451-9936/© 2022 The Authors.

Published by Elsevier Inc.

This is an open access article under the CC BY-NC-ND license

(<http://creativecommons.org/licenses/by-nc-nd/4.0/>).

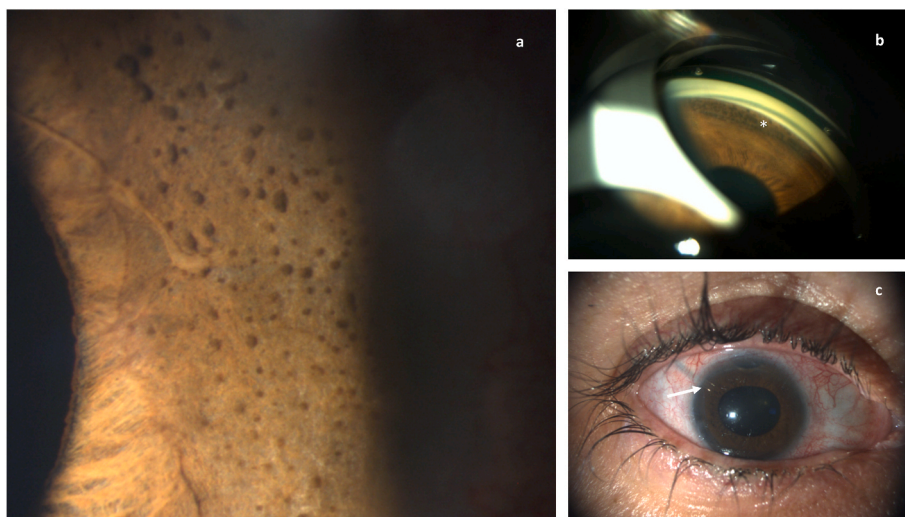


Fig. 1. a: slit lamp exam photo of the multiple small round pigmented irregular iris lesions. b: gonioscopic exam showing the same lesions (*) in the iridocorneal angle in the infero-temporal quadrant. c: anterior segment picture after the tube surgery, the arrow shows the tube in the supero-temporal position).

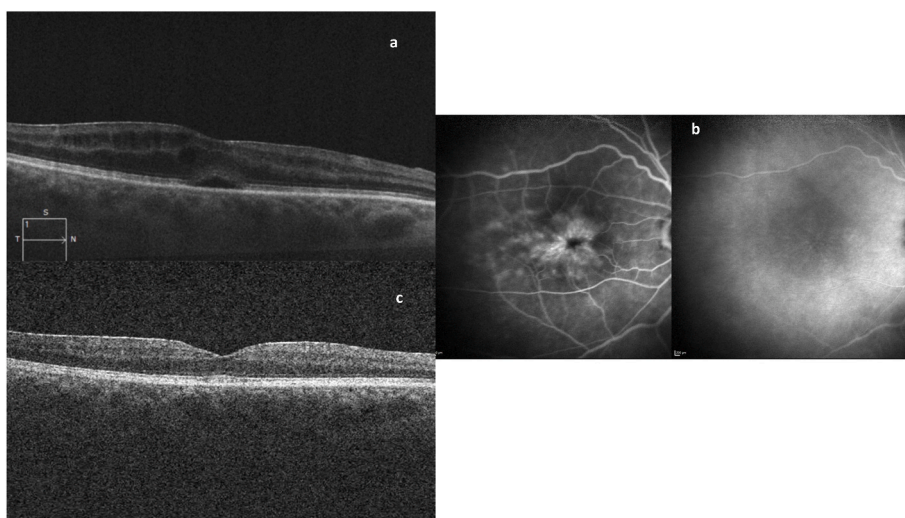


Fig. 2. a: macular OCT, B-scan showing intraretinal cysts with a slight subfoveal fluid. b: fluorescein (left) and indocyanine (right) medium time showing unspecific diffuse macular fluorescein leakage with petaloid pooling, no indocyanine anomaly. c: macular OCT, B-scan presenting a normal foveal profile after 3 months of flurbiprofen treatment./

showed intraretinal cyst with discreet subfoveal fluid.

Fluorescein angiography showed unspecific diffuse macular leakage with petaloid pooling but without any papillary leakage, indocyanine angiography was unremarkable (Fig. 2b). Topical flurbiprofen therapy three times a day was started for 3 months.

The OCT showed a complete edema resolution from the first month with a lasting effect over the 3 months of treatment. After stopping flurbiprofen, we observed a recurrence of ME a month later. Reintroduction test treatment was successful.

3. Discussion

Refractory OHT is well described in CRS with multiple surgeries often needed.⁵ OHT recurrence is explained by the cells' collagenous basal membrane extension sealing the drainage orifice.⁶

Macula edema is not a common complication of CRS. Several differential diagnosis can be suspected as following. Microcystic degenerative macular lesions, as seen in advanced glaucomatous optic neuropathies, are usually localized in the intern nuclear layer and do not

induce fluorescein leakage. The absence of choroid hyperpermeability and thick choroid does not comfort a pachychoroid spectrum exudation cause. OCT and angiography descriptions are not in favor of a choroidal neovascularization either. Although a discreet epiretinal membrane can be noticed on the OCT, the positive edema evolution does not support tractional process. Irvine Gass Syndrome must be discussed and cannot be ruled out, even if the normal status of the macula was checked after transscleral diode cyclophotocoagulation. Acetazolamide prescribed as hypotensive treatment several months after surgery, may have disturbed its diagnosis, as we know this molecule can stimulate retinal pigmented epithelium fluid absorption too. The chronology of CME appearance (3 months after stopping acetazolamide) remains doubtful.

Interestingly, Fourmaux et al. described in 2005 the acetazolamide resistance of a CME associated with an essential iris atrophy, before disappearing after a triamcinolone subtenonian injection.⁷

Kocaoglan et al. reported a CME in a Chandler syndrome successfully treated with topical prednisolone and ketorolac.⁸ The latest description in 2016 by Suzuki et al. in a CRS, reported the effectiveness of topical nepafenac.⁹

The authors suggested that the proliferation of abnormal endothelial cells may be disrupting the inner blood-retinal barrier and inflammatory derivatives such as prostaglandin may be produced by pathological endothelial cells. They also hypothesize that the infectious pathway (herpes often suspected in ICE syndrome as *primum movens*) may be another source of pro-inflammatory cytokines production.¹⁰

Nonsteroidal anti-inflammatory drug (NSAID) efficacy reports are in keeping with an inflammatory process, in addition to the successful reintroduction therapeutic test in our case (not previously described).

4. Conclusions

Poor visual prognosis in ICE syndrome rest upon the corneal and papillary damages. According to literature and our case, a chronic macular edema may appear during the follow up and remains certainly underestimated. Macular status should be screened in such cases beyond OHT management.

Our case highlights a quick efficacy of flurbiprofen, nevertheless no consensus is available concerning the treatment duration. NSAID were preferred to steroids as the CRS evolution is often threatened by OHT recurrences.

Further investigations are needed to strengthen these descriptive hypotheses.

Patient consent

Written consent to publish personal information and case details has been obtained from the patient.

Funding

No funding or grant support.

Authorship

All authors attest that they meet the current ICMJE criteria for

Authorship.

Declaration of competing interest

The authors declare that they have no known competing financial interests or personal relationships that could have appeared to influence the work reported in this paper.

The following authors have no financial disclosures: BH, HP, AE, ECH, DC.

Acknowledgements

None.

References

1. Cogan DG, Reese AB. A syndrome of iris nodules, ectopic Descemet's membrane, and unilateral glaucoma. *Doc Ophthalmol Adv Ophthalmol*. 1969;26:424–433.
2. Sherrard ES, Frangoulis MA, Muir MG. On the morphology of cells of posterior cornea in the iridocorneal endothelial syndrome. *Cornea. mai*. 1991;10(3):233–243.
3. Robert AM, Renard G, Robert L, Bourges J-L. Le syndrome irido-cornéo-endothélial ou la perte du contrôle du cycle cellulaire de l'endothélium cornéen. *Une revue. Pathol Biol. avr*. 2013;61(2):75–82.
4. Silva L, Najafi A, Suwan Y, Teekhasaene C, Ritch R. The iridocorneal endothelial syndrome. *Surv Ophthalmol. sept*. 2018;63(5):665–676.
5. Sacchetti M, Mantelli F, Marengo M, Macchi I, Ambrosio O, Rama P. Diagnosis and management of iridocorneal endothelial syndrome. *BioMed Res Int*. 2015;2015:1–9.
6. Doe EA, Budenz DL, Gedde SJ, Imami NR. *Long-term Surgical Outcomes of Patients with Glaucoma Secondary to the Iridocorneal Endothelial Syndrome*. vol. 108. 2001:7, 10.
7. Fourmaux E, Velasque L. Atrophie essentielle de l'iris associée à un œdème maculaire cystoïde chronique. *J Fr Ophtalmol. avr*. 2005;28(4):407–410.
8. Kocaoglan H, Unlü N, Kanpolat A, Yalvaç IS, Acar MA, Duman S. Macular edema and iridocorneal endothelial syndrome: a case report. *Cornea. mars*. 2005;24(2):221–223.
9. Suzuki K, Mizuguchi T, Seno Y, Tanikawa A, Horiguchi M. Cystoid macular edema associated with iridocorneal endothelial syndrome: a case report. *BMC Ophthalmol. déc*. 2016;16(1):155.
10. Li F, Liu Y, Sun Y, Zhang X. Etiological mechanism of iridocorneal endothelial (ICE) syndrome may involve infection of herpes simplex virus (HSV) and integration of viral genes into human genome. *Med Hypotheses. janv*. 2018;110:50–52.