

Bone impregnated hip screw in femoral neck fracture

Clinicoradiological results

PK Sundar Raj^{1,2}, Jiju A Nuuman³, Amish Sunder Pattathil²

ABSTRACT

Background: Femoral neck fractures are treated either by internal fixation or arthroplasty. Usually, cannulated cancellous screws are used for osteosynthesis of fracture neck of femur. The bone impregnated hip screw (BIHS) is an alternative implant, where osteosynthesis is required in femoral neck fracture.

Materials and Methods: The BIHS is a hollow screw with thread diameter 8.3 mm, shank diameter 6.5 mm and wall thickness 2.2 mm and holes in the shaft of the screw with diameter 2 mm, placed in a staggered fashion. Biomechanical and animal experimental studies were done. Clinical study was done in two phases: Phase 1 in a group of volunteers, only with BIHS was used in a pilot study and phase 2 comparative study was done in a group with AO cannulated screws and the other group treated with BIHS.

Results: In the phase 1 study, out of 15 patients, only one patient had delayed union. In phase 2, there were 78 patients, 44 patients in BIHS showed early union, compared to the rest 34 cases of AO cannulated screws. Out of 44 patients with BIHS, 41 patients had an excellent outcome, 2 had nonunions and one implant breakage was noted.

Conclusions: Bone impregnated hip screw has shown to provide early solid union since it incorporates the biomechanical principles and also increases the osteogenic potential and hence, found superior to conventional cannulated cancellous screw.

Key words: Bone impregnated hip screw, osteogenic, femoral neck fracture, cannulated cancellous screws

MeSH terms: Femoral neck fractures, bone screws, grafting, bone

INTRODUCTION

Femoral neck fractures are treated traditionally by internal fixation or arthroplasty. The goal of treatment is to restore the anatomical reduction, stable fixation and unions as to achieve stability of the lower limb later to bear weight on it. Usually, cannulated screws^{1,2} are used for fixation of fracture neck of femur. Controversy still exists in the mode of treatment of fracture neck of femur in the “young old” age (age between 55 and 65). In a meta-analysis, it was found that there exists no statistical difference in the method of treatment employed, either internal fixation or arthroplasty. In treating femoral

neck fracture, cannulated cancellous screws are the gold standard, ideally using three screws. Some surgeons replace one of the screws with fibular strut graft^{3,4} to stimulate bone growth. Present understanding of biomechanical principles employ three screws, each assigned a particular area of the neck of femur, and this assumes an inverted triangular configuration.^{5,6} Since each of the screws have a particular function to perform, if one of the screws is replaced by fibular strut graft, the function assigned to that particular screw will be lost and the construct becomes unstable and the fracture tends to displace laterally leading to delayed union and avascular necrosis.^{7,8}

This study uses an implant, bone impregnated hip screw (BIHS), which combines the biomechanical properties of the standard cancellous screws and as well as providing provision for placing cancellous bone grafts within the body of the screw. The BIHS is an alternative implant. In this retrospective study, we present the clinical and radiological results of femoral neck fracture managed with BIHS.

MATERIALS AND METHODS

Bone impregnated hip screw

Similar to the conventional hip screws it has a structure that retains the biomechanical stability, but also provides provision for osteogenic potential. The BIHS has a thread

¹Department of Orthopedics, Government Medical College, Thiruvananthapuram, ²Department of Orthopedics, Azeezia Medical College, Kollam, ³Department of Orthopedics, Government Taluk Headquarter’s Hospital, Chirayinkeezhu, Thiruvananthapuram, Kerala, India

Address for correspondence: Dr. Amish Sunder Pattathil, Department of Orthopedics, Azeezia Medical College, Kollam, Kerala, India. E-mail: dramishsunder@gmail.com

Access this article online	
Quick Response Code:	Website: www.ijoonline.com
	DOI: 10.4103/0019-5413.152472

diameter of 8.3 mm, shank diameter of 6.5 mm and wall thickness of 2.2 mm. The screw has provision for filling it with cancellous graft. Holes of diameter 2 mm are placed in a staggered fashion in the shaft [Figures 1 and 2].

Biomechanics

The yield strength was calculated using the Amsler universal testing machine. (Jayon Implants Private Limited, Palakkad, Kerala, India). The holes in the screw allow blood vessels from the surroundings to permeate into the graft. We found during the course of biomechanical analysis that if the holes are 2 mm in diameter and placed in a staggered way the yield strength is higher when compared to holes more than 2 mm and placed in a linear arrangement [Table 1].

The inclusion criteria were unstable femoral neck fractures Gardens type III and type IV cases treated with BIHS screw. The exclusion criteria were obese patients and old age patients (>60 years), were excluded from the study.

Phase 1 pilot study

Phase 1 clinical trial was done in 15 patients. All 15 patients volunteered themselves for the procedure and the complications were explained in detail to them. Study was done after getting a detailed “special informed consent” and “Ethical Committee Clearance.”

Operative procedure

Under C-arm, the fracture was reduced and the limb secured on an operating fracture table. The reduction achieved was checked under image intensifier so that near normal anatomical reduction according to Garden’s index was achieved, both in AP and lateral views. Three guide wires were passed as per the standard biomechanical



Figure 1: Bone impregnated hip screw showing staggered holes

principles^{5,7} [Figure 3]. The first screw should rest along the inferior cortex in the anteroposterior projection and in centre on the lateral projection. This position will optimally resist inferior displacement and varus collapse while the femoral head is loaded in a standing position. The second screw is placed parallel to the first close to the posterior cortex and central on the anteroposterior image. This pin will resist posterior displacement and anterior angulation while the patient is rising from a seated position. The final screw should be placed anteriorly on the lateral view and central on the anteroposterior view. A fully superior position is avoided due to the concern over damage to the lateral epiphyseal artery branches entering the superior neck.^{5,7,9,10} Cannulated drill bit and cannulated tap used thereafter and 6.5 mm cancellous screw were inserted, again the position verified and also the exact length of screws were determined. The exact size “BIHS” corresponding to the cannulated screws was selected and filled fully with autogenous cancellous bone [Figure 4]. The guide wires were removed as there was already a well prepared tract. The BIHS screw was tightened after incorporating the washer and tightening with 4.5 mm cap screws as in a DHS. The whole construct checked entirely again by AP, Lateral and oblique projections as per need.

Postoperatively, the patient was given modified external rotation stop using a “wooden scale” fixed to a canvas shoe which the patient was advised to wear for 1-month. Static quadriceps and hamstring exercise started early and as soon



Figure 2: Bone impregnated hip screw cross section showing bone graft and staggered holes

Table 1: Yield strength

Screw	Outer diameter (mm)	Inner diameter (mm)	Hole diameter (mm)	Area (mm ²)	Load bearing capacity (kg)	Yield strength N/mm ²
DHS	7.2	3.17	-	32.82	2200	657.6
6.5 mm cancellous screw	4.55	1.85	-	13.57	650	469.9
BIHS 2 mm hole	6.32	3.75	2	8.1	450	545
BIHS 3 mm hole	6.91	3.63	3	18.70	350	183.5

DHS=Dynamic hip screw, BIHS=Bone impregnated hip screw

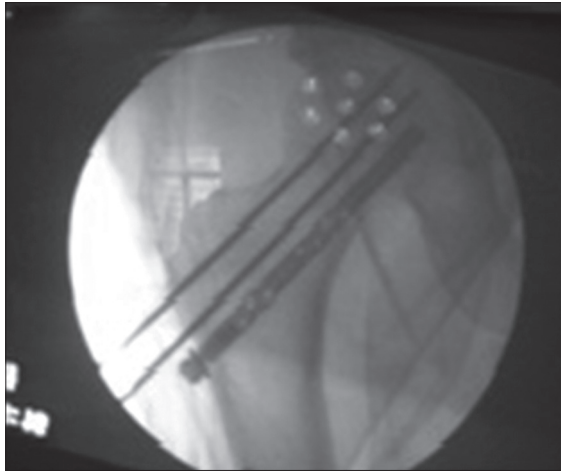


Figure 3: Peroperative fluoroscopy view of fracture neck femur showing guide wires and one screw *in situ*

as sutures were removed. Gentle knee flexion exercises were started after the tenth postoperative day. Active assisted range of motions of the hip started at 3 weeks. Partial weight bearing started at 12 weeks after visualizing early signs of union. Of the 15 patients, only one patient had nonunion which required hemiarthroplasty. The distal limb of the Moore's approach incision was extended to the previous operation scar and the screws removed without encountering difficulty. Encouraged by these results, phase 2 trial was initiated.

Phase 2 comparative clinical study

The phase 2 clinical comparative study between cancellous screw group and BIHS group was done between 2002 and 2011. Out of 78 patients, 44 patients were treated with BIHS and the rest with cancellous screws. Early union was noticed in the BIHS patients [Figure 5] [Table 2].

The BIHS and cancellous groups differ significantly in the union rate ($P < 0.05$). BIHS group reported significantly early union (mean = 12.77 weeks, standard deviation [SD] = 2.42 weeks) as compared to cancellous group (mean = 16 weeks, SD = 4.385 weeks).

RESULTS

The results were assessed with radiological analysis and Harris hip score. Functional outcome was assessed using Harris hip score on qualitative parameters of pain (in the distance walked), limp, activities, stair climbing, public transportation, sitting, and quantitative assay of hip movements. According to Harris hip score, questionnaire was given to the patients initially for qualitative analysis. Quantitative analysis of limb length discrepancy and range of movements assessed. The final outcome was graded as poor, fair, good and excellent.



Figure 4: Clinical photograph of bone impregnated (graft) hip screw

Table 2: Comparison of groups (*t* test) based on rate of union

Group	n	Mean	SD	t	df	P
BIHS	44	12.77	2.42	2.095	21	0.048*
Cancellous	34	16.00	4.85			

*Significant at 5% level ($P < 0.05$). SD=Standard deviation, BIHS=Bone impregnated hip screw

Out of 44 patients with BIHS, 41 patients had an excellent outcome, 2 nonunions and one implant breakage. Radiologically, good union was noted in 41 patients. One patient had poor Harris hip score⁹ (< 70) with 0° flexion and external rotation of 5°–10°. 2 cases had a fair score of with flexion of 25°, external rotation of 10°, abduction and adduction of 10°. 39 cases had an excellent score with a good range of all movements [Table 3].

All 41 patients were able to squat, sit on the floor and do all the works. Radiographically, good union was noted in 26 cases within 16 weeks. 10 cases had union within 12 weeks, 4 had union within 10 weeks and 2 had union after 16 weeks. 2 nonunion cases were noted [Table 4]. Comparing the results with cases treated with AO cancellous screw showed nonunion for 5 cases in cancellous screw group and 2 nonunions in BIHS group. Rate of union was more in the BIHS group with lesser time. Implant breakage was noted in one patient. The patient started weight bearing early and started to climb “coconut tree” and the screw was broken [Figure 6].

The BIHS and cancellous group differ significantly in the union rate ($P < 0.05$). BIHS group reported significantly early union (mean = 12.77 weeks, SD = 2.42 weeks) as compared to cancellous group (mean = 16 weeks, SD = 4.385 weeks). The variables flexion, external rotation, abduction and adduction do not differ significantly between BIHS and cancellous groups ($P > 0.05$) [Table 5].

In the BIHS groups, majority (90.3%) belonged to excellent flexion level, but in cancellous groups only 55.20% showed excellent flexion level.

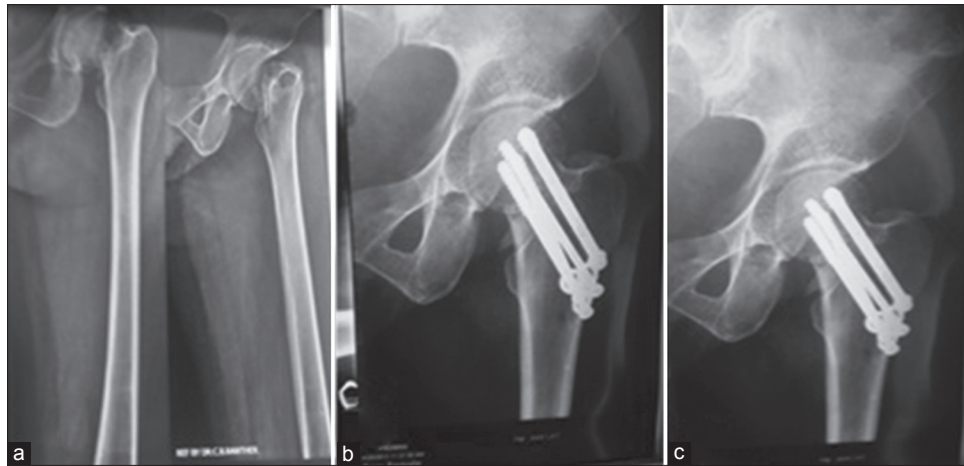


Figure 5: X-ray left hip joint anteroposterior views (BIHS group) showing (a) Preoperative X-rays. (b) immediate postoperative X-ray with bone impregnated hip screw *in situ* (c) Followup at 3 months, good union seen

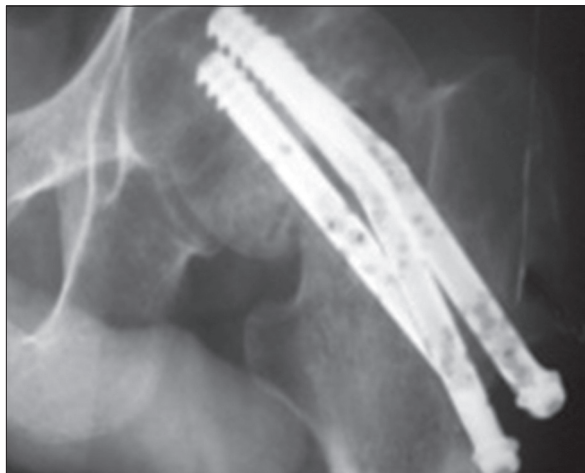

Figure 6: X-ray left hip joint anteroposterior view treated with BIHS showing implant breakage in the phase 2 series

Comparing the results with cases treated with AO cancellous screw, 5 cases of nonunion were reported in cancellous screw group and 2 were noted in BIHS group. Rate of union was more in the BIHS group with lesser time. Statistical analysis clearly showed rate of union was more in the BIHS group.

DISCUSSION

Cannulated cancellous screws remained the gold standard for fixation of femoral neck fracture over the years. The best results are obtained with perfect anatomical reduction,¹¹ possibly due to the fact that during anatomical reduction, the blood vessels¹² which were kinked will regain their entire lumen. A sound knowledge of anatomy and biomechanical principles are essential for understanding the present concept in fixation of the fracture.¹²⁻¹⁸ The incidence of fracture neck of femur in between 50 and 70 years the productive group has increased in Indian population and

Table 3: Functional outcome

Haris hip score	Cancellous screw (n=34)	BIHS screw (n=44)
<70° (poor)	3	1
Fair	13	2
Excellent score	18	41
<30 fixed flexion	0	0
<10 fixed internal rotation in extension	1	1
<10 fixed adduction	0	0
Limb length discrepancy <3.2 cm	2	1

BIHS=Bone impregnated hip screw

Table 4: Comparison of groups (t test) based on Harris hip score rate in phase 2

Variable	Group	n	Mean	SD	t	df	P
Rate of union	BIHS	44	14.35	3.99	2.012	58	0.040*
	Cancellous	34	17.69	8.26			
Flexion	BIHS	44	88.06	22.39	1.438	58	0.150 ns
	Cancellous	34	79.66	22.91			
External rotation	BIHS	44	15.97	3.01	1.512	58	0.130 ns
	Cancellous	34	14.48	4.50			
Abduction	BIHS	44	12.90	2.51	1.084	58	0.280 ns
	Cancellous	34	12.07	3.41			
Adduction	BIHS	44	11.94	2.48	1.248	58	0.210 ns
	Cancellous	34	11.03	3.10			

*Significant at 5% level (P<0.05). ns=Not significant (P>0.05). BIHS=Bone impregnated hip screw, SD=Standard deviation

Table 5: Grading of harris hip scores based on flexion in BIHS and cancellous groups

Group	Flex-level	Poor	Fair	Excellent	Total
BIHS	Count	1	2	41	44
	%	3.20	6.50	90.30	100
Cancellous	Count	3	13	18	34
	%	10.30	34.50	55.20	100

BIHS=Bone impregnated hip screw

rest of the world. This population demand treatment with excellent functional outcome, so that they can do manual work, able to squat and climb stairs.¹⁹ The fracture neck of

femur classified²⁰ by Garden into four grades based on the fracture displacement^{18,19} and Gardens alignment index is to be maintained after reduction with alignment index of <150° and 180° in both views. Hemiarthroplasty and total arthroplasty²¹ can provide good functional outcome, with the risk of an unstable hip. BIHS provide a stable near anatomical hip with the freedom to be young and do all the manual work.

The various methods in treating femoral neck fracture includes internal fixation after reduction and use of muscle pedicle graft or fibular graft. Muscle pedicle graft harvested through the incision in the posterior capsule. The quadratus femoris²² is lifted out from the intertrochantric line along bone graft and inserted in to the femoral head. The graft is placed in the position in a tunnel created up under the articular surface of the femoral head. Graft to be fixed with 3.5 cancellous screw from posterior to anterior to compress and support the posterior cortex. Muscle pedicle graft does not provide stability at the fracture site. Various osteotomies²³⁻²⁶ are tried for femoral neck fracture and nonunions, but this alters the anatomy and challenges a subsequent prosthesis replacement.

It is a settled matter that if any of the screws are replaced by a fibular struct graft, the function attributed to that particular screw will be lost. The BIHS retains the fixation principle and also increases the osteogenic potential as the screw itself has cancellous bone. Further cancellous bone is the richest source of stem cells. Lot of research is taking place worldwide regarding efficacy of BMP. BIHS can hence also act as a vehicle of delivery of all bone forming tissue at the site of lesion. Hence, it can find a place in osteoporotic bone and also in impending fracture. The screw provides three-point fixation stability and osteogenic potential with cancellous graft filled in the cannulated part.

The BIHS were of 2 mm in diameter holes and placed in a staggered way. The cannulated part filled with cancellous graft. This structure of the screw resulted in a higher yield strength. The patient treated with BIHS reported significant early union compared to cancellous group. When assessed with Harris hip score, there was no much difference in flexion, external rotation, abduction, adduction in both the BIHS group and cancellous group. The rate of union was more in the BIHS group with lesser time. The BIHS group had Harris hip score of excellent score in majority 90% with good flexion movement range.

The comparative study showed an excellent result in the group treated with BIHS. This procedure requires no special equipment other than the instruments used for standard internal fixation. It is cost effective in Indian population.

Patients can undergo hemiarthroplasty or total arthroplasty with ease if this treatment modality fails. The limitations of the study are the small sample size and the wide variation in the ages of the patients.

Bone impregnated hip screw had shown to provide early solid union. It incorporates the biomechanical principle, increase the osteogenic potential and hence, found superior to conventional cannulated cancellous screw. Further, it will find a place as a vehicle of delivery for all the bone forming tissue. This implant is an innovation for the people who are "old," but do not accept to be old and are forced to work to earn for livelihood, or by their lifestyle, the desired term "young old."

REFERENCES


1. Bonnaire FA, Weber AT. Analysis of fracture gap changes, dynamic and static stability of different osteosynthetic procedures in the femoral neck. *Injury* 2002;33 Suppl 3:C24-32.
2. Stankewich CJ, Chapman J, Muthusamy R, Quaid G, Schemitsch E, Tencer AF, *et al.* Relationship of mechanical factors to the strength of proximal femur fractures fixed with cancellous screws. *J Orthop Trauma* 1996;10:248-57.
3. Meyers MH, Harvey JP Jr, Moore TM. The muscle pedicle bone graft in the treatment of displaced fractures of the femoral neck: Indications, operative technique, and results. *Orthop Clin North Am* 1974;5:779-92.
4. Beris AE, Payatakes AH, Kostopoulos VK, Korompilias AV, Mavrodontidis AN, Vekris MD, *et al.* Nonunion of femoral neck fractures with osteonecrosis of the femoral head: Treatment with combined free vascularized fibular grafting and subtrochanteric valgus osteotomy. *Orthop Clin North Am* 2004;35:335-43, ix.
5. Mullis BH, Johnson SD, Veillette C. Ortho One Assistan Surgical Management of Femoral Neck Fractures. *Orthopaedics One Articles*. In: *Orthopaedics One-the Orthopaedic Knowledge Network*. Created Jun 05, 2010 12:17. Last modified Aug 16, 2012 05:31 ver. 20. [Last retrieved on 2014 02-03].
6. Johnson KD, Brock G. A review of reduction and internal fixation of adult femoral neck fractures in a county hospital. *J Orthop Trauma* 1989;3:83-96.
7. Gerber C, Strehle J, Ganz R. The treatment of fractures of the femoral neck. *Clin Orthop Relat Res* 1993;77-86.
8. Dedrick DK, Mackenzie JR, Burney RE. Complications of femoral neck fracture in young adults. *J Trauma* 1986;26:932-7.
9. Bachiller FG, Caballer AP, Portal LF. Avascular necrosis of the femoral head after femoral neck fracture. *Clin Orthop Relat Res* 2002;87-109.
10. Trueta J, Harrison MH. The normal vascular anatomy of the femoral head in adult man. *J Bone Joint Surg Br* 1953;35-B: 442-61.
11. Garden RS. Malreduction and avascular necrosis in subcapital fractures of the femur. *J Bone Joint Surg Br* 1971;53:183-97
12. Swiontkowski MF, Tepic S, Rahn BA, Cordey J, Perren SM. The effect of fracture on femoral head blood flow. Osteonecrosis and revascularization studied in miniature swine. *Acta Orthop Scand* 1993;64:196-202.
13. Sevitt S. Avascular necrosis and revascularisation of the femoral head after intracapsular fractures; a combined

- arteriographic and histological necropsy study. *J Bone Joint Surg Br* 1964;46:270-96.
14. Arnoldi CC, Lemperg RK. Fracture of the femoral neck. II. Relative importance of primary vascular damage and surgical procedure for the development of necrosis of the femoral head. *Clin Orthop Relat Res* 1977;217-22.
 15. Arnoldi CC, Linderholm H. Fracture of the femoral neck. I. Vascular disturbances in different types of fractures, assessed by measurements of intraosseous pressures. *Clin Orthop Relat Res* 1972;84:116-27.
 16. Swiontkowski MF, Tepic S, Perren SM, Moor R, Ganz R, Rahn BA. Laser Doppler flowmetry for bone blood flow measurement: Correlation with microsphere estimates and evaluation of the effect of intracapsular pressure on femoral head blood flow. *J Orthop Res* 1986;4:362-71.
 17. Maruenda JI, Barrios C, Gomar-Sancho F. Intracapsular hip pressure after femoral neck fracture. *Clin Orthop Relat Res* 1997;172-80.
 18. Barnes R, Brown JT, Garden RS, Nicoll EA. Subcapital fractures of the femur. A prospective review. *J Bone Joint Surg Br* 1976;58:2-24.
 19. Zetterberg C, Elmerson S, Andersson GB. Epidemiology of hip fractures in Göteborg, Sweden, 1940-1983. *Clin Orthop Relat Res* 1984;43-52.
 20. Bartonicek J, Pauwels' classification of femoral neck fractures: Correct interpretation of the original. *J Orthop Trauma* 2001;15:358-60.
 21. Harris WH. Traumatic arthritis of the hip after dislocation and acetabular fractures: treatment by mold arthroplasty. An end-result study using a new method of result evaluation. *J Bone Joint Surg Am* 1969;51:737-55.
 22. Morwessel R, Everts CM. The use of quadratus femoris muscle pedicle bone graft for the treatment of displaced femoral neck fractures. *Orthopedics* 1985;8:972-6.
 23. Hartford JM, Patel A, Powell J. Intertrochanteric osteotomy using a dynamic hip screw for femoral neck nonunion. *J Orthop Trauma* 2005;19:329-33.
 24. Kalra M, Anand S. Valgus intertrochanteric osteotomy for neglected femoral neck fractures in young adults. *Int Orthop* 2001;25:363-6.
 25. Anglen JO. Intertrochanteric osteotomy for failed internal fixation of femoral neck fracture. *Clin Orthop Relat Res* 1997;175-82.
 26. Schoenfeld AJ, Vrabec GA. Valgus osteotomy of the proximal femur with sliding hip screw for the treatment of femoral neck nonunions: The technique, a case series, and literature review. *J Orthop Trauma* 2006;20:485-91.

How to cite this article: Sundar Raj PK, Nuuman JA, Pattathil AS. Bone impregnated hip screw in femoral neck fracture Clinoradiological results. *Indian J Orthop* 2015;49:187-92.

Source of Support: Nil, **Conflict of Interest:** None.

Announcement



Download
iPhone, iPad
application

A free application to browse and search the journal's content is now available for iPhone/iPad. The application provides "Table of Contents" of the latest issues, which are stored on the device for future offline browsing. Internet connection is required to access the back issues and search facility. The application is Compatible with iPhone, iPod touch, and iPad and Requires iOS 3.1 or later. The application can be downloaded from <http://itunes.apple.com/us/app/medknow-journals/id458064375?ls=1&mt=8>. For suggestions and comments do write back to us.