

First case of feline cryptococcosis in Hong Kong, caused by *Cryptococcus neoformans*

Angel Almendros^{a,*}, Daniela H. Muguero^b, Fraser I. Hill^b, Vanessa R. Barrs^c

^a CityU Veterinary Medical Center, City University of Hong Kong, Kowloon Tong, Hong Kong, China

^b CityU Veterinary Diagnostic Laboratory, City University of Hong Kong, Kowloon Tong, Hong Kong, China

^c Department of Public Health & Infectious Diseases, Jockey Club College of Veterinary Medicine, City University of Hong Kong, Kowloon Tong, Hong Kong, China



ARTICLE INFO

Keywords:

Cryptococcus neoformans
Basidiomycetous fungi
Lymphadenopathy
Azole therapy
Histopathology

ABSTRACT

A nine-year-old domestic short hair cat was presented for a nasal planum mass, nasal discharge, hyporexia and weight loss. On physical examination nasal proliferative and ulcerative lesions and submandibular lymphadenopathy were identified. Cytology, histopathology, fungal culture, antigen serology and MALDI-TOF confirmed cryptococcal rhinitis with regional mandibular lymph node involvement due to *Cryptococcus neoformans* infection. This is the first reported case of cryptococcosis in a feline patient in Hong Kong.

1. Introduction

The *Cryptococcus gattii*/*Cryptococcus neoformans* species complex comprises seven species of globally distributed dimorphic, basidiomycetous fungi that affect humans, dogs, cats and other animals, with a predilection for felines reportedly six to eight times higher than dogs [1–4]. *C. neoformans* is most frequently found in pigeon guano and plant matter [5], and was first identified in 1955 in urban and rural areas of the United States [6].

Feline cryptococcosis is most prevalent in Australia, Western Canada and the Western United States and occurs sporadically in other countries [1,2,7,8]. *Cryptococcus neoformans* is the species with highest prevalence in cats in southeastern Australia and is of epidemiological relevance as it is also the species that most often affects immunosuppressed humans [2,3]. In the United States *C. neoformans* is more prevalent in dogs whereas cats are most commonly infected by *C. gattii* [9].

Infection occurs after inhalation of basidiospores, followed by adhesion to and invasion of epithelial cells leading to colonization of mucosa, triggering cryptococcal rhinitis. In contrast to the pulmonary predilection described in humans, the nasal cavity is the main site of infection in cats and dogs [1,10].

We report here the first case of cryptococcosis in a domestic cat in Hong Kong.

2. Case

A nine-year-old neutered female cat was referred to City University of Hong Kong, Veterinary Medical Centre (City U VMC) for suspected nasal neoplasia. The cat had outdoor access, roaming freely, with a history of hunting birds and other pests. The client reported intermittent hyporexia, lethargy and gradual weight loss for the previous two months. The cat had been sneezing intermittently for the last month with a gradual increase in frequency, and developed intermittent epistaxis one week before presentation. The client noticed swelling in the neck area and an enlarged, red nose three weeks before presentation.

On physical exam (Day 0) the cat had proliferative, erythematous and ulcerative lesions involving the nasal rostrum, nasal planum and philtrum that partially occluded the nares (Fig. 1). The nasal lesions were associated with an audible stertor and intermittent open mouth breathing. Marked bilateral mandibular lymphadenopathy was also identified. Vital signs were normal and the rest of the physical exam was unremarkable.

Hematology and serum biochemistry revealed mild leukocytosis (WBC $17.10 \times 10^9/L$; reference range (RR) $2.87\text{--}17.2 \times 10^9/L$) due to mild neutrophilia ($11.12 \times 10^9/L$; RR 2.30–10.29) and mild monocytosis ($0.91 \times 10^9/L$; RR 0.05–0.67), and hyperproteinemia (98 g/L; RR 57–89 g/L) caused by hyperglobulinemia (70 g/L; RR 28–51) with otherwise unremarkable findings. Feline leukemia virus (FeLV) antigen and Feline immunodeficiency virus (FIV) antibody serology were both negative on an ELISA in-house test on (IDEXX-SNAP, Pty Ltd,

* Corresponding author.

E-mail address: afalm@cityuvmc.com.hk (A. Almendros).

<https://doi.org/10.1016/j.mmcr.2020.04.008>

Received 21 April 2020; Received in revised form 30 April 2020; Accepted 30 April 2020

Available online 19 May 2020

2211-7539/ © 2020 The Authors. Published by Elsevier B.V. on behalf of International Society for Human and Animal Mycology. This is an open access article under the CC BY-NC-ND license (<http://creativecommons.org/licenses/by-nc-nd/4.0/>).

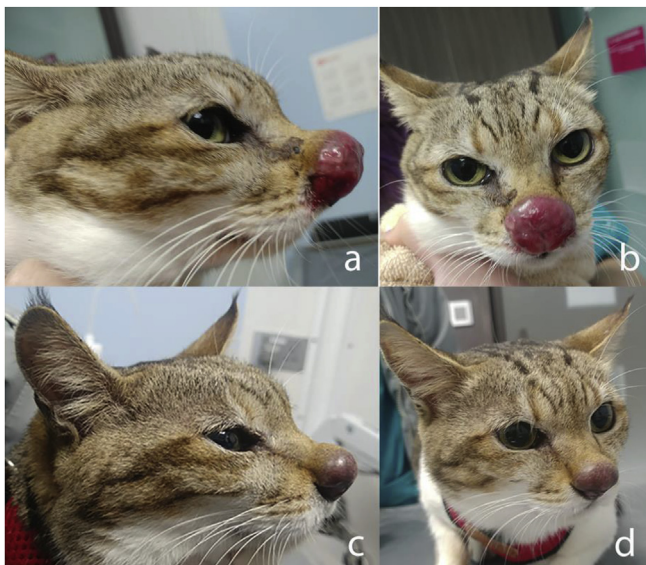

Fig. 1. Ulcerative and proliferative cryptococcal granuloma involving nasal planum, rostrum and philtrum, with partial obstruction of the nares pre-treatment (a, b) and 5 weeks post-treatment (c, d).

Rydalmer, Australia). A respiratory panel (qPCR test) from an oropharyngeal swab tested at a referral laboratory (CityU Veterinary Diagnostic Laboratory, CityU VDL City University of Hong Kong) revealed concurrent infection with *Feline calicivirus* (FCV) and *Mycoplasma felis*.

Computed tomography (CT) of the head and thorax was performed under general anaesthesia (Day 1) (Siemens Somatom go.Up, Siemens Healthcare GmbH, Erlangen, Germany) to assess the extent of local disease including involvement of the nasal cavity, sinuses, CNS and osseous structures, as well as lymph node and thoracic involvement. On CT the rostral 15 mm of the nasal cavity was occupied by soft tissue attenuating material. The caudal nasal cavity was unremarkable with no evidence of nasal bone, septal or turbinate destruction. The submandibular and medial retropharyngeal nodes were grossly enlarged up to 16 mm and 17 mm diameter, respectively (Fig. 2). These displaced adjacent structures such as the salivary glands that showed mild enhancement.

Cytological and histopathological assessment of mandibular lymph nodes and nasal tissue revealed fungal microorganisms. On cytological examination there were numerous extracellular yeasts, moderate numbers of macrophages, and small amounts of blood. The yeasts were round to oval and rarely displayed narrow-based budding (Fig. 3). They had a variably thick non-staining capsule and often a pale center, giving the specimen a bubbly appearance. Several yeasts displayed blue-purple internal granularity or a folded membrane. The yeasts varied from ~3 µm to rarely 10–13 µm in diameter. The macrophages were usually

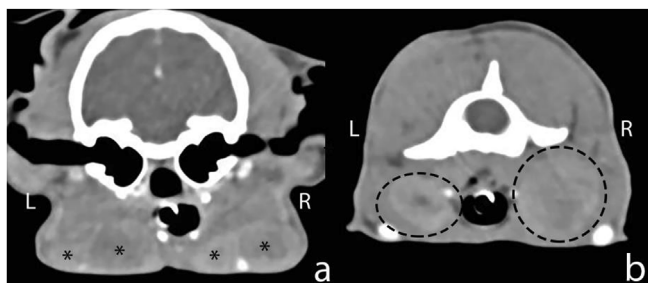


Fig. 2. Computed tomographic images of the head, transverse sections, soft-tissue window showing enlarged submandibular (a, asterisks) and retropharyngeal (b, encircled) lymph nodes due to cryptococcal infiltration.

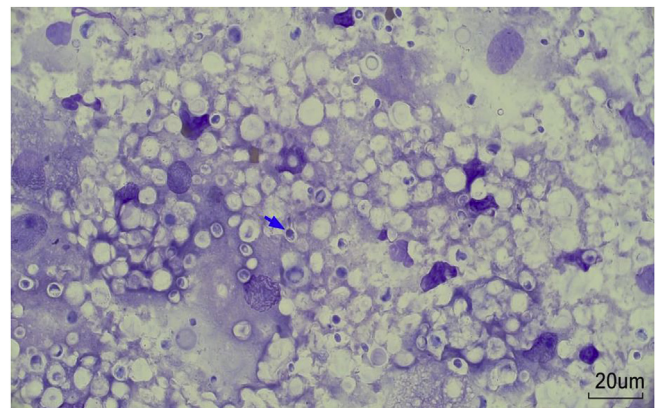


Fig. 3. Numerous variably encapsulated yeasts consistent with *Cryptococcus* spp. present extracellularly and within macrophages. The yeasts rarely display narrow-necked budding (blue arrow). Several nuclei of macrophages can be seen, but the cytoplasmic margins are obscured by the fungal structures (mandibular lymph node, 60x). (For interpretation of the references to colour in this figure legend, the reader is referred to the Web version of this article.)

laden with yeasts. Low numbers of macrophages were multinucleate. The cytological diagnosis was granulomatous inflammation with intralésional yeasts consistent with *Cryptococcus* spp.

The histopathological assessment from the nasal lesions reported that within the submucosa, the epidermis and the surface crust of necrotic debris and keratin were numerous 5–10 µm diameter spherical cryptococcal organisms surrounded by a clear capsule. Bests Mucicarmine stains applied to the sections highlighted the organism and the capsule (Fig. 4). The organisms were surrounded by moderate numbers of macrophages admixed with plasma cells and lymphocytes. In the surface crust were laminated regions of necrotic debris, fibrin and neutrophils.

A fungal culture submitted on Day 1 grew organisms identified as *C. neoformans* by matrix-assisted laser desorption/ionization with time-of-flight mass spectrometer (MALDI-TOF) and a Cryptococcal Antigen Latex Agglutination System (CALAS) test submitted on Day 7 confirmed the presence of *Cryptococcus* antigen with a final dilution titer of 1:2048.

The cat was initially treated with itraconazole (8.5 mg/kg) q24h PO, and six doses of amphotericin B deoxycholate (0.5mg/kg) of a 50 mg/mL solution diluted in 300 ml of 2.5% dextrose solution given subcutaneously (SQ) q56h that commenced after culture confirmation two weeks after presentation (Day 14).

The nasal lesions and lymphadenopathy remained similar in size after oral itraconazole but improved after each dose of amphotericin B.

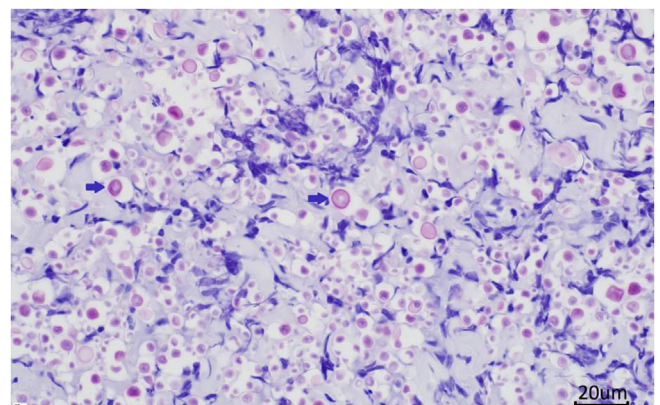


Fig. 4. Histopathology; numerous Cryptococcal organisms are expanding the nasal submucosa (arrows); Best mucicarmine stain (600x oil magnification).

The hyporexia and lethargy resolved shortly (Day 3) after starting treatment. Due to transient increasing azotemia after the 4th dose of amphotericin B on Day 24 (creatinine 217 µmol/L; RR 71–212, urea 13.7 mmol/L RR 5.7–12.9) and Day 28 (creatinine 242 µmol/L; RR 71–212) administration of amphotericin was delayed for 10 days and resumed on Day 38, when itraconazole was replaced by fluconazole 50mg PO q12h PO. A follow up LCAT test was repeated at day 91 without antigen titer improvement at 1:2048. Despite the unchanged titer a positive response to therapy was observed with prompt resolution of the epistaxis and improved demeanor shortly after treating with amphotericin B. Further improvement was observed after replacement of itraconazole by fluconazole with visible marked reduction of nasal lesions and lymph nodes size, which has been maintained up to the time of writing this article. Regular monitoring has been scheduled and continuation of treatment is in place.

3. Discussion

This is the first case of cryptococcosis reported in an animal in Hong Kong. Interestingly, the cat was an owned pet with outdoor access that roamed freely for most of the day. By contrast, most owned cats in Hong Kong are housed in apartments without outdoor access due to high urban population density. Other investigators have shown that while the majority of cats diagnosed with cryptococcosis have outdoor access, up to a quarter of cases occur in cats with no outdoor access at all, presumably through contact with aerosolized environmental basidiospores, or with contaminated soil such as in pot-plants or carried indoors on shoes [1].

As the infectious propagule in *Cryptococcus* spp. infections is the basidiospore, produced by the filamentous form of the organism and only the yeast forms grow in vivo in animal tissue, cryptococcal infections in cats are not zoonotic. However, animals can serve as sentinels for human infections, as was observed in the *C. gattii* outbreak on Vancouver Island in 2001–2002 when a cluster of 45 laboratory confirmed animal cases and 50 human cases was identified [11]. Animal species diagnosed with cryptococcosis included cats, dogs, porpoises, ferrets and llamas.

In Hong Kong, cryptococcosis is uncommon in humans both in immunocompromised and immunocompetent patients. In a one-year cross-sectional surveillance study of non-Candida fungaemia involving 25 hospitals located in China, Hong Kong, India, Singapore, Taiwan and Thailand 109 *Cryptococcus* spp isolates were detected. Of these, 17 isolates were from Hong Kong and all were *C. neoformans* [12]. Among immunocompetent patients *C. neoformans* is the most commonly identified cause of infection and meningitis is the most common clinical presentation [13].

Reports of feline cryptococcosis in nearby Asian countries are scarce. Single case reports of cryptococcal rhinitis, and of a cat with cutaneous cryptococcal lesions in Malaysia, and the Philippines, respectively are described [14] and two cryptococcal isolates, both *C. neoformans*, from cats with cryptococcosis in Thailand were included in a report describing the diversity and antifungal drug susceptibility of cryptococcal isolates in Thailand [14–16]. However, the paucity of reports is not likely reflective of infection prevalence. Cryptococcosis in cats in Malaysia is not considered a rare disease by veterinarians working there (Barrs, pers comm).

The large tumor-like growth affecting the nasal planum in this case, although shocking in appearance, did not extend into the nasal cavity or sinuses and did not infiltrate osseous structures. Nasal cryptococcosis in cats is typified by rostral nasal cavity involvement with sneezing, nasal discharge, nasal planum or nasal bridge distortion, or visible polypoid nasal masses [3]. Involvement of contiguous or nearby structures, such as regional lymph nodes, as occurred in this case, is common in feline cryptococcosis, occurring in approximately 40% of cases in one study [3]. The absence of systemic dissemination in this case, is typical, and occurs in less than 10% of cats with nasal cryptococcosis [3]. As well as

regional lymph nodes, eyes, skin and central nervous system (CNS) are other common sites infected via hematogenous spread and by leukocyte trafficking [10,17].

First-line therapy for feline cryptococcosis is fluconazole due to a low incidence of adverse effects and its ability to achieve high tissue concentrations in the brain, and eye, which are frequently involved in nasal cryptococcosis [2,18]. Itraconazole can also be used for first line therapy, although CNS penetration is inferior to fluconazole and adverse effects are more common [1]. In this case, the lack of response to itraconazole was most likely due to the short course of treatment or inadequate trough concentrations. Azole resistance, although reported, is rare among feline clinical isolates of *Cryptococcus* [7].

Amphotericin B alone or together with 5-flucytosine is added to the therapeutic regimen when disease is severe, or there is CNS or other systemic involvement [19]. A limitation of the use of amphotericin B deoxycholate is its nephrotoxicity. The onset of azotemia limited the use of AMB in this patient. The cumulative dose of 16 mg/kg was never reached but the elevation of renal values raised concerns.

The prognosis for cats with nasal cryptococcosis is generally favorable [2,3]. However, CNS involvement is associated with higher mortality rates and decreased survival times. In the present case, advanced imaging ruled out gross pathology in the CNS and thorax, and despite the prominent nasal lesion and lymphadenomegaly, the cat was clinically well, which was a positive prognostic indicator. A lag in decline of CALAS titre behind clinical improvement, as seen here, is not uncommon.

This confirmed case of *C. neoformans* should raise awareness about the presence of disease in the domestic pet population in Hong Kong. Diagnostic vigilance for fungal disease should be advocated and testing should be performed in cats presented with relevant clinical signs. Nasal ulcerations, rhinitis and lymphadenopathy should be included as differential diagnosis for cryptococcosis in the feline population of Hong Kong. The more recent availability of lower-cost point-of-care cryptococcal assays with moderate to high sensitivity (80–92%) and specificity (95%) could facilitate earlier diagnosis and management of the disease [20].

Declaration of competing Interest/COI

None.

Acknowledgements

The authors would like to thank Vidya Bhardwaj and Christina To from Veterinary Diagnostic Laboratory, City University of Hong Kong for generating the culture reports and Prof. Robert Kirberger from the Companion Animal Clinical Studies Department, University of Pretoria for the radiological interpretation.

References

- [1] S.R. Trivedi, J.E. Sykes, M.S. Cannon, E.R. Wisner, W. Meyer, B.K. Sturges, et al., Clinical features and epidemiology of cryptococcosis in cats and dogs in California: 93 cases (1988–2010), *J. Am. Vet. Med. Assoc.* 239 (3) (2011) 357–369.
- [2] S. McGill, R. Malik, N. Saul, S. Beeton, C. Secombe, I. Robertson, et al., Cryptococcosis in domestic animals in Western Australia: a retrospective study from 1995–2006, *Med. Mycol.* 47 (6) (2009) 625–639.
- [3] C. O'Brien, M. Krockenberger, D. Wigney, P. Martin, R. Malik, Retrospective study of feline and canine cryptococcosis in Australia from 1981 to 2001: 195 cases, *Med. Mycol.* 42 (5) (2004) 449–460.
- [4] F. Hagen, K. Khayhan, B. Theelen, A. Kolecka, I. Polacke, E. Sionov, et al., Recognition of seven species in the *Cryptococcus gattii*/*Cryptococcus neoformans* species complex, *Fungal Genet. Biol.* 78 (2015) 16–48.
- [5] M. Lazera, F. Pires, L. Camillo-Coura, M. Nishikawa, C. Bezerra, L. Trilles, et al., Natural habitat of *Cryptococcus neoformans* var. *neoformans* in decaying wood forming hollows in living trees, *J. Med. Vet. Mycol.* 34 (2) (1996) 127–131.
- [6] C.W. Emmons, Saprophytic sources of *Cryptococcus neoformans* associated with the pigeon (*Columba livia*), *Am. J. Hyg.* 62 (3) (1955) 227–232.
- [7] R. Kano, M. Okubo, T. Yanai, A. Hasegawa, H. Kamata, First isolation of azole-resistant *Cryptococcus neoformans* from feline cryptococcosis, *Mycopathologia* 180

- (5–6) (2015) 427–433.
- [8] B. Flatland, R. Greene, M. Lappin, Clinical and serologic evaluation of cats with cryptococcosis, *J. Am. Vet. Med. Assoc.* 209 (6) (1996) 1110–1113.
- [9] S.R. Trivedi, R. Malik, W. Meyer, J.E. Sykes, Feline cryptococcosis: impact of current research on clinical management, *J. Feline Med. Surg.* 13 (3) (2011) 163–172.
- [10] J.E. Sykes, B. Sturges, M. Cannon, B. Gericota, R. Higgins, S. Trivedi, et al., Clinical signs, imaging features, neuropathology, and outcome in cats and dogs with central nervous system cryptococcosis from California, *J. Vet. Intern. Med.* 24 (6) (2010) 1427–1438.
- [11] C. Stephen, S. Lester, W. Black, M. Fyfe, S. Raverty, Multispecies outbreak of cryptococcosis on southern vancouver Island, British columbia, *Can. Vet. J.* 43 (10) (2002) 792–794.
- [12] S.Y. Lin, P.L. Lu, B.H. Tan, A. Chakrabarti, U.I. Wu, J.H. Yang, et al., The epidemiology of non-Candida yeast isolated from blood: the Asia Surveillance Study, *Mycoses* 62 (2) (2019) 112–120.
- [13] G. Lui, N. Lee, M. Ip, K. Choi, Y. Tso, E. Lam, et al., Cryptococcosis in apparently immunocompetent patients, *Q. J. Med.* 99 (3) (2006) 143–151.
- [14] A. Habibahl, A. Mutalib, M. Hair-Bejo, H. Hengl, Feline cryptococcosis in Malaysia: a first report, *J. Vet. Malays.* 21 (1) (2009) 35–38.
- [15] R.B. Oronan, P.M.R. Eguia, Cryptococcosis in a four-year-old intact male domestic short-haired cat, *Philipp. J. Vet. Anim. Sci.* 39 (1) (2013) 141–146.
- [16] N. Worasilchai, M. Tangwattanachuleeporn, K. Meesilpavikkai, C. Folba, M. Kangogo, U. Groß, et al., Diversity and antifungal drug susceptibility of *Cryptococcus* isolates in Thailand, *Med. Mycol.* 55 (6) (2017) 680–685.
- [17] J. Paulin, M. Morshed, A.G. Armien, Otitis interna induced by *Cryptococcus neoformans* var. *grubii* in a cat, *Vet. Pathol.* 50 (2) (2013) 260–263.
- [18] R. Malik, D. Wigney, D. Muir, D. Gregory, D. Love, Cryptococcosis in cats: clinical and mycological assessment of 29 cases and evaluation of treatment using orally administered fluconazole, *J. Med. Vet. Mycol.* 30 (2) (1992) 133–144.
- [19] R. Malik, A. Craig, D. Wigney, P. Martin, D. Love, Combination chemotherapy of canine and feline cryptococcosis using subcutaneously administered amphotericin B, *Aust. Vet. J.* 73 (4) (1996) 124–128.
- [20] K.L. Reagan, I. McHardy, G.R. Thompson III, J.E. Sykes, Evaluation of the clinical performance of 2 point-of-care cryptococcal antigen tests in dogs and cats, *J. Vet. Intern. Med.* 33 (5) (2019) 2082–2089.