



CASE REPORT

Lumbar Pedicular Stress Fracture Post-laminectomy: a Case Report

Noémie Ampe^{1,2} · P. Meersman³ · D. Ghysen³ · B. Kegelaers⁴ · C. Gorris¹ · J. Debeuf⁵ · P. Van Wambeke² · M. Schreurs¹

Accepted: 9 September 2022

© The Author(s), under exclusive licence to Springer Nature Switzerland AG 2022

Abstract

We present the case of a 74-year-old male suffering from degenerative lumbar spinal stenosis with neurogenic claudication resulting in reduced walking distance. MR imaging indicated spinal canal stenosis at the level of L3–L4 and L4–L5 due to degenerative discopathy, discal extrusion, and facet arthrosis. After conservative treatment had failed, a multilevel laminectomy was performed. Four months postoperatively, the patient developed a stress fracture of the L4 pedicle. Pedicular stress fractures are uncommon and few case reports are found in the literature. Usually, they occur due to contralateral spondylolysis or congenital anomalies. The findings in this case however suggest a change of biomechanical load over the pedicle due to spinal surgery. An overview of the literature concerning spinal instability after laminectomy is provided. Spinal decompressive surgery can significantly change the biomechanical forces on the spinal structures, resulting in important postoperative complications. Whether pedicle stress fracture in this case is a result of pre- or postoperative circumstances remains a subject for discussion.

Keywords Case report · Laminectomy · Stress fracture

Introduction

In elderly patients over 65 years of age, lumbar spinal stenosis with neurogenic claudication is the most frequent indication for spinal surgery [1]. Lumbar spinal stenosis is defined as “a narrowing of the spinal canal, the lateral nerve root canals or the intervertebral neural foramina due to hypertrophy of any of the surrounding ligamentous or osteocartilaginous elements, resulting in vascular or neurogenic compression”

[2]. The cause of spinal canal stenosis can be either congenital as the direct result of congenital features (e.g., short pedicles) or degeneration, or a combination of those two. The degenerative type is a result of a process with a typical loss of disc height, associated disc bulging, and folding in of the ligamentum flavum, combined with facet osteoarthritis and hypertrophy. Finally, spinal stenosis may also occur in combination with spondylolisthesis [1].

The most common complaint in patients suffering from spinal stenosis is neurogenic claudication, characterized as pain in the lower extremities, resulting in a reduced walking capacity [3]. Often, a flexion of the spine can provide some relief from these symptoms. However, no clear diagnostic criteria exist. Conservative treatments consist of pain treatment and improving mobility and control of the movement of the lumbar spine [3]. Operative methods include the removal of pathological compressive structures, often referred to as “decompression.” However, spinal instability is a major complication associated with decompressive spinal surgery [2], often requiring re-intervention (e.g., spinal fusion). More specifically, postoperative spondylolysis or spondylolisthesis is a common complication after lumbar laminectomy, due to excessive shear displacement [4]. We discuss a single-level pedicular stress fracture

This article is part of the Topical Collection on *Surgery*

✉ Noémie Ampe
noemie.ampe@uzleuven.be

¹ Department of Physical and Rehabilitation Medicine, Heilig-Hart Ziekenhuis, Lier, Belgium

² Department of Physical and Rehabilitation Medicine, UZ Leuven, Leuven, Belgium

³ Department of Radiology, Heilig-Hart Ziekenhuis, Lier, Belgium

⁴ Department of Neurosurgery, Heilig-Hart Ziekenhuis, Lier, Belgium

⁵ Department of Anesthesiology, Heilig-Hart Ziekenhuis, Lier, Belgium

post-laminectomy on an individual level, further commenting on the biomechanical changes caused by laminectomy. To our knowledge, only one other case report discusses a similar case with a pedicular stress fracture after laminectomy due to rotational instability [5].

Case Report

This report involves a 74-year-old male, suffering from metabolic syndrome with insulin-dependent diabetes mellitus type 2, arterial hypertension, obesity (BMI 39 kg/m²), and hypercholesterolemia. Furthermore, the patient has a medical history of pontine stroke, leading to dysarthria and an atactic paresis in the right hand. Relevant spinal history includes a herniated disk on the right at the level of L4–L5 which was successfully treated conservatively with transforaminal epidural infiltrations.

On initial presentation, the primary complaint of the patient was a pain in the right gluteal area with radiation to the right upper leg and impaired walking tolerance. MR imaging showed degenerative discopathies at the L3–L4 and L4–L5 levels—with disc extrusion. On level L4–L5, there is additionally ligamentum flavum hypertrophy resulting in compression of the origin of the L4 root on the right. These findings result in a spinal canal stenosis at both L3–L4 and L4–L5 levels. Electromyographic findings showed a right radiculopathy on level L4. After unsuccessful conservative treatment with epidural infiltrations and exercise therapy, a L4 spinous process resection with laminectomy in combination with a right discectomy L3–L4 was performed (Fig. 1). A facetectomy was not carried out.

After surgery, initial pain control was obtained with alleviation of the sciatica and improved gait performance. However, after a few weeks, the patient presented with a relapse of lumbalgia. This lumbalgia got worse over the following months, with the development of bilateral mechanical

sciatica. On clinical examination, there were no signs of motor deficit in the legs, with intact and symmetric knee and Achilles tendon reflexes. At this point, a walking aid was necessary as his walking distance was limited to 100 m. MRI findings showed a hypointense interruption with surrounding bone-marrow edema in the right pedicle of the L4 vertebra (Fig. 2). On electromyography, a L5 radiculopathy was described by new unstable motor units without denervation activity; this was considered a new finding in comparison with older EMG results. On the left side, a stable multi-level radiculopathy was shown. Epidural infiltrations failed to achieve pain reduction.

Additional Tc99m-HDP-SPECT-CT imaging showed a metabolically active, linear lucency with sclerotic margins in the right pedicle of the L4 vertebra, suggesting a stress fracture (Fig. 3).

Interdisciplinary deliberation with representatives of the different departments incl. neurosurgery, algology, and physical and rehabilitation medicine was scheduled. In retrospect, this pedicular lesion was already apparent on an MRI of the lumbar spine four months after the laminectomy procedure, with bone marrow edema centered around a sclerotic pedicle. A percutaneous posterolateral fusion of L4–L5 was performed.

Due to the COVID-19 pandemic outbreak, postoperative rehabilitation physiotherapy was postponed and started only 3 months after lumbar fusion surgery. Until then, the patient's lumbalgia had significantly improved, but did not resolve completely.

Discussion

Pedicular stress fractures are considered a rare finding in patients with low back pain. They can occur as a result of two basic mechanisms: the exertion of an unusual force on an otherwise normal and healthy bone or a normal force applied on an already diseased or weakened bone structure.

Fig. 1 Preoperative axial (left) and midsagittal (right) TSE-T2 images of the lumbar spinal stenosis at L3–L4 level

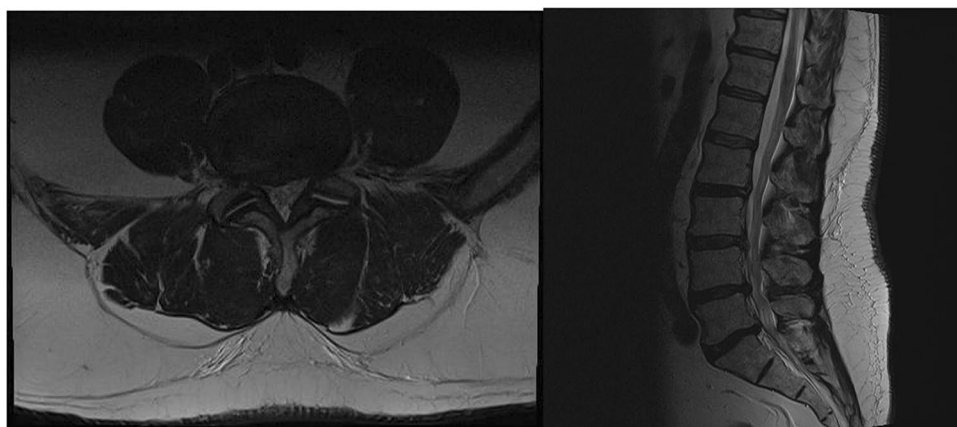


Fig. 2 Axial (left) and sagittal (right) TSE-T2 images demonstrating the hypointense stress fracture with surrounding hyperintense bone-marrow edema in the right L4 pedicle

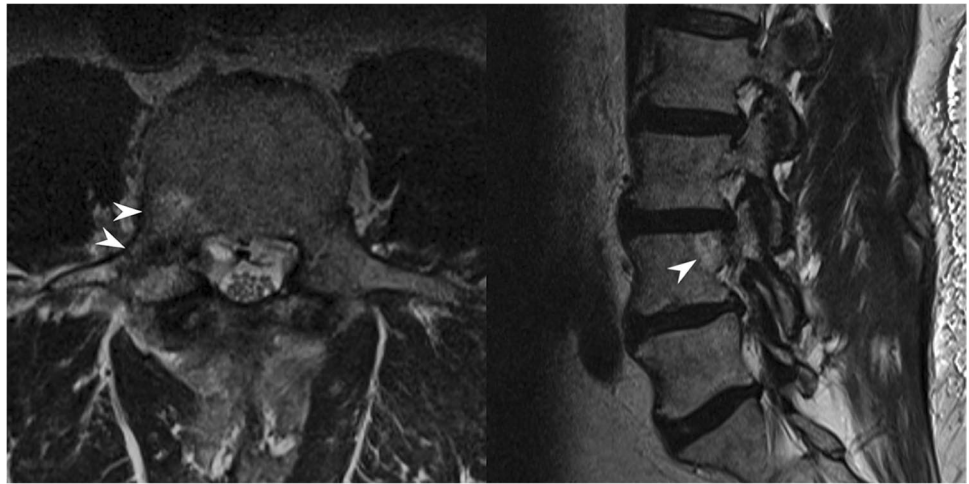
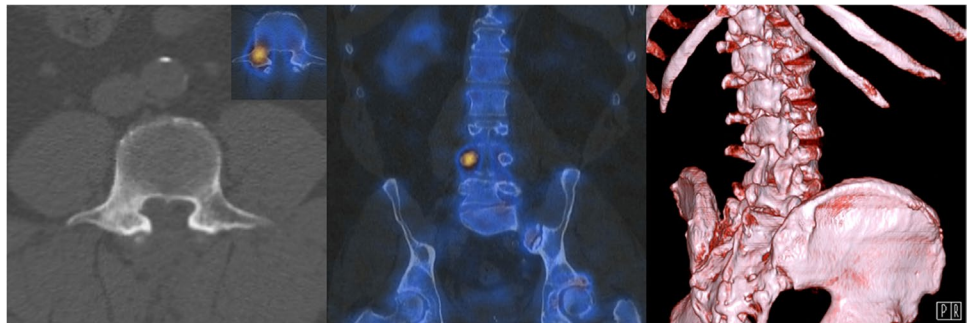


Fig. 3 Left: axial CT-view of the L4 vertebra shows a sclerotic right pedicle. Middle: coronal SPECT-CT view showing a markedly increased osteogenesis. Right: volume-rendered image demonstrating the laminectomy with the right L4-pedicle at the center of the image



The pedicular fracture in this case is probably an unusual case of the first mechanism, as the involved bone structures were normal [6]. Case reports have been written about bilateral pedicle fracture in a patient with spinal stenosis [7] or after an osteoporotic compression fracture [8].

Imaging is the cornerstone in diagnosing stress fractures, spinal or otherwise. Radiography is often the first modality of choice but has very poor sensitivity, both for early-stage (15–35%) and late-stage (30–70%) injuries. As MRI shows superior sensitivity to both CT and bone scintigraphy, it is the modality of choice [9]. With much better tissue contrast, MRI is able to differentiate the often painful stress reaction prior to the stress fracture. During this reaction, where bone strengthening as a reaction to stress has reached a plateau, bone marrow edema, hyperemia, and increased osteoclastic activity develop within the bone as well as periosteal edema, resulting in increased signal intensity on fluid-sensitive sequences, similar to a bone marrow contusion. During this period, signal alterations on T1-weighted images are absent. As stress persists, a fracture develops, which increases the signal alterations on fluid-sensitive sequences. These fractures, unlike simple stress reactions, show structural changes on T1-weighted images as a discrete cortical defect, periosteal callus formation, or a trabecular distortion. However,

these structural changes may still be absent and conversely, even after complete healing some structural change may persist albeit in the absence of bone marrow edema [10–13].

When performing a laminectomy, the vertebral laminae, the ligamentum flavum, the supra- and interspinous ligaments, and the medial facet joint capsule are removed to obtain spinal decompression. Whether the decompression should be supplemented with a fusion procedure, is still a matter of debate. The decompression results in an alteration of the spine biomechanics [14]. It was Goel et al. [15] who described that the supraspinous ligament is exposed to the greatest force during a flexion movement of a lumbar segment. A laminectomy, with the removal of this supraspinous ligament, induces an anterior shift of the compressive weight-bearing axis. Stress in the anterior annulus fibrosus, the most anterior part of intervertebral articulation, is increased by 130% in post-mortem laminectomies on level L4–L5 opposed to normal spine specimens [16]. This shift in weight transfer not only increases the load on ligamentous structures, but also on the osseous components of the spine.

When lacking the ligamentous support after laminectomy, the stability is provided by the paraspinal musculature. Unfortunately, these are often damaged during surgery (e.g., direct trauma, denervation, muscular atrophy)

and thus fail to provide this support in the postoperative setting. In a retrospective study by Yang et al. [17], spinal instability (defined as spondylolisthesis and/or segmental angulation) was found to be more prevalent in patients with asymmetrical paraspinal muscle volume ($p < 0.01$) and is even associated with worse long-term clinical outcome.

In conclusion, treatment for spinal stenosis should be tailored, taking into account many factors. Both conservative and surgical treatment seem feasible, but spinal decompressive surgery can significantly change the biomechanical forces on the spinal structures by mechanisms not yet fully understood, possibly resulting in important postoperative complications.

Author Contribution SM and KB were the treating physicians of the patient. GD was responsible for imaging and retrospective analysis of the imaging. AN, MP, and VWP performed the literature research. DJ and CG were involved in the multidisciplinary meeting (referred to as Spine Unit). AN, MP, VWP, and SM wrote the manuscript. All authors read, reviewed, and approved the manuscript.

Data Availability The data that support the findings of this study are available on request from the corresponding author, NA. The data are not publicly available due to restrictions as this contains information that could compromise the privacy of the research participant.

Code Availability Not applicable.

Declarations

Ethics Approval This case study was approved by the Medical Ethical Committee of Heilig Hart Ziekenhuis, Lier.

Consent to Participate The participant has consented to the writing of the case report.

Consent for Publication The participant has consented to the publishing of the case report.

Conflict of Interest The authors declare no competing interests.

References

- Katz JN, Harris MB. Clinical practice. Lumbar spinal stenosis. *N Engl J Med*. 2008;358:818–25.
- Adilay U, Guclu B. Comparison of single-level and multilevel decompressive laminectomy for multilevel lumbar spinal stenosis. *World Neurosurg*. 2018;111:e235–40.
- Zaina F, Tomkins-Lane C, Carragee E, Negrini S. Surgical versus non-surgical treatment for lumbar spinal stenosis. *Cochrane Database Syst Rev* 2016;1:CD010264. <https://doi.org/10.1002/1461858.CD010264.pub2>
- Bisschop A, van Royen BJ, Mullender MG, et al. Which factors prognosticate spinal instability following lumbar laminectomy? *Eur Spine J*. 2012;21:2640–8.
- Sirvanci M, Ulusoy L, Duran C. Pedicular stress fracture in lumbar spine. *Clin Imaging*. 2002;26:187–93.
- Matcuk GR Jr, Mahanty SR, Skalski MR, et al. Stress fractures: pathophysiology, clinical presentation, imaging features, and treatment options. *Emerg Radiol*. 2016;23:365–75.
- Doita M, Shimomura T, Nishida K, et al. Bilateral pedicle stress fracture in a patient with lumbar spinal stenosis: a case report. *J Spinal Disord Tech*. 2008;21:531–4.
- Doita M, Ando Y, Hirata S, et al. Bilateral pedicle stress fracture in a patient with osteoporotic compression fracture. *Eur Spine J*. 2009;18(Suppl 2):206–9.
- Gross I. Nutritional and hormonal influences on lung phospholipid metabolism. *Fed Proc*. 1977;36:2665–9.
- Stafford SA, Rosenthal DI, Gebhardt MC, et al. MRI in stress fracture. *AJR Am J Roentgenol*. 1986;147:553–6.
- Marshall RA, Mandell JC, Weaver MJ, et al. Imaging features and management of stress, atypical, and pathologic fractures. *Radiographics*. 2018;38:2173–92.
- Lee JK, Yao L. Stress fractures: MR imaging. *Radiology*. 1988;169:217–20.
- Spitz DJ, Newberg AH. Imaging of stress fractures in the athlete. *Radiol Clin North Am*. 2002;40:313–31.
- Tai C-L, Hsieh P-H, Chen W-P, et al. Biomechanical comparison of lumbar spine instability between laminectomy and bilateral laminotomy for spinal stenosis syndrome - an experimental study in porcine model. *BMC Musculoskelet Disord*. 2008;9:84.
- Goel VK, Fromknecht SJ, Nishiyama K, et al. The role of lumbar spinal elements in flexion. *Spine*. 1985;10:516–23.
- Rao RD, Wang M, Singhal P et al (2002) Intradiscal pressure and kinematic behavior of lumbar spine after bilateral laminotomy and laminectomy. *Spine J* 2. [https://doi.org/10.1016/s1529-9430\(02\)00402-3](https://doi.org/10.1016/s1529-9430(02)00402-3).
- Yang JC, Kim SG, Kim TW, Park KH. Analysis of factors contributing to postoperative spinal instability after lumbar decompression for spinal stenosis. *Korean J Spine*. 2013;10:149–54.

Publisher's Note Springer Nature remains neutral with regard to jurisdictional claims in published maps and institutional affiliations.

Springer Nature or its licensor holds exclusive rights to this article under a publishing agreement with the author(s) or other rightsholder(s); author self-archiving of the accepted manuscript version of this article is solely governed by the terms of such publishing agreement and applicable law.