

# An unusual presentation of Hashimoto's encephalopathy

Rajeev Philip, Sanjay Saran, Manish Gutch, Keshavkumar Gupta

Department of Endocrinology, LLRM Medical College, Meerut, Uttar Pradesh, India

### ABSTRACT

Hashimoto's encephalopathy (HE) is a rare steroid-responsive encephalopathy syndrome, which can have highly variable neuropsychiatric manifestations and can go unrecognized for a long time. HE is a diagnosis of exclusion and should be kept in mind when evaluating a patient with a cognitive dysfunction and high titers of anti-thyroid antibodies as it responds dramatically to steroids. Steroid responsive myoclonus can be a presentation of HE.

**Key words:** Anti-thyroid antibodies, autoimmune thyroid disease, Hashimoto encephalopathy, hypothyroidism, steroid responsive encephalopathy

## INTRODUCTION

Hashimoto's encephalopathy is a rare steroid responsive encephalopathy syndrome characterized by persisting or fluctuating neurologic and neuropsychological deficits associated with elevated blood concentrations of anti-thyroid antibodies.<sup>[1,2]</sup> The classically described clinical manifestations usually include acute to subacute onset of confusion with alteration of consciousness, but myoclonus is a less publicized manifestation of the disease.<sup>[3]</sup> We present a case of Hashimoto's encephalopathy, presenting as steroid responsive myoclonus in a setting of autoimmune thyroid disease.

## CASE REPORT

An 18-year-old male patient was diagnosed to have primary hypothyroidism 6 months back following weight gain, edema and facial puffiness of 3 years duration. His initial thyroid function test (TFT) was T4: 2.3 µg/dl (5.01-12.4)

T3: 0.35 ng/ml (0.6-1.81) and thyroid stimulating hormone (TSH): 180 µIU/ml (0.35-5.50) and was started on L thyroxine, with a significant improvement of symptoms. He started developing myoclonus for the past 1 month, for which he was referred to our hospital.

On examination, he was conscious, with a cognitive impairment and had memory loss for recent events, with the poor attention span, difficulty in finding words, dyscalculia and dysgraphia. His mini mental status examination (MMSE) was 11 suggestive of moderate cognitive impairment. He also had myoclonus, involving both upper limbs and lower limbs.

On investigations, blood routine examination and erythrocyte sedimentation rate was normal and liver function test, kidney function test, sodium, potassium, calcium and magnesium were normal and so were the arterial blood gas analysis. His latest TFTs show normal T3 and T4 with mild elevation of TSH (TSH-9.1 µIU/ml). Anti-thyroid peroxidase antibody was positive (>1300 IU/ml). His electroencephalogram (EEG) showed a diffuse slow wave activity [Figure 1] and magnetic resonance images (MRI) showed a pituitary hyperplasia [Figure 2] with non-specific White matter changes [Figure 3]. Cerebrospinal fluid (CSF) study had normal cytology, but slightly increased protein.

Antinuclear antibody titer, anti-double-stranded deoxyribonucleic acid, hepatitis B surface antigen,

#### Access this article online

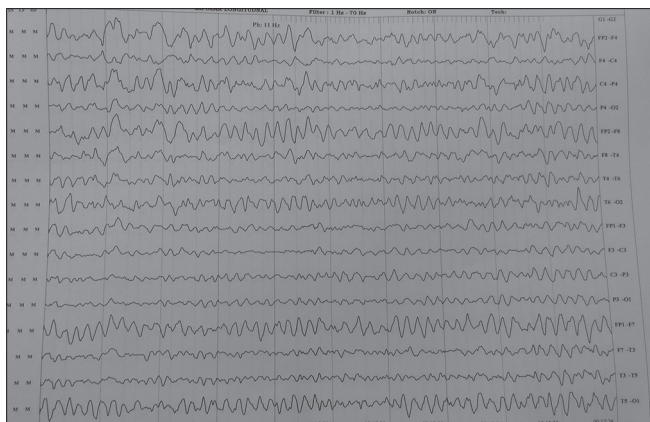##### Quick Response Code:



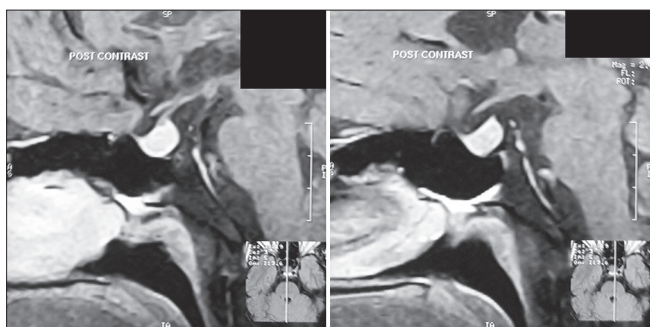
Website:  
www.ijem.in

DOI:  
10.4103/2230-8210.126589

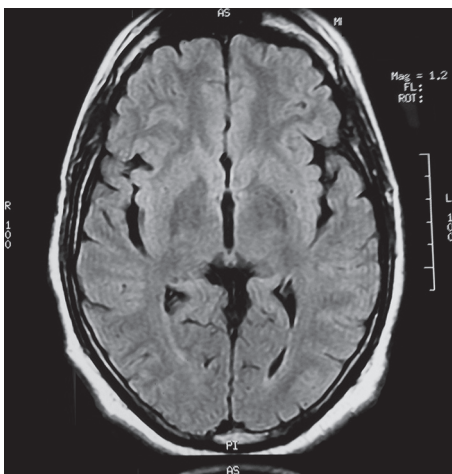
Corresponding Author: Dr. Rajeev Philip, G 10, PG Hostel, LLRM Medical College, Meerut - 250 004, Uttar Pradesh, India. E-mail: endollrm@yahoo.com



**Figure 1:** Electroencephalogram showing diffuse slow wave activity



**Figure 2:** Magnetic resonance images showing pituitary hyperplasia



**Figure 3:** Magnetic resonance images showing non-specific White matter changes

anti-hepatitis C virus, lupus anticoagulant and Venereal Disease Research Laboratory (VDRL) test were carried out to evaluate the cause of decreased cognitive function, myoclonus and seizures, which were all negative. CSF electrophoresis was normal.

In view of these neurologic symptoms, associated with high titers of anti-thyroid antibodies and the exclusion of other possible causes of encephalopathy, patient was diagnosed with Hashimoto's encephalopathy. He was started

on methylprednisolone 1 g/day for 3 days and was shifted over to prednisone 1 mg/kg/day. There was a marked improvement in the symptoms with no further episodes of myoclonus or seizures. One month after discharge, the patient reported a sustained improvement on all parameters, including memory and cognition, making it possible for his to return to an almost normal routine. His MMSE had improved to 26 and he is seizure free. Prednisone dose was tapered over the period of 3 months without the recurrence of symptoms.

## DISCUSSION

Hashimoto's encephalopathy is a rare steroid responsive neuropsychiatric syndrome, associated with the serologic evidence of anti-thyroid antibodies, when other causes of encephalopathy are excluded. This syndrome was first described by Brain *et al.* in 1966,<sup>[4]</sup> but it still remains a rare or under diagnosed condition with only about 130 cases reported in the literature until date, predominantly in adult females. The difficulty in diagnosis is due to the varied presentations and subtlety of symptoms, which may be acute or chronic.<sup>[5]</sup>

The pathophysiology of Hashimoto encephalopathy is still unclear and the proposed pathogenetic mechanisms include autoimmune cerebral vasculitis, toxic effects of thyroid-stimulating hormone on the central nervous system and neuronal reaction mediated by antibodies.<sup>[6]</sup> The anti-thyroid antibodies does not appear to be pathogenic and are considered as markers of the disease. Based on this observation, it has been proposed to rename Hashimoto's encephalopathy (HE) as steroid-responsive encephalopathy associated with autoimmune thyroiditis.<sup>[2]</sup>

The clinical manifestations usually include acute to the subacute onset of confusion with alteration of consciousness. Two-thirds of patients may experience focal or generalized tonic-clonic seizures and 12% may present with status epilepticus. Hyperreflexia and other pyramidal tract signs are found in 85% of patients and psychosis, visual hallucinations and paranoid delusions have been reported in 25-36% of patients.<sup>[1,5]</sup>

Myoclonus is a less publicized but common manifestation of HE, with 52% patients diagnosed to have HE, having a history of myoclonus.<sup>[7]</sup>

### Diagnosis

The diagnosis of HE should be considered in patients presenting with the characteristic neuropsychiatric manifestations excluding other causes of encephalopathy. They should have (1) presence of high levels of anti-thyroid antibodies in serum or CSF; (2) no alteration in the

CSF and/or imaging tests compatible with infectious, vascular, or neoplastic etiology; and (3) a good response to immunosuppressive therapy.

Elevated CSF protein is a common<sup>[6]</sup> and the thyroid profile may be variable, with 23-35% of patients having subclinical hypothyroidism, 17-20% having hypothyroidism, 7% having hyperthyroidism and 18-45% being euthyroid.

Non-specific EEG abnormalities are seen in 90-98% of patients and brain MRI may show abnormalities in 49% such as cerebral atrophy, focal cortical abnormality, diffuse subcortical abnormality and non-specific subcortical focal White matter abnormality.<sup>[1]</sup>

### Treatment

The disease is responsive to immunosuppressive therapy and intravenous (IV) methylprednisolone (500-1000 mg/day) for 3-5 days, followed by an oral dose of prednisone (1-2 mg/kg/day), followed by gradual tapering based on the clinical response being the commonly followed protocol. Around 2-5% of patients may not respond to steroids, in whom azathioprine, IV immunoglobulins or plasmapheresis can be used with good results.<sup>[8]</sup>

## REFERENCES

1. Kothbauer-Margreiter I, Sturzenegger M, Komor J, Baumgartner R, Hess CW. Encephalopathy associated with Hashimoto thyroiditis: Diagnosis and treatment. *J Neurol* 1996;243:585-93.
2. Castillo P, Woodruff B, Caselli R, Vernino S, Lucchinetti C, Swanson J, *et al.* Steroid-responsive encephalopathy associated with autoimmune thyroiditis. *Arch Neurol* 2006;63:197-202.
3. Gücüyener K, Serdaroğlu A, Bideci A, Yazman Y, Soysal AS, Cinaz P. Tremor and myoclonus heralding Hashimoto's encephalopathy. *J Pediatr Endocrinol Metab* 2000;13:1137-41.
4. Brain L, Jellinek EH, Ball K. Hashimoto's disease and encephalopathy. *Lancet* 1966;2:512-4.
5. Chong JY, Rowland LP, Utiger RD. Hashimoto encephalopathy: Syndrome or myth? *Arch Neurol* 2003;60:164-71.
6. Takahashi S, Mitamura R, Itoh Y, Suzuki N, Okuno A. Hashimoto encephalopathy: Etiologic considerations. *Pediatr Neurol* 1994;11:328-31.
7. de Holanda NC, de Lima DD, Cavalcanti TB, Lucena CS, Bandeira F. Hashimoto's encephalopathy: Systematic review of the literature and an additional case. *J Neuropsychiatry Clin Neurosci* 2011;23:384-90.
8. Mocellin R, Walterfang M, Velakoulis D. Hashimoto's encephalopathy: Epidemiology, pathogenesis and management. *CNS Drugs* 2007;21:799-811.

**Cite this article as:** Philip R, Saran S, Gutch M, Gupta K. An unusual presentation of Hashimoto's encephalopathy. *Indian J Endocr Metab* 2014;18:113-5.

**Source of Support:** Nil, **Conflict of Interest:** None declared.