

## ORIGINAL RESEARCH

# Histopathological changes to the peripheral vestibular system following meningitic labyrinthitis

Henrique F. Pauna MD<sup>1</sup>  | Renata M. Knoll MD<sup>2,3</sup>  | Rory J. Lubner<sup>2,3</sup>  |  
 Jacob R. Brodsky MD<sup>4</sup>  | Sharon L. Cushing MD, MSc<sup>5</sup> |  
 Miguel A. Hyppolito MD, PhD<sup>1</sup>  | Joseph B. Nadol Jr MD<sup>6</sup>  |  
 Aaron K. Remenschneider MD, MPH<sup>2,3</sup>  | Elliott D. Kozin MD<sup>2,3</sup> 

<sup>1</sup>Department of Ophthalmology, Otorhinolaryngology and Head and Neck Surgery, Ribeirão Preto Medical School (FMRP-USP), University of São Paulo, Ribeirão Preto, São Paulo, Brazil

<sup>2</sup>Department of Otolaryngology, Massachusetts Eye and Ear, Boston, Massachusetts

<sup>3</sup>Department of Otolaryngology, Harvard Medical School, Boston, Massachusetts

<sup>4</sup>Department of Otolaryngology and Communication Enhancement, Boston Children's Hospital, Boston, Massachusetts

<sup>5</sup>Department of Otolaryngology, Head & Neck Surgery, Hospital for Sick Children, University of Toronto, Toronto, Ontario, Canada

<sup>6</sup>Otopathology Laboratory, Department of Otolaryngology, Massachusetts Eye and Ear, Boston, Massachusetts

**Correspondence**

Aaron Remenschneider, Department of Otolaryngology, Harvard Medical School, 243 Charles Street, Boston, MA 02114. Email: aaron\_remenschneider@meei.harvard.edu or Elliott D. Kozin, Department of Otolaryngology, Harvard Medical School, 243 Charles Street, Boston, MA 02114. Email: elliot\_kozin@meei.harvard.edu

**Abstract**

**Objective:** While cochlear ossification is a common sequela of meningitic labyrinthitis, less is known about the effects of meningitis on the peripheral vestibular end organs. Herein, we investigate histopathologic changes in the peripheral vestibular system and cochlea in patients with a history of meningitic labyrinthitis.

**Methods:** Temporal bone (TB) specimens from patients with a history of meningitis were evaluated and compared to age-matched controls. Specimens were evaluated by light microscopy and assessed for qualitative changes, including the presence of vestibular and/or cochlear endolymphatic hydrops, presence and location of inflammatory cells, new bone formation, and labyrinthitis ossificans; and quantitative changes, including Scarpa's ganglion neuron (ScGN) and spiral ganglion neuron (SGN) counts.

**Results:** Fifteen TBs from 10 individuals met inclusion and exclusion criteria. Presence of inflammatory cells and fibrous tissue was found in 5 TBs. Of these, evidence of labyrinthitis ossificans was found in 2 TBs. In the peripheral vestibular system, mild to severe degeneration of the vestibular membranous labyrinth was identified in 60% of cases (n = 9 TBs). There was a 21.2% decrease (range, 3%-64%) in the mean total count of ScGN in patients with meningitis, compared to age-matched controls. In the cochlea, there was a 45% decrease (range, 25.3%-80.9%) in the mean total count of SGN compared to age-matched controls (n = 14 TBs).

**Conclusions:** Otopathologic analysis of TBs from patients with a history of meningitic labyrinthitis demonstrated distinct peripheral vestibular changes. Future research may help to delineate potential mechanisms for the observed otopathologic changes following meningitis.

**Level of Evidence:** N/A

**KEYWORDS**

meningitis, otopathology, Scarpa ganglion neurons, spiral ganglion neurons, temporal bone, vestibular changes

This is an open access article under the terms of the Creative Commons Attribution-NonCommercial-NoDerivs License, which permits use and distribution in any medium, provided the original work is properly cited, the use is non-commercial and no modifications or adaptations are made.

© 2020 The Authors. *Laryngoscope Investigative Otolaryngology* published by Wiley Periodicals, Inc. on behalf of The Triological Society.

## 1 | INTRODUCTION

Meningitis is a major cause of mortality and morbidity worldwide.<sup>1</sup> It is estimated that the incidence of bacterial meningitis is about 0.8-2.6 per 100,000 adults in developed countries.<sup>2-4</sup> The most common causative microorganisms are the *Haemophilus influenzae* type B (Hib), *Streptococcus pneumoniae*, and *Neisseria meningitidis*.<sup>3,5</sup> The overall incidence of bacterial meningitis as well as its morbidity has decreased due to the introduction of vaccines, implementation of effective antibiotic and steroid therapy, and modern intensive care facilities.<sup>1,2,4</sup> Despite improved outcomes, meningitis remains an important public health issue, especially in developing nations.<sup>1,2,4,6,7</sup> Worse, it can increase its incidence and transmissibility when families decide not to vaccinate their children.<sup>8</sup>

Sensorineural hearing loss (SNHL) may affect up to 54% of survivors following meningitis.<sup>1,2,4,5,9</sup> Likewise, vestibular dysfunction also occurs frequently and is nearly universal in those with SNHL.<sup>10,11</sup> Previous otopathological studies have suggested that SNHL following meningitis occurs due to the spread of the infection from the meninges to the labyrinth via three routes, including (a) the cochlear aqueduct and the cochlear modiolus (meningogenic), (b) the vascular support of the inner ear (hematogenic), or (c) the oval and round windows (tympanic routes).<sup>12-14</sup> Once in the labyrinth, inflammatory mediators may induce severe labyrinthitis and disrupt the blood-labyrinth barrier, resulting in hearing and vestibular loss.<sup>13-16</sup>

Despite research on peripheral auditory pathway damage, few studies have examined the peripheral vestibular system following meningitis.<sup>10,11,17,18</sup> It is estimated that 15% to 85% of children with SNHL following meningitis present with associated vestibular dysfunction.<sup>10,11,18</sup> Zingler et al reported bilateral vestibular dysfunction in 11% of patients with dizziness, in which 5% of the cases were caused by meningoencephalitis.<sup>18</sup> Symptoms of vertigo and dizziness may not be the best measures of the true prevalence of vestibular dysfunction following meningitis. Using objective assessments of vestibular end-organ testing, including horizontal canal function as measured by caloric stimulation, high-frequency rotation, and otolithic function as measured by vestibular evoked myogenic potential (VEMP), Cushing et al also demonstrated that vestibular function was compromised in children with SNHL after meningitis.<sup>10,11</sup> These vestibular end-organ deficits translated functionally into poor balance skills in this cohort.<sup>19</sup> Likewise, children with SNHL and vestibular and balance impairment due to meningitis who were rehabilitated with cochlear implants also demonstrated a higher rate of cochlear implant failure.<sup>20</sup> In an additional study, the poor cochlear implant performance was hypothesized to be due to their vestibular and balance impairments.<sup>21</sup>

To date, no otopathology study has systematically evaluated peripheral vestibular changes following meningogenic labyrinthitis. The specific aims of the paper are to (a) describe the histopathologic changes in the human inner ear in cases of meningitis, and (b) correlate pathologic changes within the vestibule and the cochlea.

## 2 | MATERIALS AND METHODS

### 2.1 | Subjects

The National Temporal Bone Hearing and Balance Pathology Resource Registry database were used to identify cases. The TB collection at the Massachusetts Eye and Ear Infirmary contains 2290 TBs from 1340 individuals with well documented clinical histories. The TB data is cataloged electronically and contains information for each specimen, including medical history, auditory and vestibular data, and an overview of histopathologic findings. The keywords related to meningitis, including labyrinthitis, meningoencephalitis, central nervous system infection, intracranial infection, and brain abscess were used for the database search. The inclusion and exclusion criteria are available in Table 1. The National Temporal Bone Hearing and Balance Pathology Resource Registry has a cohort of "normal" individuals without evidence of inner ear pathology beyond changes associated with aging. The controls for this study were recruited from this registry. Similar cohorts of normal patients have been studied at our institution for otopathologic studies.<sup>22-24</sup> To avoid counting bias and any potential differences between historical articles<sup>22-24</sup> and the present study, controls were manually counted.<sup>25</sup> Age-matched controls were randomly selected, within an interval of a decade for adults, and within an interval of 1 year for infants. The study was approved by the Massachusetts Eye and Ear Infirmary Institutional Review Board (196232-23).

### 2.2 | Histologic methods

TB specimens were removed for histologic analysis following a previously described methodology.<sup>26</sup> Briefly, the preparation for light microscopy included fixation in 10% formalin, decalcification in EDTA, dehydration with increasing concentration of alcohol, and embedding in celloidin. Temporal bones were sectioned at a thickness of 20  $\mu$ m in an axial plane, stained with hematoxylin and eosin, and mounted on glass slides.

**TABLE 1** Criteria used for patient selection

Inclusion
History of meningitis or central nervous system infection as documented in the donor's medical record
Exclusion
1. Auditory or vestibular dysfunction prior to meningitis, such as acute or chronic otitis media, otosclerosis, Meniere's disease, or SNHL;
2. History of middle or inner ear surgery, such as cochlear implantation;
3. Metastatic disease or chemotherapy and/or radiotherapy of the head and neck;
4. Past usage of any known ototoxic or vestibulotoxic drug; and
5. Severe postmortem changes, such as compression artifact or autolysis

## 2.3 | Quantification of Scarpa's ganglion neurons from the vestibular nerve

The peripheral vestibular neurons, also known as Scarpa's ganglion neurons (ScGNs), of the superior and inferior vestibular nerves within the internal auditory canal, were quantified in serial axial sections as previously described.<sup>27</sup> Each ganglion cell nucleus contains a single nucleolus. The nucleoli were counted in every stained section at a magnification of  $\times 400$ . The neurons were counted on horizontal serial sections, superiorly to inferiorly, in which the numbers (a) increased to a maximum representing the central area of the superior division, then (b) decreased to a minimum designated as the boundary between the superior and inferior divisions of the ganglion, and (c) finally increased again as the main bulk of the inferior division is reached. A correction factor of 0.88 was used to avoid double counting of nucleoli. The percentage loss was calculated by comparison with normative data<sup>22</sup> and categorized into four groups based on severity: none (ie, no loss of ScGNs), mild loss ( $\leq 33\%$ ), moderate loss ( $>33\%$  to  $\leq 67\%$ ), and severe loss ( $>67\%$  to 100%).

## 2.4 | Evaluation of vestibular sensory epithelium of otolith organs and semicircular canals

The otolith organs and the semicircular canals were evaluated and analyzed by individuals trained in otopathology techniques (H.F.P., R.M.K., A.K.R., J.B.N., and E.D.K.). The appearance of vestibular hair cells—type I (flask-shaped with spherical nucleus) and type II (cylindrical shaped with oval nucleus)—and the dendrites of the maculae of both otolithic organs (utricle and saccule) and the cristae of all three semicircular canals (superior, lateral, and posterior) were evaluated. The presence of endolymphatic hydrops in each vestibular organ, as well as the patency of the endolymphatic duct, were documented. Cochlear endolymphatic hydrops was defined as any convexity of the Reissner's membrane toward the scala vestibuli, and vestibular endolymphatic hydrops as any dilatation of vestibular membranes (saccular, utricular, or ampullary), as previously described.<sup>28,29</sup>

## 2.5 | Spiral ganglion neurons quantification

The Rosenthal's canal was reconstructed two-dimensionally and the spiral ganglion neurons (SGN) population was quantified along the Rosenthal's canal based on previously described methodologies.<sup>30-32</sup> The SGN populations were then compared with age-matched controls.<sup>30</sup> The SGN population was determined for each of the four segments and for the cochlea as a whole by multiplying the counts by a factor of 10 (to account the unmounted sections) and by a factor of 0.91 to avoid double counting.

## 2.6 | Assessment of the presence and location of labyrinthitis

The vestibular end-organs and the cochlea were assessed in every stained section at different magnifications looking for the three stages of labyrinthitis, as previously described by Xu et al.<sup>12</sup> The first stage (acute stage), is characterized by purulent effusion followed by serofibrinous precipitates within the perilymphatic spaces. The second stage (fibrous stage), shows marked fibroblastic proliferation and angiogenesis, and begins approximately 2 weeks after the onset of injury. The third stage (ossification) shows new bone formation. The presence of labyrinthitis ossificans associated with the round window membrane (RWM) was described following the grading system created by Kaya et al<sup>14</sup> as *grade I*—ossification limited to the RWM, *grade II*—ossification involves the whole RWM with less than half of the scala tympani, *grade III*—ossification involves the whole RWM and more than 50% of the scala tympani, and *grade IV*—ossification involves the whole RWM, more than 50% of the scala tympani and at least one other scala (the scala vestibuli and/or the scala media).

## 2.7 | Statistical analysis

The independent *t* test and the Mann-Whitney *U* test were used, as appropriate, with SPSS 24.0 software (SPSS Inc., Chicago, IL). To assess whether there was a correlation between the time from the diagnosis of meningitis to death and the number of remaining SGN and ScGN, Pearson's correlation coefficient was calculated. A *P*-value  $< .05$  was considered statistically significant.

# 3 | RESULTS

## 3.1 | Clinical history

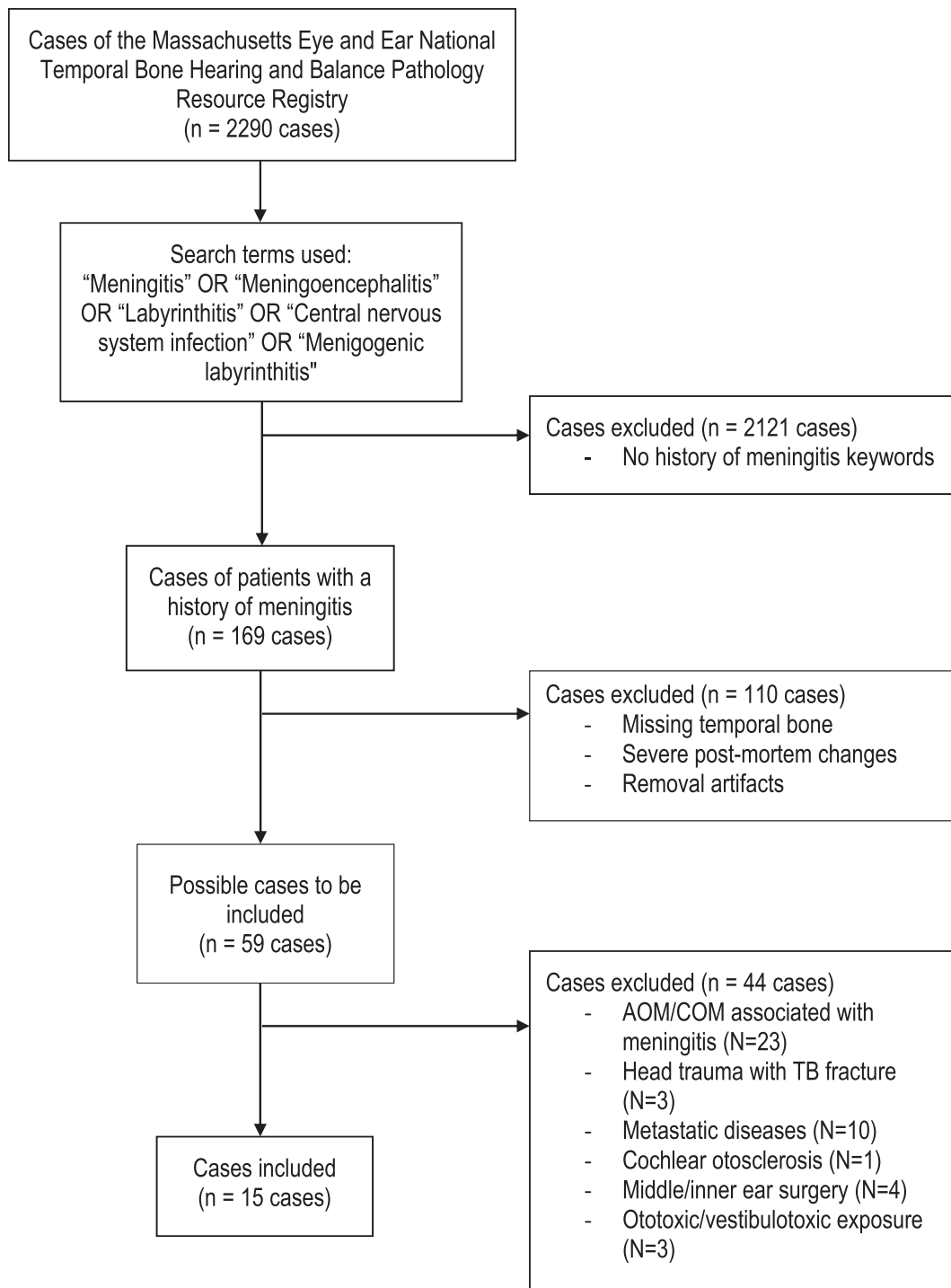
Fifteen TBs from 10 patients (9 male and 1 female) met the study criteria (Figure 1). Two cases (cases 5 and 6) had one TB excluded each due to cochlear implantation on that side after hearing loss following meningitis. The two contralateral ears were available and were included in our analysis. Out of the 59 possible cases, 44 were excluded for the following reasons: acute/chronic otitis media associated with meningitis ( $n = 23$ ), head trauma with TB fracture ( $n = 3$ ), metastatic disease to the head ( $n = 10$ ), the presence of cochlear otosclerosis ( $n = 1$ ), middle or inner ear surgery ( $n = 4$ ), and ototoxic/vestibulotoxic exposure ( $n = 3$ ). The mean age of death was  $28.8 \pm 30.8$  years (range, 15 days-78 years). The time from the diagnosis of meningitis to death ranged from 3 days to 52 years (mean,  $13.6 \pm 20.8$  years). Three cases (cases 1, 5, and 7) were diagnosed with meningococcal meningitis, and one case (case 6) was diagnosed with pneumococcal meningitis. The most severe changes within the inner ear were observed in case 6, which included labyrinthitis ossificans throughout the cochlea and vestibule. Additional

clinical details and etiology for each case are summarized in Table 2. We included 14 TBs from nine donors (7 male and 2 female) as normal controls for further analysis.

### 3.2 | Clinical audiovestibular findings

One patient (case 1) had a history of occasional tinnitus but no vertigo after meningitis; and one patient (case 10) had a history of frequent falls,

marked lateral gaze deviation, slow reflexes, and poor equilibrium and balance. These two cases (cases 1 and 10) had no vestibular testing results available. One patient (case 4) with no responses by either air or bone conduction on audiometric evaluation had diminished responses to ice-cold water caloric tests, but no description of vestibular symptoms. Profound hearing loss was reported in 5 out of the 10 patients (cases 1, 4, 5, 6, and 10), but only four of them had audiograms described in their medical charts. Deafness was stated in the medical records from case 10.



**FIGURE 1** Flow chart of the study population

**TABLE 2** Clinical data from patients with meningitis

Case	Side	Age of death	Sex	Etiologic agent	Age at time of meningitis	Time from meningitis to death
1	L	78 years	F	<i>Neisseria meningitidis</i>	55 years	23 years
2	R	4 years	M	<i>Haemophilus influenzae</i> type B	4 years	3 days
2	L	4 years	M	<i>Haemophilus influenzae</i> type B	4 years	3 days
3	R	15 days	M	<i>Proteus mirabilis</i>	6 days	9 days
3	L	15 days	M	<i>Proteus mirabilis</i>	6 days	9 days
4	R	56 years	M	Measles	4 years	52 years
4	L	56 years	M	Measles	4 years	52 years
5	L	72 years	M	<i>Neisseria meningitidis</i>	20 years	52 years
6	R	5 years	M	<i>Streptococcus pneumoniae</i>	1.5 year	3.5 years
7	L	3 months	M	<i>Neisseria meningitidis</i>	86 days	4 days
8 <sup>a</sup>	R	3 months	M	?	87 days	3 days
9	R	60 years	M	<i>Cryptococcus neoformans</i>	60 years	30 days
9	L	60 years	M	<i>Cryptococcus neoformans</i>	60 years	30 days
10	R	13 years	M	<i>Mycobacterium tuberculosis</i>	2.5 years	10.5 years
10	L	13 years	M	<i>Mycobacterium tuberculosis</i>	2.5 years	10.5 years

<sup>a</sup>Patient presented a history of lethargy, vomiting, fever, and nuchal rigidity. He was admitted and died 3 days later with a diagnostic of gram-negative septicemia secondary to meningitis.

Abbreviations: F, female; L, left; M, male; R, right.

**TABLE 3** Vestibular inner ear pathology

Demographic data			Hydrops		Degeneration of the membranous labyrinth				
					Otolith organ		Semicircular canal		
Case	Side	Age	Cochlea	Vestibular	Sacculle	Utricule	Superior	Lateral	Posterior
1	L	78 years	No	No	Mild	Mild	Mod	Mild	Mild
2	R	4 years	No	No	Normal	Normal	Normal	Normal	Normal
2	L	4 years	No	No	Normal	Normal	Normal	Normal	Normal
3 <sup>a</sup>	R	15 days	Yes <sup>b</sup>	Yes <sup>d</sup>	N/A	N/A	N/A	N/A	N/A
3 <sup>a</sup>	L	15 days	No	Yes <sup>d</sup>	N/A	N/A	N/A	N/A	N/A
4	R	52 years	No	No	Mod-Sev	Mod-Sev	Mod-Sev	Mod	Mod-Sev
4	L	52 years	Yes <sup>b</sup>	No	Mod-Sev	Mod-Sev	Mod-Sev	Mod	Mod-Sev
5	L	52 years	Yes	Yes <sup>d</sup>	Mod	Mild	N/A	Mod	Mod
6 <sup>c</sup>	R	5 years	N/A	N/A	N/A	N/A	N/A	N/A	N/A
7	L	3 months	No	No	Normal	Normal	Mild	Normal	Normal
8	R	3 months	No	No	Normal	Normal	Normal	Normal	Normal
9	R	60 years	No	No	Mild	Normal	Mild	Normal	Mild
9	L	60 years	Yes <sup>b</sup>	No	Mild	Normal	Mild	Mod	Mild
10	R	13 years	No	No	Normal	Mild	Normal	Normal	Normal
10	L	13 years	No	No	Mild	Mild	Normal	Normal	Normal

Abbreviations: L, left; Mod, moderate; Mod-Sev, moderate-severe; N/A, not available; Sev, severe.

<sup>a</sup>Severe postmortem autolysis of the vestibular epithelia.

<sup>b</sup>Limited to apical turn.

<sup>c</sup>Labyrinthitis ossificans throughout the inner ear.

<sup>d</sup>Presence of fibrous tissue and/or neo-ossification blocking the endolymphatic duct.

### 3.3 | Evaluation of vestibular sensory epithelium of otolith organs and semicircular canals

There was mild to severe degeneration of the cristae of the semicircular canals in cases 1, 4R, 4L, 5, 6, 7, 9R, and 9L (Table 3). Sacculle and utricle remnant otolithic membranes were identified in all cases. The macula of the utricle and sacculle showed mild to severe degeneration in cases 1, 4R, 4L, 5, 6, 9R, 9L, 10R, and 10L. The macula of the otolith organs was considered to be normal in cases 2R, 2L, 7, and 8. Unfortunately, otolithic particles (otoconia) are usually lost during the EDTA decalcification process for histologic preparation, and it was not possible to comment on the appearance of the otolithic membrane. Furthermore, none of the cases demonstrated fragmented otolith particles (otoconia) in the semicircular canals.

Vestibular endolymphatic hydrops was observed in cases 3R, 3L, and 5. Partial blockage of the endolymphatic duct due to neo-ossification and/or fibrous tissue was observed in cases 3R, 3L, 5, 6, 7, and 9R. None of the cases showed signs of enlarged vestibular aqueduct (EVA), perilymphatic fistula, or superior semicircular canal dehiscence. None of the control specimens had histopathological abnormalities, including endolymphatic hydrops, inflammatory cells, or membranous labyrinth degeneration beyond those associated with aging.

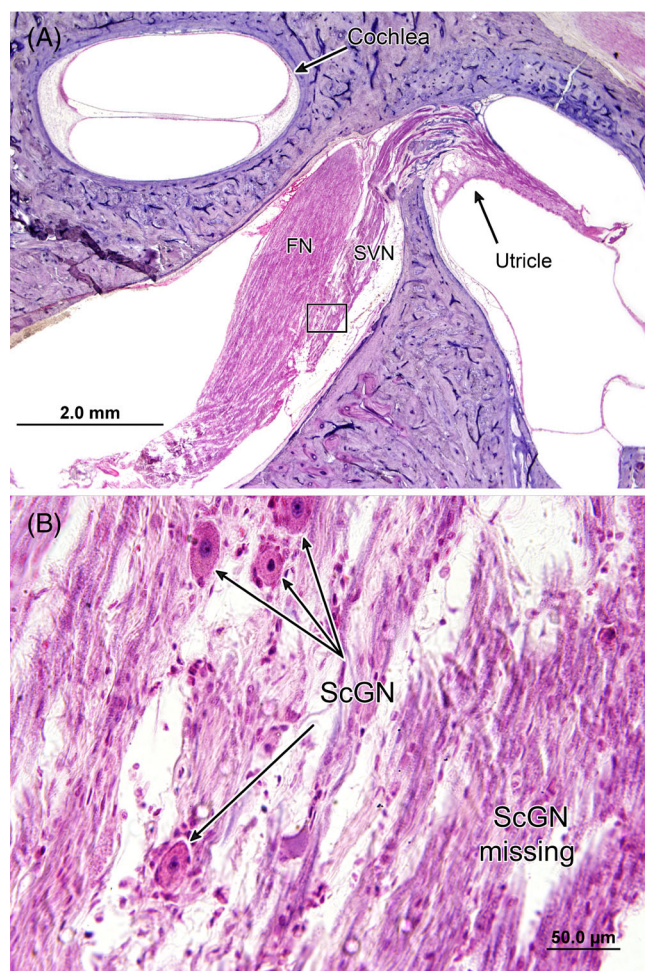
### 3.4 | Quantification of Scarpa's ganglion neurons of the vestibular nerve

Quantification of ScGN was possible in 13 TBs. The vestibular nerve was absent in two cases (Cases 4L and 5L) in the internal auditory canal, which may have occurred by avulsion at the time of the TB extraction process. Therefore, quantification of ScGN in these cases was not possible. There was mild to severe atrophy of the superior and inferior vestibular nerves in 13 of the 15 (86.7%,  $P = .077$ ,  $t$  test) TBs (Figure 2). There was an average loss of 21.2% (range, 6.0%-45.0%) in the inferior vestibular nerve and an average loss of 14.6% (range, 3.0%-48.0%) in the superior vestibular nerve of ScGNs compared to age-matched controls ( $P = .01$ ,  $t$  test, and  $P = .523$ ,  $t$  test, respectively; Table 4, Figure 3).

### 3.5 | Spiral ganglion neurons quantification

Reduced population of SGN was found in all cases, with an average loss of 45.0% (range, 25.3%-80.9%) vs age-matched controls (Figure 4). The SGN loss along all segments of the Rosenthal's canal (I-IV) was evenly distributed (Table 3).

The total number of SGN was significantly reduced in the meningitis cases compared to age-matched controls (mean of 16 192.2 and 26 895.6, respectively;  $P < .001$ ,  $t$  test). When analyzed by segment, there was also a decreased number of SGN in segment I in the meningitis cases compared to age-matched controls (mean of 2086.4 and 3805.0, respectively;  $P = .003$ , Mann-Whitney  $U$  test); in segment II



**FIGURE 2** Low and high-power views of case 4R. (A) Photomicrograph of a representative area containing the cochlea, the vestibule, and the internal auditory canal (IAC). (B) High-power view photomicrograph from the highlighted area from (A) shows moderate atrophy of the superior vestibular nerve (SVN), with a decreased number of ScGN. Abbreviations: FN, facial nerve; ScGN, Scarpa's ganglion neurons

(mean of 6420.8 and 10 159.9, respectively;  $P = .003$ ,  $t$  test); in segment III (mean of 3893.2 and 6399.4, respectively;  $P < .001$ ,  $t$  test); and in segment IV (mean of 3791.7 and 6531.3;  $P < .001$ ,  $t$  test). The time from diagnosis of meningitis to death was negatively correlated with the total number of remaining SGN ( $P = .038$ ;  $r = -.540$ ) and total counts of ScGN ( $P = .079$ ;  $r = -.504$ ). Similar correlation was found when analyzing by segment for segment I ( $P = .027$ ;  $r = -.570$ ) and segment IV ( $P = .023$ ;  $r = -.580$ ).

### 3.6 | Assessment of the presence and location of labyrinthitis

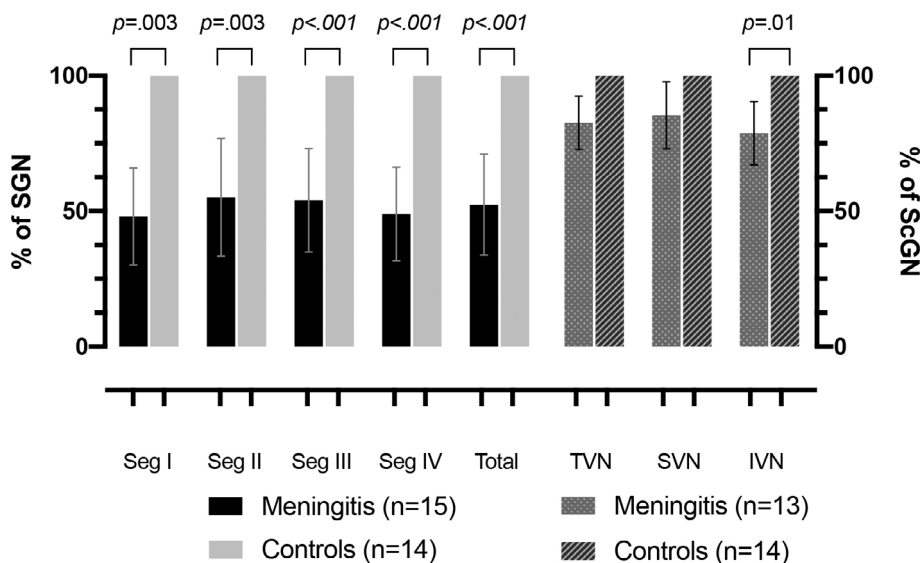
Notably, the presence of few to abundant inflammatory cells (macrophages, lymphocytes, or monocytes) was seen in the internal auditory canal in 8 TBs (53.3%). There was also presence of lymphocytes in the

**TABLE 4** ScGN and SGN counts of cases vs age-matched controls

Case	Side	ScGN (%)			SGN (%)				
		Total	SVN	IVN	Total	Segment I	Segment II	Segment III	Segment IV
1	L	90	86	94	65	76	75	52	54
2	R	77	93	55	52	43	50	51	62
2	L	85	96	71	65	76	75	52	54
3	R	73	66	83	63	67	54	71	69
3	L	65	63	69	58	64	58	63	50
4	R	53	52	55	63	67	54	71	69
4	L	NA	NA	NA	58	64	58	63	50
5	L	NA	NA	NA	75	73	93	75	47
6	R	89	80	100	70	62	79	69	61
7	L	85	88	80	75	73	93	75	47
8	R	97	100	82	70	62	79	69	61
9	R	81	90	68	37	8	31	50	48
9	L	92	97	86	19	22	19	19	18
10	R	94	96	91	37	8	31	50	48
10	L	93	96	88	19	22	19	19	18

For cases 4L and 5L, vestibular nerves were avulsed during the temporal bone removal.

Abbreviations: IVN, inferior vestibular nerve; L, left; NA, not applicable; ScGN, Scarpa's ganglion neurons; SGN, spiral ganglion neurons; SVN, superior vestibular nerve.



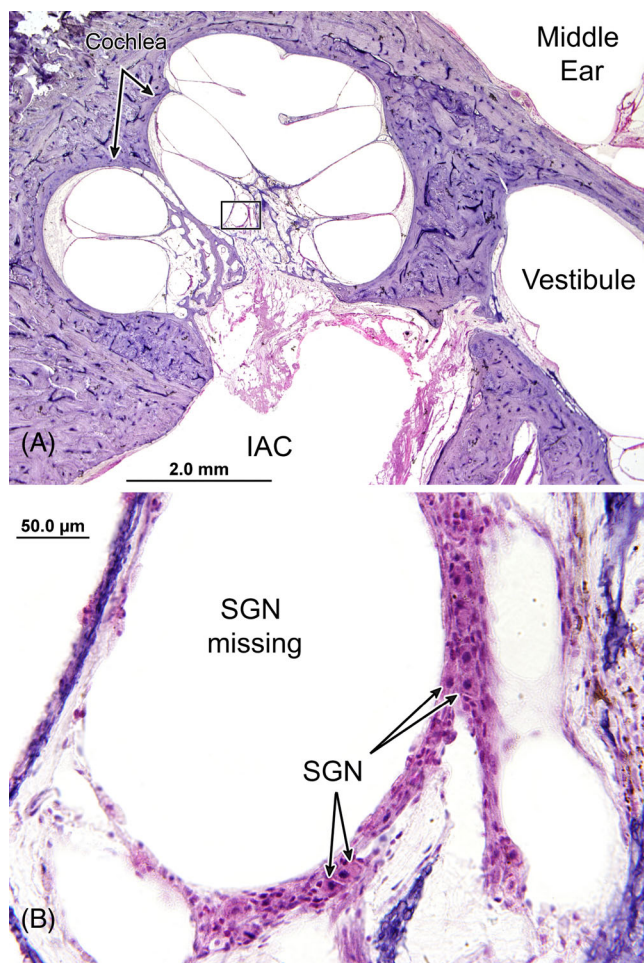
**FIGURE 3** Bar graph of mean spiral ganglion neurons count, for the total counting and in the four segments of the Rosenthal's canal [on the left], Scarpa's ganglion neurons count, for the total counting, the superior vestibular nerve, and the inferior vestibular nerve [on the right] in both meningitis and control groups. Error bars indicate standard deviations. Abbreviations: IVN, inferior vestibular nerve; ScGN, Scarpa's ganglion neurons; SGN, spiral ganglion neurons; Seg I, segment I of the Rosenthal's canal; Seg II, segment II of the Rosenthal's canal; Seg III, segment III of the Rosenthal's canal; Seg IV, segment IV of the Rosenthal's canal; SVN, superior vestibular nerve; TVN, total counting of the vestibular nerve

cochlear aqueduct in 3 TBs (20.0%), and in the vestibular aqueduct in 2 TBs (13.0%). Additionally, cryptococcal infection was seen within the internal auditory canal and modiolus in 2 TBs (13.0%)—cases 9R and 9L. Of the 15 TBs in the meningitis group, one (case 5) had grade II ossification; and one (case 6), grade IV ossification (Figure 5). These same cases presented inflammatory cells and new bone formation within the vestibular system: in the ampullated and nonampullated ends of the lateral semicircular canal, utricle, and saccule (case 5); throughout the vestibule and semicircular canals (case 6; Figure 5). All the remaining TBs had no ossification within the inner ear. We found

no differences in all parameters, including quantification of ScGNs and SGN, evaluation of the vestibular sensory epithelium, and the presence and location of labyrinthitis, between TBs from the same donors when both TBs were available for comparison.

#### 4 | DISCUSSION

The current otopathology study investigated a series of human TBs from individuals with a history of meningitis and is the first, to the

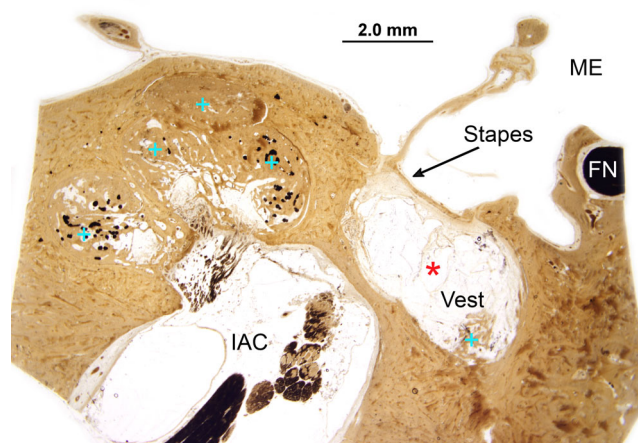


**FIGURE 4** Low and high-power views of case 4R. (A) Photomicrograph shows a representative area of the modiolus with absent spiral ganglion neurons (SGNs). (B) High-power view photomicrograph view of the modiolus with a large area with no SGNs and a thin area with some remaining neurons (arrows). Abbreviations: IAC, internal auditory canal

best of our knowledge, to describe simultaneous pathologic changes within the vestibule and the cochlea. Major findings included mild degeneration of ScGNs and mild to severe degeneration of SGNs. The TBs had on average 82.0% of the total number of ScGNs and 55.1% of the total number of SGNs as compared to age-matched controls.

A previous study documented the distribution of inflammatory cells (ie, polymorphonuclear leukocytes) in 20 TBs with meningogenic labyrinthitis.<sup>9</sup> The cells were confined almost exclusively to the perilymphatic compartment. The scala tympani and scala vestibuli were affected in 100.0% and 50.0% of the TBs, respectively. Meanwhile, the perilymphatic space of the vestibular organs was less affected. We found inflammatory cells in the internal auditory canal, cochlear aqueduct, and in the vestibular aqueduct in 53.3%, 20.0%, and 13.0%, respectively.

Previous otopathologic studies have shown that bacteria and inflammatory products may reach the inner ear either by the RWM, the internal auditory canal, and cochlear aqueduct or by vascular supply.<sup>33,34</sup> Polymorphonuclear invasion, fibrosis and/or angiogenesis,



**FIGURE 5** Low-power view of case 6R. Midmodiolar section of a right temporal bone from a 5-year-old child with extensive labyrinthitis ossificans after pneumococcal meningitis. Abbreviations: FN, facial nerve; IAC, internal auditory canal; ME, middle ear; Vest, vestibule. \*Areas of labyrinthitis ossificans within the cochlea and vestibule. \*Presence of inflammatory cells and fibrous tissue

osteoid deposition, and mineralization were described as early as 2 weeks to 2 months from the beginning of this process.<sup>2</sup> Different studies have demonstrated the location of new bone formation in TB with labyrinthitis ossificans.<sup>12,15,23,35-37</sup> Our findings are consistent with other studies that showed the presence of new bone formation beginning at the lower segments of the cochlea.<sup>9,38</sup> We were able to find new bone formation (close the RWM or throughout the cochlea) in two (13.3%) TBs. Merchant and Gopen<sup>9</sup> found inflammatory cells in 20 TBs with suppurative labyrinthitis in the perilymphatic space of the lateral, superior, and posterior semicircular canals (50.0%, 35.0%, and 30.0%, respectively), and vestibule (20.0%). In the present study, inflammatory cells were found within the internal auditory canal in 53.3% of the TBs, and new bone formation was seen among two cases (cases 5 and 6) in the vestibule and/or the semicircular canals. Additionally, the presence of inflammatory cells was observed in the cochlear aqueduct and vestibular aqueduct among 20.0% and 13.0%, respectively, of all TBs in this study. Merchant and Gopen's study showed inflammatory cells in the cochlear aqueduct lumen in 78.0% of TBs with suppurative labyrinthitis and no polymorphonuclear leukocytes in the endolymphatic sac or duct among their specimens.

We speculate that cochlear changes are more common than those changes in the vestibular system due to differences in the vascular supply, differences in the anatomy of the cochlear aqueduct and vestibular aqueduct, and immunological properties of the endolymphatic sac. First, the inner ear is supplied by the labyrinthine artery and its three branches: anterior vestibular artery, vestibulocochlear artery, and cochlear artery (that sometimes supplies the entire cochlea and is said to be the dominant vessel for the cochlea).<sup>39</sup> However, the cochlear artery radiates from the modiolus to supply the spiral ganglions, the organ of Corti, and the stria vascularis, while all the remaining inner ear structures are supplied by the anterior vestibular artery and the posterior vestibular artery—another branch of the vestibulocochlear artery.<sup>40</sup>



Therefore, it is plausible to assume that inflammatory cells may predominantly reach the cochlea due to its vascular pathway. Second, there is evidence that infection initially reaches the inner ear structures through the cochlear aqueduct and modiolus, then advances through the endolymphatic duct and reaches the endolymphatic sac.<sup>9,17</sup> The endolymphatic sac is the primary immunological organ of the inner ear. It provides defense against pathogens and contributes to a secondary immunologic response due to its reminiscent mucosa-associated lymphoid tissue (MALT).<sup>17</sup> Additionally, although the utriculoendolymphatic valve (also known as Bast's valve) is thought to control the flow of endolymph toward the endolymphatic duct and the endolymphatic sac,<sup>41-43</sup> there is no evidence to date that it could work as a route or protective barrier to the infection. However, it may act as protective mechanism against any fluctuations in the pressure of endolymph caused by labyrinthitis. Finally, it is possible that the specific origin of infection may differentially influence its impact on the labyrinth.

Despite antibacterial therapy and supportive intensive care, nearly half of survivors of meningitis suffer from long-term sequelae.<sup>44</sup> Most studies focus on cochlear changes, since the prevalence of SNHL is close to 54% after meningitis.<sup>1,2,4,5,9,17</sup> As described previously, infection reaches the perilymphatic spaces causing a reactive immune response and damage to the inner ear structures, such as the organ of Corti or the SGN, resulting in SNHL.<sup>44</sup> Meningitis caused by *S. pneumoniae* is the most common form of bacterial meningitis, and it is of particular interest to otologists due to its association with purulent otitis media in 20% to 30% of cases, which may result in hearing loss in up to 30% of survivors.<sup>38,45,46</sup> Douglas et al reported that *S. pneumoniae* was associated with more severe labyrinthitis ossificans when the degree of cochlear ossification was determined by the depth of insertion of the cochlear implant electrode.<sup>47</sup> The only case of pneumococcal meningitis included in this study had the most severe changes, with the cochlea, vestibule, and the three semicircular canals completely filled with new bone formation. Previous studies have demonstrated degeneration of the SGN predominantly at the basal turn of the cochlea in cases of pneumococcal meningitis.<sup>38,48-50</sup>

Meningitis caused by measles, *Cryptococcus neoformans*, and *Mycobacterium tuberculosis* were also identified. Hearing loss caused by measles is related to range from 0.1% to 3.4%.<sup>51</sup> Harada et al demonstrated loss of SGN in Rosenthal's canal, atrophy of the organ of Corti, but found that the vestibular nerve was free from pathology in a case of cryptococcal meningitis.<sup>52</sup> In another TB study from a case of tuberculous meningitis, Kuan et al found inflammatory changes in the internal auditory canal, modiolus and Rosenthal's canal (whereas the perilymphatic spaces were less involved) and degeneration of the organ of Corti, cochlear nerve fibers and SGN (particularly in the basal and middle turns).<sup>53</sup>

The gold standard treatment for severe to profound bilateral SNHL is cochlear implantation.<sup>44,54-60</sup> Its efficacy depends on multiple factors, including cognitive measures, proper surgical insertion, and duration of deafness.<sup>44,54-59</sup> Moreover, although a critical number of remaining SGN is necessary to achieve proper functioning of cochlear implants,<sup>54</sup> meningitis is known to cause a dramatic SGN loss resulting in limited satisfactory outcomes.<sup>9,16,23</sup> Merchant and Gopen<sup>9</sup> and

Nadol and Hsu<sup>23</sup> found degeneration of SGN in 12.0% and 16.6% of TBs in cases of meningitis, respectively. In our sample, degeneration of the SGN was found in 20.0% of cases. This difference may be related to the differences in inclusion criteria, as patients suffering from acute bacterial meningitis or whose death occurred directly from meningitis (acute stage) were included in their studies. Interestingly, only a few studies have compared cochlear changes to vestibular end-organ changes after meningitis, and mostly via radiological evaluation.<sup>37,60</sup>

While beyond the scope of the current paper, recent studies have suggested vestibular implantation as a promising procedure to restore vestibular function in patients with disabling bilateral vestibular deficits.<sup>61,62</sup> Vestibular implants consist of an array of electrodes that is introduced by an extralabyrinthine or intralabyrinthine surgical approach to electrically stimulate the ampullary nerves.<sup>59</sup> The first vestibular implantation procedure was performed in 2007, and since then, many efforts have been made to develop balance function, adaptive capacities of the brain, and processes of temporal integration for equilibrium with such devices.<sup>63</sup> It is unknown if a vestibular implant would provide meaningful rehabilitation following meningitis, and additional studies are needed. Furthermore, given findings of ossification, it is unknown if technical implantation would be possible, similar to challenges of cochlear implantation following meningitis. At the current time, most patients with bilateral vestibular weakness improve with physical therapy targeting vestibular rehabilitation.<sup>64</sup>

This study has several limitations. First, the sample was relatively small. Second, the time from meningitis to death varied among cases. Unknown factors between time of infection and death could have affected the histopathologic changes found in the present study. Lastly, lack of documented evaluations of vestibular symptoms and function testing made it difficult to interpret whether histopathologic changes translated into clinical vestibular symptoms.

In summary, otopathological changes were found in the peripheral vestibular system of patients with a history of meningitis, although the changes were less severe than those observed in the cochlea. The present study provides a unique analysis of human TB specimens that may help elucidate the pathophysiology of both vestibular and cochlear dysfunction following meningitis infection. Future prospective research may better delineate the association of histologic findings to meningitic labyrinthitis and vestibular and cochlear dysfunction.









## 5 | CONCLUSION

Otopathologic analysis of patients with meningitic labyrinthitis demonstrated peripheral vestibular changes. Future research may help delineate potential mechanisms for observed otopathologic differences following meningitis with the aim to improve both acute treatments and chronic rehabilitation in these individuals.

## ACKNOWLEDGMENTS

We would like to thank Barbara Burgess, Diane Jones, Jenifer O'Malley, and Meng Yu Zhu for their skillful histologic preparation of the specimens.

## ORCID

Henrique F. Pauna  <https://orcid.org/0000-0002-5575-7030>  
 Renata M. Knoll  <https://orcid.org/0000-0002-5533-4118>  
 Rory J. Lubner  <https://orcid.org/0000-0001-9884-2799>  
 Jacob R. Brodsky  <https://orcid.org/0000-0001-9656-5855>  
 Miguel A. Hyppolito  <https://orcid.org/0000-0001-9688-782X>  
 Joseph B. Nadol Jr  <https://orcid.org/0000-0002-4033-3104>  
 Aaron K. Remenschneider  <https://orcid.org/0000-0003-0989-6264>  
 Elliott D. Kozin  <https://orcid.org/0000-0002-0305-0682>

## BIBLIOGRAPHY

- Smith AW, Bradley AK, Wall RA, et al. Sequelae of epidemic meningococcal meningitis in Africa. *Trans R Soc Trop Med Hyg.* 1988;82(2):312-320.
- Lucas MJ, Brouwer MC, van de Beek D. Neurological sequelae of bacterial meningitis. *J Infect.* 2016;73(1):18-27.
- Kim KS. Acute bacterial meningitis in infants and children. *Lancet Infect Dis.* 2010;10(1):32-42.
- Xu M, Hu L, Huang H, et al. Etiology and clinical features of full-term neonatal bacterial meningitis: a multicenter retrospective cohort study. *Front Pediatr.* 2019;7:31.
- Swanson D. Meningitis. *Pediatr Rev.* 2015;36(12):514-524.
- Wahl B, Sharan A, Knoll MD, et al. National, regional, and state-level burden of *Streptococcus pneumoniae* and *Haemophilus influenzae* type b disease in children in India: modelled estimates for 2000-15. *Lancet Glob Health.* 2019;7:e735-e747.
- Tsolenyano E, Bancroft RE, Sesay AK, et al. Etiology of pediatric bacterial meningitis pre- and post-PCV13 introduction among children under 5 years old in Lomé, Togo. *Clin Infect Dis.* 2019;69(Suppl 2):S97-S104.
- Tin Tin Htar M, van den Biggelaar AHJ, Sings H, et al. The impact of routine childhood immunisation with higher-valent pneumococcal conjugate vaccines on antimicrobial-resistant pneumococcal diseases and carriage: a systematic literature review. *Expert Rev Vaccines.* 2019;18:1069-1089. <https://doi.org/10.1080/14760584.2019.1676155>.
- Merchant SN, Gopen Q. A human temporal bone study of acute bacterial meningogenic labyrinthitis. *Am J Otol.* 1996;17(3):375-385.
- Cushing SL, Gordon KA, Rutka JA, James AL, Papsin BC. Vestibular end-organ dysfunction in children with sensorineural hearing loss and cochlear implants: an expanded cohort and etiologic assessment. *Otol Neurotol.* 2013;34(3):422-428.
- Cushing SL, Papsin BC, Rutka JA, James AL, Blaser SL, Gordon KA. Vestibular end-organ and balance deficits after meningitis and cochlear implantation in children correlate poorly with functional outcome. *Otol Neurotol.* 2009;30(4):488-495.
- Xu HX, Joglekar SS, Paparella MM. Temporal bone histopathology case of the month: Labyrinthitis ossificans. *Otol Neurotol.* 2009;30:579-580.
- Nichani J, Green K, Hans P, Bruce I, Henderson L, Ramsden R. Cochlear implantation after bacterial meningitis in children: outcomes in ossified and nonossified cochleas. *Otol Neurotol.* 2011;32(5):784-789.
- Kaya S, Paparella MM, Cureoglu S. Pathologic findings of the cochlea in labyrinthitis ossificans associated with the round window membrane. *Otolaryngol Head Neck Surg.* 2016;155(4):635-640.
- Tokat T, Catli T, Bayrak F, Bozkurt EB, Olgun L. Cochlear implantation in postmeningitic deafness. *J Craniofac Surg.* 2018;29(3):e245-e248.
- Juhn SK, Hunter BA, Odland RM. Blood-labyrinth barrier and fluid dynamics of the inner ear. *Int Tinnitus J.* 2001;7(2):72-83.
- Møller MN, Brandt C, Østergaard C, Caye-Thomasen P. Endolymphatic sac involvement in bacterial meningitis. *Eur Arch Otorhinolaryngol.* 2015;272(4):843-851.
- Zingler VC, Cnyrim C, Jahn K, et al. Causative factors and epidemiology of bilateral vestibulopathy in 255 patients. *Ann Neurol.* 2007;61(6):524-532.
- Cushing SL, Chia R, James AL, Papsin BC, Gordon KA. The vestibular Olympics: a test of dynamic balance function in children with cochlear implants. *Arch Otol Head Neck Surg.* 2008;134(1):34-38.
- Eskander A, Gordon KA, Kadhim L, et al. Low pediatric cochlear implant failure rate: contributing factors in large-volume practice. *Arch Otolaryngol Head Neck Surg.* 2011;137(12):1190-1197.
- Wolter NE, Gordon KA, Papsin BC, Cushing SL. Vestibular and balance impairment contributes to cochlear implant failure in children. *Otol Neurotol.* 2015;36(6):1029-1034.
- Velázquez-Villaseñor L, Merchant SN, Tsuji K, Glynn RJ, Wall C 3rd, Rauch SD. Temporal bone studies of the human peripheral vestibular system. Normative Scarpa's ganglion cell data. *Ann Otol Rhinol Laryngol Suppl.* 2000;181:14-19.
- Nadol JB Jr, Hsu WC. Histopathologic correlation of spiral ganglion cell count and new bone formation in the cochlea following meningogenic labyrinthitis and deafness. *Ann Otol Rhinol Laryngol.* 1991;100(9 Pt 1):712-716.
- Schuknecht HF. Surgical pathology: cochlear implantation. In: Merchant SN, Nadol JB, eds. *Schuknecht's Pathology of the Ear.* Shelton, CT: People's Medical Publishing House; 2010:842-850.
- Knoll RM, Ishai R, Lubner RJ, et al. (in press). Peripheral vestibular organ degeneration after temporal bone fracture: a human otopathology study. *Laryngoscope.* 2019. <https://doi.org/10.1002/lary.28010>.
- Schuknecht H. Temporal bone removal at autopsy. Preparation and uses. *Arch Otolaryngol.* 1968;87(2):129-137.
- Knoll RM, Ishai R, Trakimas DR, et al. Peripheral vestibular system histopathologic changes following head injury without temporal bone fracture. *Otolaryngol Head Neck Surg.* 2019;160(1):122-130.
- Kaya S, Tsuprun V, Hizli Ö, Paparella MM, Cureoglu S. Quantitative assessment of cochlear histopathologic findings in patients with suppurative labyrinthitis. *JAMA Otolaryngol Head Neck Surg.* 2016;142(4):364-369.
- Rauch SD, Merchant SN, Thedinger BA. Ménière's syndrome and endolymphatic hydrops: a double-blind temporal bone study. *Ann Otol Rhinol Laryngol.* 1989;98:873-883.
- Otte J, Schuknecht HF, Kerr AG. Ganglion cell populations in normal and pathological human cochleas. Implications for cochlear implantation. *Laryngoscope.* 1978;88(8 Pt 1):1231-1246.
- Nadol JB Jr. Quantification of human spiral ganglion cells by serial section reconstruction and segmental density estimates. *Am J Otolaryngol.* 1988;9(2):47-51.
- Robert ME, Linthicum FH Jr. Empirical derivation of correction factors for human spiral ganglion cell nucleus and nucleolus count units. *Otolaryngol Head Neck Surg.* 2016;154(1):157-163.
- Paparella MM, Sugiura S. The pathology of suppurative labyrinthitis. *Ann Otol Rhinol Laryngol.* 1967;76(3):554-586.
- Goycoolea MV, Paparella MM, Goldberg B, Carpenter AM. Permeability of the round window membrane in otitis media. *Arch Otolaryngol.* 1980;106(7):430-433.
- Nabili V, Brodie HA, Neverov NI, Tinling SP. Chronology of labyrinthitis ossificans induced by *Streptococcus pneumoniae* meningitis. *Laryngoscope.* 1999;109(6):931-935.
- Caye-Thomasen P, Dam MS, Omland SH, Mantoni M. Cochlear ossification in patients with profound hearing loss following bacterial meningitis. *Acta Otolaryngol.* 2012;132(7):720-725.
- Young NM, Hughes CA, Byrd SE, Darling C. Postmeningitic ossification in pediatric cochlear implantation. *Otolaryngol Head Neck Surg.* 2000;122(2):183-188.
- Perny M, Roccio M, Grandgirard D, Solyga M, Senn P, Leib SL. The severity of infection determines the localization of damage and extent of sensorineural hearing loss in experimental pneumococcal meningitis. *J Neurosci.* 2016;36(29):7740-7749.

39. Mei X, Atturo F, Wadin K, et al. Human inner ear blood supply revisited: the Uppsala collection of temporal bone-an international resource of education and collaboration. *Ups J Med Sci.* 2018;123(3):131-142.
40. Baloh RW, Honrubia V. Clinical neurophysiology of the vestibular system. *Contemp Neurol Ser.* 1979;18:1-21.
41. Schuknecht HF, Belal AA. The utriculo-endolymphatic valve: its functional significance. *J Laryngol Otol.* 1975;89(10):985-996.
42. Hofman R, Segenhout JM, Buytaert JAN, Dirckx JJJ, Wit HP. Morphology and function of Bast's valve: additional insight in its functioning using 3D-reconstruction. *Eur Arch Otorhinolaryngol.* 2008;265:153-157.
43. Bachor E, Karmody CS. The utriculo-endolymphatic valve in pediatric temporal bones. *Eur Arch Otorhinolaryngol.* 1995;252:167-171.
44. Demel C, Hoegen T, Giese A, et al. Reduced spiral ganglion neuronal loss by adjunctive neurotrophin-3 in experimental pneumococcal meningitis. *J Neuroinflammation.* 2011;8(1):7.
45. Bohr V, Paulson OB, Rasmussen N. Pneumococcal meningitis late neurologic sequelae and features of prognostic impact. *Arch Neurol.* 1984;41(10):1045-1049.
46. Rasmussen N, Johnsen NJ, Bohr VA. Otologic sequelae after pneumococcal meningitis: a survey of 164 consecutive cases with a follow-up of 94 survivors. *Laryngoscope.* 1991;101(8):876-882.
47. Douglas SA, Sanli H, Gibson WPR. Meningitis resulting in hearing loss and labyrinthitis ossificans - does the causative organism matter? *Cochlear Implants Int.* 2008;9(2):90-96.
48. Subotić R. Histopathological findings in the inner ear caused by measles. *J Laryngol Otol.* 1976;90(2):173-181.
49. Igarashi M, Weber SS, Alford BR, Coats AC, Jerger J. Temporal bone findings in cryptococcal meningitis. *Arch Otolaryngol.* 1975;101(9):577-583.
50. Kuan CC, Kaga K, Tsuzuku T. Tuberculous meningitis-induced unilateral sensorineural hearing loss: a temporal bone study. *Acta Otolaryngol.* 2007;127(5):553-557.
51. Cohen BE, Durstenfeld A, Roehm PC. Viral causes of hearing loss: a review for hearing health professionals. *Trends Hear.* 2014;18:1-17.
52. Harada T, Sando I, Myers EM. Temporal bone histopathology in deafness due to cryptococcal meningitis. *Ann Otol Rhinol Laryngol.* 1979;88(5 Pt 1):630-636.
53. Kuan CC, Kaga K, Tsuzuku T. Tuberculous meningitis-induced unilateral sensorineural hearing loss: a temporal bone study. *Acta Otolaryngol.* 2007;127(5):553-557.
54. Nadol JB Jr, Young YS, Glynn RJ. Survival of spiral ganglion cells in profound sensorineural hearing loss: implications for cochlear implantation. *Ann Otol Rhinol Laryngol.* 1989;98(6):411-416.
55. Philippon DBF, Ferron P, Bussi eres R. Cochlear implantation in postmeningitic deafness. *Otol Neurotol.* 2010;31(1):83-87.
56. Fayad JN, Linthicum FH Jr. Multichannel cochlear implants: relation of histopathology to performance. *Laryngoscope.* 2006;116(8):1310-1320.
57. Khan AM, Handzel O, Burgess BJ, Damian D, Eddington DK, Nadol JB Jr. Is word recognition correlated with the number of surviving spiral ganglion cells and electrode insertion depth in human subjects with cochlear implants? *Laryngoscope.* 2005;115(4):672-677.
58. Seyyedi M, Eddington DK, Nadol JB Jr. Effect of monopolar and bipolar electric stimulation on survival and size of human spiral ganglion cells as studied by postmortem histopathology. *Hear Res.* 2013;302:9-16.
59. Durisin M, Buchner A, Lesinski-Schiedat A, Bartling S, Warnecke A, Lenarz T. Cochlear implantation in children with bacterial meningitic deafness: the influence of the degree of ossification and obliteration on impedance and charge of the implant. *Cochlear Implants Int.* 2015;16(3):147-158.
60. Johnson MHHM, Seicshnaydre MA, Williams GH. CT of postmeningitic deafness: observations and predictive value for cochlear implants in children. *Am J Neuroradiol.* 1995;16(1):103-109.
61. Perez Fornos A, Cavuscens S, Ranieri M, et al. The vestibular implant: a probe in orbit around the human balance system. *J Vestib Res.* 2017;27(1):51-61.
62. Guyot JP, Perez Fornos A. Milestones in the development of a vestibular implant. *Curr Opin Neurol.* 2019;32(1):145-153.
63. Rinne T, Bronstein AM, Rudge P, Gresty MA, Luxon LM. Bilateral loss of vestibular function: clinical findings in 53 patients. *J Neurol.* 1998;245(6-7):314-321.
64. Hain TC, Cherchi M, Yacovino DA. Bilateral vestibular weakness. *Front Neurol.* 2018;9:344.

**How to cite this article:** Pauna HF, Knoll RM, Lubner RJ, et al. Histopathological changes to the peripheral vestibular system following meningitic labyrinthitis. *Laryngoscope Investigative Otolaryngology.* 2020;5:256–266. <https://doi.org/10.1002/lio2.349>