

Editorial

The posterior cerebellum, a new organ at risk?



ARTICLE INFO

Article history:

Available online 23 November 2017

Keywords:

Neuro-oncology
 Delineation atlas
 Posterior cerebellum
 Radiotherapy
 Cognition
 Organ at risk

ABSTRACT

Eekers et al. have recently proposed a neuro-oncology atlas, which was co-authored by most centers associated in the European Proton Therapy Network (EPTN; Figure 1). With the introduction of new treatment techniques, such as integrated magnetic resonance imaging and linear accelerators (MR-linac) or particle therapy, the prediction of clinical efficacy of these more costly treatment modalities becomes more relevant. One of the side-effects of brain irradiation, being cognitive decline, is one of the toxicities most difficult to measure and predict. In order to validly compare different treatment modalities, 1) a uniform nomenclature of the organs at risk (OARs), 2) uniform atlas-based delineation [e.g., Eekers et al.], 3) long-term follow-up data with standardized cognitive tests, 4) a large patient population, and 5) (thus derived) validated normal tissue complication probability (NTCP) models are mandatory.

Apart from the Gondi model, in which the role of the dose to 40% of both hippocampi (HC) proves to be significantly related to cognition in 18 patients, no similar models are available. So there is a strong need for more NTCP models, on HC, brain tissue and possible other relevant brain structures. In this review we summarize the available evidence on the role of the posterior cerebellum as a possible new organ at risk for cognition, which is deemed relevant for irradiation of brain and head and neck tumors.

© 2017 The Authors. Published by Elsevier Ireland Ltd on behalf of European Society for Radiotherapy and Oncology. This is an open access article under the CC BY-NC-ND license (<http://creativecommons.org/licenses/by-nc-nd/4.0/>).

Introduction

Survival rates of brain tumors, including gliomas have improved by the use of multimodality therapy, with advances in surgery, radiation therapy, chemotherapy and radiological technology prior to and throughout the treatment [3,4]. As survival rates increase, awareness of long-term complications due to therapy raises as well, for children as well as adults [5]. One of these (long-term) complications following (radio)therapy is neurocognitive decline, which is marked by reduction of verbal memory, spatial processing, attention and novel problem solving ability [6]. This decline has been shown in survivors of pediatric brain tumors, treated with multimodal treatment schedules, who have lower rates on high school graduation and employment relative to the overall population [7].

Traditionally, the cerebral hemispheres are considered the regions of the brain responsible for cognitive function, while the cerebellum is known for its role in regulation and coordination in movement, posture and balance [8]. However, several clinical, anatomical and neuro-imaging studies have shown that the cerebellum may also play a role in neurocognition [9–11]. The aim of this review was to summarize the available evidence on role of the cerebellum in cognition and on the effects of radiation dose on the cerebellum in regard to neurocognitive function. Potentially, this will lead to new NTCP models, such as the Gondi [2] model, to

predict neurocognitive outcomes related to radiation dose in different brain structures. Delineation guidelines for anatomical structures relevant in neuro-oncology have recently been proposed by Eekers et al. [1] (Fig. 1).

Cognition and the cerebellum

Historical perspective

Until the 20th century, studies on cerebellar function primarily focused on motor function [12–14]. It is unclear why cerebellar involvement in cognition and language remained uninvestigated in that period, but this may be due to the subtlety of cognitive defects or the fact that motor function and cognitive function were investigated as two separate entities. In 1971 Prescott and Piaget [15] described that motor development is inherently connected to emotional and neurocognitive development. Children with motor development difficulties are often emotionally and cognitively challenged as well. Both development processes could be connected and cannot be studied separately. These new insights led to the theory that the cortex and cerebellum might be connected and that both regions may be involved in neurocognitive function. In 1978, Watson [16] was one of the first authors to suggest the possible role of the cerebellum in sensory processing, learning, affect and cognition. In current literature, evidence is mounting

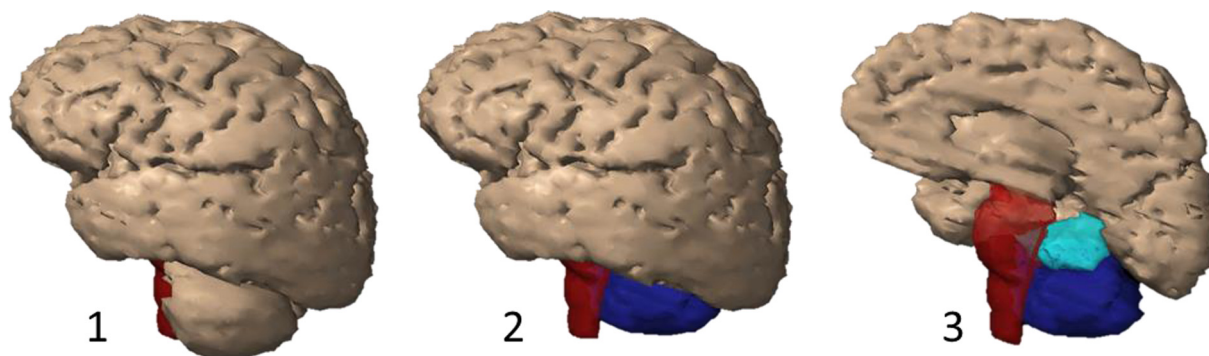


Fig. 1. 3D view of the Brain, brainstem, cerebellum posterior and anterior. Lateral view of a 3D-reconstruction on CT of: 1. Total brain (brown) and brainstem (red). 2. Brain (brown), brainstem (red), cerebellum posterior* (dark blue). 3. Right brain (brown), brainstem (red), right cerebellum anterior* (light blue) and right cerebellum posterior* (dark blue). *In accordance to Atlas for Neuro-Oncology (Eekers et al., submitted). (For interpretation of the references to colour in this figure legend, the reader is referred to the web version of this article.)

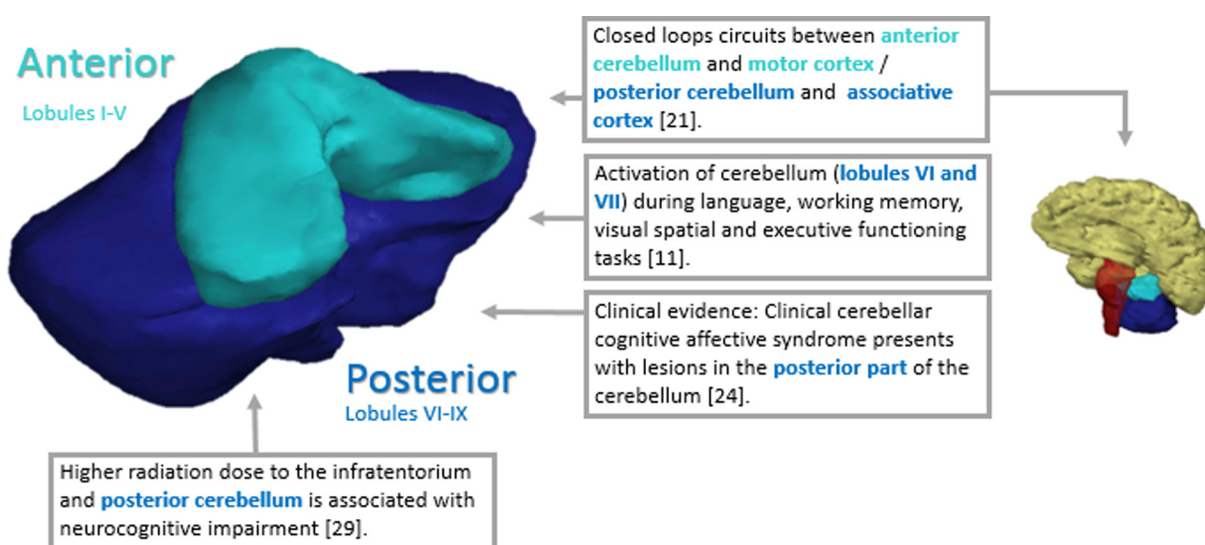


Fig. 2. Role of cerebellum in cognition.

to support this suggestion, even though many questions remain unanswered.

Anatomy of the cerebellum

The cerebellum consists of two hemispheres divided by the vermis. Both hemispheres are organized into ten lobules. Traditionally, the cerebellum has been recognized as having three anterior-posterior divisions [10]: the primary fissure separates the anterior lobe (lobules I–V) from the posterior lobe (lobules VI–IX) and the posterolateral fissure separates the posterior lobe from the flocculonodular lobe (lobule X). Two other approaches to divide the cerebellum are based upon functional (F) or phylogenetic (P) criteria. The vestibocerebellum (F) or archicerebellum (P) contains the flocculonodular lobe and immediately adjacent vermis. The spinocerebellum (F) or paleocerebellum (P) contains the vermis and intermediate parts of the vermis. The cerebrocerebellum (F) or neocerebellum (P) contains the lateral parts of the hemispheres [10].

There are four deep nuclei in the cerebellum, the dentate, emboliform, globose, and fastigial, which receive and send information to the specific parts of the brain. Most afferent cerebral

projections pass through the basal pontine nuclei and intermediate cerebellar peduncle, while most cerebello-cerebral efferent projections pass through dentate and ventral thalamic nuclei [17,18].

Cerebellum and the sensorimotor & associative cortex

In order to determine whether the cerebellum plays a role in cognition it is crucial to unravel whether there are anatomical connections between the cerebellum and regions of the brain with higher cognitive functions. As a matter of fact, multiple studies, including viral tract tracing methods and resting-state functional connectivity data, support the presence of reciprocal links between the cerebellum and the prefrontal and parietal association cortices via cerebello-thalamo-cortical and cortico-ponto-cerebellar loops [9–11,18–21]. These closed loop circuits provide topographically segregated connections between the cerebral cortex and the cerebellum [22,23]. Information from the primary motor cortex passes the caudal part of the brainstem and enters the anterior part of the cerebellum via pontocerebellar fibers through the intermediate peduncle. Information from associative cortices passes several points in the brain stem and enters the posterior part of the cerebellum via the intermediate peduncle [21]. In conclusion, the

primary motor cortex is predominantly connected to the anterior part of the cerebellum, whereas the associative cortices are predominantly connected to the posterior part of the cerebellum [10].

Cerebellum activation in cognitive tasks

Activation of the cerebellum in cognitive tasks has been found in multiple functional imaging studies. It is present during language, working memory, visual spatial and executive functioning tasks. Each domain and its matching tests have different activation patterns. Language-related activity is focused in lateral and posterior cerebellar regions, while working memory and reading tasks activate bilateral regions of the cerebellar posterior lobe, mainly lobules VI and VII. Functional imaging of affective processing, executive functioning and spatial processing highlights lobules VI and VII of the posterior cerebellar lobe. One of the first studies to describe this connection was published by Kim et al. [24] in 1994. The authors used magnetic resonance imaging (MRI) to examine the activation of the dentate nucleus of the cerebellum in seven healthy human volunteers during their attempts to solve a puzzle. All seven adult participants showed more bilateral activation of the dentate nucleus during more challenging neurocognitive tasks. Later on, multiple imaging studies followed and found similar results [10]. In general, cerebellar activation during cognitive tasks is found in conjunction with activation of prefrontal and parietal regions, supporting the concept that the cerebellum is part of these functional networks [10,11].

Cerebellum and cognition

Clinical evidence for cognitive functioning of the cerebellum can, e.g., be found in the clinical cerebellar cognitive affective syndrome (CCAS; Fig. 2). CCAS is a condition, which leads to deficits in cognitive functioning resulting from cerebellar damage. This syndrome has been described in both children and adults. Affected domains are executive function, spatial cognition, working memory, language and affect [25,26]. Depending on the location of the lesion, CCAS can be present in the absence of cerebellar motor syndrome, which is a syndrome that affects motor functions. The lesions that are associated with CCAS are situated in the posterior lobe of the cerebellum. Schmahmann and Pandya [19] were the first to describe this syndrome after studying 20 adults with cerebellar lesions due to either neoplasms, or vascular or traumatic damage. They all showed deficits in multiple cognitive domains as described above whilst maintaining semantic and episodic memory and consciousness. The latter deems cerebral damage as cause for these deficits unlikely. Lesions of the anterior lobe of the cerebellum produced only minor changes in executive and visual-spatial functions in contrary to the lesions in the posterior lobe. The constellation of deficits is suggestive of disruption in neural circuits connecting the cerebellum to prefrontal, posterior parietal, superior temporal, and limbic cortices [25,26].

Cuny et al. [27] recently published the cases of two siblings with small retrovermian arachnoid cysts. The 3-year-old children initially presented cerebellar signs and cognitive disorders with progressive worsening. Surgery was performed to relieve intracranial pressure in the posterior fossa. In both cases significant improvement was seen in the children's neurological and neuropsychological status during 3 years of follow-up.

Other clinical studies show specific neurocognitive domains can be affected by damage to specific regions of the cerebellum. It is reported that verbal expression impairments result from damage to the right cerebellar lobe, whereas spatial difficulties can arise from lesions in the left cerebellar lobe, damage to the midline vermis has been associated with deficits in social and affective processing [10,11,25,26].

Cerebellar volume and cognitive function

A large body of literature supports the hypothesis that cerebellar volume decreases with increasing age. It has been suggested that this has its effect on neurocognitive function as well. Hoogendam et al. [28] examined the correlation between cerebellar volume and neurocognitive function. They included 3745 individuals above the age of 45 years and found a minor non-significant relationship between larger cerebellar volume and better global cognition, executive function, information processing speed, memory and motor speed. Their findings support the notion that the cerebellar volume has an influence on decline of cognition in aging but it is not the predominant structure. Likewise, Weier et al. [29] examined 28 pediatric-onset relapsing-remitting Multiple Sclerosis patients, comparing their cerebellar volumes to a control group and found that while the volumes did not differ between groups, posterior cerebellar lobe volume and infra-tentorial lesion volume accounted for extra variance on measures of information processing and vocabulary. Many other studies support these findings and underline the hypothesis that the cerebellum has a function in neurocognitive functioning [30].

Radiation to the cerebellum

One of the most interesting studies on radiation to the cerebellum was published by Merchant et al. [31], separately delineating the cerebellum and dividing it into a posterior and anterior part according to the article of Schmahmann et al. [32]. Seventy-eight children with low-grade glioma were included, prior treatment with chemotherapy was allowed in this study and there was no limit for the interval first surgery until irradiation (54–59.4 Gy), baseline and serial evaluations were performed to assess cognitive outcomes [31]. They found a statistically significant correlation between the radiation dose to the infratentorium and posterior cerebellum and neurocognitive impairment at several cognitive domains. To date, this is the only available study with separate dosimetric data for the posterior cerebellum. Noteworthy, one of the limitations of that study was the absence of a control group. Rønning et al. [33] compared an only surgically treated pediatric patient cohort with astrocytoma (n = 12) to a pediatric cohort with medulloblastoma (n = 10), who had been treated with surgery followed by radio(chemo)therapy. Both the astrocytoma and medulloblastoma groups scored below the standard norms regarding motor speed, attention and executive function. The medulloblastoma group, however, performed worse than the astrocytoma group on the following neuropsychological measures: intelligence, motor function, speed processing, verbal and visual memory. Since the astrocytoma group was treated with surgery alone, cerebellar lesions were held responsible for neurocognitive decline. The fact that the medulloblastoma cohort was more affected may be explained by several factors including the underlying malignancy and the use of radiotherapy [33]. Gan et al. [34] assessed a group of ten adult patients treated with (intensity modulated) radio(chemo)therapy for squamous cell cancer of the head and neck. The authors delineated several brain structures separately, including temporal lobes and cerebellum, and performed neurocognitive function tests before and after treatment. The study population scored well on IQ but mean scores for all cognitive domains, except language and global cognitive function, were significantly lower than anticipated from the patients' IQ. Memory was the most severely affected cognitive domain. The patient with the lowest scores received a maximum dose of 36 Gy on the cerebellum and low radiation doses on the whole brain and hippocampi [34]. The studies of Merchant et al. [49] even demonstrated that radiation dose-volume-parameters remain the most clinically significant determinants of IQ

outcomes and that further reduction in radiation dose to specific volumes of the brain should be pursued.

Beside radiation dose to the cerebellum, multiple modalities in the treatment of brain tumor patients can induce neurocognitive sequelae. These include the pre-treatment neurocognitive function, surgery and peri-operative complications, radiation dose and volume to the craniospinal axis, systemic or intrathecal application chemotherapy, implantation of a shunt for increased intracranial pressure, patient factors such as age, stress, fatigue and anxiety [33–49].

Conclusion & future perspectives

There is growing evidence from structural and functional imaging studies that the cerebellum plays an evident role in neurocognition (Fig. 2). Radiation to the posterior fossa has shown to have a negative effect on neurocognitive outcomes in long-term pediatric brain survivors. In order to derive an NTCP model for the (posterior) cerebellum, it is necessary to collect data on varying radiation doses to the (posterior and anterior) cerebellum and on prospectively assessing neurocognitive outcome.

Author's contributions

Lieke in 't Ven: study concept and design, acquisition of data, analysis and interpretation, manuscript.

Daniëlle Eekers: analysis and interpretation, critical revision of the manuscript for important intellectual content, study supervision.

Esther Troost: analysis and interpretation, critical revision of the manuscript for important intellectual content, study supervision.

Sabine Deprez: critical revision of the manuscript for important intellectual content.

Linda Jacobi: critical revision of the manuscript for important intellectual content.

Erik Roelofs: critical revision of the manuscript for important intellectual content.

Ann Hoeben: critical revision of the manuscript for important intellectual content.

Philippe Lambin: study concept and design, study supervision.

Dirk de Ruyscher: critical revision of the manuscript for important intellectual content.

Disclosure of conflicts of interest

This research was partially supported by the Brains Unlimited Pioneer Fund of the Limburg University Fund/SWOL (S.2013.1.011).

Ethical publication statement

We confirm that we have read the Journal's position on issues involved in ethical publication and affirm that this report is consistent with those guidelines.

Acknowledgement

The authors sincerely thank Marlies Granzier, dosimetrist at MAASTRO clinic, for her support in the delineation presented for Fig. 1.

References

- Eekers DBP, in 't Ven L, Roelofs E, Postma A, Alapetite C, Burnet N, et al. The EPTN consensus-based atlas for CT- and MR-based contouring in Neuro-Oncology. Submitted.
- Gondi V, Hermann BP, Mehta MP, Tomé WA. Hippocampal dosimetry predicts neurocognitive function impairment after fractionated stereotactic radiotherapy for benign or low-grade adult brain tumors. *Int J Radiat Oncol Biol Phys* 2013;85(2):348–54.
- Kaatsch P. Epidemiology of childhood cancer. *Cancer Treat Rev* 2010;36(4):277–85.
- Habrand JL, De Crevoisier R. Radiation therapy in the management of childhood brain tumors. *Childs Nerv Syst* 2001;17(3):121–33.
- Ribi K, Rely C, Landolt MA, Alber FD, Boltshauser E, Grotzer MA. Outcome of medulloblastoma in children: long-term complications and quality of life. *Neuropediatrics* 2005;36(6):357–65.
- Greene-Schloesser D, Robbins ME. Radiation-induced cognitive impairment from bench to bedside. *Neuro-Oncol* 2012;14(Suppl 4):iv37–44.
- Hoppe-Hirsch E, Brunet L, Laroussinie F, Cinalli G, Pierre-Kahn A, Renier D, et al. Intellectual outcome in children with malignant tumors of the posterior fossa: influence of the field of irradiation and quality of surgery. *Childs Nerv Syst* 1995;11(6):340–5.
- Rapoport M, van Reekum R, Mayberg H. The role of the cerebellum in cognition and behavior: a selective review. *J Neuropsychiatry Clin Neurosci* 2000;12(2):193–8.
- Leiner HC. Solving the mystery of the human cerebellum. *Neuropsychol Rev* 2010;20(3):229–35.
- Stoodley CJ, Schmahmann JD. Evidence for topographic organization in the cerebellum of motor control versus cognitive and affective processing. *Cortex J Devoted Study Nerv Syst Behav* 2010;46(7):831–44.
- Stoodley CJ, Valera EM, Schmahmann JD. Functional topography of the cerebellum for motor and cognitive tasks: an fMRI study. *NeuroImage* 2012;59(2):1560–70.
- Fine EJ, Ionita CC, Lohr L. The history of the development of the cerebellar examination. *Semin Neurol* 2002;22(4):375–84.
- Babinski JFF. Babinski sign. *Arch Neurol Psychiatry* 1933;29(1):168.
- Holmes G. The cerebellum of man. *Brain* 1939;62(1):1–30.
- Prescott JW. Early somatosensory deprivation as ontogenetic process in the abnormal development of the brain and behaviour. *Med Primatol* 1970:356–75.
- Watson PJ. Nonmotor functions of the cerebellum. *Psychol Bull* 1978;85(5):944–67.
- Ristanović D, Milošević NT, Stefanović BD, Marić DL, Rajković K. Morphology and classification of large neurons in the adult human dentate nucleus: a qualitative and quantitative analysis of 2D images. *Neurosci Res* 2010;67(1):1–7.
- D'Angelo E, Casali S. Seeking a unified framework for cerebellar function and dysfunction: from circuit operations to cognition. *Front Neural Circuits* 2012;6:116.
- Schmahmann JD, Pandya DN. The cerebrocerebellar system. *Int Rev Neurobiol* 1997;41:31–60.
- Middleton F. Basal ganglia and cerebellar loops: motor and cognitive circuits. *Brain Res Rev* 2000;31(2–3):236–50.
- Kelly RM, Strick PL. Cerebellar loops with motor cortex and prefrontal cortex of a nonhuman primate. *J Neurosci Off J Soc Neurosci* 2003;23(23):8432–44.
- Bernard JA, Mittal VA. Dysfunctional activation of the cerebellum in schizophrenia: a functional neuroimaging meta-analysis. *Clin Psychol Sci J Assoc Psychol Sci* 2015;3(4):545–66.
- Noroozian M. The role of the cerebellum in cognition: beyond coordination in the central nervous system. *Neurol Clin* 2014;32(4):1081–104.
- Kim SG, Uğurbil K, Strick PL. Activation of a cerebellar output nucleus during cognitive processing. *Science, New Series* 1994; 265(5174): 949–951.
- Schmahmann JD. The cerebellar cognitive affective syndrome. *Brain* 1998;121(4):561–79.
- Schmahmann JD, Caplan D. Cognition, emotion and the cerebellum. *Brain* 2006;129:290–2.
- Cuny ML, Pallone M, Piana H, Boddaert N, Sainte-Rose C, Vaire-Douret L, et al. Neuropsychological improvement after posterior fossa arachnoid cyst drainage. *Childs Nerv Syst* 2017;33(1):135–41.
- Hoogendam YY, van der Geest JN, Niessen WJ, van der Lugt A, Hofman A, Vernooij MW, et al. The role of cerebellar volume in cognition in the general elderly population. *Alzheimer Dis Assoc Disord* 2014;28(4):352–7.
- Weier K, Till C, Fonov V, Yeh EA, Arnold DL, Banwell B, et al. Contribution of the cerebellum to cognitive performance in children and adolescents with multiple sclerosis. *Mult Scler J* 2016;22(5):599–607.
- Bernard JA, Seidler RD. Moving forward: age effects on the cerebellum underlie cognitive and motor declines. *Neurosci Biobehav Rev* 2014;42:193–207.
- Merchant TE, Sharma S, Xiong X, Wu S, Conklin H. Effect of cerebellum radiation dosimetry on cognitive outcomes in children with infratentorial ependymoma. *Int J Radiat Oncol Biol Phys* 2014;90(3):547–53.
- Schmahmann JD, Doyon J, McDonald D, Holmes C, Lavoie K, Hurwitz AS, et al. Three-dimensional MRI atlas of the human cerebellum in proportional stereotaxic space. *NeuroImage* 1999 Sep;10(3):233–60.
- Rønning C, Sundet K, Due-Tønnessen B, Lundar T, Helseth E. Persistent cognitive dysfunction secondary to cerebellar injury in patients treated for posterior fossa tumors in childhood. *Pediatr Neurosurg* 2005;41(1):15–21.
- Gan HK, Bernstein LJ, Brown J, Ringash J, Vakilha M, Wang L, et al. Cognitive functioning after radiotherapy or chemoradiotherapy for head-and-neck cancer. *Int J Radiat Oncol Biol Phys* 2011;81(1):126–34.
- Brouwer CL, Steenbakkers RJHM, Bourhis J, Budach W, Grau C, Grégoire V, et al. CT-based delineation of organs at risk in the head and neck region: DAHANCA,

- EORTC, GORTEC, HKNPCSG, NCIC CTG, NCRI, NRG Oncology and TROG consensus guidelines. *Radiother Oncol* 2015;117(1):83–90.
- [36] Scoccianti S, Detti B, Gadda D, Greto D, Furfaro I, Meacci F, et al. Organs at risk in the brain and their dose-constraints in adults and in children: a radiation oncologist's guide for delineation in everyday practice. *Radiother Oncol* 2015;114(2):230–8.
- [37] Tamboli DA, Harris MA, Hogg JP, Realini T, Sivak-Callcott JA. Computed tomography dimensions of the lacrimal gland in normal caucasian orbits. *Ophthal Plast Reconstr Surg* 2011;27(6):453–6.
- [38] Celesia GG, DeMarco PJ. Anatomy and physiology of the visual system. *J Clin Neurophysiol* 1994;11(5):482–92.
- [39] Merchant TE, Goloubeva O, Pritchard DL, Gaber MW, Xiong X, Danish RK, et al. Radiation dose-volume effects on growth hormone secretion. *Int J Radiat Oncol* 2002;52(5):1264–70.
- [40] Elson A, Bovi J, Kaur K, Maas D, Sinson G, Schultz C. Effect of treatment modality on the hypothalamic-pituitary function of patients treated with radiation therapy for pituitary adenomas: hypothalamic dose and endocrine outcomes. *Front Oncol* 2014;4:73.
- [41] Rappaport R, Brauner R. Growth and endocrine disorders secondary to cranial irradiation. *Pediatr Res* 1989;25(6):561–7.
- [42] Baroncini M, Jissendi P, Balland E, Besson P, Pruvo J-P, Francke J-P, et al. MRI atlas of the human hypothalamus. *NeuroImage* 2012;59(1):168–80.
- [43] Chera BS, Amdur RJ, Patel P, Mendenhall WM. A radiation oncologist's guide to contouring the hippocampus. *Am J Clin Oncol* 2009;32(1):20–2.
- [44] Konrad C, Ukas T, Nebel C, Arolt V, Toga AW, Narr KL. Defining the human hippocampus in cerebral magnetic resonance images—an overview of current segmentation protocols. *NeuroImage* 2009;47(4):1185–95.
- [45] Bender ET, Mehta MP, Tomé WAA. On the estimation of the location of the hippocampus in the context of hippocampal avoidance whole brain radiotherapy treatment planning. *Technol Cancer Res Treat* 2009;8(6):425–32.
- [46] Kojima S, Suzuki K, Hirata M, Shinohara H, Ueno E. Depicting the semicircular canals with inner-ear MRI: a comparison of the SPACE and TrueFISP sequences. *J Magn Reson Imaging JMIR* 2013;37(3):652–9.
- [47] Kocak-Uzel E, Gunn GB, Colen RR, Kantor ME, Mohamed ASR, Schoultz-Henley S, et al. Beam path toxicity in candidate organs-at-risk: assessment of radiation emetogenesis for patients receiving head and neck intensity modulated radiotherapy. *Radiother Oncol* 2014;111(2):281–8.
- [48] Sun Y, Yu X-L, Luo W, Lee AWM, Wee JTS, Lee N, et al. Recommendation for a contouring method and atlas of organs at risk in nasopharyngeal carcinoma patients receiving intensity-modulated radiotherapy. *Radiother Oncol* 2014;110(3):390–7.
- [49] Merchant TE, Kiehna EN, Li C, Xiong X, Mulhern RK. Radiation dosimetry predicts IQ after conformal radiation therapy in pediatric patients with localized ependymoma. *Int J Radiat Oncol Biol Phys* 2005;63(5):1546–54.

Daniëlle B.P. Eekers¹

Department of Radiation Oncology (MAASTRO), GROW – School for Oncology and Developmental Biology, Maastricht University Medical Centre, Maastricht, The Netherlands

Proton Therapy Department South-East Netherlands (ZON-PTC), Maastricht, The Netherlands

Lieke in 't Ven^{*2}

Department of Radiation Oncology (MAASTRO), GROW – School for Oncology and Developmental Biology, Maastricht University Medical Centre, Maastricht, The Netherlands

* Address: MAASTRO Clinic, Doctor Tanslaan 12, 6229 ET Maastricht, The Netherlands.

E-mail address: Lieke.Ven@maastro.nl

Sabine Deprez

Department of Imaging and Pathology, KU Leuven, Leuven, Belgium

Department of Radiology, University Hospital Leuven, Leuven, Belgium

Linda Jacobi

Dept. of Radiology, GROW – School for Oncology and Developmental Biology, Maastricht University Medical Centre, Maastricht, The Netherlands

Erik Roelofs

Department of Radiation Oncology (MAASTRO), GROW – School for Oncology and Developmental Biology, Maastricht University Medical Centre, Maastricht, The Netherlands

The D-Lab: Decision Support for Precision Medicine, GROW – School for Oncology and Developmental Biology, Maastricht Comprehensive Cancer Centre, Maastricht University Medical Centre, Maastricht, The Netherlands

Ann Hoeben

Dept of Medical Oncology, GROW – School for Oncology and Developmental Biology, Maastricht University Medical Centre, Maastricht, The Netherlands

Philippe Lambin

The D-Lab: Decision Support for Precision Medicine, GROW – School for Oncology and Developmental Biology, Maastricht Comprehensive Cancer Centre, Maastricht University Medical Centre, Maastricht, The Netherlands

Dept of Medical Oncology, GROW – School for Oncology and Developmental Biology, Maastricht University Medical Centre, Maastricht, The Netherlands

Dirk de Ruyscher

Department of Radiation Oncology (MAASTRO), GROW – School for Oncology and Developmental Biology, Maastricht University Medical Centre, Maastricht, The Netherlands

KU Leuven, Radiation Oncology University Hospitals Leuven, Department of Radiation Oncology/KU Leuven, Radiation Oncology, Leuven, Belgium

Esther G.C. Troost

Department of Radiation Oncology, Medical Faculty and University Hospital Carl Gustav Carus, Technische Universität Dresden, Dresden, Germany

Institute of Radiooncology – OncoRay, Helmholtz-Zentrum Dresden – Rossendorf, Dresden, Germany

OncoRay – National Center for Radiation Research in Oncology, Dresden, Germany

German Cancer Consortium (DKTK), Partnersite Dresden, and German Cancer Research Center (DKFZ), Heidelberg, Germany

Received 28 September 2017

Revised 21 November 2017

Accepted 21 November 2017

¹ Equally shared first author.

² Equally shared first author.