

Transperineal Ultrasound-Guided 12-Core Prostate Biopsy: An Extended Approach to Diagnose Transition Zone Prostate Tumors

Ming-Hua Yao¹, Li-Ling Zou², Rong Wu^{1*}, Le-Hang Guo¹, Guang Xu¹, Juan Xie¹, Pei Li¹, Shuai Wang¹

¹ Department of Ultrasound in Medicine, Shanghai Tenth People's Hospital, Tongji University School of Medicine, Shanghai, China, ² Department of Health Statistics, Tongji University School of Medicine, Shanghai, China

Abstract

Objective: Transperineal ultrasound-guided (TPUS) 12-core prostate biopsy was evaluated as an initial strategy for the diagnosis of prostate cancer. The distribution of prostate cancer lesions was assessed with zone-specific biopsy.

Methods: From January 2010 to December 2012, 287 patients underwent TPUS-guided 12-core prostate biopsy. Multiple cores were obtained from both the peripheral zone (PZ) and the transition zone (TZ) of the prostate. Participants' clinical data and the diagnostic yield of the cores were recorded and prospectively analyzed as a cross-sectional study.

Results: The diagnostic yield of the 12-core prostate biopsy was significantly higher compared to the 6-core scheme (42.16 vs. 21.6%). The diagnostic yield of the 10-core prostate biopsy was significantly higher compared to the 6-core scheme (37.6 vs. 21.6%). The 12-core scheme improved the diagnostic yield in prostates >50 ml (12-core scheme: 28.1% vs. 10-core scheme: 20.4%; $p=0.034$).

Conclusions: The 12-core biopsy scheme is a safe and effective approach for the diagnosis of prostate cancer. TZ biopsies in patients with larger prostates should be included in the initial biopsy strategy.

Citation: Yao M-H, Zou L-L, Wu R, Guo L-H, Xu G, et al. (2014) Transperineal Ultrasound-Guided 12-Core Prostate Biopsy: An Extended Approach to Diagnose Transition Zone Prostate Tumors. PLoS ONE 9(2): e89171. doi:10.1371/journal.pone.0089171

Editor: Masaru Kato, National Cancer Center, Japan

Received: September 12, 2013; **Accepted:** January 16, 2014; **Published:** February 25, 2014

Copyright: © 2014 Yao et al. This is an open-access article distributed under the terms of the Creative Commons Attribution License, which permits unrestricted use, distribution, and reproduction in any medium, provided the original author and source are credited.

Funding: The authors have no support or funding to report.

Competing Interests: The authors have declared that no competing interests exist.

* E-mail: wurongmedsci@163.com

Introduction

Prostate cancer is the sixth leading cause of cancer-related death among older men in developed countries [1] and is on the rise in developing countries including China. Its pathogenesis is poorly understood. Prostate cancer are often asymptomatic during the early stages of disease. Although PSA-based screening has resulted in a significant increase in the detection rate of PCa, its use remains controversial because elevated levels of PSA are not cancer specific. Moreover, clinically significant PCa can exist in men with relatively low PSA levels [2](Thompson et al, 2004). Besides the conventional digital rectal examination (DRE) and the controversy surrounding prostate specific antigen (PSA)-based screening, ultrasonography (US) and magnetic resonance imaging (MRI) are the most common imaging technologies to screen for prostate cancer. US can visualize the prostate directly; and due to certain advantages— it is conducted in real-time, it is portable and economical— it is often used for biopsy guidance. MRI can provide more information about the properties of the tissue, such as enhancement and diffusion, that are valuable in the evaluation of tumor extent [3]. According to the guidelines of the European Association of Urology (EAU), among the main diagnostic tools to diagnose prostate cancer, the systematic prostate biopsy under ultrasound guidance is the preferred diagnostic method [4]. An

ultrasound-guided biopsy uses either a transrectal or transperineal approach to access the prostate. Although both have been reported to have equal detection rates [5–7], the transperineal approach may be preferred under certain circumstances [8]. Even though few biomarkers exist, biopsy is the most successful diagnostic approach [9]. TPUS-guided biopsy provides uniform sampling of the entire prostate and a relatively high probability of clinical diagnosis [10]. However, the search for an improved biopsy technique, which includes a better diagnosis with relatively few complications, is ongoing [11]. Biopsy techniques that optimize the number of cores that are sampled, as well as their locations within the prostate gland, may be considered [12]. In this prospective analysis, we estimated the diagnostic yield of different biopsy schemes, analyzed the locations within the prostate of the carcinoma-positive cores identified during TPUS-guided extended biopsy, and evaluated the efficacy of TPUS-guided extended biopsy for detecting disease in various locations within the prostate gland.

Materials and Methods

Subjects

From January 2010 to December 2012, 287 patients underwent TPUS-guided biopsy at our hospital, Department of Ultrasound in

Medicine, Shanghai tenth People's Hospital. Inclusion criteria were one or more of the following: i) High PSA level (>4 ng/ml), but urinary tract infection, prostatitis or prostate massage excluded; ii) Abnormal findings by DRE; iii) Hypoechoic areas during examination of the prostate by transrectal or abdominal ultrasound; iv) Abnormalities identified by magnetic resonance imaging (MRI) of the prostate (such as T2-weighted). Patients with previous histology requiring repeat biopsy were excluded from the study. This study was performed in strict accordance with the ethical guidelines of the Helsinki Declaration. The study protocol was approved by the Ethics Committees of the People's Hospital of Tongji University, Shanghai, and all participants provided written informed consent. Patients were divided into three groups according to age, prostate volume, and PSA level. Patient demographic and clinical data were recorded as well as the numbers of carcinoma-positive cores by location within the prostate. The diagnostic yield of the 12-core method was compared to the sextant biopsy and 10-core biopsy schemes.

Equipment

The Hitachi 8500 sonographer (Hitachi, Japan) equipped with a 5.0/7.5 MH z transrectal dual-plane probe was used to perform ultrasonography. The Bard automated biopsy gun (Tempe, Arizona, America) with 22 mm range and 18G needle was used for biopsy.

Biopsy

Preoperative examinations including routine blood and urine tests were performed to exclude coagulation disorders, hematuria, and urinary tract infections. The 12-core transperineal prostate biopsy was carried out with patients in the lithotomy position. Perineal skin was prepared, disinfected, and locally anesthetized with 1% lidocaine. Under the guidance of TRUS, the 18G biopsy needle was inserted through the perineal skin, and the cores were taken as follows: traditional sextant; four cores in the lateral PZ; two cores in the TZ (Figure 1). After biopsy, specimens were collected in 10% formaldehyde for pathological examination. Post-surgical pain was assessed using the visual analogue scale (VAS: a score of 0 indicated no pain, a score of 10 indicated extreme pain). Post biopsy, patients remained in the hospital for observation for two days. Patients were followed-up to gather information relating to biopsy-related complications by telephone for one week.

Statistical analysis

SPSS 17 was used for statistical analysis. χ^2 test was used to compare the diagnosis rate among groups; $p < 0.05$ was considered statistically significant.

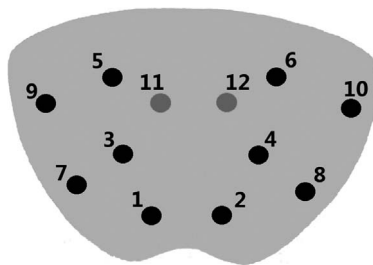


Figure 1. Transverse section: Biopsy cores were distributed in pairs. 1 to 6: the standard sextant cores; 7 to 10: the four additional cores in the lateral peripheral zone (PZ); 11 to 12: two cores in the transition zone (TZ). doi:10.1371/journal.pone.0089171.g001

Results

287 patients were enrolled in the study. Table 1 shows the baseline characteristics for all patients. 42.1% (121/287) patients tested positive for prostate cancer by 12-core biopsy; 37.6% (108/287) patients tested positive for prostate cancer by 10-core biopsy; and 21.6% (62/287) patients tested positive for prostate cancer by 6-core biopsy. Diagnostic yield among the three approaches was significantly different ($p < 0.01$; Table 2). After the pathological examination, the Gleason score (GS) of each patient was obtained. The results show that 65 patients (53.8%) had a GS of 6; 44 patients (36.3%) had a GS of 7; and 12 patients (9.9%) had a GS of 8 to 10.

The cancer lesions of 121 patients were characterized by real-time ultrasonography. The maximal diameter of the lesion was less than 10 mm in 15 patients (12.4%); between 10 and 15 mm in 22 patients (18.2%); and greater than 15 mm in 24 patients (19.8%). Diffusion lesions were observed in 29 patients (24.0%), and the lesion was unobservable in 31 patients (25.6%).

There was no statistical difference in the diagnostic yield of carcinoma-positive cores sampled from the PZ by sextant biopsy compared to 10-core biopsy ($p = 0.54$, Table 3), which indicates that there is a uniform distribution of lesions in the PZ. There were no significant differences in diagnostic yield by 10-core and 12-core biopsy schemes when grouped by age, PSA levels, and DRE. When patients were grouped according to prostate volume (≤ 50 ml and > 50 ml), 12-core biopsy diagnosed significantly more patients with carcinoma-positive cores in the TZ compared to 10-core biopsy (28.1 vs. 20.4%, Table 4).

Participants were similarly tolerant of procedural and post-procedural pain (VAS score of 0-3). Gross hematuria was observed in 21 patients (7.3%), hematuria with hematospermia in 8 patients (2.8%), urinary tract infection in 19 patients (6.6%), and acute urinary retention in 3 patients (1.0%). No serious biopsy hematoma or neurovascular injury occurred.

Discussion

Prostate cancer is the most common malignant tumor among older men [13]. According to a study [14], the median age of diagnosis of prostate cancer in the United States is more than 65 years. Prostate cancer reduces life expectancy and lowers quality-of-life [15,16]. TPUS-guided biopsy is the preferred approach for prostate cancer diagnosis. The traditional sextant TPUS biopsy has a history of under-diagnosing a large number of patients [17]. It is likely that more cores should be sampled to increase the diagnostic yield. However, such approaches may lead to a greater number of biopsy-associated complications. It is essential to achieve a balance between diagnostic yield, the number of cores sampled, and the risk for complications.

Table 1. Patient baseline characteristics (n = 287).

Criteria	Value
Median Age, in years (range)	71 (25–86)
Age > 60	86.4%
Mean Prostate volume, ml, (SD)	47.0 (23.0)
Prostate volume > 50 ml	36.2%
Mean Level of PSA, ng/ml, (SD)	22.8(29.5)
Level of PSA > 10 ng/ml	48.1%

doi:10.1371/journal.pone.0089171.t001

Table 2. Diagnostic yield of TPUS-guided sextant, 10-core, and 12-core biopsy schemes.

Technique	Positive Diagnosis		Negative Diagnosis		Total
	Number	Percentage	Number	Percentage	
Sextant biopsy	62	21.6	225	78.4	287
10-core biopsy	108	37.6*	179	68.4	287
12-core biopsy	121	42.1*	166	57.9	287

*p<0.01: statistically significant difference between the schemes
doi:10.1371/journal.pone.0089171.t002

Since its introduction by Hodge in 1989, sextant biopsy has been modified several times [18]. In particular, the sextant protocol fails to detect a large number of carcinomas in the PZ region of the prostate gland [19]. This observation prompted the Italian National Comprehensive Cancer Network to recommend the sampling of 4 cores from the lateral PZ in addition to the traditional sextant scheme [20]. In current practice, 10–12 cores are used as an extended biopsy approach [21], with minimal biopsy-related complications [22]. Previous reports of the results of the 12-core biopsy were based on the conventional sextant plus 6 cores in the peripheral zone. The detection rate ranged from 30.3% to 51% [23], [24]. Some researchers believe that there is no difference in the detection rate between a 6-core and 12-core biopsy [25], or between an 8-core and 12-core biopsy [26], while other researchers believe that adding more cores will increase the detection rate [27], [28], [29]. Moreover, some studies focused on the relationship between the Gleason score and the 12-core biopsy. For instance, Arrabal-Polo et al. determined that there is no difference in Gleason score between the specimens from 6-core and 12-core biopsies [30–34]. Our study indicated that the TPUS-guided 12-core biopsy technique provided improved diagnostic yields, especially in cancers originating in the TZ of larger prostates, without increasing the risk of biopsy-related complications.

Anatomically the prostate is divided into three regions: the PZ, TZ and central zone (CZ), and is covered in a tough fibrous sheath [35]. The PZ is further divided into the apex, midgland and the base. Results describing the distribution of tumors within the zones of the prostate are inconsistent. Some studies suggest that 75% prostate cancers occur in the PZ, and 25% occur in the CZ and TZ [36]. A Study by Demura et al, [37] indicated that the distribution of prostate cancer is uniform within the entire gland. Other reports show that the carcinoma foci are more localized in the anterior location [38]. Our study revealed that there are no differences in tumor distribution between the apex, midgland and base in the PZ. However, although not statistically significant, the ratio of the diagnostic yield of 10-core biopsy relative to sextant biopsy was 1.74 (37.63% vs 21.60%), indicating that increasing the number of cores sampled in the PZ may improve diagnosis.

Age is a strong predictor of prostate cancer. Several reports [39,40] suggest that mortality is positively correlated with age. In our study, the age of the majority of patients diagnosed with prostate cancer was over 60 years (>90%). In these older males, the diagnostic yield was similar with both the 10-core and 12-core biopsy schemes, suggesting that the number of cores is not an important predictor of the success of the diagnostic approach in this patient population.

Prostate volume is another predictor of prostate cancer. Yamamoto et al.[41] and Novara et al. [42] showed that there was a negative correlation between diagnostic yield and prostate

Table 3. Diagnosis of carcinoma positive cores by location within the prostate gland: sextant and 10-core biopsy schemes.

Core Number	Lobe	Site	Positive number	%	p*
1	Right	Apex	41	33.88	0.54
2	Left	Apex	42	34.71	
3	Right	Midgland	43	35.54	
4	Left	Midgland	38	31.40	
5	Right	Base	45	37.19	
6	Left	Base	42	34.71	
7	Right	Lateral midgland	37	30.58	
8	Left	Lateral midgland	32	26.45	
9	Right	Lateral base	30	24.79	
10	Left	Lateral base	40	33.06	

*p=0.54: no significant difference in diagnosis by sextant or 10-core biopsy
doi:10.1371/journal.pone.0089171.t003

volume. In our study, the diagnostic yield of 12-core biopsy was higher than that of 10-core biopsy, and when prostate volume was over 50 ml, adding cores in the TZ significantly increased the number of tumors detected.

PSA is a protease secreted by prostate epithelial cells. A number of events cause an increase in PSA levels, including benign prostate hyperplasia (BPH) and prostatitis [43]. Currently, it is recommended not to screen for prostate cancer based on PSA-levels due to the risks of over-diagnosis and over-treatment [44,45]. However, the predictive value of PSA is an important non-invasive screening method. Screening for prostate cancer

Table 4. Group analysis of prostate cancer diagnosis using 10-core and 12-core TPUS guided biopsy schemes.

	10-core biopsy		12-core biopsy		p value
	number	percentage	number	percentage	
Age (in years)					0.942
≤60	6	5.6	8	6.6	
61~80	78	72.2	87	71.9	
≥81	24	22.2	26	21.5	
Prostate volume					0.034*
≤50 ml	99	79.6	99	71.9	
>50 ml	9	20.4	22	28.1	
Level of PSA					0.732
4~10 ng/ml	25	23.1	28	23.1	
10~50 ng/ml	37	34.3	47	38.8	
≥50 ng/ml	46	42.6	46	38.0	
DRE					0.857
Positive	17	15.7	18	14.0	
Negative	91	84.3	103	86.0	

* p value = 0.034 Rate of prostate cancer diagnosis is improved by TPUS-guided 12-core biopsy in patients with larger prostates
doi:10.1371/journal.pone.0089171.t004

based on PSA significantly reduces the risk of metastatic cancer [46]. Our data indicate that biopsy should be performed in patients with PSA levels greater than 4 ng/ml, but extended approaches are not required.

Several reports [47,48] show that the diagnostic yield from core samples in the TZ is so low that it could be omitted. Other studies recommend including biopsy cores from the TZ to improve the diagnostic yield [49], at least in repeat biopsies [50]. Our research found that the addition of 2 cores in the TZ resulted in the diagnosis of 13 extra TZ-only positive patients who were DRE negative. Further research based on a larger number of patients is required before it can be concluded that the TZ should be routinely included in prostate biopsy schemes.

References

1. Ng MK, Van As N, Thomas K, Woode-Amisah R, Horwich A, et al. (2009) Prostate-specific antigen (PSA) kinetics in untreated, localized prostate cancer: PSA velocity vs PSA doubling time. *BJU Int* 103: 872–876.
2. Thompson IM, Pauler DK, Goodman PJ, Tangen CM, Lucia MS, et al. (2004) Prevalence of prostate cancer among men with a prostate-specific antigen level < or = 4.0 ng per milliliter. *N Engl J Med* 350: 2239–2246.
3. Talab SS, Preston MA, Elmi A, Tabatabaie S (2012) Prostate Cancer Imaging What the Urologist Wants to Know. *Radiologic Clinics of North America* 50: 1015–4.
4. Heidenreich A, Bellmunt J, Bolla M, Joniau S, Mason M, et al. (2011) EAU Guidelines on Prostate Cancer. Part 1: Screening, Diagnosis, and Treatment of Clinically Localised Disease. *Eur Urol* 59: 61–71.
5. Hara R, Jo Y, Fujii T, Kondo N, Yokoyama T, et al. (2008) Optimal approach for prostate cancer detection as initial biopsy: prospective randomized study comparing transperineal versus transrectal systematic 12-core biopsy. *Urology* 71: 191–195.
6. Takenaka A, Hara R, Ishimura T, Fujii T, Jo Y, et al. (2008) A prospective randomized comparison of diagnostic efficacy between transperineal and transrectal 12-core prostate biopsy. *Prostate Cancer Prostatic Dis* 11: 134–138.
7. Shen PF, Zhu YC, Wei WR, Li YZ, Yang J, et al. (2012) The results of transperineal versus transrectal prostate biopsy: a systematic review and meta-analysis. *Asian J Androl* 14: 310–315.
8. Chang DT, Challacombe B, Lawrentschuk N (2013) Transperineal biopsy of the prostate—is this the future? *Nat Rev Urol*.
9. Van der Kwast T, Bubendorf L, Mazerolles C, Raspollini MR, Van Leenders GJ, et al. (2013) Guidelines on processing and reporting of prostate biopsies: the 2013 update of the pathology committee of the European Randomized Study of Screening for Prostate Cancer (ERSPC). *Virchows Arch*.
10. Humphrey P, Andriole G (2010) Prostate cancer diagnosis. *Missouri medicine* 107: 107.
11. Scattoni V, Raber M, Abdollah F, Roscigno M, Deho F, et al. (2010) Biopsy schemes with the fewest cores for detecting 95% of the prostate cancers detected by a 24-core biopsy. *Eur Urol* 57: 1–8.
12. Scattoni V, Raber M, Capitanio U, Abdollah F, Roscigno M, et al. (2011) The optimal rebiopsy prostate scheme depends on patient clinical characteristics: results of a recursive partitioning analysis based on a 24-core systematic scheme. *Eur Urol* 60: 834–841.
13. Ravizzini G, Turkbey B, Kurdziel K, Choyke PL (2009) New horizons in prostate cancer imaging. *Eur J Radiol* 70: 212–226.
14. Zullig LL, Jackson GL, Dorn RA, Provenzale DT, McNeil R, et al. (2012) Cancer incidence among patients of the U.S. Veterans Affairs Health Care System. *Mil Med* 177: 693–701.
15. Deshields TL, Potter P, Olsen S, Liu J (2013) The persistence of symptom burden: symptom experience and quality of life of cancer patients across one year. *Support Care Cancer*.
16. (2013) Prostate cancer: Survival nomogram for men with progressive mCRPC. *Nat Rev Urol*.
17. Kopke T, Oberpenning F, Bettendorf O, Eltze E, Herrmann E, et al. (2010) Negative predictive value of systematic ultrasound-guided prostate biopsy: which tumours do we miss? *Anticancer Res* 30: 1823–1827.
18. Nesrallah L, Nesrallah A, Antunes AA, Leite KR, Srougi M (2008) The role of extended prostate biopsy on prostate cancer detection rate: a study performed on the bench. *Int Braz J Urol* 34: 563–570; discussion 570–561.
19. Moussa AS, Meshref A, Schoenfield L, Masoud A, Abdel-Rahman S, et al. (2010) Importance of additional “extreme” anterior apical needle biopsies in the initial detection of prostate cancer. *Urology* 75: 1034–1039.
20. Ficarra V, Novella G, Novara G, Galfano A, Pea M, et al. (2005) The potential impact of prostate volume in the planning of optimal number of cores in the systematic transperineal prostate biopsy. *Eur Urol* 48: 932–937.
21. Philip J, Manikandan R, Javle P, Foster CS (2009) Prostate cancer diagnosis: should patients with prostate specific antigen >10 ng/mL have stratified prostate biopsy protocols? *Cancer Detect Prev* 32: 314–318.

Conclusion

In summary, prostate lesions occur uniformly in the PZ. Biopsy of the TZ should be reserved as initial biopsy in patients whose prostate volume is over 50 ml. The 12-core biopsy approach maximizes the sensitivity of cancer detection while keeping biopsy-related complications low. Thus, TPUS-guided 12-core biopsy is a safe and effective method to improve the diagnostic yield of tumors occurring in the TZ of larger prostates.

Author Contributions

Conceived and designed the experiments: RW. Performed the experiments: MHY. Analyzed the data: LHG LLZ. Contributed reagents/materials/analysis tools: SW PL. Wrote the paper: GX JX.

22. Gore JL, Shariat SF, Miles BJ, Kadmon D, Jiang N, et al. (2001) Optimal combinations of systematic sextant and laterally directed biopsies for the detection of prostate cancer. *J Urol* 165: 1554–1559.
23. Jeong H, Jeong BC, Kwak C, Lee E, Lee SE, et al. (2008) A comparison of prostate cancer detection rates by 12 or 6 core biopsy at different prostate-specific antigen densities in Korean men. *World J Urol* 26: 395–400.
24. Emiliozzi P, Longhi S, Scarpone P, Pansadoro A, DePaula F, et al. (2001) The value of a single biopsy with 12 transperineal cores for detecting prostate cancer in patients with elevated prostate specific antigen. *J Urol* 166: 845–850.
25. Naughton CK, Miller DC, Mager DE, Ornstein DK, Catalona WJ (2000) A prospective randomized trial comparing 6 versus 12 prostate biopsy cores: impact on cancer detection. *J Urol* 164: 388–392.
26. Abd TT, Goodman M, Hall J, Ritenour CW, Petros JA, et al. (2011) Comparison of 12-core versus 8-core prostate biopsy: multivariate analysis of large series of US veterans. *Urology* 77: 541–547.
27. Elabbady AA, Khedr MM (2006) Extended 12-core prostate biopsy increases both the detection of prostate cancer and the accuracy of Gleason score. *Eur Urol* 49: 49–53; discussion 53.
28. Tobiume M, Yamada Y, Nakamura K, Honda N (2008) Retrospective study comparing six- and twelve-core prostate biopsy in detection of prostate cancer. *Int Braz J Urol* 34: 9–14.
29. O’Connell MJ, Smith CS, Fitzpatrick PE, Keane CO, Fitzpatrick JM, et al. (2004) Transrectal ultrasound-guided biopsy of the prostate gland: value of 12 versus 6 cores. *Abdom Imaging* 29: 132–136.
30. Arrabal-Polo MA, Jimenez-Pacheco A, Mijan-Ortiz JL, Arrabal-Martin M, Valle-Diaz de la Guardia F, et al. (2010) Relationship between biopsy Gleason score and radical prostatectomy specimen Gleason score in patients undergoing sextant vs 12 core biopsies. *Arch Esp Urol* 63: 791–796.
31. Bigliocchi M, Marini M, Nofroni I, Perugia G, Shahabadi H, et al. (2007) Prostate cancer detection rate of transrectal ultrasonography, digital rectal examination, and prostate-specific antigen: results of a five-year study of 6-versus 12-core transperineal prostate biopsy. *Minerva Urol Nefrol* 59: 395–402; 403–396.
32. Luciani LG, De Giorgi G, Valotto C, Zanin M, Berti S, et al. (2006) Role of transperineal six-core prostate biopsy in patients with prostate-specific antigen level greater than 10 ng/mL and abnormal digital rectal examination findings. *Urology* 67: 555–558.
33. Takenaka A, Hara R, Hyodo Y, Ishimura T, Sakai Y, et al. (2006) Transperineal extended biopsy improves the clinically significant prostate cancer detection rate: a comparative study of 6 and 12 biopsy cores. *Int J Urol* 13: 10–14.
34. Emiliozzi P, Scarpone P, DePaula F, Pizzo M, Federico G, et al. (2004) The incidence of prostate cancer in men with prostate specific antigen greater than 4.0 ng/ml: a randomized study of 6 versus 12 core transperineal prostate biopsy. *J Urol* 171: 197–199.
35. Fine SW, Reuter VE (2012) Anatomy of the prostate revisited: implications for prostate biopsy and zonal origins of prostate cancer. *Histopathology* 60: 142–152.
36. Liu XG, Shen C, Li J, Zhang K, Yu W, et al. (2012) [Distribution characteristics of cancerous foci in the prostate among patients undergoing single positive core biopsy]. *Zhonghua Nan Ke Xue* 18: 155–159.
37. Demura T, Hioka T, Furuno T, Kaneta T, Gotoda H, et al. (2005) Differences in tumor core distribution between palpable and nonpalpable prostate tumors in patients diagnosed using extensive transperineal ultrasound-guided template prostate biopsy. *Cancer* 103: 1826–1832.
38. Yan W, Li H, Zhou Y, Huang Z, Rong S, et al. (2009) Prostate carcinoma spatial distribution patterns in Chinese men investigated with systematic transperineal ultrasound guided 11-region biopsy. *Urol Oncol* 27: 520–524.
39. Stamatou KN (2011) Elderly and prostate cancer screening. *Urology Journal* 8: 83–87.
40. Hamstra DA, Bae K, Pilepich MV, Hanks GE, Grignon DJ, et al. (2011) Older age predicts decreased metastasis and prostate cancer-specific death for men

- treated with radiation therapy: meta-analysis of radiation therapy oncology group trials. *Int J Radiat Oncol Biol Phys* 81: 1293–1301.
41. Yamamoto S, Kin U, Nakamura K, Hamano M, Nishikawa Y, et al. (2005) Transperineal ultrasound-guided 12-core systematic biopsy of the prostate for patients with a prostate-specific antigen level of 2.5–20 ng/ml in Japan. *Int J Clin Oncol* 10: 117–121.
 42. Novara G, Boscolo-Berto R, Lamon C, Fracalanza S, Gardiman M, et al. (2010) Detection rate and factors predictive the presence of prostate cancer in patients undergoing ultrasonography-guided transperineal saturation biopsies of the prostate. *BJU Int* 105: 1242–1246.
 43. Fujita K, Imamura R, Tanigawa G, Nakagawa M, Hayashi T, et al. (2012) Low serum neutrophil count predicts a positive prostate biopsy. *Prostate Cancer Prostatic Dis* 15: 386–390.
 44. Schroder FH (2011) Stratifying risk—the U.S. Preventive Services Task Force and prostate-cancer screening. *N Engl J Med* 365: 1953–1955.
 45. Brett AS, Ablin RJ (2011) Prostate-cancer screening—what the U.S. Preventive Services Task Force left out. *N Engl J Med* 365: 1949–1951.
 46. Schroder FH, Hugosson J, Carlsson S, Tammela T, Maattanen L, et al. (2012) Screening for prostate cancer decreases the risk of developing metastatic disease: findings from the European Randomized Study of Screening for Prostate Cancer (ERSPC). *Eur Urol* 62: 745–752.
 47. Hwang SI, Lee HJ, Cho JY, Kim SH, Lee SE, et al. (2009) Should transition zone biopsies be added to 12-core systematic biopsies of the prostate? *J Clin Ultrasound* 37: 281–284.
 48. Dogan B, Serefoglu EC, Atmaca AF, Canda AE, Akbulut Z, et al. (2012) Is sampling transitional zone in patients who had prior negative prostate biopsy necessary? *Int Urol Nephrol* 44: 1071–1075.
 49. Yunkai Z, Yaqing C, Ren W, Yongchang Z (2010) Are transition zone biopsies necessary in transrectal ultrasound-guided transperineal prostate biopsy protocol? Results of a Chinese population-based study. *Clin Imaging* 34: 43–46.
 50. de la Rosette JJ, Wink MH, Mamoulakis C, Wondergem N, ten Kate FJ, et al. (2009) Optimizing prostate cancer detection: 8 versus 12-core biopsy protocol. *J Urol* 182: 1329–1336.