

Acute Uterine Inversion: A Simple Modification of Hydrostatic Method of Treatment

Gupta P, Sahu R L¹, Huria A²

Department of Gynecology and Obstetrics, Post Graduate Institute of Medical Sciences and Research, Employees' State Insurance Corporation, Basaidarapur, New Delhi, ¹Department of Orthopedics, Sharda University and Medical College, Greater Noida, Uttar Pradesh, ²Department of Gynecology and Obstetrics, Government Medical College, Chandigarh, India

Address for correspondence:

Dr. Pratiksha Gupta,
Department of Gynecology
and Obstetrics, Post Graduate
Institute of Medical Sciences
and Research, Employees'
State Insurance Corporation,
Basaidarapur, New Delhi, India.
E-mail: drpratiksha@gmail.com

Abstract

Background: Hydrostatic method for reducing acute uterine inversion is simple method, if advocated properly. **Aim:** The aim of this study is to reduce the failures in technique in O'Sullivan's method in acute puerperal uterine inversion hence reducing maternal mortality and morbidity. **Subjects and Methods:** This study was conducted over a 6 year period from 2007 to 2013. Women with acute uterine inversion immediately after delivered were included in the study. Repositioning of acute uterine inversion in six patients in emergency was done using trans-urethral resection of prostate set (TURP set), used in endoscopic resection of prostate, and two 3 L saline bags. **Results:** The repositioning was successful in all requiring no anesthesia. **Conclusions:** This technique modification is improvisation of hydrostatic pressure with a trans-urethral resection of prostate set (TURP set) and 3 L saline bags and it is simple and effective and will definitely save women's lives; thus, reducing maternal morbidity and mortality.

Keywords: Hydrostatic method, Trans-urethral resection of prostate set, Uterine inversion

Introduction

Uterine inversion is an introflexion of parietes uteri, which takes place during the third stage of labor, or during the 1st h of puerperium.^[1] It's a rare life-threatening complication. Incidence varies widely from 1 in 2,000 to 1 in 50,000 deliveries.^[2] Shock is out of proportion with apparent blood loss, being a neurogenic shock, with profound hypotension, bradycardia and cardiac arrest commences within a short time and it should be managed immediately. We aim to evaluate if we can reduce the maternal mortality and morbidity in remote areas where medical aid is scarce - by the simple technique modification of hydrostatic method for repositioning of acute uterine inversion.

Subjects and Methods

The Study period was for 6 years from 2007 to 2013. Immediately delivered women with acute uterine inversion were included in the study. We had carried out this procedure in six acute puerperal inversions; all were in profound shock. Patients were between 25 years and 36 years of age and their parities were between two and three. Study was approved by institutional Ethical committee and informed consent was taken from all patient's husband. The waiting period for anesthesia was long for the other traditional techniques as manual reposition. Resuscitative measures generally take longer time in patients of profound shock, hence anesthesia usually is delayed. Management included summoning assistance and initial shock management with two wide bore intravenous cannulae, rapid infusion of 1-2 L of crystalloid, cross matching four units of blood and indwelling bladder catheterization. Patients were put in the reverse trendelenburg lithotomy position. Neither anesthesia nor tocolysis was used, only analgesia was used. The inverted uterus was pushed into the vagina. Hydrostatic method was now commenced. Prior to the procedure, patients were checked and lacerations ruled out. None of our patients had laceration.

The principle of this technique is to instill a large volume of fluid about 2-3 L, into the upper vagina, with adequate pressure,

Videos available on www.amhsr.org

Access this article online

Quick Response Code:



Website: www.amhsr.org

DOI:
10.4103/2141-9248.129059

pressure here is created by gravity and by two regulators present in the tubing of trans-urethral resection of prostate set (TURP set), without using any pressure pumps, pressure is enough when both regulators are fully opened and saline bottles are at about one metre distance above patients table, thus distending the fornices, which serves to pull open the cervical ring, allowing replacement of the uterine fundus. The use of 1 L warm saline bags with a pressure infusion pump is usually recommended, but small saline bottles needs to be replaced quickly and to create pressure by pump requires a longer time, which most often leads to failure of this procedure.

We modified this technique by using two large 3 L warm saline bags and a using a trans-urethral resection of prostate set (TURP set). In trans-urethral resection of prostate set (TURP set), two nozzles are present proximally, which is to be inserted into both saline bags to create sufficient pressure, where in the distal tube end is guided into the posterior fornix by one hand that also cups the fundus. The other hand seals the introitus around the wrist so that there is no egress of fluid [Figures 1-4]. The basic failures are generally due to inadequate saline pressure gradient and if the introitus is not sealed adequately, both can be overcome by using trans-urethral resection of prostate set (TURP set) and two 3 L saline bags and a closed fist or a vacuum cup. Following successful reduction, intravenous oxytocin kept the uterus firmly contracted for 8-12 h and broad-spectrum antibiotics were given for 24-48 h. It took 10-15 min from the time of diagnosis to complete uterine reduction in all the six cases. Video incorporated [Video 1].

A good saline seal and adequate saline pressure gradient are crucial to the success of hydrostatic reduction. This technique modification is simple and effective and it can be taught to all medical personnel who conduct delivery.

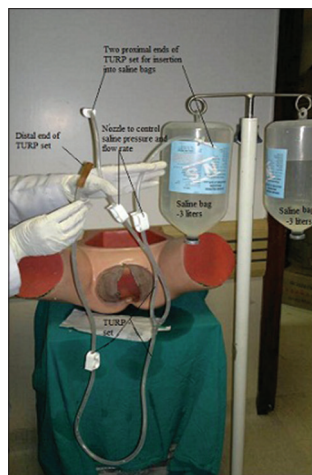


Figure 1: Trans-urethral resection of prostate set, large 3 L saline bottles

Results

Reduction was successful in all the six women. Total blood loss was minimal after the procedure. Patients were discharged after 24 h of observation and remained well at subsequent reviews.

Discussion

Acute uterine inversion can be classified as first, second or third degree according to the zone concerned in the introflexion. It is first when only the fundus is prolapsing and second when the corpus emerges in the vagina and third when the entire uterus emerges from the vulvar orifice.^[1] It can also be classified into complete and incomplete inversion. Complete occurs when the inverted uterus has passed completely through the cervix to lie within the vagina or less often, outside the introitus. Incomplete inversion occurs when the fundus of the uterus has turned inside out, rather like the toe of a sock, but the inverted fundus has not descended through the cervix.^[2] For the uterus to be inverted it must be relaxed and this, along with fundal insertion of the placenta, are important pre-disposing conditions. Additional factors are mismanagement of the third stage of labor involving fundal pressure and or cord traction before placental separation and while the uterus is still relaxed. Abnormally short cord or functionally shortened by being wrapped around the fetal body is a rare cause. Sudden rise in intra-abdominal pressure, morbid adherence of a fundally implanted placenta, manual removal of placenta during the cesarean section-this can occur with those who routinely undertake manual removal of placenta at the time of caesarian section before the uterus has contracted. While pulling the cord the placenta, which is still attached to the fundus of the uterus, so as when placenta is withdrawn so too is the fundus of the uterus; thus inversion occurs.^[2] Even connective tissue disorders can pre-dispose to acute uterine inversion.^[3] Diagnosis may be obvious and dramatic with a large boggy mass appearing at the introitus.

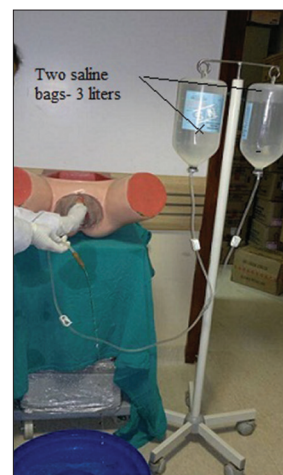

Figure 2: Trans-urethral resection of prostate set being connected to large saline bottles and regulators made open so there is egress of saline

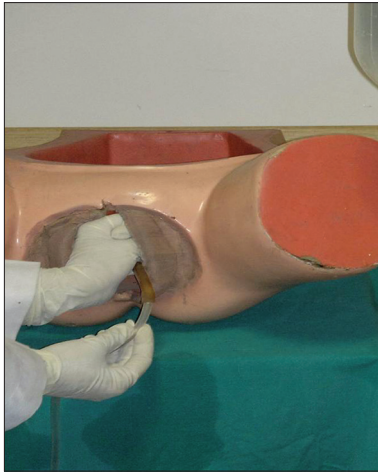


Figure 3: Introitus being sealed with the help of one hand, other hand being inserted into introitus with the distal end of trans-urethral resection of prostate set with fluid flowing through it

The other signs and symptoms are severe and sustained hypogastric pain in the third stage of labor, shock and absence of uterus abdominally in complete inversion. Shock is out of proportion with apparent blood loss - being a neurogenic shock, due to stretching of the infundibulopelvic and round ligament, ovaries and associated nerves being pulled into the crater of the inversion that provides a strong vasovagal stimulus. Thus, the woman often becomes pallid and sweaty, with profound hypotension with bradycardia and may even, on rare occasions, have a cardiac arrest. Within a short time, in the majority of cases, there is also marked hemorrhage and hypovolemic shock.^[4,5]

Once the diagnosis of inversion is made, measures should be undertaken to manage and correct acute blood loss and potential shock. In conjunction with anesthesia personnel, immediate uterine replacement should be considered. Immediate recognition and early treatment to relax the cervico-uterine junction should ensure rapid replacement of the uterus. Manual repositioning of uterus under anesthesia is immediately recommended,^[2] if there is a delay in anesthesia and patient is in profound shock (or even if the manual replacement has failed), O'Sullivan's hydrostatic replacement technique can be remarkable and is gratifyingly effective and is to be undertaken.^[6-8] If done properly is always successful and it avoids the risk of anesthesia and reduces maternal morbidity and mortality. The challenge in O'Sullivan's method is in developing a water seal. Use of 1 L bags of warmed saline with a pressure infusion pump is usually recommended, but small saline bottles need to be replaced quickly and to create pressure by pump requires a longer time. Some workers have modified this technique by attaching the tubing to a silastic vacuum extractor cup, which is placed inside the introitus and might help provide a better seal.^[9] We modified this technique by using a trans-urethral resection of prostate set (TURP set), used in endoscopic resection of prostate and two 3 L warm saline bags with success.

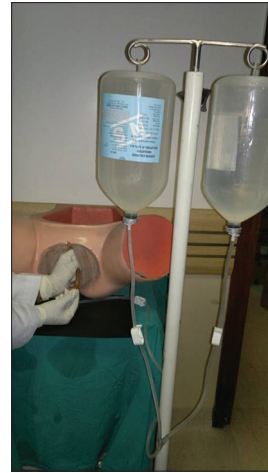

Figure 4: This figure shows complete procedure being done

Manual reposition of uterus is recommended in immediately delivered women with acute inversion without anesthesia, if patient is not in profound shock,^[2] it is easily carried out, but since all of our patients had delivery outside and came in not in profound shock, so manual reposition without anesthesia was not attempted.

Acute uterine inversion can be fatal if not managed as soon as it occurs. If there is a delay in anesthesia and manual reposition has failed, hydrostatic replacement especially using trans-urethral resection of prostate set (TURP set), two 3 L saline bags and a vacuum cup or closed fist will definitely save women's lives; thus, reducing maternal mortality and morbidity by just a simple technique modification. Good saline seal and an adequate saline pressure gradient are crucial to the success of hydrostatic reduction. This technique modification is simple and effective and it can be taught to all medical personnel who conduct delivery.

References

1. Studziński Z, Branicka D. Acute complete uterine inversion - Care report. *Ginekol Pol* 2001;72:881-4.
2. Baskett TF, Calder AA, Arulkumaran S. Acute uterine inversion. In: Green E, editor. *Munro Kerr's, Operative Obstetrics*. 11th ed. Amsterdam: Saunders Elsevier; 2007. p. 243-9.
3. Quinn RJ, Mukerjee B. Spontaneous uterine inversion in association with Marfan's syndrome. *Aust N Z J Obstet Gynaecol* 1982;22:163-4.
4. Wendel PJ, Cox SM. Emergent obstetric management of uterine inversion. *Obstet Gynecol Clin North Am* 1995;22:261-74.
5. Rachagan SP, Sivanesaratnam V, Kok KP, Raman S. Acute puerperal inversion of the uterus - An obstetric emergency. *Aust N Z J Obstet Gynaecol* 1988;28:29-32.
6. O'Sullivan JV. Acute Inversion of the Uterus. *Br Med J* 1945;2:282-3.
7. Ogueh O, Ayida G. Acute uterine inversion: A new technique of hydrostatic replacement. *Br J Obstet Gynaecol* 1997;104:951-2.

8. Antonelli E, Irion O, Tolck P, Morales M. Subacute uterine inversion: Description of a novel replacement technique using the obstetric ventouse. *BJOG* 2006;113:846-7.
9. Momani AW, Hassan A. Treatment of puerperal uterine inversion by the hydrostatic method; reports of five cases. *Eur J Obstet Gynecol Reprod Biol* 1989;32:281-5.

How to cite this article: Gupta P, Sahu RL, Huria A. Acute uterine inversion: A simple modification of hydrostatic method of treatment. *Ann Med Health Sci Res* 2014;4:264-7.

Source of Support: Nil. **Conflict of Interest:** None declared.