

## [ Orthopaedic Surgery ]

# Rates of Deep Venous Thrombosis and Pulmonary Embolus After Anterior Cruciate Ligament Reconstruction: A Systematic Review

Brandon J. Erickson, MD,\*<sup>†</sup> Bryan M. Saltzman, MD,<sup>†</sup> Kirk A. Campbell, MD,<sup>†</sup>  
Yale A. Fillingham, MD,<sup>†</sup> Joshua D. Harris, MD,<sup>†</sup> Anil K. Gupta, MD,<sup>†</sup> and Bernard R. Bach Jr, MD<sup>†</sup>

**Context:** Venous thromboembolic (VTE) disease is thought to be an uncommon but serious problem after anterior cruciate ligament (ACL) reconstruction. Rates of VTE after ACL reconstruction are not well documented.

**Objective:** To determine the rates of deep vein thrombosis (DVT) and symptomatic pulmonary emboli (PE) after ACL reconstruction.

**Data Sources:** Five publicly available databases (PubMed, Cochrane Database of Systematic Reviews, Scopus, Embase, and CINAHL Complete) were utilized.

**Study Selection:** All studies that screened patients for DVT and reported rates of DVT and PE after ACL reconstruction were eligible for inclusion. Level 5 evidence, cadaver, biomechanical, and basic science studies; studies reporting only multiligament reconstruction outcomes; studies where rates of DVT and PE could not be separated out from patients undergoing other types of arthroscopic knee procedures; and classification studies were excluded.

**Study Design:** Systematic review.

**Level of Evidence:** Level 4.

**Data Extraction:** All study, subject, and surgical data were analyzed. Descriptive statistics were calculated.

**Results:** Six studies met the inclusion criteria, with a mean Modified Colman Methodology Score of  $30 \pm 8.22$ . A total of 692 patients (488 men [70.5%]; mean age,  $31.6 \pm 2.82$  years; mean follow-up,  $7 \pm 18.4$  months) underwent ACL reconstruction using either semitendinosus-gracilis autograft (77.6%), bone-patellar tendon-bone (BTB) autograft (22%), or allograft (0.4%). No patient received postoperative pharmacological anticoagulation. Fifty-eight patients (8.4%) had a DVT (81% below knee and 19% above knee), while only 1 patient (0.2%) had a symptomatic PE. When reported, 27% of DVT episodes were symptomatic.

**Conclusion:** The rate of DVT after ACL reconstruction in patients who did not receive postoperative pharmacological anticoagulation is 8.4%, while the rate of symptomatic PE is 0.2%. Of the DVT episodes that occurred, 73% were asymptomatic.

**Keywords:** deep venous thrombosis; pulmonary embolus; prophylaxis; anterior cruciate ligament reconstruction; knee; thromboembolic disease

From <sup>†</sup>Rush University Medical Center, Chicago, Illinois

\*Address correspondence to Brandon J. Erickson, MD, Rush University, 355 East Ohio Street, Apartment 3408, Chicago, IL 60611 (e-mail: berickso.24@gmail.com).

The following author declared potential conflicts of interest: Bernard R. Bach Jr, MD, has grants/grant pending from Arthrex, CONMED, DJ Ortho, Ossur, Tornier, Smith & Nephew and receives royalties from SLACK.

DOI: 10.1177/1941738115576927

© 2015 The Author(s)

Anterior cruciate ligament (ACL) reconstruction is one of the most common procedures performed by orthopaedic surgeons, as more than half of the 200,000 ACL tears that occur annually will undergo reconstruction.<sup>6,8,9,14</sup> With an annual cost to the health care system of more than \$1 billion, minimizing complications associated with ACL reconstruction to optimize patient care and prevent a further increase in spending is critical.<sup>9,10,20</sup> Several measures have been taken to reduce the incidence of these complications, such as preoperative antibiotics and accelerated rehabilitation.<sup>13,16</sup> However, data are currently lacking on deep vein thrombosis (DVT) and pulmonary embolism (PE) rates, as well as protocols on venous thromboembolic (VTE) prophylaxis, in patients undergoing ACL reconstruction.

Given that there is no standard of care with regard to VTE prophylaxis after ACL reconstruction, there are some surgeons who routinely use chemical VTE prophylaxis in these patients and others who do not.<sup>3,19,22</sup> Use of various types of pharmacological VTE prophylaxis including coumadin, rivaroxaban, low-molecular weight heparin (LMWH), and aspirin have been reported. While these medicines are effective in decreasing the rates of VTE after knee arthroscopy and other procedures, they are not without side effects, including hemarthrosis, adverse reactions to the medication itself, and others.<sup>18,19,23,28</sup> Therefore, it is critically important to determine the incidence of VTE after ACL reconstruction.

The purpose of this study was to perform a systematic review that determines the incidence of DVT and PE in patients after ACL reconstruction. The hypothesis is that the incidence of DVT after ACL reconstruction will be less than 10%, and the incidence of PE will be less than 1%.

## METHODS

A systematic review was conducted according to PRISMA guidelines (Preferred Reporting Items for Systematic reviews and Meta-Analyses) using a PRISMA checklist.<sup>17</sup> Systematic review registration was performed using the PROSPERO International prospective register of systematic reviews (registration number CRD42014013281, approved on August 18, 2014).<sup>27</sup> Two reviewers independently conducted the search on September 10, 2014 and again on January 2, 2015 to ensure no recent articles were missed using the following databases: PubMed, Cochrane Database of Systematic Reviews, Scopus, Embase, and CINAHL Complete. The electronic search citation algorithm used was as follows: [Anterior Cruciate Ligament or ACL] Reconstruction AND ([Deep Vein Thrombosis or DVT] OR [Pulmonary Embolism OR PE]) AND Incidence; [Anterior Cruciate Ligament or ACL] Reconstruction AND ([Deep Vein Thrombosis or DVT] OR [Pulmonary Embolism OR PE]). English-language level 1 through 4 evidence (2011 update by the Oxford Centre for Evidence-Based Medicine<sup>26</sup>) clinical studies that screened patients for DVT after ACL reconstruction and reported the rates of DVT and PE after ACL reconstruction were eligible for inclusion. Abstracts and conference proceedings were not. To verify that no studies were missed,

the reference lists of the included studies were cross-referenced to ensure that no studies were omitted.

A total of 61 studies were identified, and after implementation of the exclusion criteria, 6 studies were included in the final analysis (Figure 1). Patients of interest in this systematic review underwent either autograft or allograft ACL reconstruction for a deficient ACL and were assessed postoperatively for VTE. There was no minimum follow-up or rehabilitation requirement for the included studies. The patient demographic parameters analyzed were number of patients, sex, and age. Surgical parameters analyzed included surgical technique, operative time, concomitant procedures, graft choice (autograft vs allograft as well as the specific type of graft), type of anesthesia, use of a tourniquet, and concomitant procedures (such as meniscus, articular cartilage, multiligamentous injury). Anticoagulation protocol was recorded, as was the number of patients. The presence or absence of symptoms was also extracted and reported in relation to VTE. Clinical outcome scores were not assessed. Complications other than DVT and PE were also recorded, when reported. Study methodological quality was evaluated using the Modified Coleman Methodology Score (MCMS).<sup>4</sup>

## Statistical Analysis

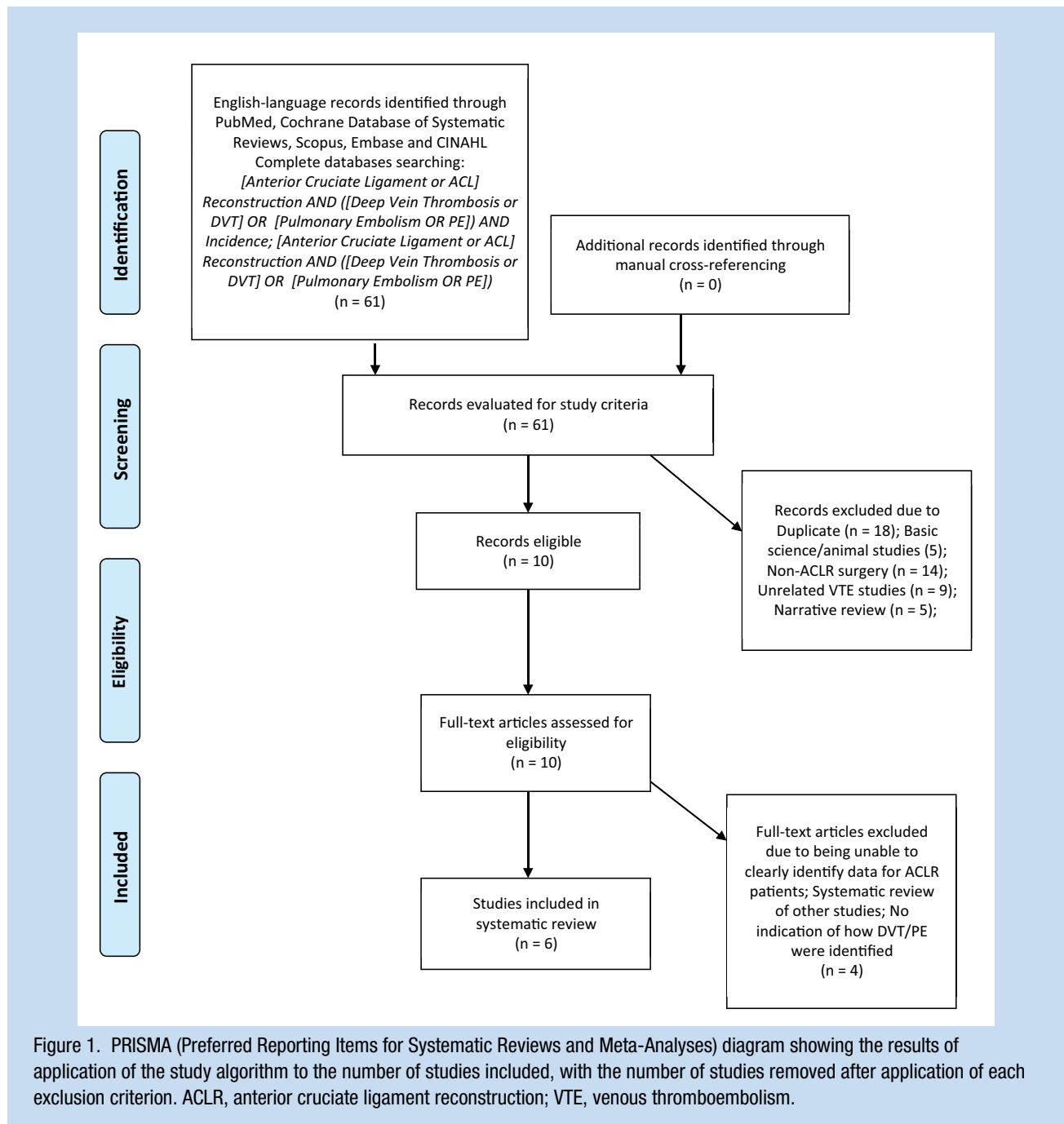
Study descriptive statistics were calculated. Continuous variable data were reported as mean  $\pm$  standard deviation from the mean. Weighted means and standard deviations were calculated for all parameters. Categorical variable data were reported as frequency with percentages.

## RESULTS

After implementation of the exclusion criteria, 6 studies were included in the final analysis.<sup>1,5,7,25,29,31</sup> A total of 692 patients (488 men [70.5%], 204 women [29.5%]; mean age, 31.6  $\pm$  2.82 years; mean follow-up, 7.0  $\pm$  18.4 months) underwent ACL reconstruction. The mean MCMS of the included studies was 30  $\pm$  8.22, indicating the overall quality of studies was poor. When reported, graft choices were as follows: semitendinosus-gracilis hamstring autograft (77.6%), bone-patellar tendon-bone (BPTB) autograft (22%), and allograft (0.4%). No patient received pharmacological postoperative anticoagulation.

Five<sup>1,7,25,29,31</sup> studies reported the use of a tourniquet in all patients, while 1 study<sup>5</sup> reported tourniquet use occasionally during ACL reconstruction (mean tourniquet time, 74.4  $\pm$  14.5 minutes). Five studies screened for DVT using ultrasound,<sup>1,5,7,25,29</sup> while 1 study used contrast venography.<sup>31</sup> Timing of DVT screening differed by study (Table 1), but all studies used a single radiologist to perform the screening. Spinal or general anesthesia was the most common type of anesthesia used (Table 2), while the type of block used in the local/regional groups could not always be determined. The mean operative time was 75.5  $\pm$  11.9 minutes. Four studies reported on concomitant procedures (Table 3).<sup>1,5,7,25</sup>

Of the 692 included patients, 58 (8.4%) showed evidence of a DVT. Of these 58 patients, studies specifically reported on the



location (below or above the knee) of the DVT in 36 patients. Twenty-nine (81%) had a DVT that was below the knee, while 7 patients (19%) had a DVT that was above the knee. Twenty-seven percent of DVTs were symptomatic (the exact definition varied by study but included patients with swollen, red, tender, painful legs). Routine screening for PE was not performed. Only 1 patient (0.2%) had a symptomatic PE (Table 4). Each study had a different protocol for how to treat patients with a DVT and how to evaluate for resolution of patients with a DVT (Table 5).

## DISCUSSION

Anterior cruciate ligament reconstruction is one of the most common procedures performed by orthopaedic surgeons.<sup>6,16</sup> The incidence and prevalence of DVT as well as PE after ACL reconstruction is not well documented.

The studies that were included in this review all routinely evaluated patients after an ACL reconstruction for DVT using some form of diagnostic imaging (ultrasound or contrast

Table 1. Timing of deep venous thrombosis (DVT) screening for all included studies

Study	Timing of DVT Screening for Study
Adala et al <sup>1</sup>	POD 3 and POD 28
Cullison et al <sup>5</sup>	POD 2 or POD 3
Struijk-Mulder et al <sup>25</sup>	Between POD 11 and POD 17
Williams et al <sup>29</sup>	Between POD 7 and POD 14
Ye et al <sup>31</sup>	POD 3
Dong et al <sup>7</sup>	POD 3 and POD 7

POD, postoperative day.

Table 2. Type of anesthesia used during anterior cruciate ligament reconstruction

Laryngeal Mask Airway (LMA)	n (%)
LMA anesthesia	112 (16.2)
Locoregional anesthesia	62 (9.0)
General anesthesia	38 (5.5)
“Spinal or general” anesthesia	242 (35.2)
“Local or general” anesthesia	171 (24.9)

venography). Patients were not routinely screened for PE unless symptomatic. As many of the DVTs that were picked up were asymptomatic (73%), studies that report the rate of DVT after ACL reconstruction without diagnostic evaluation could miss a large number of asymptomatic DVTs. This may or may not be clinically relevant, depending on the patient. Data surrounding asymptomatic DVT after ACL reconstruction is sparse, so it is difficult to draw a conclusion as to the clinical significance of an asymptomatic DVT in this patient population.

The American Academy of Orthopaedic Surgeons (AAOS) has formulated clinical practice guidelines (CPGs) regarding the use of anticoagulation after elective total joint arthroplasty. However, no such guidelines have been developed for patients undergoing ACL reconstruction.<sup>12</sup> Furthermore, data surrounding prophylaxis against DVT and PE after ACL reconstruction are lacking. Marlovits et al<sup>19</sup> performed a prospective, double-blind, randomized controlled trial to evaluate the effectiveness of enoxaparin, an LMWH, in reducing the rate of DVT in patients who had undergone ACL reconstruction. Patients were randomized to receive either enoxaparin 40 mg or placebo subcutaneously for 20 days after surgery. The study found no difference in bleeding rates, but that 2.8% of patients treated with enoxaparin had evidence of a DVT compared with 41.2% of

Table 3. Concomitant surgery at the time of the anterior cruciate ligament reconstruction<sup>a</sup>

Total patients with concomitant surgery, n (%)	168 (24.4)
Meniscal repair	20
Partial meniscectomy	61
Debridement	11
Microfracture	3
MCL/LCL	47
PCL	20
“Unspecified” procedure	6

LCL, lateral collateral ligament; MCL, medial collateral ligament; PCL, posterior cruciate ligament.

<sup>a</sup>Reported in 3 of 6 included studies.

patients who received placebo. Several studies have compared the rates of DVT in patients who have received DVT prophylaxis after arthroscopic knee surgery to those who did not.<sup>21,22</sup>

Michot et al<sup>21</sup> evaluated 218 patients who underwent arthroscopic knee surgery and randomized them to LMWH or no prophylaxis. More patients in the LMWH group had minor bleeds postoperatively (12% vs 6%). Ten patients (15.6%) in the control group had a DVT with no patient experiencing a PE, while 1 (1.5%) in the LMWH group and a DVT as well as a PE. Munoa et al<sup>22</sup> randomized 467 patients to bemiparin or rivaroxaban for VTE prophylaxis after a variety of arthroscopic knee surgeries, with no documented DVT or PE postoperatively. Wirth et al<sup>30</sup> evaluated 262 patients who underwent arthroscopic knee surgery who received either LMWH or nothing after surgery. No patient experienced a major bleed or PE, and 5 patients (4.1%) in the control group and 1 patient (0.85%) in the LMWH group

Table 4. Rates of deep venous thrombosis (DVT) and pulmonary emboli (PE) among patients undergoing anterior cruciate ligament (ACL) reconstruction, n (%)

Total patients with DVT	58 (8.4)
Below knee	29 (6.1) (of the 5 studies reporting this specifically)
Above knee DVT	7 (1.5) (of the 5 studies reporting this specifically)
Total patients with DVT progressing to PE	1 (1.7 of all patients with DVT)
Total patients with postthrombotic syndrome	0 (0.0)

Table 5. How each study treated deep venous thrombosis (DVT) and how each study assessed for DVT resolution

Study	Means for DVT Treatment
Adala et al <sup>1</sup>	Fondaparinux for 5 days → simultaneous warfarin and PT/INR adjusted at 2-3 for 3 months
Cullison et al <sup>5</sup>	NA
Struijk-Mulder et al <sup>25</sup>	Asymptomatic patients were not treated with anticoagulants, but a repeat CCUS was performed after 1 week; symptomatic patients were treated with anticoagulants. Nadroparin, 5700 IU administered subcutaneously twice daily for >5 days until an adequate INR of 2.5 to 3.5 was reached with vitamin K antagonists
Williams et al <sup>29</sup>	1 week of ASA treatment
Ye et al <sup>31</sup>	Therapeutic doses of batroxobin (3 times 5 Brabender units for distal DVT and 3-5 times for proximal DVT) and confined to bed
Dong et al <sup>7</sup>	NA
Study	Timing of DVT Resolution and Imaging
Adala et al <sup>1</sup>	Repeat US at 6 months showed resolution
Cullison et al <sup>5</sup>	Repeat US on POD 10 showed resolution
Struijk-Mulder et al <sup>25</sup>	Repeat US at POD 21 showed clots were stable, no discussion thereafter of further imaging
Williams et al <sup>29</sup>	Repeat US at 1 week after screening test demonstrated no change in any clots and no propagation, no discussion thereafter of further imaging
Ye et al <sup>31</sup>	All resolved but does not state when or how measured
Dong et al <sup>7</sup>	NA

ASA, acetyl salicylic acid (aspirin); CCUS, complete compression ultrasonography; INR, international normalized ratio; NA, not applicable; POD, postoperative day; PT, prothrombin time; US, ultrasound.

experienced a DVT. These studies clearly demonstrated a reduction in the DVT rates in patients who underwent arthroscopic knee surgery when DVT prophylaxis was used. Unfortunately, these studies did not isolate the ACL reconstruction patients.

Almost all patients included in this study underwent ACL reconstruction with the use of a tourniquet (5 of 6 studies used the

tourniquet in all patients, and 1 in some). While there is no literature that clearly documents an increase in rates of DVT or PE after ACL reconstruction with the use of a tourniquet, there was evidence in the arthroplasty literature. A systematic review of randomized controlled trials compared patients who underwent total knee arthroplasty with a pneumatic tourniquet with those

without.<sup>33</sup> The relative risk was 2.63 in the tourniquet group, suggesting a higher rate of DVT in patients with a tourniquet. Overall, this review showed a DVT rate of 8.4% after ACL reconstruction with a PE rate of 0.2%. With these rates, it is difficult to determine whether patients undergoing ACL reconstruction would benefit from DVT prophylaxis, and furthermore, which type of DVT prophylaxis should be used. However, these data can be used to inform patients about the risk of developing a PE after an ACL reconstruction, and both the surgeon and patient can decide whether the patient would rather accept the risk of a DVT and avoid the complications associated with pharmacological DVT prophylaxis or the patient would prefer to assume the medication risks and decrease their risk of a DVT. Newer DVT prophylaxis medications, such as rivaroxaban,<sup>15,32</sup> are easy-to-take, oral medications that do not require monitoring but can be associated with increased cost and potentially increased rates of bleeding, although data on this are split.<sup>2,11,24,32</sup> These are factors patients must understand when making their decision.

## Limitations

This study is subject to the limitations of the included studies: performance, selection, detection, transfer, and publication bias. Furthermore, although this review included almost 700 patients, it may not be generalizable.

## CONCLUSION

The rate of DVT after ACL reconstruction in patients who did not receive postoperative pharmacological anticoagulation is 8.4%, while the rate of PE is 0.2%. Of the DVT that occurred, 73% were asymptomatic.

## REFERENCES

- Adala R, Anand A, Kodikal G. Deep vein thrombosis and thromboprophylaxis in arthroscopic anterior cruciate ligament reconstruction. *Indian J Orthop.* 2011;45:450-453.
- Adam SS, McDuffie JR, Lachiewicz PF, Ortel TL, Williams JW Jr. Comparative effectiveness of new oral anticoagulants and standard thromboprophylaxis in patients having total hip or knee replacement: a systematic review. *Ann Intern Med.* 2013;159:275-284.
- Chahal J, Lee A, Heard W, Bach BR Jr. A retrospective review of anterior cruciate ligament reconstruction using patellar tendon: 25 years of experience. *Orthop J Sports Med.* 2013;1(3):2325967113501789.
- Cowan J, Lozano-Calderson S, Ring D. Quality of prospective controlled randomized trials. Analysis of trials of treatment for lateral epicondylitis as an example. *J Bone Joint Surg Am.* 2007;89:1693-1699.
- Cullison TR, Muldoon MP, Gorman JD, Goff WB. The incidence of deep venous thrombosis in anterior cruciate ligament reconstruction. *Arthroscopy.* 1996;12:657-659.
- DeHaven KE, Lintner DM. Athletic injuries: comparison by age, sport, and gender. *Am J Sports Med.* 1986;14:218-224.
- Dong JT, Wang X, Men XQ, Wang XF, Zheng XZ, Gao SJ. Incidence of deep venous thrombosis in Chinese patients undergoing arthroscopic knee surgery for cruciate ligament reconstruction [published online November 2, 2014]. *Knee Surg Sports Traumatol Arthrosc.* doi:10.1007/s00167-014-3216-x.
- Erickson BJ, Harris JD, Cole BJ, et al. Performance and return to sport after anterior cruciate ligament reconstruction in National Hockey League players. *Orthop J Sports Med.* 2014;2:2325967114548831.
- Frank CB, Jackson DW. The science of reconstruction of the anterior cruciate ligament. *J Bone Joint Surg Am.* 1997;79:1556-1576.
- Griffin LY, Agel J, Albohm MJ, et al. Noncontact anterior cruciate ligament injuries: risk factors and prevention strategies. *J Am Acad Orthop Surg.* 2000;8:141-150.
- Hamidi V, Ringerike T, Hagen G, Reikvam A, Klemp M. New anticoagulants as thromboprophylaxis after total hip or knee replacement. *Int J Technol Assess Health Care.* 2013;29:234-243.
- Jacobs JJ, Mont MA, Bozic KJ, et al. American Academy of Orthopaedic Surgeons clinical practice guideline on: preventing venous thromboembolic disease in patients undergoing elective hip and knee arthroplasty. *J Bone Joint Surg Am.* 2012;94:746-747.
- Kwok CS, Harrison T, Servant C. The optimal timing for anterior cruciate ligament reconstruction with respect to the risk of postoperative stiffness. *Arthroscopy.* 2013;29:556-565.
- LaBella CR, Hennrikus W, Hewett TE; Council on Sports Medicine and Fitness, and Section on Orthopaedics. Anterior cruciate ligament injuries: diagnosis, treatment, and prevention. *Pediatrics.* 2014;133:e1437-e1450.
- Lazo-Langner A, Fleet JL, McArthur E, Garg AX. Rivaroxaban vs. low molecular weight heparin for the prevention of venous thromboembolism after hip or knee arthroplasty: a cohort study. *J Thromb Haemost.* 2014;12:1626-1635.
- Leroux T, Wasserstein D, Dwyer T, et al. The epidemiology of revision anterior cruciate ligament reconstruction in Ontario, Canada. *Am J Sports Med.* 2014;42:2666-2672.
- Liberati A, Altman DG, Tetzlaff J, et al. The PRISMA statement for reporting systematic reviews and meta-analyses of studies that evaluate health care interventions: explanation and elaboration. *J Clin Epidemiol.* 2009;62:e1-e34.
- Marengoni A, Pasina L, Concoreggi C, et al. Understanding adverse drug reactions in older adults through drug-drug interactions. *Eur J Intern Med.* 2014;25:843-846.
- Marlovits S, Striessnig G, Schuster R, et al. Extended-duration thromboprophylaxis with enoxaparin after arthroscopic surgery of the anterior cruciate ligament: a prospective, randomized, placebo-controlled study. *Arthroscopy.* 2007;23:696-702.
- Marrala J, Morrissey MC, Haddad FS. A literature review of autograft and allograft anterior cruciate ligament reconstruction. *Knee Surg Sports Traumatol Arthrosc.* 2007;15:690-704.
- Michot M, Conen D, Holtz D, et al. Prevention of deep-vein thrombosis in ambulatory arthroscopic knee surgery: a randomized trial of prophylaxis with low-molecular weight heparin. *Arthroscopy.* 2002;18:257-263.
- Munoz L, Gonzalez AB, Diaz de Rada P, Valenti A, Valenti JR. Rivaroxaban is as efficient and safe as bemiparin as thromboprophylaxis in knee arthroscopy. *Musculoskelet Surg.* 2014;98:21-25.
- Raphael IJ, Tischler EH, Huang R, Rothman RH, Hozack WJ, Parvizi J. Aspirin: an alternative for pulmonary embolism prophylaxis after arthroplasty? *Clin Orthop Relat Res.* 2014;472:482-488.
- Russell RD, Hotchkiss WR, Knight JR, Huo MH. The efficacy and safety of rivaroxaban for venous thromboembolism prophylaxis after total hip and total knee arthroplasty. *Thrombosis.* 2013;2013:762310.
- Struijk-Mulder MC, Ettema HB, Verheyen CC, Büller HR. Deep vein thrombosis after arthroscopic anterior cruciate ligament reconstruction: a prospective cohort study of 100 patients. *Arthroscopy.* 2013;29:1211-1216.
- The University of Oxford Centre for Evidence Based Medicine. *The Oxford Levels of Evidence 2.* Oxford: Oxford Centre for Evidence Based Medicine; 2012.
- The University of York Centre for Reviews and Dissemination. International prospective register of systematic reviews. 2014. <http://www.crd.york.ac.uk/PROSPERO/>. Accessed December 4, 2014.
- Wang Z, Anderson FA Jr, Ward M, Bhattacharyya T. Surgical site infections and other postoperative complications following prophylactic anticoagulation in total joint arthroplasty. *PLoS One.* 2014;9:e91755.
- Williams JS Jr, Hulstyn MJ, Fadale PD, et al. Incidence of deep vein thrombosis after arthroscopic knee surgery: a prospective study. *Arthroscopy.* 1995;11:701-705.
- Wirth T, Schneider B, Misselwitz F, et al. Prevention of venous thromboembolism after knee arthroscopy with low-molecular weight heparin (reviparin): results of a randomized controlled trial. *Arthroscopy.* 2001;17:393-399.
- Ye S, Dongyang C, Zhihong X, et al. The incidence of deep venous thrombosis after arthroscopically assisted anterior cruciate ligament reconstruction. *Arthroscopy.* 2013;29:742-747.
- Yen SH, Lin PC, Kuo FC, Wang JW. Thromboprophylaxis after minimally invasive total knee arthroplasty: a comparison of rivaroxaban and enoxaparin. *Biomed J.* 2014;37:199-204.
- Yi S, Tan J, Chen C, Chen H, Huang W. The use of pneumatic tourniquet in total knee arthroplasty: a meta-analysis. *Arch Orthop Trauma Surg.* 2014;134:1469-1476.