

Endobronchial Ultrasound-guided Transbronchial Needle Aspiration Increases the Yield of Transbronchial Lung Biopsy for the Evaluation of Peribronchial Lesions

Cheng Chen¹, Chuan-Yong Mu², Mei-Qin Su¹, Jing-Yu Mao¹, Ye-Han Zhu¹, Jian-An Huang²

¹Respiratory Department, The First Affiliated Hospital of Soochow University, Suzhou, Jiangsu 215006, China

²Institute of Respiratory Diseases, Soochow University, Suzhou, Jiangsu 215007, China

Cheng Chen and Chuan-Yong Mu contributed equally to this work.

Abstract

Background: Due to absence of visible endobronchial target, the diagnostic yield of flexible bronchoscopy for peribronchial lesions has been unsatisfactory. Convex probe endobronchial ultrasound (CP-EBUS) has allowed for performing real-time transbronchial needle aspiration (TBNA) of enlarged hilar and mediastinal lymph nodes and therefore could also be used as a means of diagnosing proximal peribronchial lesions.

Methods: We retrospectively analyzed the results related to 72 patients who underwent CP-EBUS for peribronchial lesions without endobronchial involvement and adjacent to three-grade bronchi based on chest computed tomography (CT) scan. We recorded the images during EBUS as well as the diagnostic results of TBNA and conventional-transbronchial lung biopsy/brush (C-TBLB/b), and final diagnoses were based on pathologic analysis and follow-up.

Results: In all cases, the mass was able to be identified using EBUS in 97.2% patients (70/72) who were performed with EBUS-TBNA + C-TBLB/b. Sixty-six patients had a final diagnosis, 80.0% patients (56/70) had malignancies, and 14.3% patients (10/70) had benign disease. In malignancies, the diagnostic yield of C-TBLB/b was 57.1% (32/56) and in EBUS-TBNA was 85.7% (48/56), whereas pathologic diagnosis reached 94.6% when EBUS-TBNA was combined with C-TBLB/b. C-TBLB/b + EBUS-TBNA also exhibited stronger potency of histolytic diagnosis for malignancies than either EBUS-TBNA or C-TBLB/b alone. Furthermore, there are data supporting the value of EBUS-TBNA for the diagnosis of benign lung disease.

Conclusion: The combined endoscopic approach with EBUS-TBNA and C-TBLB/b is an accurate and effective method for the evaluation of peribronchial lesions, with better results than using each technique alone.

Key words: Endobronchial Ultrasound Transbronchial Needle Aspiration; Peribronchial Lesions; Transbronchial Lung Biopsy

INTRODUCTION

The proper diagnosis and staging of lung cancer is critical for the optimal management of these patients. For central, endobronchial lesions, bronchoscope-guided biopsies are preferred as they have shown an acceptable yield. However, in the absence of a visible endobronchial target, the diagnostic yield was not satisfactory.^[1]

The endobronchial ultrasound-guided transbronchial needle aspiration (EBUS-TBNA) was initially developed for lymph node staging of lung cancer, which allowed real-time biopsy of the mediastinal and hilar lymph nodes. It has been shown to

be highly effective in the nodal staging of nonsmall cell lung cancer (NSCLC) and benign granulomatous disorders.^[2-4]

Compared to common site of mediastinal and hilar lymph nodes, the indications for TBNA of peribronchial

Address for correspondence: Prof. Jian-An Huang,
Institute of Respiratory Diseases, Soochow University,
Suzhou, Jiangsu 215007, China
E-Mail: huang_jian_an@163.com

This is an open access article distributed under the terms of the Creative Commons Attribution-NonCommercial-ShareAlike 3.0 License, which allows others to remix, tweak, and build upon the work non-commercially, as long as the author is credited and the new creations are licensed under the identical terms.

For reprints contact: reprints@medknow.com

© 2017 Chinese Medical Journal | Produced by Wolters Kluwer - Medknow

Received: 01-08-2016 **Edited by:** Qiang Shi

How to cite this article: Chen C, Mu CY, Su MQ, Mao JY, Zhu YH, Huang JA. Endobronchial Ultrasound-guided Transbronchial Needle Aspiration Increases the Yield of Transbronchial Lung Biopsy for the Evaluation of Peribronchial Lesions. *Chin Med J* 2017;130:11-4.

Access this article online

Quick Response Code:



Website:
www.cmj.org

DOI:
10.4103/0366-6999.196567

lesion remained limited. Here, we aimed to evaluate the diagnostic yield of EBUS-TBNA to peribronchial lung lesions suspicious for malignancy, with no visible lesions on bronchoscopy.

METHODS

Patients

We completed a retrospective chart review of 72 patients with peribronchial lung lesions suspicious for malignancy with no visible lesions on bronchoscopy in The First Affiliated Hospital of Soochow University between January 2015 and August 2016. All patients provided written informed consent. Data of patients' age, gender, location of lesion, pathologic analysis, EBUS-TBNA, and conventional-transbronchial lung biopsy/brush (C-TBLB/b) usage were extracted from patient records.

Endobronchial ultrasound-guided transbronchial needle aspiration

All cases were performed by experienced interventional pulmonologists. EBUS-TBNA was performed due to both lack of an endobronchial target and adjacent to three grade bronchi based on chest computed tomography (CT) scan using a 21- or 22-gauge needle (Olympus Medical Systems, Japan). Once the target lesion had been visualized by ultrasound, a dedicated needle was assessed through the working channel of the EBUS bronchoscope and punctured through the tracheobronchial wall into the lesion under real-time ultrasound visualization. After EBUS-TBNA, C-TBLB/b was performed.

Final diagnosis

If improvement was seen on CT 3 months after EBUS-TBNA and/or C-TBLB/b, the lesions were regarded as benign. If EBUS-TBNA and/or C-TBLB/b did not result in a formal pathological diagnosis of malignancy, patients were referred for a transthoracic needle aspiration biopsy or a surgical diagnostic procedure.

Statistical analysis

The positive findings from the biopsy were regarded as true-positive results in our analysis. Diagnostic sensitivity, specificity, accuracy, false negative rate, false positive rate, positive predicted value, negative predicted value, negative likelihood ratio, and Youden index were analyzed.

RESULTS

Patient characteristics

A total of 72 patients met the inclusion criteria. Median age was 64 years (range: 19–83 years), with 68.1% (49/72) being male patients. In all patients, the mass was able to be identified using EBUS in 97.2% (70/72), and 91.7% (66/72) had a final diagnosis, 56 patients had malignancies, ten patients had benign diseases [Table 1]. Representative images of EBUS-TBNA during the evaluation of lung lesions are shown in Figures 1–2.

Diagnostic parameters of endobronchial ultrasound-guided transbronchial needle aspiration in malignant and benign diseases

The diagnostic sensitivity, specificity, accuracy, false negative rate, false positive rate, positive predicted value, negative predicted value, positive likelihood ratio, negative likelihood ratio, Youden index of EBUS-TBNA for benign diseases, malignancies, and all diseases (benign and malignant diseases) are shown in Table 2. EBUS-TBNA exhibited good sensitivity and specificity, especially the specificity to malignancies and sensitivity to benign diseases.

Diagnostic yield of endobronchial ultrasound-guided transbronchial needle aspiration in malignancies

In malignancies ($n = 56$), only using EBUS-TBNA, the pathologic diagnosis would be missed in eight patients if additional biopsy was not performed concomitantly. Similarly, the pathologic diagnosis would be missed in

Table 1: Patient's final diagnosis and efficacy of C-TBLB/b and/or EBUS-TBNA

Type of disease	Final diagnosis	C-TBLB/b	EBUS-TBNA	C-TBLB/b + EBUS-TBNA
Malignant	56	32	48	53
Squamous cell carcinoma	8	6	8	8
Adenocarcinoma	25	11	21	22
Small cell lung cancer	6	6	4	6
Poor differentiated carcinoma	5	1	5	5
Metastatic carcinoma	2	1	1	2
Large cell carcinoma	1	0	1	1
Adenosquamous carcinoma	1	1	0	1
Inconclusive type	8	6	8	8
Benign	10	5	8	10
Lung abscess	2	0	2	2
Organizing pneumonia	1	0	1	1
Pulmonary aspergillosis	2	0	2	2
Pneumonia	3	3	3	3
Granuloma	2	2	0	2

C-TBLB/b: Conventional-transbronchial lung biopsy/brush; EBUS-TBNA: Endobronchial ultrasound-guided transbronchial needle aspiration.

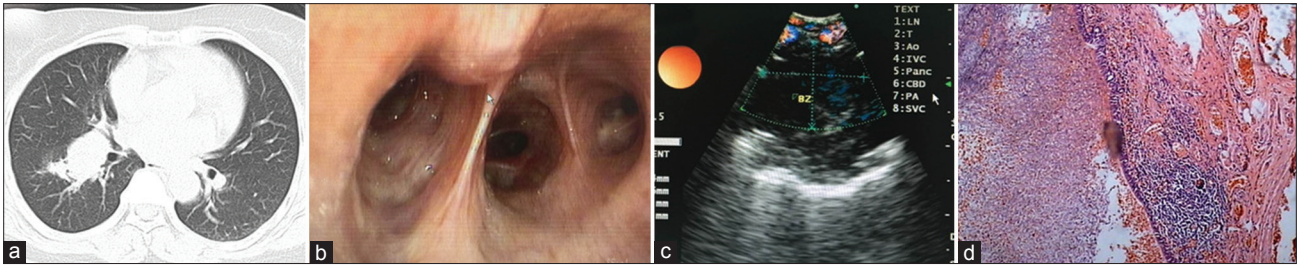


Figure 1: EBUS-TBNA in the evaluation of pulmonary aspergillosis. (a) Computerized scan of the chest showing right lower lobe lung mass. (b) No visible lesions were detected by bronchoscopy. (c) Endobronchial ultrasound image demonstrating the mass. (d) Pathological analysis confirmed the pulmonary aspergillosis (H and E staining, original magnification $\times 40$). EBUS-TBNA: Endobronchial ultrasound-guided transbronchial needle aspiration.

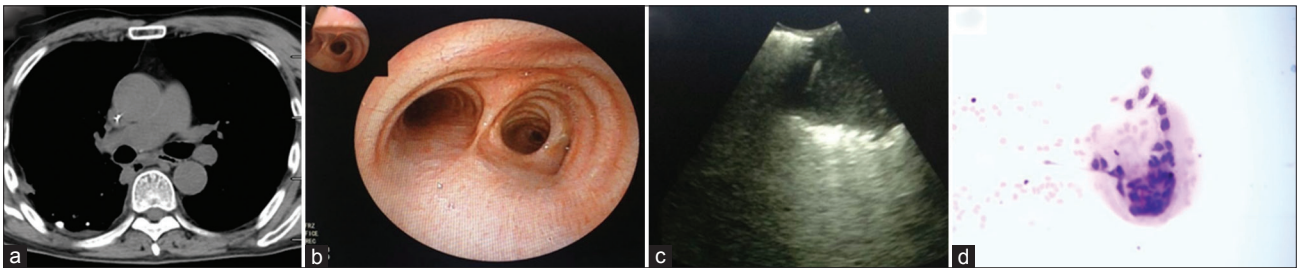


Figure 2: EBUS-TBNA in the evaluation of lung squamous carcinoma. (a) Computerized tomography scan of the chest showing right lower lobe lung mass. (b) No visible lesion was detected by bronchoscopy. (c) Endobronchial ultrasound image demonstrated the needle within the mass. (d) Pathological analysis showed the squamous carcinoma (H and E staining, original magnification $\times 40$). EBUS-TBNA: Endobronchial ultrasound-guided transbronchial needle aspiration.

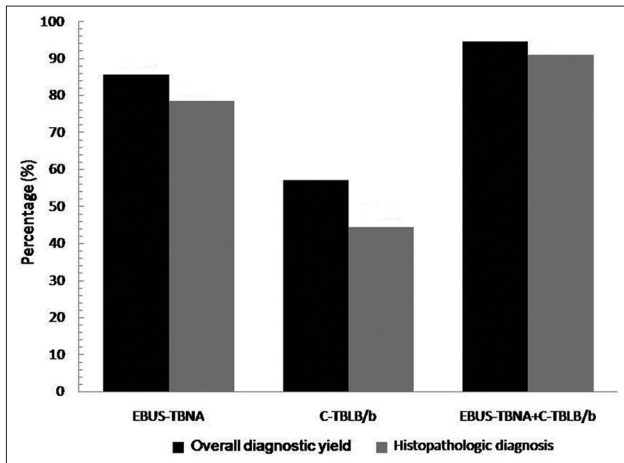


Figure 3: Diagnostic yield of EBUS-TBNA in malignancies ($n = 56$). C-TBLB/b, conventional-transbronchial lung biopsy/brush. EBUS-TBNA: Endobronchial ultrasound-guided transbronchial needle aspiration; C-TBLB/b: Conventional-transbronchial lung biopsy/brush.

12 patients if EBUS-TBNA was not concomitantly used with C-TBLB/b. Hence, in the case of combining C-TBLB/b and EBUS-TBNA, pathologic diagnosis would be missed in only three patients. Overall, as shown in Figure 3, the diagnostic yield of EBUS-TBNA was 85.7% (48/56), the yield of C-TBLB/b was 57.1% (32/56), whereas pathologic diagnosis would reach 94.6% (53/56) if EBUS-TBNA was combined with C-TBLB/b.

Histological diagnosis was successfully obtained in 78.6% (44/56) patients using EBUS-TBNA alone, in

Table 2: Diagnostic parameters of EBUS-TBNA in peribronchial lesions ($n = 70$)

Items	Benign	Malignant	Benign + malignant
Sensitivity (%)	100	85.7	87.9
Specificity (%)	85.7	100	100
Accuracy (%)	87.9	87.8	88.6
False negative rate (%)	0	14.3	12.1
False positive rate (%)	85.7	0	0
Positive predictive value (%)	55.6	100	100
Negative predictive value (%)	100	55.6	33.3
Positive likelihood ratio	1.2	—	—
Negative likelihood ratio	0	14.3	12.1
Youden index	0.86	0.86	0.88

—: Not applicable; EBUS-TBNA: Endobronchial ultrasound-guided transbronchial needle aspiration.

44.6% (25/56) patients using C-TBLB/b alone, and in 91.1% (51/56) using C-TBLB/b combined with EBUS-TBNA. Of all patients, 54.2% (25/48) patients had diagnosis of adenocarcinoma cell carcinoma using EBUS-TBNA, which was the most common pathologic type.

DISCUSSION

The conventional indications for EBUS-TBNA mainly include lymph node staging for lung cancer and diagnosing mediastinal/hilar lesions. Furthermore, it has been reported that the sensitivity and specificity of using EBUS in

determining invasion of the trachea and bronchus by tumors were significantly higher than that of using CT and magnetic resonance imaging.^[5] In the present study, we investigated the efficacy of combined EBUS-TBNA and C-TBLB/b in peribronchial lung lesions suspicious for malignancy.

The outer diameter is a limiting factor which means convex probe endobronchial ultrasound (CP-EBUS) can only be inserted as far as the upper lobar bronchi and lower lobar basal segmental bronchi. We were able to complete the procedures in all but two patients, whose ultrasound images of the target lesion during EBUS-TBNA were unable to be acquired. When adequate ultrasound images were obtainable, EBUS-TBNA of peribronchial lung lesions showed a high diagnostic yield. We did not have any specific difficulty in using either 21- or 22-gauge needle. There were no complications and no damage to the bronchoscope. We did not obtain any false-positive result that did not match our clinical suspicion. Overall, we demonstrated better diagnostic yield with the combined approach than with either EBUS-TBNA or C-TBLB/b alone.

Obtaining a tissue diagnosis of malignancy is challenging in patients with suspected lung cancer. Here, we were able to get sufficient sample for histological diagnosis purpose, which is consistent with the findings of Navani *et al.*,^[6] who have shown that EBUS-TBNA can provide adequate samples for subtyping of NSCLC.

It has been shown that conventional-TBNA had a higher diagnostic yield in malignancies than in the nonmalignant lesions. Choi *et al.*^[7] also reported that the diagnostic accuracy of EBUS-TBNA was higher for malignant diseases than for benign diseases. However, in other studies, the diagnostic accuracy of EBUS-TBNA for benign granulomatous disorders was not significantly different from that observed for malignant diseases.^[8,9] We suggest that CP-EBUS allows for performing real-time TBNA of the lesion, which might greatly improve the accuracy of the aspiration.

Taken together, EBUS-TBNA might be a sensitive tool for the diagnosis of peribronchial located primary lung cancer which is not visible with conventional bronchoscopy. The combination of EBUS-TBNA and C-TBLB/b might be favored for patients with suspected peribronchial lesions.

Financial support and sponsorship

This work was supported by grants from the Clinical Medicine Center of Suzhou (No. SZZX201502), the Societal and Developmental Project of Suzhou (No. SS201630), and Suzhou Key Laboratory for Respiratory Medicine (No. SZS201617).

Conflicts of interest

There are no conflicts of interest.

REFERENCES

1. Schwarz Y, Greif J, Becker HD, Ernst A, Mehta A. Real-time electromagnetic navigation bronchoscopy to peripheral lung lesions using overlaid CT images: The first human study. *Chest* 2006;129:988-94. doi: 10.1378/chest.129.4.988.
2. Yasufuku K, Chiyo M, Koh E, Moriya Y, Iyoda A, Sekine Y, *et al.* Endobronchial ultrasound guided transbronchial needle aspiration for staging of lung cancer. *Lung Cancer* 2005;50:347-54. doi: 10.1016/j.lungcan.2005.07.013.
3. Yasufuku K, Chiyo M, Sekine Y, Chhajed PN, Shibuya K, Iizasa T, *et al.* Real-time endobronchial ultrasound-guided transbronchial needle aspiration of mediastinal and hilar lymph nodes. *Chest* 2004;126:122-8. doi: 10.1378/chest.126.1.122.
4. Wong M, Yasufuku K, Nakajima T, Herth FJ, Sekine Y, Shibuya K, *et al.* Endobronchial ultrasound: New insight for the diagnosis of sarcoidosis. *Eur Respir J* 2007;29:1182-6. doi: 10.1183/09031936.00028706.
5. Herth F, Ernst A, Schulz M, Becker H. Endobronchial ultrasound reliably differentiates between airway infiltration and compression by tumor. *Chest* 2003;123:458-62. doi: org/10.1378/chest.123.2.458.
6. Navani N, Brown JM, Nankivell M, Woolhouse I, Harrison RN, Jeebun V, *et al.* Suitability of endobronchial ultrasound-guided transbronchial needle aspiration specimens for subtyping and genotyping of non-small cell lung cancer: A multicenter study of 774 patients. *Am J Respir Crit Care Med* 2012;185:1316-22. doi: 10.1164/rccm.201202-0294OC.
7. Choi YR, An JY, Kim MK, Han HS, Lee KH, Kim SW, *et al.* The diagnostic efficacy and safety of endobronchial ultrasound-guided transbronchial needle aspiration as an initial diagnostic tool. *Korean J Intern Med* 2013;28:660-7. doi: 10.3904/kjim.2013.28.6.660.
8. Agarwal R, Srinivasan A, Aggarwal AN, Gupta D. Diagnostic value of endobronchial ultrasound-guided transbronchial needle aspiration in arious lung diseases. *Respir Med* 2012;106:883-92. doi: 10.1016/j.rmed.2012.02.014.
9. Sun J, Teng J, Yang H, Li Z, Zhang J, Zhao H, *et al.* Endobronchial ultrasound-guided transbronchial needle aspiration in diagnosing intrathoracic tuberculosis. *Ann Thorac Surg* 2013;96:2021-7. doi: 10.1016/j.athoracsur.2014.09.029.