

[ EDITORIAL ]

# Standard and Novel Additional (Optional) Therapy for Lung Abscess by Drainage Using Bronchoscopic Endobronchial Ultrasonography with a Guide Sheath (EBUS-GS)

Makoto Miki

**Key words:** lung abscess, percutaneous transthoracic drainage, endoscopic drainage, EBUS-GS

(Intern Med 58: 1-2, 2019)

(DOI: 10.2169/internalmedicine.0968-18)

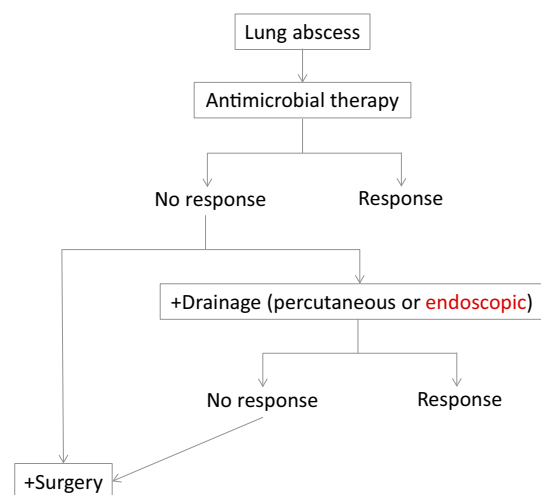
Lung abscess is an acute (<6 weeks) or chronic (>6 weeks) microbial infectious disease of the lung that causes necrosis of the pulmonary parenchymal tissues and the formation of cavities. It is often complicated to manage and treat, and is potentially life-threatening. A report from Massachusetts General Hospital indicated that the mortality rate in the period from 1909 to 1923 (before the antibiotic era) was 75% (1). Drainage reduced the mortality rate to 20-35%. Now, in the 21st century, appropriate antimicrobial therapy has further reduced the rate to 1.0-8.7% (2-5).

Lung abscess is mostly caused by the aspiration of oral anaerobic bacteria, including - but not limited to - *Peptostreptococcus* species, *Bacteroides* species, and *Fusobacterium* species. Antibiotics are usually administered as the initial medical treatment for lung abscess, and the patient's response is checked. Although around 80% of lung abscess patients are successfully treated with antibiotics covering anaerobes, when conservative therapy fails, invasive therapy with drainage or surgery is required (6-8) (Figure). Approximately 10% of patients undergo surgical resection in the acute and chronic phase (9).

Drainage is a very useful treatment for abscesses anywhere in the body. If possible, drainage should be performed in addition to antimicrobial therapy for lung cases. Either percutaneous or endoscopic approaches can be used for the tube drainage of lung abscesses. Percutaneous transthoracic drainage (PTD) was first described in 1938 (10) and endoscopic drainage (ED) with bronchoscopy was first reported in 1954 (6). The most suitable timing for the initiation of tube drainage and the optimum duration of drainage has not to be determined. When no improvement is achieved at 10 to 14 days after medical treatment, drainage therapy is indicated (11), and should be performed as soon

as possible, especially for refractory lung abscesses (12, 13). PTG has been performed more frequently than ED; ED is alternative to PTG that is used to treat cases involving central abscesses distant from the pleura in which there is a risk of puncturing the normal lung tissue (14) (Table). In ED, a guidewire is first inserted into the bronchus leading to the cavity through the working channel of the bronchoscope.

Selective bronchography is then performed to identify the location of the guidewire, and a catheter is slipped over the guidewire into the cavity (14, 15). Recently endoscopic ultrasonography with a guide sheath (EBUS-GS) has often been used for the diagnosis of pulmonary peripheral le-



**Figure.** Algorithm of treatment for lung abscess. lung abscess should be firstly treated with antibiotics covering anaerobe. When the antimicrobial therapy fails, the invasive therapy with drainage or surgery will be required. There are two methods in drainage, percutaneous and endoscopic.

**Table. The Comparison of Percutaneous Transthoracic Drainage (PTD) and Endoscopic Drainage (ED) for Lung Abscess.**

	PDG	ED
Safety	moderate	moderate
Contraindication	coagulopathy, central abscess	respiratory failure, coagulopathy
Complication	bleeding, pneumothorax bacterial seeding	bleeding, hypoxemia
Success rate	more than 70%	recently nearly 100%
Mortality rate	4.0%	-

(Adapted from vanSonnenberg E, et al. Radiology 1991; 178: 347-351 and Wali SO. Ann Thorac Med 2012; 7: 3-7)

sions (16). Izumi et al. (17) and Takaki et al. (18) applied EBUS-GS to the treatment of lung abscesses. With this technique, we can easily select the appropriate bronchus instead of using the classical method of bronchography, and drainage can be performed more safely. The causative bacterial pathogen was detected in 80% of their five cases, the treatment success rate with suitable antibiotics was 100%, the mortality rate was 0%, and no serious adverse events occurred (17, 18). Takaki's modified guide sheath in which two small holes are punched on the tip seems to be more effective than the usual type in terms of drainage efficiency. This procedure might have the advantages of detecting the causative pathogens and facilitate early infectious source control by allowing the selection of an appropriate antibiotic, which might make the duration of antimicrobial therapy shorter.

There are still unsolved clinical questions in relation to the treatment of refractory lung abscesses, and studies should be performed to accumulate more clinical evidence.

**The author states that he has no Conflict of Interest (COI).**

## References

- Lord FT. Certain aspects of pulmonary abscess, from analysis of 227 cases. *Boston Med Surg J* **192**: 785-788, 1925.
- Mansharamani N, Balachandran D, Delaney D, et al. Lung abscess in adults: clinical comparison of immunocompromised to non-immunocompromised patients. *Respir Med* **96**: 178-185, 2002.
- Wang JL, Chen KY, Fang CT, et al. Changing bacteriology of adult community-acquired lung abscess in Taiwan: *Klebsiella pneumoniae* versus anaerobes. *Clin Infect Dis* **40**: 915-922, 2005.
- Moreira Jda S, Camargo Jde J, Felicetti JC, et al. Lung abscess: analysis of 252 consecutive cases diagnosed between 1968 and 2004. *J Bras Pneumol* **32**: 136-143, 2006.
- Takayanagi N, Kagiyama N, Ishiguro T, et al. Etiology and outcome of community-acquired lung abscess. *Respiration* **80**: 98-105, 2010.
- Metras H, Chapin J. Lung abscess and bronchial catheterisation. *J Thorac Surg* **27**: 157-159, 1954.
- Klein JS, Schultz S, Heffner JE. Interventional radiology for the chest: Imaging-guided percutaneous drainage of epidural effusions, lung abscess, and pneumothorax. *AJR* **165**: 581-588, 1995.
- Herth F, Ernst A, Becker HD. Endoscopic drainage of lung abscesses: technique and outcome. *Chest* **127**: 1378-1381, 2005.
- Kuhajda I, Zarogoulidis K, Tsirgogianni K, et al. Lung abscess-etiology, diagnostic and treatment options. *Ann Transl Med* **3**: 183, 2015.
- Neuhof H, Touroff ASW. Acute putrid abscess of the lung. Hyperacute variety. *J Thorac Surg* **12**: 98-106, 1942.
- Parker LA, Melton JW, Delany DJ, Yankeskas BC. Percutaneous small bore catheter drainage in the management of lung abscesses. *Chest* **92**: 213-218, 1987.
- Weissberg D. Percutaneous drainage of lung abscess. *J Thorac Cardiovasc Surg* **87**: 308-312, 1984.
- vanSonnenberg E, D'Agostino HB, Casola G, Wittich GR, Varney RR, Harker C. Lung abscess: CT-guided drainage. *Radiology* **178**: 347-351, 1991.
- Wali SO. An update on the drainage of pyogenic lung abscesses. *Ann Thorac Med* **7**: 3-7, 2012.
- Loukeri AA, Kampolis CF, Tomos P, et al. Diagnosis, treatment and prognosis of lung abscess. *Pneumon* **28**: 54-60, 2015.
- Kurimoto N, Miyazawa T, Okimasa S, et al. Endobronchial ultrasonography using a guide sheath increases the ability to diagnose peripheral pulmonary lesions 174 endoscopically. *Chest* **126**: 959-965, 2004.
- Izumi H, Kodani M, Matsumoto S, et al. A case of lung abscess successfully treated by transbronchial drainage using a guide sheath. *Respirol Case Rep* **5**: e00228, 2017.
- Takaki M, Tsuyama N, Ikeda E, et al. The transbronchial drainage of a lung abscess using endobronchial ultrasonography with a modified guide sheath. *Intern Med* **58**: 97-100, 2019.

The Internal Medicine is an Open Access journal distributed under the Creative Commons Attribution-NonCommercial-NoDerivatives 4.0 International License. To view the details of this license, please visit (<https://creativecommons.org/licenses/by-nc-nd/4.0/>).