Journal of Rural Medicine

Case report

Advanced esophagogastric junction cancer with brain, bone and gastric intramural metastases responding to combined modality therapy

Takehiro Takagi[1], Satoshi Kobayashi[1], Atsushi Sekimura[1], Kenichi Komaya[1], Yuji Yamauchi, and Akihiro Hori[1]

[1]*Department of Surgery, Gifu Kouseiren Kumiai Kousei Hospital, Japan*

Abstract

A 63-year-old man was admitted to our hospital in March 2017 with dysphagia and right homonymous hemianopsia. We diagnosed him with esophagogastric junction cancer (adenocarcinoma) with metastases to the cerebral occipital lobe, bone, and lymph nodes. After one cycle of 5FU + cisplatin (FP), the brain metastasis was resected because of the hemiplegic symptoms he developed. Histology of the resected tissue showed no viable tumor cells. After three cycles of FP, the primary lesion and metastases were resolved. Upper gastrointestinal endoscopy revealed a scar at the primary site. This was considered a complete response (CR). In April 2018, CT revealed a mass at the cardia, which was considered as lymph node metastases with gastric wall invasion. Although two additional cycles of FP were administered for recurrent tumors, the efficacy was progressive. In August 2018, proximal gastrectomy and D1 + lymph node dissection were performed. The pathological diagnosis was gastric intramural metastases and lymph node metastases (ypN1 [2/22]). Weekly paclitaxel therapy was administered for three months after surgery. Two years have passed since the last surgery without recurrence. We report a rare case of esophagogastric junction cancer with brain, bone, and gastric intramural metastases that responded to combined modality therapy.

Key words: esophagogastric junction cancer, gastric intramural metastases, bone metastasis, combined modality therapy

(J Rural Med 2021; 16(3): 179–183)

Introduction

Clinical studies have reported that metastasis from gastric cancer (GC) usually occurs in the abdominal cavity, such as the peritoneum, lymph nodes, and liver. Bone or gastric intramural metastasis from GC is also less common[1)]. The presence of these metastases is thought to be a poor prognostic factor for GC. This case report presents a rare case of esophagogastric junction cancer with brain, bone, and gastric intramural metastases successfully treated with a multidisciplinary approach including chemotherapy and surgery.

Received: November 18, 2020
Accepted: April 12, 2021
Correspondence: Takehiro Takagi, Department of Surgery, Gifu Kouseiren Kumiai Kousei Hospital, 1-1 Nakagiri-cho, Takayama-shi, Gifu 506-8502, Japan
E-mail: gogominicooper2000@yahoo.co.jp

Case Report

A 63-year-old man was admitted to our hospital in March 2017 with dysphagia and right homonymous hemianopsia. Head computed tomography (CT) and magnetic resonance imaging revealed a cerebral tumor in the left occipital lobe, and cerebral edema around the lesion (Figure 1A, 1B). Abdominal CT showed thickened esophagogastric junction wall and swelling of the cardia lymph nodes. Gastrointestinal endoscopy indicated type II advanced esophagogastric junction cancer, and the biopsy specimen revealed poorly differentiated adenocarcinoma (Figure 2A). Serum levels of carcinoembryonic antigen (CEA) and carbohydrate antigen 19-9 (CA 19-9) were within normal ranges. Fluorine-18 fluorodeoxyglucose positron emission tomography (PET) revealed abnormal uptake within the esophagogastric junction, cardia lymph nodes, and left femoral bone (Figure 2B). A biopsy specimen of the femoral bone mass revealed poorly differentiated adenocarcinoma. Based on these clinical and pathological findings, the patient was diagnosed with Siew-

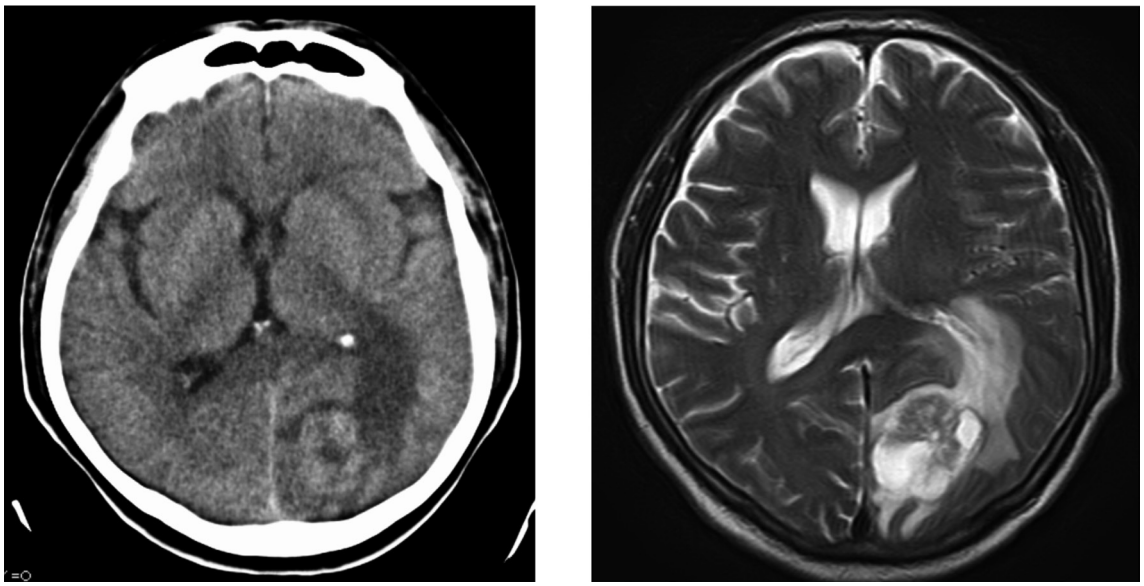

Figure 1 A. Head computed tomography scan revealing a cerebral tumor in the left occipital lobe. B. Head magnetic resonance image showing cerebral edema around the cerebral tumor.

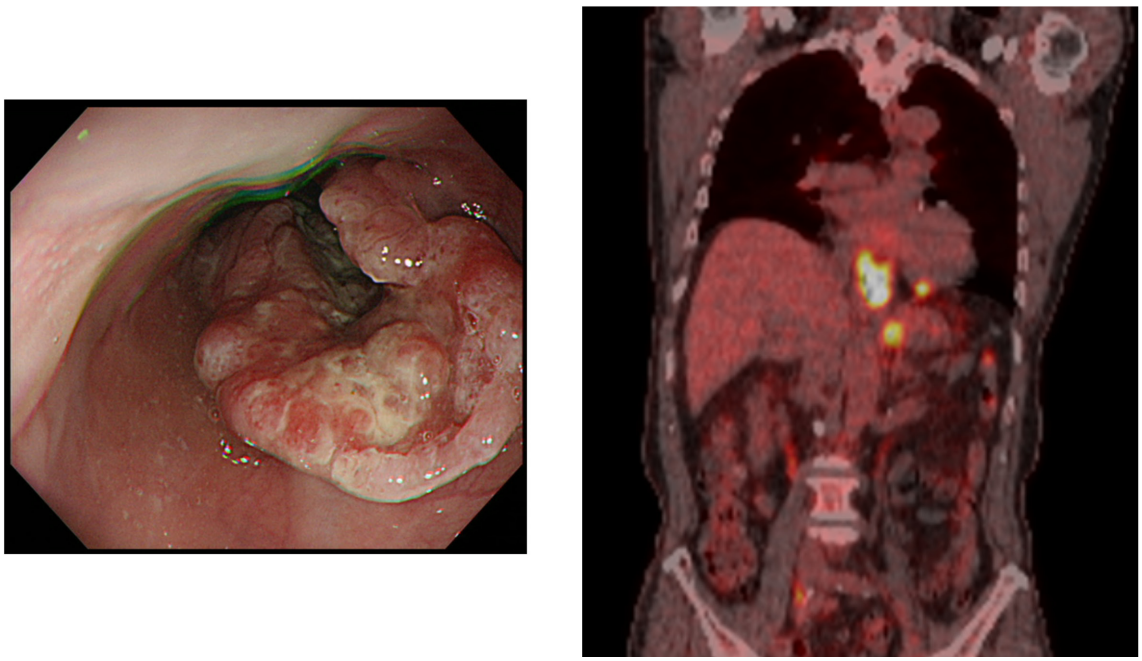

Figure 2 A. Esophagogastroduodenoscopy showing type 2 advanced esophagogastric junction cancer. B. Positron emission tomography scan indicating abnormal uptake within the esophagogastric junction, cardia lymph nodes and left femur.

ert type I esophagogastric junction adenocarcinoma with metastasis to the lymph nodes, brain, and bone. The clinical stage was T3 N1 M1, stage IV, according to the Japanese classification for esophageal cancer, 11th edition. Considering the progressive nature of the disease, the patient was commenced on chemotherapy (5FU + cisplatin [FP]). 5FU (800 mg/m^2 body surface area) was administered intravenously from day one to day five, and cisplatin (80 mg/m^2 body surface area) was administered intravenously on day one. After one cycle of FP, hemiplegic symptoms were observed. Magnetic resonance imaging with fat-saturation sequences showed increased internal serous fluid and thinning of the tumor contrast area (Figure 3A, 3B). The brain metastasis to the left occipital lobe was resected. Pathological examinations showed no viable tumor cells. After the surgery, the hemiplegia improved. After three cycles of FP, the

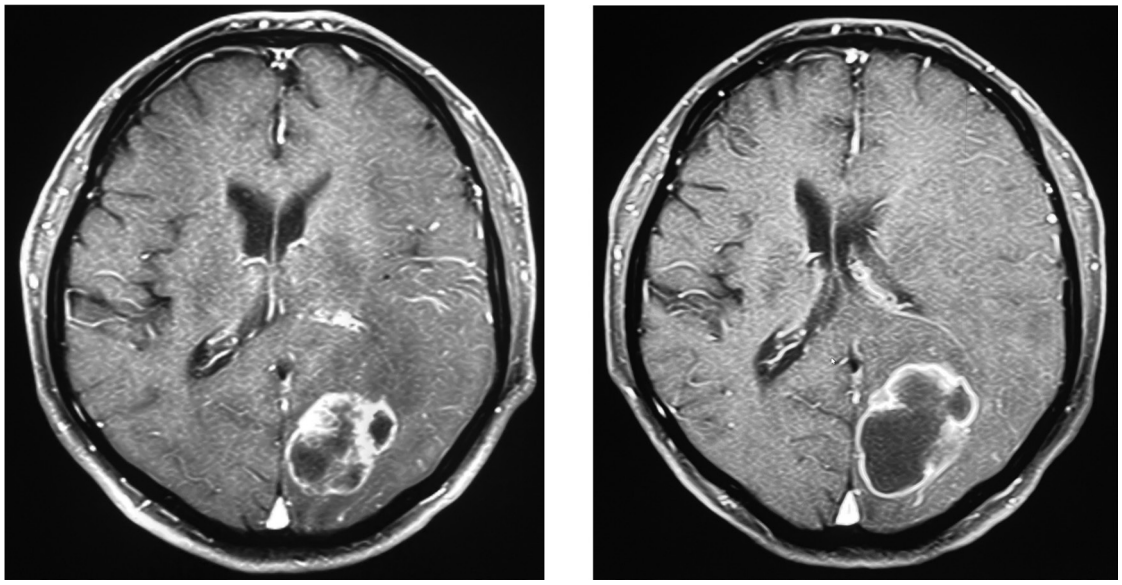

Figure 3 A. Magnetic resonance image with fat-saturation sequences before 5FU + cisplatin (FP) and after FP (Figure 3B) showing increased internal serous fluid and thinning of the tumor contrast area.

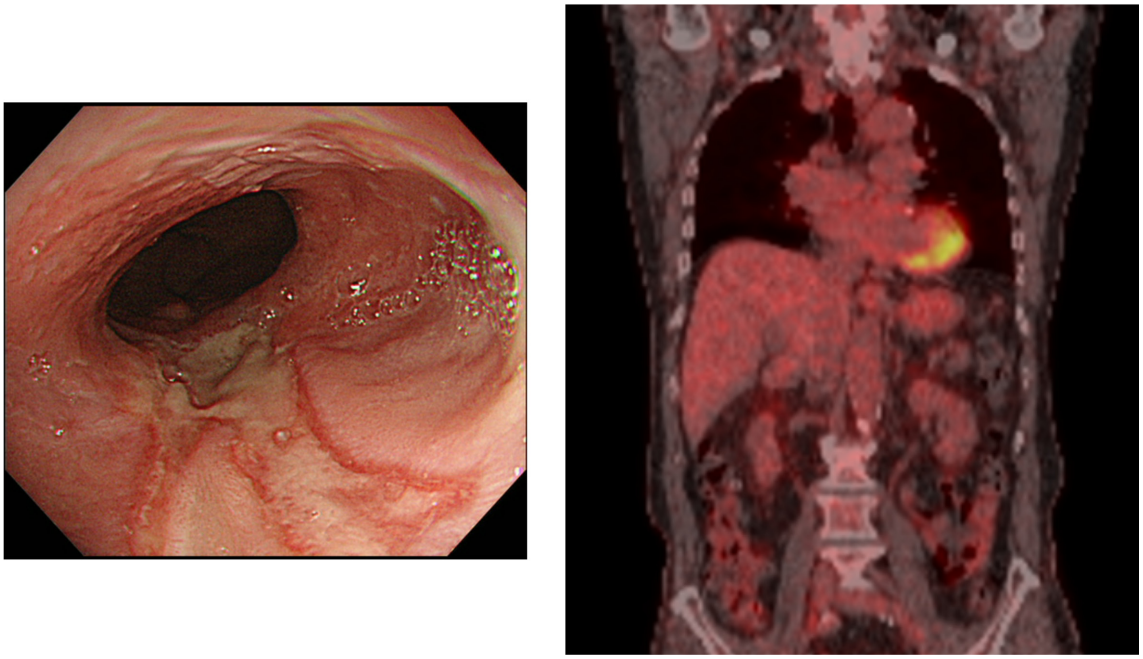

Figure 4 A. Esophagogastroduodenoscopy after three cycles of 5FU + cisplatin (FP). B. Abnormal uptake in positron emission tomography within the esophagogastric junction, cardia lymph nodes and left femur markedly disappeared after three cycles of FP.

primary lesion and metastases were found to have resolved on abdominal CT. Upper gastrointestinal endoscopy showed that the tumor had resolved, and only an area of ulceration was observed (Figure 4A). Abnormal uptake in PET within the esophagogastric junction, cardia lymph nodes, and left femoral bone was completely absent on repeat PET (Figure 4B). This was considered a complete response (CR). Subsequently, S-1 (100 mg/day) was administered orally for seven months. In April 2018, the CEA level had increased to 25.5 ng/ml, and CT revealed a mass at the cardia, which was considered to be lymph node metastases with gastric wall invasion (Figure 5A). Despite the two additional cycles of FP, the efficacy was progressive. In August 2018, proximal gastrectomy and D1 + lymph node dissection were per-

formed (Figure 5B). No postoperative complications were observed. The patient was discharged on the tenth day after surgery. Pathological examination of the intramural tumor showed no lymph node structure and it covered with normal gastric mucosa and serosa. We made a pathological diagnosis of gastric intramural metastatic adenocarcinoma (por 1 > tub 2) with extensive hemorrhagic necrosis due to chemotherapy and lymph node metastases (ypN1 [2/22]). CEA had decreased from 56.9 to 4.7 ng/ml (Figure 6). Weekly paclitaxel (160 mg/day) therapy was administered for three months after the surgery. It has been 42 months since the patent's first visit and 26 months since the last surgery, and he is alive without any feature of recurrence.

Discussion

The major feature of recurrence in patients with GC is intra-abdominal spread. Bone metastasis from GC is rare, occurring in only 0.9–3.8% of GC patients[2–4]. Furthermore, intramural metastases from GC are also rare, occurring in only 0.6% of GC[5]. This case was a rare esophagogastric junction cancer with brain, bone, and recurrent gastric intramural metastases.

Even more surprisingly, this case had multidisciplinary treatment with a combination of two surgeries and chemotherapy, resulting in a curative response, and currently 26 months recurrence-free. The median survival for patients

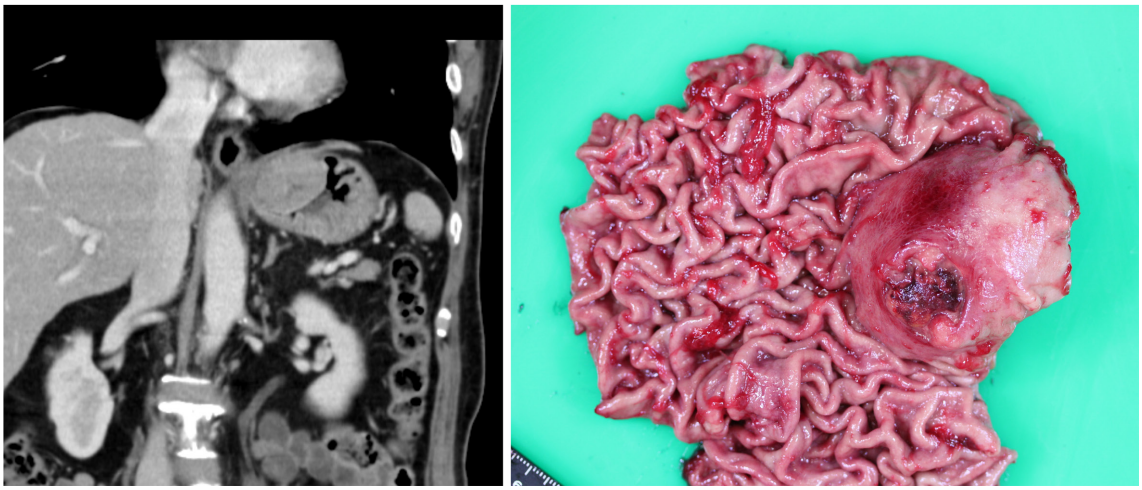

Figure 5 A. Computed tomography scan showing a mass at the cardia, which was diagnosed as intramural metastasis of gastric cancer after surgery. B. Resected specimen of proximal gastrectomy for intramural metastasis of gastric cancer.

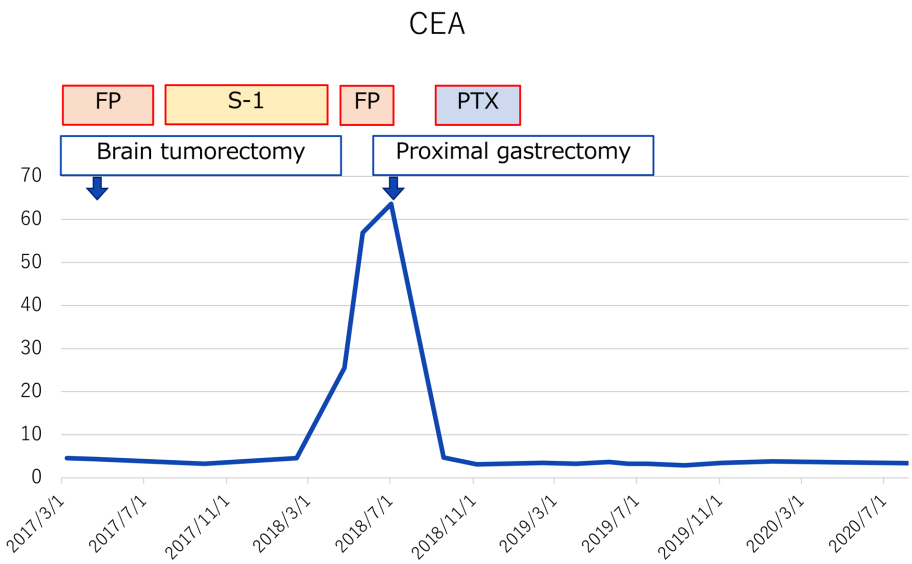

Figure 6 Information of this case report has been organized into a timeline with carcinoembryonic antigen levels throughout the whole treatment course.

with bone and brain metastasis from GC is four months and three months, respectively[6]. The prognosis is even worse (two months) if both bone and brain metastases occur concurrently[6]. The presence of intramural metastases is thought to be a poor prognostic factor for GC[5]. It is interesting that this case, which has many poor prognostic factors, had a curative response and long-term survival.

For patients with single brain tumors, local treatments such as surgery and radiation therapy are generally performed. GC is considered a solid cancer that is not highly sensitive to chemotherapy. The brain tumor treatment guidelines published by the Japan society for neuro-oncology in 2019 recommended that general chemotherapy should be limited to brain tumors with extracranial lesions and with no symptoms due to the brain metastases[7]. Because of the blood-brain barrier, it is generally difficult for drugs to reach brain tumors, the main purpose for this provision is for the effect on the extracranial lesions. Therefore, despite administration of chemotherapy (5FU + cisplatin) in our case, when he developed hemiplegia, the brain metastasis in the left occipital lobe had to be resected. The surgery was performed early because of the patient's symptoms. Magnetic resonance imaging after FP showed thinning of the tumor contrast area and increased internal serous fluid, which is thought to have caused neurological symptoms. Brain tumorectomy was very effective in treating the hemiplegia. Pathological examinations of the resected tumor showed no viable cancer cells. Surprisingly, cytotoxic chemotherapy, which is thought to be usually ineffective against brain metastases, was significantly effective against brain metastasis in this case.

Bone metastases from GC are often multiple and rarely resected. Radiation therapy is effective for pain but has not been reported to improve the prognosis. Chemotherapy, in contrast, has been reported to significantly improve the prognosis[3, 4]. This patient had a single bone metastasis and radiation therapy was also considered. However, chemotherapy resulted in radiological CR; this was thought to have contributed to the good course.

Esophageal squamous cell carcinoma is often accompanied by intramural metastases, and such cases have been reported to have a poor prognosis[8]. Hashimoto *et al.* reported intramural metastasis in GC to be rare and to be a poor prognostic factor[5]. The median survival time of GCs with intramural metastases was significantly shorter than that of those without intramural metastases ($P<0.0001$). However, it has been reported that long-term survival may be achieved if R0 curability by aggressive surgery can be obtained. In this case, proximal gastrectomy with D1 + lymph node dissection was performed, and as a result, R0 resection was performed for intramural metastasis. This is also considered the reason for the good progress.

Chemotherapy was administered for poor prognosis factors such as bone metastasis and lymph node metastasis, and surgeries were actively performed for symptomatic brain metastases and intramural metastasis. All these factors were thought to have contributed to the good course.

At present, with the emergence of various molecular-targeted drugs and immunotherapy, the prognosis is improved. Multidisciplinary treatment is becoming more important than ever.

Conclusion

We report a case of long-term survival of advanced esophagogastric junction adenocarcinoma managed with a multimodal treatment that included surgical resection and chemotherapy for metachronous metastases to the brain and bone, with gastric intramural and lymph nodes metastases.

Conflict of interest: The authors declare no conflicts of interest associated with the present study.

References

1. Deng J, Liang H, Wang D, *et al*. Investigation of the recurrence patterns of gastric cancer following a curative resection. Surg Today 2011; 41: 210–215. [Medline] [CrossRef]
2. Guadagni S, Catarci M, Kinoshitá T, *et al*. Causes of death and recurrence after surgery for early gastric cancer. World J Surg 1997; 21: 434–439. [Medline] [CrossRef]
3. Nakamura K, Tomioku M, Nabeshima K, *et al*. Clinicopathologic features and clinical outcomes of gastric cancer patients with bone metastasis. Tokai J Exp Clin Med 2014; 39: 193–198. [Medline]
4. Turkoz FP, Solak M, Kilickap S, *et al*. Bone metastasis from gastric cancer: the incidence, clinicopathological features, and influence on survival. J Gastric Cancer 2014; 14: 164–172. [Medline] [CrossRef]
5. Hashimoto T, Arai K, Yamashita Y, *et al*. Characteristics of intramural metastasis in gastric cancer. Gastric Cancer 2013; 16: 537–542. [Medline] [CrossRef]
6. Qiu MZ, Shi SM, Chen ZH, *et al*. Frequency and clinicopathological features of metastasis to liver, lung, bone, and brain from gastric cancer: A SEER-based study. Cancer Med 2018; 7: 3662–3672. [Medline] [CrossRef]
7. The brain tumor treatment guidelines, 2nd ed. Japan Society for Neuro-Oncology, Tokyo, 2019; CQ2.
8. Nishimaki T, Suzuki T, Tanaka Y, *et al*. Intramural metastases from thoracic esophageal cancer: local indicators of advanced disease. World J Surg 1996; 20: 32–37. [Medline] [CrossRef]