



Since January 2020 Elsevier has created a COVID-19 resource centre with free information in English and Mandarin on the novel coronavirus COVID-19. The COVID-19 resource centre is hosted on Elsevier Connect, the company's public news and information website.

Elsevier hereby grants permission to make all its COVID-19-related research that is available on the COVID-19 resource centre - including this research content - immediately available in PubMed Central and other publicly funded repositories, such as the WHO COVID database with rights for unrestricted research re-use and analyses in any form or by any means with acknowledgement of the original source. These permissions are granted for free by Elsevier for as long as the COVID-19 resource centre remains active.



## Case Report

## The role of ibrutinib in COVID-19 hyperinflammation: A case report



Suzanne Maynard<sup>\*</sup>, Jose Ros-Soto, Aris Chaidos, Andrew Innes, Krushika Paleja, Eitan Mirvis, Noora Buti, Harriet Sharp, Renuka Palanicawandar, Dragana Milojkovic

Department of Haematology, Imperial College Healthcare and NHS Trust Hammersmith Hospital, 72 Du Cane Rd, London, W12 0HS, United Kingdom

## ARTICLE INFO

## Article history:

Received 14 January 2021

Received in revised form 5 February 2021

Accepted 11 February 2021

## Keywords:

COVID-19

BTK-inhibitor

Ibrutinib

Waldenstrom macroglobulinaemia

## ABSTRACT

Immune modulation in COVID-19 is emerging as an important therapeutic strategy as increasing evidence suggests that inflammatory pathways are implicated in lung damage. Bruton tyrosine kinase inhibitors (BTKi), such as ibrutinib, are commonly used to treat indolent B-cell neoplasms and chronic graft-versus-host disease (GvHD). Given their potential to suppress pulmonary inflammatory cytokines and lessen acute lung injury, this could be applicable in the context of hospitalised COVID-19 patients. We describe an 81 year-old male receiving ibrutinib for Waldenstrom macroglobulinaemia (WM) who was hospitalised with COVID-19. On stopping the BTKi due to concerns of additional immunosuppression, he required non-invasive ventilation (NIV) in the intensive care unit (ICU) and demonstrated prompt clinical recovery when ibrutinib was reinstated. Continuing ibrutinib in patients with COVID-19 may be advantageous given its immunomodulatory properties and withdrawal of ibrutinib therapy may be detrimental. Further evidence is required to explore the potential therapeutic impact of BTKis and other immunomodulatory agents on the clinical course of COVID-19 as is currently being carried out in a number of clinical trials.

Crown Copyright © 2021 Published by Elsevier Ltd on behalf of International Society for Infectious Diseases. This is an open access article under the CC BY-NC-ND license (<http://creativecommons.org/licenses/by-nc-nd/4.0/>).

## Background

Immune modulation in COVID-19 is emerging as an important therapeutic strategy as increasing evidence suggests that inflammatory pathways are implicated in lung damage (Mehta et al., 2020; Ye et al., 2020). Bruton tyrosine kinase inhibitors (BTKi), such as ibrutinib, are commonly used to treat indolent B-cell neoplasms and chronic graft-versus-host disease. Given their potential to suppress pulmonary inflammatory cytokines and lessen acute lung injury (Florence et al., 2019) this could be applicable in the context of hospitalised COVID-19 patients (Thibaud et al., 2020; Treon et al., 2020; Woyach, 2020). Patients already on treatment with BTKi may be at high risk of infection with poor outcomes given advanced age, comorbidities and immune dysfunction. However, a recent multicentre analysis did not show any negative impact of continuing BTKi treatment on the survival of patients with chronic lymphocytic leukaemia hospitalised due to COVID-19 infection

(Mato et al., 2020). We report the outcome of an ibrutinib treated patient with COVID-19 who suffered respiratory deterioration after ibrutinib cessation and promptly improved after ibrutinib re-introduction.

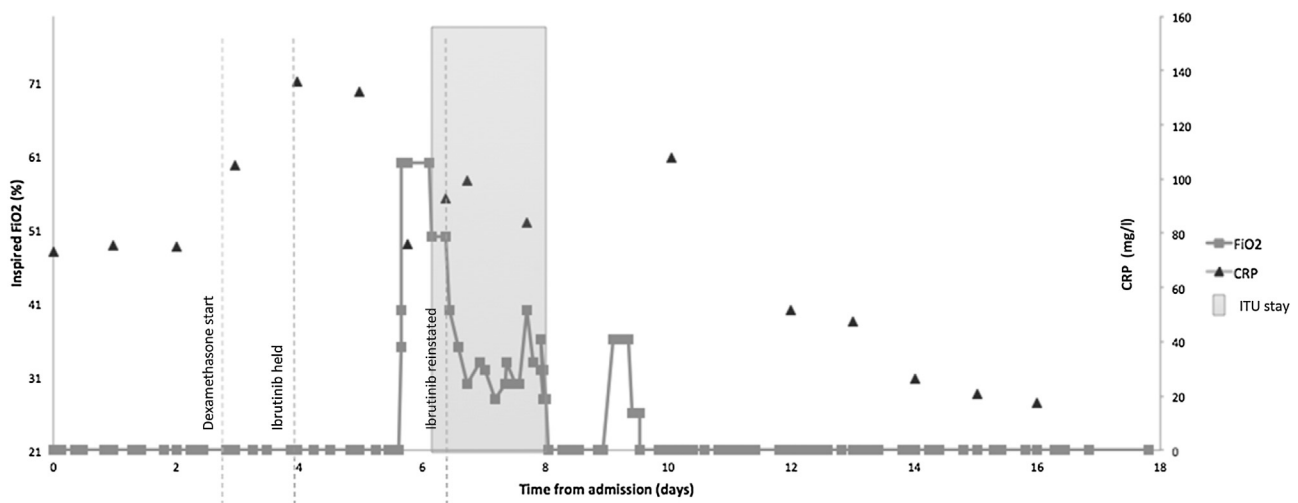
## Case

We describe an 81-year-old male receiving ibrutinib for Waldenstrom macroglobulinaemia who was hospitalised with COVID-19. Waldenstrom macroglobulinaemia is a relatively indolent lymphoproliferative disorder characterised by immunoglobulin(Ig)M monoclonal gammopathy and lymphoplasmacytic infiltrate in the bone marrow. On stopping the BTKi due to concerns of additional immunosuppression, he required non-invasive ventilation (NIV) in the intensive care unit (ICU) and demonstrated prompt clinical recovery when ibrutinib was reinstated.

On admission, the patient described a 1-week history of nausea, fever and dry cough with C-reactive protein (CRP) 73.4 mg/L and was commenced on intravenous piperacillin-tazobactam. COVID swab reverse transcription-polymerase chain reaction at

<sup>\*</sup> Corresponding author.

E-mail address: [suzanne.maynard@nhs.net](mailto:suzanne.maynard@nhs.net) (S. Maynard).



**Figure 1.** Timeline of inpatient events showing oxygen requirements and c-reactive protein (CRP) in relation to ibrutinib.

admission was positive. His observations were stable, he did not require additional oxygen, and blood tests and chest x-ray were unremarkable. Five days later, 11 days since symptoms onset, he became pyrexial at 38 °C, CRP had increased to 136 mg/L, and he was commenced on oral azithromycin and once-daily dexamethasone 8 mg. Repeat chest x-ray showed new pulmonary opacities, but he remained clinically stable with no oxygen requirement. Ibrutinib was withheld from day 6 of admission. CRP improved to 76 mg/L in accordance with the introduction of steroids (Markanday, 2015). Forty-four hours following the last dose of BTKi he developed a new, rapidly increasing, oxygen requirement and within 8 h he was admitted to ICU for NIV to achieve adequate oxygenation (day 7 of admission, 13 days since symptoms onset) (see Figure 1). Within 24 h of ITU admission, his BTKi was reinstated at full dose of 420 mg and remdesivir was commenced. A brief rise and subsequent fall in CRP followed (see Figure 1). After only 14 h of NIV (initial requirements of PEEP 8 and FiO2 55) his oxygen requirements decreased; the following day, he was stepped down to the ward on 4 L O<sub>2</sub> via nasal cannula. He continued to improve, and at 19 days after admission (day 25 of symptoms onset), he was medically fit for discharge with no supplementary oxygen requirement.

## Discussion

With a half-life of only 4–6 h, the rapid deterioration of the patient occurred at a time point when the pharmacokinetics of ibrutinib suggest it would have been eliminated from the body; thus, any potential beneficial immune modulatory effects would no longer be active (Advani et al., 2020).

Consideration should be given to the potential contribution of 'ibrutinib withdrawal' symptoms, a known phenomenon typically occurring within 5 days following treatment cessation. However, documented symptoms of 'ibrutinib withdrawal' – fever, generalised aches, headache and arthralgia – were absent. Furthermore, increased oxygen requirement has not been described as a withdrawal symptom (Castillo et al., 2018).

We acknowledge that commencing remdesivir as compassionate use, at the same time as reinstating ibrutinib, makes it difficult to attribute clinical and biochemical improvement to a specific agent. The timeliness of remdesivir's antiviral activity manifest as clinical improvement remains subject to ongoing research and as

yet remains unclear (Rochweg et al., 2020) and its efficacy remains debatable (Dyer, 2020).

The clinical events and timing of ibrutinib were not clearly mirrored in trends of ferritin or D-dimer.

## Summary

Continuing ibrutinib in patients with COVID-19 may be advantageous given its immunomodulatory properties, and withdrawal of ibrutinib therapy may be detrimental. Further evidence is required to explore the potential therapeutic impact of BTKi and other immunomodulatory agents on the clinical course of COVID-19, as is currently being carried out in a number of clinical trials

## Conflict of interest

The authors have no conflict of interest.

## Funding

Open access fund, Imperial College London.

## Ethical approval

No ethical approval required for this case report.

## Acknowledgements

E. Mirvis, N. Buti, H. Sharp were involved in the patient's care and collecting details of the inpatient stay. A Chaidos, A Innes, D Milojkovic and R Palanicawandar identified the case as of clinical interest. S Maynard wrote the report with essential contributions and feedback from D Milojkovic and J Ros-Soto. K Paleja assisted with report revisions.

## References

Advani RH, Buggy JJ, Sharman JP, Smith SM, Boyd TE, Grant B, et al. Bruton tyrosine kinase inhibitor ibrutinib (PCI-32765) has significant activity in patients with relapsed/refractory B-cell malignancies. *J Clin Oncol* 2020;31:88–94.

- Castillo JJ, Gustine JN, Meid K, Dubeau T, Severns P, Treon SP. Ibrutinib withdrawal symptoms in patients with Waldenstrom macroglobulinemia. *Haematologica* 2018;103:e307–10.
- Dyer O. Covid-19: remdesivir has little or no impact on survival, WHO trial shows. *BMJ* 2020;371:m4057.
- Florence JM, Krupa A, Booshehri LM, Davis SA, Matthay MA, Kurdowska AK. Inhibiting Bruton's tyrosine kinase rescues mice from lethal influenza-induced acute lung injury. *Am J Physiol Lung Cell Mol Physiol* 2019;315:L52–8.
- Markanday A. Acute phase reactants in infections: evidence-based review and a guide for clinicians. *Open Forum Infect Dis* 2015;2:ofv098.
- Mato AR, Roeker LE, Lamanna N, Allan JN, Leslie L, Pagel JM, et al. Outcomes of COVID-19 in patients with CLL: a multicenter international experience. *Blood* 2020;136:1134–43.
- Mehta P, McAuley DF, Brown M, Sanchez E, Tattersall RS, Manson JJ, et al. COVID-19: consider cytokine storm syndromes and immunosuppression. *Lancet* 2020;395:1033–4.
- Rochweg B, Agarwal A, Zeng L, Leo YS, Appiah JA, Agoritsas T, et al. Remdesivir for severe covid-19: a clinical practice guideline. *BMJ* 2020;371:m4542.
- Thibaud S, Tremblay D, Bhalla S, Zimmerman B, Sigel K, Gabrilove J. Protective role of Bruton tyrosine kinase inhibitors in patients with chronic lymphocytic leukaemia and COVID-19. *Br J Haematol* 2020;190:e73–6.
- Treon SP, Castillo JJ, Skarbnik AP, Soumerai JD, Ghobrial IM, Guerrera ML. The BTK inhibitor ibrutinib may protect against pulmonary injury in COVID-19-infected patients. *Blood* 2020;135:1912–5.
- Woyach J. Ibrutinib for the treatment of COVID-19 in patients requiring hospitalization. 2020. . (Accessed 29 September 2020) <https://www.clinicaltrials.gov/ct2/show/NCT04439006>.
- Ye Q, Wang B, Mao J. The pathogenesis and treatment of the 'Cytokine Storm' in COVID-19. *J Infect* 2020;80:607–13.