

Prone positioning for severe ARDS in a postpartum COVID-19 patient following caesarean section

John T Roddy ,¹ William S Collier,² Jonathan S Kurman ¹

¹Pulmonary and Critical Care Medicine, Medical College of Wisconsin, Milwaukee, Wisconsin, USA

²Medicine, Medical College of Wisconsin, Milwaukee, Wisconsin, USA

Correspondence to

Dr John T Roddy;
johnthomasrodny@gmail.com

Accepted 2 March 2021

SUMMARY

A 31-year-old pregnant woman presented with symptomatic COVID-19, which was complicated by progressive hypoxaemia requiring intensive care and emergent delivery by caesarean section. Afterward, she was successfully supported with mechanical ventilation and prone positioning and ultimately recovered. We review literature regarding complications of COVID-19 affecting pregnancy and evidence-based treatment strategies.

BACKGROUND

Since initial reports of a novel respiratory virus arrived from Wuhan, China, COVID-19 caused by SARS-CoV-2 has become a pandemic, causing ever increasing morbidity and mortality.¹ One population of particular concern is pregnant women given the medical experience during prior SARS-CoV-1 and Middle East respiratory syndrome pandemics, which were accompanied by increased peripartum complications and mortality.^{2–4}

Studies to date examining the clinical course of pregnant women with COVID-19 have demonstrated mainly mild cases, with fever, cough and dyspnoea being the predominant symptoms. Demographics of women requiring admission to the hospital due to respiratory compromise were weighted towards those in the third trimester or postpartum, ethnic minorities, being overweight or obese and maternal age greater than 35 years.^{2,5} One in 10 women in a population-based study out of Britain required intensive care, and 1 in 100 died. One in 10 of those requiring critical care received extracorporeal membrane oxygenation (ECMO). Rate of iatrogenic preterm delivery in the context of hospitalisation of pregnant patients varied between 60% and 75% according to published reports, with a high rate of those being via caesarean section (C-section).⁵

Care is required in the treatment of late pregnancy hospitalisation for COVID-19 due to the possibility of maternal complications including respiratory compromise, thrombosis and cardiomyopathy, as well as the possibility of fetal compromise from delivery complications and vertical transmission, which has been reported.^{2,6,7} Delivery via C-section is not recommended routinely for patients with COVID-19 given concerns about increased complications, but maternal decompensation and common fetal complications may necessitate it.⁸

Consideration of the effects of treatments administered both on maternal and fetal health is paramount in the intensive care unit (ICU) for gravid

patients with COVID-19 associated respiratory failure. Some standards of care for severe acute respiratory distress syndrome (ARDS), including prone positioning that has been shown to improve mortality, may require modification based on the specific needs of gravid patients.^{9,10}

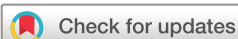CASE PRESENTATION

A 31-year-old African-American female G6P1132 with a 36-week live singleton gestation presented with a 3-day history of malaise, myalgias, cough, dyspnoea, sore throat, anosmia and subjective fever for which she had been taking acetaminophen. Her partner was diagnosed with pneumonia a day earlier and subsequently tested positive for COVID-19. At the time of presentation, the partner's COVID-19 status was unknown. There were no obstetric-related complications prior to presentation.

She was febrile to 38.4°C, normotensive, saturating 92% on room air, tachypneic to 22 breaths per minute and tachycardic to 125 beats per minute (BPM). Lungs were clear to auscultation. Chest X-ray (CXR) revealed a rounded opacity in the right midlung concerning for pneumonia (figure 1). Laboratory results were significant for lymphopenia (13%), neutrophilia (80%), anaemia (10.0 g/dL) and elevated C-reactive protein (CRP) (5.9 mg/L). COVID-19 infection was confirmed via nasopharyngeal swab. She was admitted for further management of her COVID-19 pneumonia and pregnancy.

Supplemental oxygen was not immediately required after admission. Fetal heart rate monitoring demonstrated a rate of 155 BPM with moderate variability (10×10s vs 15×15s). Ceftriaxone and azithromycin were started for empiric coverage of community-acquired pneumonia and atypical pneumonia. Over the ensuing few hours, the patient developed worsening hypotension and tachypnea that was refractory to supplemental oxygen delivered via high-flow nasal canula. The hypotension responded appropriately to intravenous fluid resuscitation. Pulmonary embolism was ruled out with CT angiography of the chest, which revealed bilateral opacities (figure 2). While starting empiric anticoagulation and avoiding imaging-associated radiation exposure was considered, CT was chosen in this case to avoid the possible risks inherent to therapeutic anticoagulation in late third trimester pregnancy and the peripartum period.¹¹

Steroids were initiated because of mild elevations in her inflammatory markers (CRP 6.3 mg/L, ferritin 20.8 ng/mL, lactate dehydrogenase 201 U/L and D-dimer 1.42 mcg/mL).¹² After a brief period of clinical improvement, her respiratory status



© BMJ Publishing Group Limited 2021. No commercial re-use. See rights and permissions. Published by BMJ.

To cite: Roddy JT, Collier WS, Kurman JS. *BMJ Case Rep* 2021;**14**:e240385. doi:10.1136/bcr-2020-240385

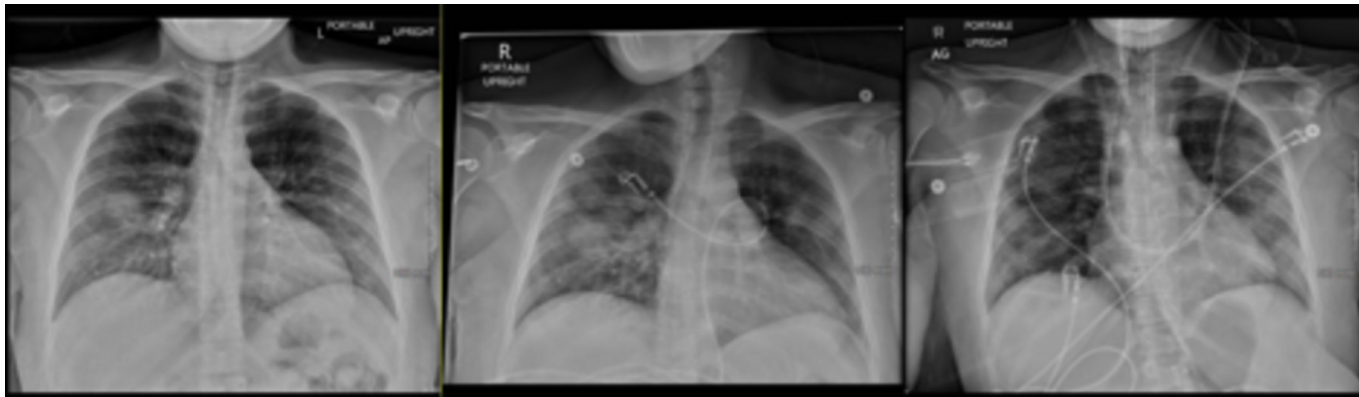

Figure 1 Disease progression on chest X-ray (day 4, day 6, day 14 of symptoms, respectively).

declined again. CXR demonstrated progression of the bilateral opacities. Fetal monitoring identified repeated heart rate deceleration and tachycardia up to 170 BPM that was unresponsive to fluid resuscitation. Convalescent plasma was administered. Despite a rise in her inflammatory markers, treatment with remdesivir and tocilizumab was declined because of their unknown impact on the fetus.

The consensus from a multidisciplinary discussion was to proceed with delivery because of the declining trajectory. Vascular access via the internal jugular vein was preemptively obtained in case ECMO became necessary. After intubation, the baby was delivered via C-section without complications. Intubation was chosen over neuroaxial anaesthesia because of the rapid decline in the patient's respiratory status and high level of oxygen requirements. Postoperatively, the patient remained intubated. Prone positioning was implemented in an effort to improve oxygenation. Remdesivir and a heparin infusion were also initiated.

OUTCOME AND FOLLOW-UP

Prone positioning was required for several days to maintain adequate oxygenation. Tocilizumab was also initiated in the context of renewed fever and rising inflammatory markers. The patient was liberated from the ventilator after 14 days. Periodic proning continued after extubation. She was eventually discharged after almost 3 weeks in the hospital. Her infant was COVID-19 negative without evidence of vertical transmission. One-month after discharge, both the patient and baby were doing well without any obvious residual effects of her illness.

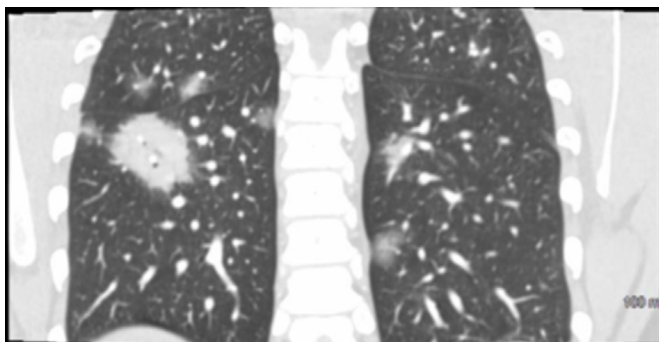


Figure 2 Presenting CT scan with scattered ground glass opacities and right lower lobe focal consolidation.

DISCUSSION

Our patient's presentation with respiratory failure due to COVID-19 complicating pregnancy falls into several higher-prevalence demographics previously reported for requiring hospitalisation: she was from a minority group, of elevated body mass index (BMI), and in the third trimester of pregnancy.^{2 5} Her course was complicated by respiratory failure requiring high flow oxygen, delivery by C-section, and ultimately intubation and postpartum prone positioning due to COVID-19 related ARDS. Unlike some peripartum patients with severe COVID-19 infection, she did not require ECMO and was successfully extubated and discharged from the hospital with her newborn after receiving a variety of therapeutic interventions.

Venous access was established prior to her C-section in anticipation of the possible need for ECMO given the rapidity of her respiratory decompensation and hypoxaemia. Although ECMO was not required, continued invasive ventilation and prone positioning were necessary to maintain adequate oxygenation. Consistent with severe ARDS, initial P/F ratio on intubation was 87 at a positive end expiratory pressure of 5, which was subsequently titrated higher for oxygenation purposes. The American Journal of Obstetrics and Gynecology Maternal Fetal Medicine has supplied guidance for labour and delivery in COVID-19, recommending the use of modified prone positioning with left lateral tilt position or full pronation with appropriate support of the gravid abdomen if required in the ICU based on reports of successful use of this technique in practice.^{10 13} Pronation was not attempted predelivery given the rapidity of her clinical decompensation. It was, however, well tolerated after delivery and necessary given the refractory hypoxaemia.

Prone positioning has proven beneficial in the treatment of ARDS most notably in the Prone Positioning in Severe Acute Respiratory Distress Syndrome (PROSEVA) trial published in 2013.¹⁴ The physiological rationale by which prone positioning benefits patients is suspected to be related to improved ventilation perfusion matching by optimising aeration in the posterior portion of the lung. The posterior aspect of the lungs is higher in volume than the anterior lung fields and prone to atelectasis and collapse in the context of severe ARDS. This benefit is likely pronounced in conditions that contribute extrapulmonary sources of poor compliance, including pregnancy and high BMI.¹⁵ Multiple studies provide evidence for oxygenation improvement following prone positioning in patients with respiratory failure related to COVID-19.^{16 17} In patients with ARDS having recently undergone abdominal surgery, research supports the safe use of prone positioning to improve oxygenation.¹⁸

Duration of pronation is an additional topic worth considering in the context of COVID-19 given frequently encountered refractory hypoxaemia and system-wide resource restraints. Previously studied regimens for prone positioning have consisted of intermittent prone positioning during a majority of the day with several hours spent supine. This patient was unable to tolerate supination for the first several days following intubation due to hypoxaemia, so she remained prone for the first 72 hours, following which she successfully had a more standard intermittent regimen for the remainder of her intubation. Prolonged pronation has been studied in limited sample size feasibility studies and proposed as a possible alternative to established intermittent prone positioning.¹⁹ Several factors must be considered, however, including frequent repositioning to avoid facial pressure sores and facial oedema.

A variety of treatments have been proposed, and some are showing preliminary efficacy in the treatment of COVID-19. Remdesivir, liponavir, convalescent plasma, steroids and hydroxychloroquine have all been used in pregnant patients with severe COVID-19 infection, although some (including hydroxychloroquine) have not been shown to be beneficial.²⁰ In one cohort, pregnant patients admitted to a critical care unit with respiratory failure from COVID-19 required intubation in 95% of cases, and prone positioning was required in 20% due to refractory hypoxaemia.² Our patient received remdesivir, convalescent plasma and steroids (dexamethasone 6 mg daily).¹² Later evidence would indicate that convalescent plasma may have been ineffective in this case given that its predominant benefit was noted when used early for less severe, mild presentations of COVID-19 and not in hospitalised patients, who likely had already developed antibodies.^{21 22} She did not receive hydroxychloroquine given its lack of efficacy in randomised trials.^{23 24}

The newborn was monitored in the neonatal ICU but did well and was discharged while the patient was still intubated. Reports based on retrospective data indicate that C-section in COVID-19 is associated with higher rates of respiratory decompensation, maternal need for intensive care and neonatal requirement for intensive care, which were all observed in this case.⁸

This case differs from other reports in that the patient received early C-section at 37 weeks in the context of rapid respiratory decompensation, after which she tolerated prone positioning and was successfully extubated following clinical improvement.^{13 25}

Learning points

- There are several important clinical points that this patient's presentation and clinical course illustrate. First, clinical vigilance is required in pregnant patients admitted with severe respiratory failure due to COVID-19, as decompensation can be precipitous and extreme. Second, standard evidence-based treatment of peripartum patients with severe acute respiratory distress syndrome in COVID-19 is the same as for non-pregnant patients, including lung protective ventilatory strategies, prone positioning, and the use of steroids and antivirals. This unique patient population will benefit from continued investigation of optimal management strategies in light of the paradigm shift COVID-19 has caused in the medical field.

Twitter John T Roddy @JohnRoddyMD

Contributors Conception and design: JTR, WSC and JSK conceived and designed case report. Administrative support: none. Provision of study materials or patients: none. Collection and assembly of data: JTR and WSC collected data/chart review.

Data analysis and interpretation: JTR and JSK analyzed data and interpreted. Manuscript writing: JTR, WSC and JSK. All contributed to drafting. Final approval of manuscript: JTR, WSC and JSK provided final approval

Funding The authors have not declared a specific grant for this research from any funding agency in the public, commercial or not-for-profit sectors.

Competing interests None declared.

Patient consent for publication Obtained.

Provenance and peer review Not commissioned; externally peer reviewed.

This article is made freely available for use in accordance with BMJ's website terms and conditions for the duration of the covid-19 pandemic or until otherwise determined by BMJ. You may use, download and print the article for any lawful, non-commercial purpose (including text and data mining) provided that all copyright notices and trade marks are retained.

ORCID iDs

John T Roddy <http://orcid.org/0000-0003-1056-8241>

Jonathan S Kurman <http://orcid.org/0000-0001-8018-496X>

REFERENCES

- Zhou P, Yang X-L, Wang X-G, *et al.* A pneumonia outbreak associated with a new coronavirus of probable bat origin. *Nature* 2020;579:270–3.
- Pierce-williams RAM, Burd J, Felder L. Clinical course of severe and critical coronavirus disease 2019 in hospitalized pregnancies : a United States cohort study 2020.
- Assiri A, Abedi GR, Al Masri M, *et al.* Middle East respiratory syndrome coronavirus infection during pregnancy: a report of 5 cases from Saudi Arabia: table 1. *Clin Infect Dis* 2016;63:951–3.
- Wong SF, Chow KM, Leung TN, *et al.* Pregnancy and perinatal outcomes of women with severe acute respiratory syndrome. *Am J Obstet Gynecol* 2004;191:292–7.
- Knight M, Bunch K, Vousden N, *et al.* Characteristics and outcomes of pregnant women admitted to hospital with confirmed SARS-CoV-2 infection in UK: national population based cohort study. *BMJ* 2020;369:m2107.
- Juusela A, Nazir M, Gimovsky M. Two cases of coronavirus 2019-related cardiomyopathy in pregnancy. *Am J Obstet Gynecol MFM* 2020;2:100113.
- Patanè L, Morotti D, Giunta MR, *et al.* Vertical transmission of coronavirus disease 2019: severe acute respiratory syndrome coronavirus 2 RNA on the fetal side of the placenta in pregnancies with coronavirus disease 2019–positive mothers and neonates at birth. *Am J Obstet Gynecol MFM* 2020;100145.
- Martínez-Pérez O, Vouga M, Cruz Melguizo S, *et al.* Association between mode of delivery among pregnant women with COVID-19 and maternal and neonatal outcomes in Spain. *JAMA* 2020;324:296–9.
- Scholten EL, Beitler JR, Prisk GK, *et al.* Treatment of ARDS with prone positioning. *Chest* 2017;151:215–24.
- Boelig RC, Manuck T, Oliver EA, *et al.* Labor and delivery guidance for COVID-19. *Am J Obstet Gynecol MFM* 2020;2:100110.
- Pahade JK, Litmanovich D, Pedrosa I, *et al.* Imaging pregnant patients with suspected pulmonary embolism: what the radiologist needs to know. *RadioGraphics* 2009;29:639–54.
- The RECOVERY Collaborative. Dexamethasone in hospitalized patients with Covid-19 — preliminary report. *N Engl J Med* 2020:1–11.
- Schenttler WT, Al Ahwel Y, Suhag A. Severe acute respiratory distress syndrome in coronavirus disease 2019-infected pregnancy: obstetric and intensive care considerations. *Am J Obs Gynecol MFM* 2020.
- Guérin C, Reignier J, Richard J-C, *et al.* Prone positioning in severe acute respiratory distress syndrome. *N Engl J Med* 2013;368:2159–68.
- De Jong A, Molinari N, Sebbane M, *et al.* Feasibility and effectiveness of prone position in morbidly obese patients with ARDS: a case-control clinical study. *Chest* 2013;143:1554–61.
- Coppo A, Bellani G, Winterton D, *et al.* Feasibility and physiological effects of prone positioning in non-intubated patients with acute respiratory failure due to COVID-19 (PRON-COVID): a prospective cohort study. *Lancet Respir Med* 2020;8:765–74.
- Mittermaier M, Pickerodt P, Kurth F, *et al.* Evaluation of PEEP and prone positioning in early COVID-19 ARDS. *EClinicalMedicine* 2020;28:100579.
- Gaudry S, Tuffet S, Zucman N. Prone positioning in acute respiratory distress syndrome after abdominal surgery: a multicenter retrospective study: SAPRONADONF (study of ARDS and prone position after abdominal surgery in France). *Ann Intensive Care* 2017;7.
- Carsetti A, Damia Paciarini A, Marini B, *et al.* Prolonged prone position ventilation for SARS-CoV-2 patients is feasible and effective. *Crit Care* 2020;24:1–3.
- Crosby JC, Heimann MA, Burleson SL, *et al.* COVID-19: a review of therapeutics under investigation. *J Am Coll Emerg Physicians Open* 2020;1:231–7.
- Libster R, Pérez Marc G, Wappner D, *et al.* Early high-titer plasma therapy to prevent severe Covid-19 in older adults. *N Engl J Med* 2021:1–9.
- Li L, Zhang W, Hu Y, *et al.* Effect of convalescent plasma therapy on time to clinical improvement in patients with severe and life-threatening COVID-19. *JAMA* 2020;324:460–70.

- 23 Horby P, Mafham M, Linsell L. Effect of hydroxychloroquine in hospitalized patients with COVID-19: preliminary results from a multi-centre, randomized, controlled trial. *medRxiv* 2020;2020:20151852.
- 24 Skipper CP, Pastick KA, Engen NW, *et al.* Hydroxychloroquine in nonhospitalized adults with early COVID-19. *Ann Intern Med* 2020:1–10.
- 25 Oliva M, Hsu K, Alsamarai S, *et al.* Clinical improvement of severe COVID-19 pneumonia in a pregnant patient after caesarean delivery. *BMJ Case Rep* 2020;13:e236290.

Copyright 2021 BMJ Publishing Group. All rights reserved. For permission to reuse any of this content visit <https://www.bmj.com/company/products-services/rights-and-licensing/permissions/>
BMJ Case Report Fellows may re-use this article for personal use and teaching without any further permission.

Become a Fellow of BMJ Case Reports today and you can:

- ▶ Submit as many cases as you like
- ▶ Enjoy fast sympathetic peer review and rapid publication of accepted articles
- ▶ Access all the published articles
- ▶ Re-use any of the published material for personal use and teaching without further permission

Customer Service

If you have any further queries about your subscription, please contact our customer services team on +44 (0) 207111 1105 or via email at support@bmj.com.

Visit casereports.bmj.com for more articles like this and to become a Fellow