

## CLINICAL ARTICLE

# Effects of Single-Foot Centered and Double-Foot Centered X-ray Projection on Hallux Valgus Measurement

Hai-tao Li, MM, Bei-xi Bao, MM, Jian-zhong Zhang, MM 

*Department of Orthopaedics, Tongren Hospital of China Capital Medical University, Beijing, China*

**Objective:** To investigate whether use of single-foot centered and double-foot centered weight-bearing X-rays has an impact on the relevant indicators of hallux valgus.

**Methods:** A total of 55 female patients from the Department of Ankle Surgery of Beijing Tongren Hospital with hallux valgus (110 feet) were collected from September to December 2015. The age of these patients ranged from 18 to 43 years, with an average age of  $47.9 \pm 8.5$  years. All selected patients fit the diagnostic criteria of hallux valgus and had weight-bearing single foot centered and double foot centered radiographs taken. During the projection, all patients were instructed to stand on the X-ray box, with the knee joint straightened and legs perpendicular to the floor. The projection center of the single foot was directed at the lateral part of the scaphoid bone of the foot, while the projection center was directed at the position between the scaphoid bones of both feet for the double-foot shooting. The hallux valgus angle (HAV), the intermetatarsal angle between the first and second metatarsals (IMA), the intermetatarsal angle between the first and fifth metatarsals (IM1-5), and the metatarsal adduction angle (MAA) were measured and examined. The difference between these two shooting conditions was compared and analyzed.

**Results:** The differences in X-ray measurement results (IMA, HAV, IM1-5, and MMA) between different measures for the same patient were not statistically significant. The values of HAV, IMA, IM1-5, and MAA are common indexes for evaluating hallux valgus. The average IMA was  $15.9^\circ$  for single-foot centered and  $14.1^\circ$  for double-foot centered X-rays. The average HAV was  $30.2^\circ$  for single-foot centered and  $29.7^\circ$  for double-foot centered X-rays. The average IM1-5 was  $31.1^\circ$  for single-foot centered and  $29.7^\circ$  for double-foot centered X-rays. The average of metatarsal adduction angle was  $13.8^\circ$  for single-foot centered and  $14.1^\circ$  for double-foot centered X-rays. The differences between single-foot centered and double-foot centered X-rays were statistically significant in terms of the measurement index ( $P < 0.05$ ). In addition, compared with double-foot centered weight-bearing X-rays, the focus of single-foot centered X-rays was located on the lateral part of the scaphoid bone of the foot, and the ray was closer to the vertical foot in the single-foot centered weight-bearing X-ray.

**Conclusion:** When the weight-bearing position and projection distance are the same, the single-foot centered weight-bearing X-ray is more effective in evaluating the severity of hallux valgus compared with the double-foot centered weight-bearing X-ray.

**Key words:** Hallux valgus; Radiographic analysis; Single foot center; Double foot center

**Address for correspondence** Jian-zhong Zhang, MM, Department of Foot Ankle Surgery, Tongren Hospital of China Capital Medical University, No. 1 Dongjiaominxiang Street, Dongcheng District, Beijing, China 100730 Tel: +86-13911071626; Fax:+86-010-58266699; Email: jianzhong200@163.com

**Disclosure:** The authors declare that they have no competing interests.

Received 15 May 2019; accepted 17 November 2019

## Introduction

Hallux valgus was first proposed by Carl Hueter in 1871 and is one of the common diseases in the forefoot characterized by the outward deviation of the hallux beyond the normal physiological angle and first metatarsal adduction. It is a common deformity of the forefoot that usually exists on both feet<sup>1</sup>. It is generally believed that when the outward deviation of the hallux is more than  $15^\circ$ , it is a hallux valgus deformity. X-ray measurement of the foot is important for understanding the pathological changes of hallux valgus, and developing a surgical plan<sup>2,3</sup>. X-ray examination of the foot is critical for further summarizing the pathological changes of hallux valgus and developing a surgical plan<sup>4,5</sup>. At present, the X-ray measurement for hallux valgus is generally conducted with weight-bearing of the foot. However, there is still some controversy about the angle of projection and the position of the foot during shooting. For patients with hallux valgus, the presently used methods in clinical practice are single-foot centered shooting and double-foot centered shooting. However, it remains inconclusive whether related indicators of hallux valgus vary with these two different methods of shooting, and which method is more effective in showing the severity and pathological changes of hallux valgus. In the present study, 55 patients with double-foot hallux valgus were enrolled, and weight-bearing single-foot centered and double-foot centered X-ray films were taken. The intermetatarsal angle between the first and second metatarsals (IMA), the hallux valgus angle (HVA), the intermetatarsal angle between the first and fifth metatarsals (IM1-5), and the changes in the metatarsal adduction angle (MAA) of single-foot centered and double-foot centered X-rays were compared, to determine whether these two different shooting conditions affect the relevant indicators of hallux valgus. Furthermore, our study evaluates which method is better for assessing the severity of hallux valgus. Therefore, the main goals of our study are: (i) to compare the single-foot centered and double-foot centered in the measurement of the intermetatarsal angle between the first and second metatarsals

(IMA), the hallux valgus angle (HVA), the intermetatarsal angle between the first and fifth metatarsals (IM1-5), and the metatarsal adduction angle (MAA); (ii) to evaluate which method is better for assessing the severity of hallux valgus; and (iii) to explore the limitations and the possible direction of evaluation of severity of hallux valgus.

## Methods

### Inclusion and Exclusion Criteria

Inclusion criteria for hallux valgus<sup>3</sup>: (i) patients had hallux valgus deformity or presence of hallux bursitis; (ii) IMA  $\geq 10^\circ$  on weight-bearing X-ray film; (iii) HVA  $\geq 20^\circ$  on weight-bearing X-ray film; (iv) all patients had no other treatment before surgery; and (v) informed consent was obtained from all individual participants who were enrolled in the study.

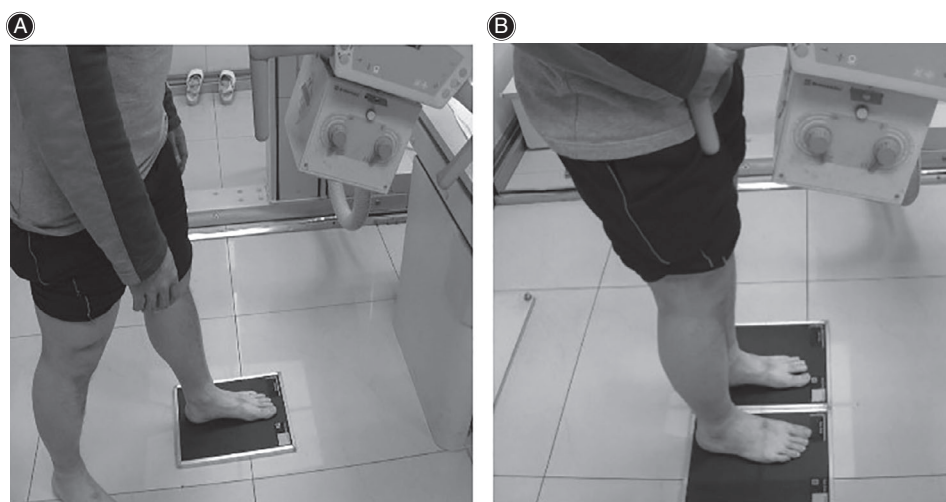
Exclusion criteria: (i) past history of foot surgery; (ii) rheumatoid arthritis or diabetic foot; (iii) other diseases like neurological diseases that may affect the ability to balance; (iv) other diseases like cerebral infarction that may affect patient standing; and (v) general condition too poor to receive the examinations.

### Study Subjects

From September to December 2015, 55 consecutive patients with hallux valgus of both feet were collected from the Department of Ankle Surgery of Beijing Tongren Hospital, and single-foot centered and double-foot centered weight-bearing X-ray films were taken. All patients were women. The age of these patients ranged from 18 to 43 years, with an average age of  $47.9 \pm 8.5$  years; a total of 110 feet were included. The present study was approved by the ethics committee of our hospital. All patients provided informed consent prior to the examination.

### Instruments and Methods

A Shimadzu R-20J X-ray machine (Shimadzu, Japan) was used for the X-ray projection. During the projection, the patient was



**Fig. 1** X-ray projection methods of hallux valgus. During the projection of shooting, the patient was instructed to stand on the X-ray box, with the knee joint straightened and legs perpendicular to the floor. (A) Single-foot centered projection mode: The shooting center was directed at the lateral part of the scaphoid bone of the foot. (B) Double-foot centered projection mode: The shooting center was directed at the position between the scaphoid bones of both feet.

instructed to stand on the X-ray box, with their knee joint straightened and legs perpendicular to the floor. The X-ray tube was 1 m from the film box and  $15^\circ$  from the longitudinal axis of the human body. During the single-foot shooting, the projection center was directed at the lateral part of the scaphoid bone of the foot, while during the double-foot shooting, the projection center was directed at the position between the scaphoid bones of both feet (Fig. 1). The speed of shooting was 20 ms, the voltage was 50 kV, and the current was 10 mAs.

#### Examination of Measurement Method

Before the present study was carried out, several orthopaedicians participating in the present study were organized to review the research program and to determine the relevant operating procedures and evaluation criteria. The surveyors and observers were uniformly trained. To ensure the consistency of the results of measurement and observation, the same physicians were assigned to perform the measurements and observations. Furthermore, the imaging data were repeatedly measured and checked. Quality supervisors were appointed to regularly observe the whole process of the study and to conduct a quality evaluation, to ensure that the records and reports of the data were consistent with the original data, and that the case report forms were complete and correct. Repeatability evaluation of measurement methods: The X-ray films of a patient with hallux valgus were randomly selected, including one single-foot centered X-ray film and one double-foot centered X-ray film. Then, three orthopaedicians were randomly selected to measure the same hallux valgus X-ray film. The repeated measurements were performed five times every 3 days, and the average values of these measurements were recorded.

#### Relevant Indicators

Selection of the central axis of the first metatarsal bone: The metatarsal shaft was equally divided on two planes; a straight line formed by connecting two points and the extending line was the first metatarsal axis (Fig. 2). The IMA, HVA, IM1-5 and MAA were measured on positive weight-bearing X-ray films.

#### Hallux Valgus Angle

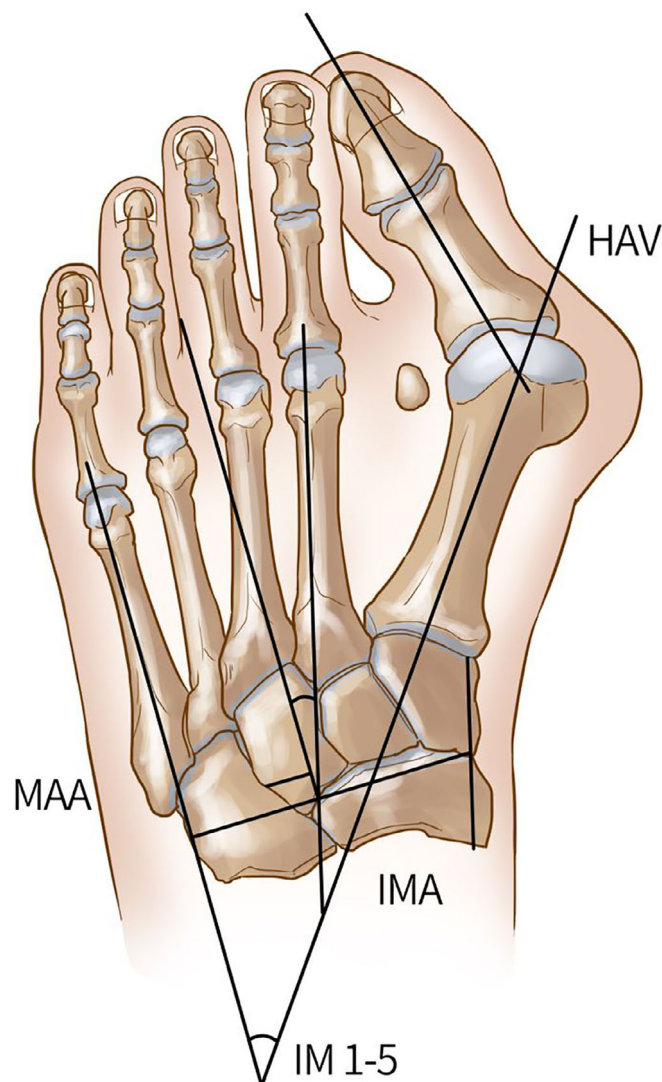
On the posterior X-ray before loading, the angle between the longitudinal axis of the first toe and the longitudinal axis of the proximal phalanx of the first toe is  $10^\circ$ – $15^\circ$  in normal subjects.

#### Intermetatarsal Angle between the First and Fifth Metatarsals

This refers to the angle between the first metatarsal axis and the fifth metatarsal axis; this angle directly reflects the relationship between the metatarsal bones of the foot. The abnormal enlargement of IM1-5 can indirectly reflect the widening of the forefoot and the collapse of the transverse arch of the foot. IM1-5 in hallux valgus patients is increased when compared with normal subjects.

#### Intermetatarsal Angle Between the First and Second Metatarsals

The normal value of the angle between the longitudinal axis of the first toe and the extended line of the longitudinal axis of the second toe is  $8^\circ$ – $12^\circ$ . For patients with metatarsal adduction, the normal value is  $8^\circ$ – $10^\circ$ . The hallux valgus can be classified according to the hallux valgus angle (HVA) and the first/second intermetatarsal angle (IMA). Mild: The medial part of the first metatarsal head protrudes with pain,  $HVA < 30^\circ$ ,  $IMA < 13^\circ$ . Moderate: The thumb has lateral deviation to compress the second toe, the sesamoid bone is



**Fig. 2** Measurement of the hallux valgus angle. The metatarsal shaft was equally divided on two planes; a straight line formed by connecting two points and the extending line was the first metatarsal axis. HAV refers to the angle between the central axis of the metatarsal bone and the central axis of the proximal phalanx of the thumb. IM1-5 refers to intermetatarsal angle between the first and fifth metatarsals. IMA refers to intermetatarsal angle between the first and second metatarsals.

dislocated, HVA is 30°–40°, IMA is 13°–16°. Severe: The thumb has lateral deviation to ride across the second toe, the hallux has pronation, the dislocation of the sesamoid bone is located at the fibular margin of the metatarsal head (7°), HVA > 40°, IMA > 14°.

#### Metatarsal Adduction Angle

The midpoint of the connecting line between the medial tarsometatarsal joint and the medial margin of the talonavicular joint is connected with the midpoint of the connecting line between the cuboid joint and the lateral margin of the cuboid joint of the fifth metatarsal bone. A vertical line is made at the midpoint of this connecting line; the angle between it and the second metatarsal axis is generally less than 15° in normal subjects. If the metatarsal adduction angle is  $\geq 15^\circ$ , it is called adduction of foot. This angle reflects the relationship between the metatarsal bone and the middle foot, and affects the measurement of the first/second IMA, resulting in a decrease in the measured IMA compared to the actual IMA of the patient. In addition, the adduction of metatarsals will affect the distal displacement of the first metatarsal after osteotomy. An excessive angle of adduction of metatarsal should be corrected by operation.

#### Statistical Analysis

The SPSS 17 software was used. The measurement data of the HVA, the metatarsal adduction angle, and the IMA (IM1-5) were presented as mean  $\pm$  standard deviation (mean  $\pm$  SD). The measurement data were compared among the different measures using analysis of variance. The measurement data between single-foot centered and double-foot centered X-rays were compared using *t*-tests.  $P < 0.05$  was considered statistically significant.

## Results

#### Consistency among Different Measures

The differences in X-ray measurement results (IMA, HAV, IM1-5, and MAA) between different measures for the same patient were not statistically significant ( $P > 0.05$ , Table 1).

#### Intermetatarsal Angle

The IMA of the single-foot centered X-ray projection was 10.3°–30.7°, and the average value was 15.9°, while the IMA of the double-foot centered X-ray projection was 7.7°–30.3°, and the average value was 14.1°. The average ratio of double-foot centered to single-foot centered X-rays was 0.94, which suggested that the IMA of the double-foot centered X-ray was lower than that of the single-foot centered X-ray with a statistically significant difference ( $P < 0.05$ ). The IM1-5 of the single-foot centered X-ray projection was 14.7°–64.3°, and the average value was 30.2°, while the IM1-5 of the double-foot centered X-ray projection was 12.7°–60.7°, and the average value was 29.7°. The average ratio of double-foot centered to single-foot centered X-rays was 0.99, suggesting that the IM1-5 of the double-foot centered X-ray was greater than that of the single-foot centered X-ray with statistically significant difference ( $P < 0.05$ ).

#### Hallux Valgus Angle

The HVA of the single-foot centered X-ray projection was 20.7°–60.3°, and the average value was 31.1°, while the HVA of the double-foot centered X-ray projection was 17.7°–57.3°, and the average value was 29.7°. The average ratio of the double-foot centered to single-foot centered X-ray was 0.96, and the HVA of the double-foot centered X-ray projection was statistically greater than that of the single-foot centered X-ray ( $P < 0.05$ ).

#### Metatarsal Adduction Angle

The metatarsal adduction angle of the single-foot centered X-ray projection was 5.7°–24.0°, and the average value was 13.8°, while the metatarsal adduction angle of the double-foot centered X-ray projection was 8.7°–21.3°, and the average value was 14.1°. The average ratio of the double-foot centered to single-foot centered X-ray was 1.07, and the metatarsal adduction angle of the double-foot centered was statistically greater than that of the single-foot centered ( $P < 0.05$ ).

**TABLE 1 Comparison of X-ray results of the same patient using different methods ( $^\circ$ ,  $\bar{x} \pm s$ )**

Number	Single-foot center				Double-foot center			
	IMA	HAV	IM1-5	MAA	IMA	HAV	IM1-5	MAA
1	15.7 $\pm$ 0.66	30.2 $\pm$ 1.04	31.1 $\pm$ 1.23	13.5 $\pm$ 0.87	14.2 $\pm$ 0.65	29.9 $\pm$ 1.15	29.5 $\pm$ 0.96	14.6 $\pm$ 0.92
2	15.5 $\pm$ 0.77	30.9 $\pm$ 1.12	30.9 $\pm$ 1.09	14.1 $\pm$ 0.96	14.6 $\pm$ 0.73	30.1 $\pm$ 1.08	29.0 $\pm$ 1.03	14.0 $\pm$ 0.75
3	16.0 $\pm$ 0.83	31.1 $\pm$ 1.32	30.5 $\pm$ 1.14	13.7 $\pm$ 1.10	14.1 $\pm$ 0.82	29.4 $\pm$ 0.95	29.3 $\pm$ 1.12	14.2 $\pm$ 0.81
F value	1.576	1.905	2.247	2.557	1.337	1.954	2.205	2.867
P value	0.934	0.876	0.765	0.657	0.964	0.834	0.775	0.669

MAA: The midpoint of the medial line between the metatarsal wedge joint and the talus-scaphoid joint is connected with the midpoint of the line between the fifth metatarsal, the cuboid joint, and the external line of the calcaneocuboid joint. A perpendicular line is made by the line intersecting with the midline of the second metatarsal bone. The angle between the line and the midline of the second metatarsal is MAA.

## Discussion

X-ray measurement of the foot is important for further understanding the pathological changes of the hallux valgus, and developing a surgical plan<sup>4,5</sup>. Many measurement indicators of the hallux valgus are correlated to the central axis of the first metatarsal bone. There is also a divergence in the selection of the central axis of the first metatarsal bone<sup>6-8</sup>. At present, there are five commonly used clinical measurement methods: (i) the axis of the first metatarsal bone is chosen as its axis; (ii) the metatarsal trunk is equally divided on two planes, and a straight line is formed by connecting two points; (iii) the connecting line between the midpoint of the facies articularis capituli of the first metatarsal bone and the midpoint of the proximal articular surface of the first metatarsal bone; (iv) the connecting line between the midpoint of the head of the first metatarsal bone and the midpoint of the base of the first metatarsal bone; and (v) the connecting line between the midpoint of the first metatarsal bone and the midpoint of the proximal axis of the first metatarsal bone. For the X-ray indicators for hallux valgus, accurate measurement results can guide the selection of follow-up treatment plans. At present, these measurement indicators mainly depend on manual drawing and measurements on X-ray films. To improve the accuracy of measurement, relevant computer software can be used for measurement, or the error can be reduced by taking its mean value from multiple measurements<sup>9-12</sup>.

The HVA refers to the angle between the central axis of the metatarsal bone and the central axis of the proximal phalanx of the thumb, which is normally 15°–20°, and this is often used in the diagnosis, classification, and prognosis evaluation of hallux valgus. According to Coughlin *et al.*<sup>13</sup>, hallux valgus can be diagnosed when HVA is >15° or IMA is >8°, and the following degrees are determined according to HVA: HVA <25° is defined as mild, 25° ≤ HVA < 35° is defined as moderate, and HVA ≥35° is defined as severe. Gui *et al.* suggested by studying the first sequence that<sup>14</sup> HVA and other angles were needed to act as the main judging standard for hallux valgus classification. The present study revealed that the average values of HVA measured by single-foot centered and double-foot centered shooting were 30.2° and 29.7°, respectively, and the difference in HVA between these two different shooting methods was statistically significant ( $P < 0.05$ ). With the continuous development of the study of hallux valgus, and although HVA can reflect the severity of hallux valgus to a certain extent, the pathological changes of hallux valgus cannot be completely determined by HVA alone. Hence, to reflect the severity of hallux valgus more comprehensively, it is necessary to combine other measurement indicators.

When hallux valgus occurs, the first metatarsal bone adduction and IMA increases. Hence, restoring the normal IMA is one of the keys to the success of hallux valgus surgery. Therefore, IMA is an important indicators for evaluating the severity and prognosis of hallux valgus<sup>15-17</sup>. The present study revealed that the average values of IMA measured by single-foot centered

and double-foot centered shooting were 15.9° and 14.1°, respectively, and the difference was statistically significant ( $P < 0.05$ ).

The IM1-5 directly reflects the relationship between the metatarsal bones of the foot. The abnormal enlargement of IM1-5 can indirectly reflect the widening of the forefoot and the collapse of the transverse arch of the foot. In previous studies it has been reported that IM1-5 in hallux valgus patients increased when compared with normal subjects<sup>18-20</sup>. The present study revealed that the average values of IM1-5 measured by single-foot centered and double-foot centered shooting were 31.1° and 29.7°, respectively, and the difference was statistically significant ( $P < 0.05$ ).

Patients with hallux valgus may also have adduction of the second metatarsal bone, while the metatarsal adduction angle reflects the relationship between the metatarsal and middle foot, accordingly reflecting the severity of adduction of the metatarsal bone to a certain extent and affecting the measurement of IMA. The metatarsal adduction angle in normal subjects is generally less than 15°. However, the measurement of this angle is also controversial at present. According to some scholars, the measurement method is as follows: the midpoint of the connecting line between the medial tarsometatarsal joint and the medial margin of the talonavicular joint is connected with the midpoint of the connecting line between the cuboid joint and the lateral margins of the cuboid joint and the calcaneocuboid joint of the fifth metatarsal bone; a vertical line through the intersection of the line with the midline of the second metatarsal bone is made; and the angle between the vertical line and midline of the second metatarsal bone is the metatarsal adduction angle<sup>14</sup>. The present study revealed that the average values of metatarsal adduction angles measured by single-foot centered and double-foot centered shooting were 13.8° and 14.1°, respectively, and the difference was statistically significant ( $P < 0.05$ ). The above results showed that there was a statistical difference between single-foot centered X-rays and double-foot centered X-rays for IMA, HVA, and IM1-5, and the ratio of double-foot to single-foot centered X-rays was less than 1.0, so it is more effective to assess the severity of hallux valgus when one foot is weighted. However, the metatarsal adduction angle of the double-foot centered X-ray was statistically greater than that of the single-foot centered X-ray. Considering that the differences in the above measurement indicators may be correlated to the projection angle when double-foot centered shooting was used, and because the focus of the projection is between the scaphoid bones of both feet, there was a certain angle between the rays and both feet. Furthermore, when single-foot centered shooting is used, the focus is located on the lateral part of the scaphoid bone of the foot when compared with double-foot centered shooting. Moreover, in the single-foot centered shooting, the ray was closer to the vertical foot. Therefore, when the weight-bearing position and projection distance are the same, it would be more effective to assess the severity of the hallux valgus when single-foot centered shooting is used.

In summary, compared with double-foot centered shooting, when single-foot centered shooting is used, the projection direction is closer to being vertical to the foot, which is more effective in assessing the severity of hallux valgus. The present study only measured indicators reflecting the severity of hallux valgus, but this does not mean that all hallux valgus indicators are different when using these two different shooting methods. In addition, the present study

did not perform further grouping comparisons according to the severity of hallux valgus. Therefore, further research is needed to confirm the results of the present study.

### Acknowledgments

We are particularly grateful to all the people who have helped us with our article.

### References

- George EE. Hallux valgus, allied deformities of the forefoot and metatarsalgia. *Br Med J*, 1965, 2: 1231–1232.
- Bi CQ, Wen JM, Sang ZC, Sun WD, Wen GN, Chang C. X-ray evaluation of the stability of the osteotomy end after hallux valgus surgery and its clinical application. *China Med Herald*, 2017, 14: 134–137.
- Wang ZY. *Foot and Ankle Surgery*. Beijing: People's Health Publishing House, 2006; 455–487.
- Gribbin CK, Ellis SJ, Nguyen J, Williamson E, Cody EA. Relationship of radiographic and clinical parameters with hallux valgus and second ray pathology. *Foot Ankle Int*, 2017, 38: 14–19.
- Ponzio DY, Pedowitz DI, Verma K, Maltenfort MG, Winters BS, Raikin SM. Radiographic outcomes of postoperative taping following hallux valgus correction. *Foot Ankle Int*, 2015, 36: 820–826.
- Gao GQ, Dong Y, Wen JM, et al. Observation on curative effect of minimally invasive osteotomy combined with traditional Chinese and Western medicine for severe hallux valgus. *Chin J Basic Med Tradit*, 2016, 22: 132–134.
- Wu CS, Hu HW, Wen JM, et al. Bland-Altman analysis of different X-ray measurements of HAV angle and IM angle after distal hallux valgus osteotomy. *Chin J Bone Joint Injury*, 2015, 30: 610–613.
- Dixon AE, Lee LC, Charlton TP, Thordarson DB. Increased incidence and severity of postoperative radiographic hallux valgus interphalangeus with surgical correction of hallux valgus. *Foot Ankle Int*, 2015, 36: 961–968.
- Schneider W, Csepan R, Knahr K. Reproducibility of the radiographic metatarsophalangeal angle in hallux surgery. *J Bone Joint Surg Am*, 2003, 85: 494–499.
- Meng HZ, Zhang WL, Li XC, Yang MW. Radiographic angles in hallux valgus: comparison between protractor and iPhone measurements. *J Orthop Res*, 2015, 33: 1250–1254.
- Xu H, Jin K, Fu Z, et al. Radiological characteristics and anatomical risk factors in the evaluation of hallux valgus in Chinese adults. *Chin Med J (Engl)*, 2015, 128: 51–57.
- Geaney LE, Myerson MS. Radiographic results after hallux metatarsophalangeal joint arthrodesis for hallux varus. *Foot Ankle Int*, 2015, 36: 391–394.
- Coughlin MJ. Hallux valgus. *J Bone Joint Surg Am*, 1996, 78: 932–966.
- Gui JC, Gu XJ, Hou MF, et al. Measurement of the first sequence of normal foot and valgus foot and its clinical significance. *Chin J Orthop*, 2001, 21: 137–140.
- Wang LJ, Zhang JZ. Research progress of the first metatarsal angle of lateral talus. *Chin J Med Imag*, 2012, 20: 558–560.
- Jin WK, Sun JS. Juvara osteotomy combined with soft tissue release for moderate to severe hallux valgus. *Chin J Bone Joint Injury*, 2017, 32: 439–441.
- Strydom A, Saragas NP, Ferrao PNF. A radiographic analysis of the contribution of hallux valgus interphalangeus to the total valgus deformity of the hallux. *Foot Ankle Surg*, 2015, 23: 27–31.
- Mckean RM, Bergin PF, Watson G, Mehta SK, Tarquinio TA. Radiographic evaluation of Intermetatarsal angle correction following first MTP joint arthrodesis for severe hallux valgus. *Foot Ankle Int*, 2016, 37: 1183–1186.
- Zhang QS, Yan GH. Reverdin operation combined with first metatarsal base osteotomy and wedge bone grafting in the treatment of 20 cases of moderate and severe hallux valgus. *J Pract Med*, 2016, 32: 2248–2250.
- Roan LY, Tanaka Y, Taniguchi A, Tomiwa K, Kumai T, Cheng YM. Why do lesser toes deviate laterally in hallux valgus? A radiographic study. *Foot Ankle Int*, 2015, 36: 664–672.