



## Case report

## Neovascularization of the iris in retinoschisis

Geraldine R. Slean<sup>a</sup>, Arthur D. Fu<sup>a, b</sup>, Judy Chen<sup>a, b</sup>, Ananda Kalevar<sup>a, b, \*</sup><sup>a</sup> Department of Ophthalmology, California Pacific Medical Center, 711 Van Ness, Suite 250, San Francisco, CA, 94102, USA<sup>b</sup> West Coast Retina, 1445 Bush Street, San Francisco, CA, 94109, USA

## ARTICLE INFO

## Article history:

Received 14 January 2017

Accepted 20 June 2017

Available online 22 June 2017

## Keywords:

Senile retinoschisis  
Iris neovascularization  
Rubeosis iridis

## ABSTRACT

**Purpose:** To report the association of rubeosis iridis with chronic bullous degenerative peripheral retinoschisis.**Observations:** A 63-year-old female presented with acute hyphema and neovascularization of the iris in association with elevated intraocular pressure. Posterior segment examination including imaging revealed no vascular occlusion as a potential cause. However, large, peripheral bullous retinoschisis was noted in the right eye. No nonperfusion aside from that seen within the schism detachment, or neovascularization of the retina on wide-field fundus photography or fluorescein angiography was noted. Bullous retinoschisis was also found in the left eye. The patient was treated conservatively with prednisolone acetate and timolol eye drops.**Conclusions and importance:** Chronic bullous retinoschisis can be associated with anterior segment neovascularization such as rubeosis iridis, presumably due to non-perfusion within the retinoschisis cavity.© 2017 The Authors. Published by Elsevier Inc. This is an open access article under the CC BY-NC-ND license (<http://creativecommons.org/licenses/by-nc-nd/4.0/>).

## 1. Introduction

Senile, acquired, or degenerative retinoschisis was first described by Bartels in 1933 and is defined as splitting of the neurosensory retina.<sup>1,2</sup> The split often occurs at the outer plexiform layer or the inner nuclear layer. This disruption of retinal architecture may lead to vascular compromise and abnormalities, such as aneurysms, telangiectasias, and neovascularization.<sup>3,4</sup> To our knowledge these complications have been limited to the posterior segment. Herein, we describe rubeosis iridis in the setting of chronic bullous retinoschisis.

## 2. Case report

A 63-year-old female presented initially with a complaint of episodic vision decrease in her right eye. She denied systemic inflammatory conditions, and had no history of hypertension or diabetes. Best-corrected visual acuity was 20/50 in the right and 20/20 in the left. Intraocular pressures were 21 mmHg and 10 mmHg in the right and left eyes, respectively. Anterior segment

examination of the right eye revealed a hyphema with fine, tortuous neovascularization at the papillary margin from 3 to 9 o'clock (Fig. 1). Anterior segment exam of the left eye was without rubeosis. Gonioscopy revealed no neovascularization of the angle in either eye. On posterior segment examination, a large bullous retinoschisis cavity without holes was seen superotemporally in the right eye (Fig. 2) and inferotemporally in the left eye. A posterior vitreous detachment was also noted in the right eye. No neovascularization of the retina or disc was appreciated in either eye.

Spectral-domain optical coherence tomography (OCT) of the macula were unremarkable (Fig. 3). OCT angiography revealed no choroidal neovascularization. OCT of the superotemporal retina (Fig. 4) confirmed a bullous retinoschisis. Fluorescein angiography revealed retinal nonperfusion corresponding to the retinoschisis cavity without leakage (Fig. 5). The patient was started on prednisolone acetate 1% QID and timolol 0.5% BID in the right eye. Three months after initial presentation, the hyphema and intraocular pressure rise had resolved, but the neovascularization of the iris could still be detected. She deferred any additional intervention in favor of observation and medical topical treatment as needed.

\* Corresponding author. West Coast Retina, 1445 Bush Street, San Francisco, CA 94109, USA.

E-mail address: [andy.kalevar@mail.mcgill.ca](mailto:andy.kalevar@mail.mcgill.ca) (A. Kalevar).

### 3. Discussion

Iris neovascularization can arise from multiple etiologies including diabetic retinopathy, central retinal vein occlusion, branch retinal vein occlusion, ocular ischemic syndrome, retinal detachment, and uveitis.<sup>5</sup> These causes typically result from a common pathway of retinal ischemia extensive enough to induce angle or iris neovascularization. Neovascularization and vascular anomalies have been reported with other forms of retinoschisis and chronic retinal detachments. For instance, myopic macular retinoschisis has been associated with the disruption of retinal microcirculation.<sup>6</sup> Juvenile X-linked retinoschisis has been linked to avascularity in areas of schisis and peripheral retina, underdeveloped capillaries, and peripheral neovascularization.<sup>7</sup> Moreover, chronic retinal detachment with macrocyst formation has been linked to peripheral capillary nonperfusion, telangiectasias, and retinal neovascularization.<sup>8</sup> Neovascular glaucoma has also been reported in cases of X-linked retinoschisis,<sup>9,10</sup> branch retinal vein occlusion,<sup>11</sup> and peripheral retinal detachment.<sup>12</sup>

Anterior segment neovascularization can occur without retinal or optic disc neovascularization in such pathologies as diabetic retinopathy and ocular ischemic syndrome.<sup>13</sup> Posterior vitreous detachment can limit posterior segment neovascularization.<sup>14</sup> Similarly, vitrectomy in retinal ischemic disease has been found to be beneficial.<sup>15</sup> This may help explain why retinal or optic disc neovascularization was not present in our patient.

Senile retinoschisis exists in two forms: 1) flat or typical involving an area anterior to the equator, and 2) bullous or reticular involving an area posterior to the equator and occasionally associated with retinal holes or breaks.<sup>16</sup> Bullous retinoschisis results from the union of smaller cystic lesions in peripheral cystoid degeneration.<sup>17</sup> Males and females are equally affected, with a mean age of  $68.6 \pm 5.3$  years.<sup>1</sup> Senile retinoschisis is commonly bilateral and typically involves the inferotemporal or superotemporal quadrants.<sup>2</sup> Vision is rarely impacted with most cases being asymptomatic and non-progressive.<sup>1,2</sup> OCT can be helpful in identifying the neurosensory split and can demonstrate schisis pillars and cystic spaces.<sup>18,19</sup>

Several vascular abnormalities in the setting of senile retinoschisis have been reported. Two cases have demonstrated the presence of telangiectatic retinal vessels overlying areas of senile retinoschisis.<sup>3</sup> Three other cases reported associated vitreous hemorrhage (VH).<sup>4</sup> In these VH cases, neovascularization was seen on the apex of the dome and fluorescein angiography demonstrated

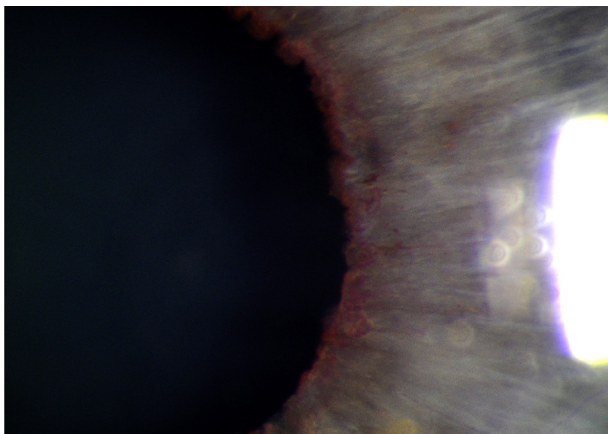


Fig. 1. Anterior segment photography highlights rubeosis iridis in the right eye.

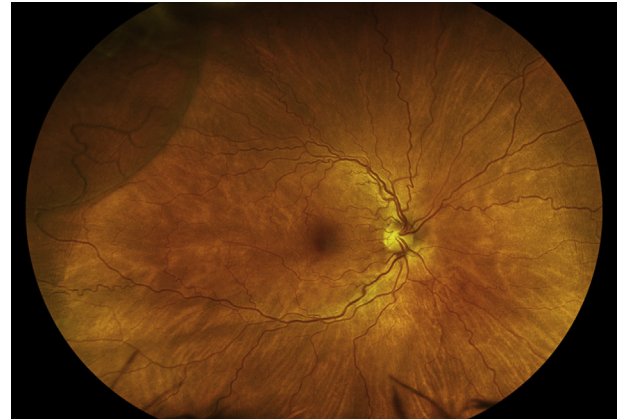

Fig. 2. Wide-field fundus photography demonstrates a bullous retinoschisis superotemporally.

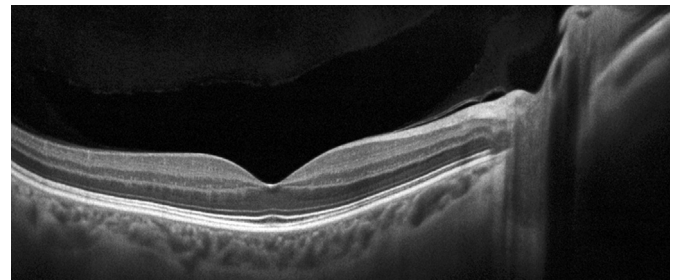


Fig. 3. OCT of the macula in the right eye was unremarkable.

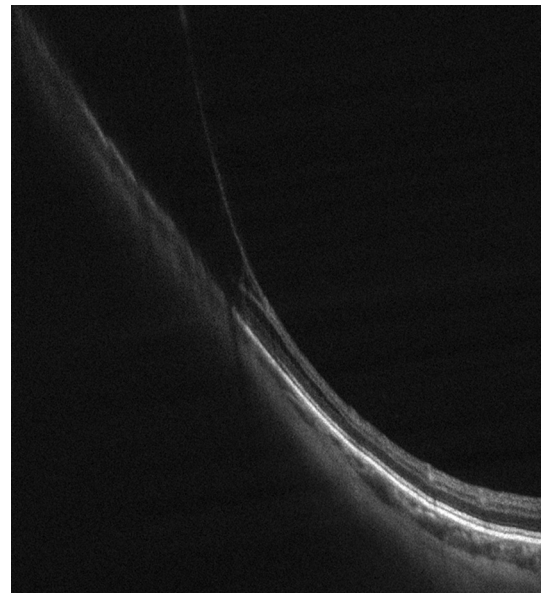
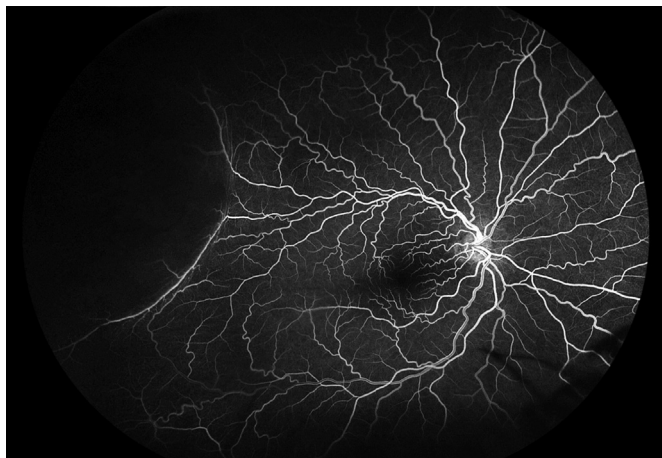


Fig. 4. OCT through the superotemporal retina demonstrates a split of the neurosensory retina representing retinoschisis.

patchy filling of the capillaries along the anterior margin of the bullous retinoschisis and leakage into the inner layer of the cyst. One of these VH cases also demonstrated neovascularization of the retina without underlying retinoschisis. The authors theorized that chronic retinal elevation combined with capillary nonperfusion in bullous retinoschisis can produce sufficient hypoxic drive to cause



**Fig. 5.** Fluorescein angiography reveals nonperfusion over the retinoschisis cavity.

neovascularization. Moreover, neovascularization at a distant site can be attributable to diffusible vasculogenic factors.

#### 4. Conclusions

To the best of our knowledge, this is the first reported case of bullous retinoschisis with rubeosis iridis. Retinal nonperfusion in the area of the retinoschisis may be responsible for producing angiogenic factors, such as vascular endothelial growth factor, and thereby stimulating the formation of new vessels on the iris.

#### Patient consent

The patient described herein has agreed to be featured in this case report. Written consent to publish has been obtained.

#### Funding

No funding or grant support was obtained for this case report.

#### Authorship

All authors attest that they meet the current ICMJE criteria for Authorship.

#### Conflicts of interest

The following authors have no financial disclosures: GS, AF, JC, AK.

#### Acknowledgements

The authors would like to thank Ryan Terribilini in his role as photographer.

#### References

1. Buch H, Vinding T, Nielsen NV. Prevalence and long-term natural course of retinoschisis among elderly individuals: the copenhagen city eye study. *Ophthalmology*. 2007;114:751–755.
2. Byer NE. Long-term natural history study of senile retinoschisis with implications for management. *Ophthalmology*. 1986;93:1127–1137.
3. Ong DN, Harper CA, Lim LL, Fagan X. Primary retinoschisis with vascular changes mimicking neovascularization, illustrated with multimodal imaging. *Clin Exp Ophthalmol*. 2017;45:201–203.
4. Campo RV, Reeser FH, Flindall RJ. Vascular leakage, neovascularization, and vitreous hemorrhage in senile bullous retinoschisis. *Am J Ophthalmol*. 1983;95:826–832.
5. Jeong YC, Hwang YH. Etiology and Features of eyes with rubeosis iridis among Korean patients: a population-based single center study. *PLoS One*. 2016;11:e0160662.
6. Durkin SR, Polkinghorne PJ. Myopic macular retinoschisis with microvascular anomalies. *Eye (Lond)*. 2014;28:501–503.
7. Pearson R, Jagger J. Sex linked juvenile retinoschisis with optic disc and peripheral retinal neovascularisation. *Br J Ophthalmol*. 1989;73:311–313.
8. Labriola LT, Brant AM, Eller AW. Chronic retinal detachment with secondary retinal macrocyst and peripheral neovascularization. *Semin Ophthalmol*. 2009;24:2–4.
9. Shazly TA, Latina MA. Neovascular glaucoma: etiology, diagnosis and prognosis. *Semin Ophthalmol*. 2009;24:113–121.
10. Zuo C, Chen C, Xing Y, Du L. Neovascular glaucoma in a patient with X-linked juvenile retinoschisis. *Yan Ke Xue Bao*. 2005;21:140–141, 151.
11. Chan CK, Ip MS, Vanveldhuisen PC, et al. SCORE Study report #11: incidences of neovascular events in eyes with retinal vein occlusion. *Ophthalmology*. 2011;118:1364–1372.
12. Barile GR, Chang S, Horowitz JD, Reppucci VS, Schiff WM, Wong DT. Neovascular complications associated with rubeosis iridis and peripheral retinal detachment after retinal detachment surgery. *Am J Ophthalmol*. 1998;126:379–389.
13. Hayreh SS. Neovascular glaucoma. *Prog Retin Eye Res*. 2007;26:470–485.
14. Hikichi T, Konno S, Trempe CL. Role of the vitreous in central retinal vein occlusion. *Retina*. 1995;15:29–33.
15. Holekamp NM. The vitreous gel: more than meets the eye. *Am J Ophthalmol*. 2009;149:32–36.
16. Straatsma BR, Foss RY. Typical and reticular degenerative retinoschisis. *Am J Ophthalmol*. 1973;75:551–575.
17. Lewis H. Peripheral retinal degenerations and the risk of retinal detachment. *Am J Ophthalmol*. 2003;136:155–160.
18. Landa G, Shirkey BL, Garcia PM, Milman T, Garcia JP, Rosen RB. Acquired senile retinoschisis of the peripheral retina imaged by spectral domain optical coherence tomography: a case report. *Eur J Ophthalmol*. 2010;20:1079–1081.
19. Agarwal A, Fan S, Invernizzi A, et al. Characterization of retinal structure and diagnosis of peripheral acquired retinoschisis using high-resolution ultrasound B-scan. *Graefes Arch Clin Exp Ophthalmol*. 2016;254:69–75.