

Extensive pelvic and abdominal lymphadenopathy with hepatosplenomegaly treated with radiotherapy—A case report

Sahil Mittal¹, Shaikh A. Hussain², Rahul V. C. Tiwari³, Ajith B. Poovathingal⁴, Padma Priya B⁵, Rishabh Bhanot⁶, Heena Tiwari⁷

¹Department of General Surgery, Maharishi Markandeshwar Institute of Medical Sciences and Research (Deemed to be University), H No. 3478 Sector 23D, ²Department of Anatomy, SSR Medical College, Belle Rive, Mauritius, ³Department of Oral and Maxillofacial Surgery, Sri Sai College of Dental Surgery, Vikarabad, Telangana, ⁴Post Graduate Resident, Internal Medicine, Yerevan State Medical University, Yerevan, Armenia, ⁵Pediatric Post Graduate Resident, Yerevan State Medical University, Yerevan, Armenia, ⁶Consultant Oral and Maxillofacial Surgeon, SRCJC Hospital, Ludhiana, Punjab, ⁷Government Dental Surgeon, Chhattisgarh, India

ABSTRACT

This is a case report of a 65-year-old female patient diagnosed with Grade II Follicular Lymphoma of the pelvic and abdomen was treated with a combination of R-CHOP chemotherapy and radiotherapy.

Keywords: Abdominal lymphadenopathy, hepatosplenomegaly, radiotherapy

Introduction

Lymphomas are divided into two general categories, Hodgkin lymphoma and non-Hodgkin lymphoma (NHL), which are differentiated and detected based on the microscopic features. Within these two large groups, there are a myriad of subtypes out of which the most common types are diffuse large B-cell lymphoma and follicular lymphoma.^[1] Follicular lymphoma (FL) is an indolent lymphoproliferative disorder of B-cells with variable clinical behavior. It is second most common variant of NHL which accounts to 10–20% of NHLs in USA and European countries.^[2] In India, the incidence rate as reported by different studies ranges between 7.2 and 19.3%, average age

of occurrence ranges between 50 and 60 years.^[3] Patients often present with palpable adenopathy throughout the body including cervical, axillary, and inguinal regions. Patient also complains of fever, malaise, unexplained weight loss, and profuse night sweats.^[4] Diagnosis of follicular lymphoma is often delayed due to non-specific presentation of its symptoms. A complete diagnostic work-up is advised [Table 1]. World Health Organization (WHO), classified lymphomas histologically based on the number of blasts/high-power field in a lymphnode biopsy section [Table 2].

Factors influencing the treatment plan are patient's age, patient's symptoms, overall tumor burden and stage of lymphoma. Based on these factors if the patient is asymptomatic they are kept under periodic observation, in case of mild symptoms rituximab monotherapy is considered. In cases with high tumor burden, treatment varies between surgery, chemoimmunotherapy, and radiotherapy. Prognosis is determined based on a

Address for correspondence: Dr. Sahil Mittal, Department of General Surgery, Maharishi Markandeshwar Institute of Medical Sciences and Research (Deemed to be University), H No. 3478 Sector 23D, Chandigarh, India. E-mail: thesispublicationdissertation@gmail.com

Received: 12-09-2019

Revised: 13-01-2020

Accepted: 24-01-2020

Published: 28-02-2020

Access this article online

Quick Response Code:



Website:
www.jfmpc.com

DOI:
10.4103/jfmpc.jfmpc_1125_19

This is an open access journal, and articles are distributed under the terms of the Creative Commons Attribution-NonCommercial-ShareAlike 4.0 License, which allows others to remix, tweak, and build upon the work non-commercially, as long as appropriate credit is given and the new creations are licensed under the identical terms.

For reprints contact: reprints@medknow.com

How to cite this article: Mittal S, Hussain SA, Tiwari RV, Poovathingal AB, Priya BP, Bhanot R, *et al.* Extensive pelvic and abdominal lymphadenopathy with hepatosplenomegaly treated with radiotherapy—A case report. J Family Med Prim Care 2020;9:1215-8.

“Follicular Lymphoma-specific International Prognostic Index (FLIPI)” [Table 3].^[5]

This is a case report of a 65-year-old female patient diagnosed with Grade II follicular lymphoma and was treated with chemotherapy along with radiotherapy to reduce the tumor burden.

Case Report

Initial examination

A 65-year-old female patient was referred to the general surgery department with a complaint of abdominal pain, distension of abdomen, and intermittent fever since 5–6 months. The patient developed dull, non-radiating pain in the umbilical and hypogastric region 6 months back which was insidious in onset,

Table 1: Diagnostic work-up

i.	Physical examination of peripheral lymph nodes, liver and spleen
ii.	Complete blood examination including lactate dehydrogenase (LDH), β 2 microglobulin and uric acid
iii.	Screening tests for human immunodeficiency virus (HIV), hepatitis B virus (HBV) and hepatitis C
iv.	Biopsy
v.	Computed tomography (CT) scan of neck, thorax, abdomen and pelvis
vi.	Positron emission tomography (PET)-CT - to confirm the localised disease or in case of suspected transformation
vii.	Bone marrow aspirate - if indicated clinically
viii.	Electrocardiogram, Creatinine clearance and Reproductive counselling in young patients

Table 2: World health organization histological classification based on the number of blasts/high-power field in a lymphnode biopsy section

GRADE OF TUMOR	NO OF BLASTS/HIGH POWER FIELD
Grade 1 -	≤ 5 blasts/high-power field
Grade 2 -	6-15 blasts/high-power field
Grade 3A-	>15 blasts/high-power field, centroblasts with intermingled centrocytes
Grade 3B-	>15 blasts/high-power field, pure sheets of blasts

Table 3: Follicular lymphoma-specific international prognostic index (FLIPI) risk factors

PARAMETER	DEFINITION OF RISK FACTORS	
	FLIPI I	FLIPI II
NODAL SITES	>4 lymph node regions	Long diameter of largest lymph node >6 cm
AGE	>60 years	>60 years
SERUM MARKER	Elevated LDH	Elevated β 2 microglobulin
STAGE	Advanced (III-IV according to Ann Arbor classification)	Bone marrow involvement
HEMOGLOBIN	<12 g/dl	<12 g/dl

0-1 risk factors, low risk; 2 risk factors, intermediate risk; 3-5 risk factors, high risk. LDH, lactate dehydrogenase.

aggravated during physical activity, relieved her of pain in supine position and was not associated with nausea or vomiting. She complained of distension of abdomen which was associated with respiratory difficulty in supine position and increased frequency of urination. Her fever since 5 months was low grade, intermittent in nature, lasted 3–4 days and was not associated with chills and rigors. Relief from medications prescribed by a local physician was short-lived. She also reported loss of appetite and weight loss during the preceding 6 months. Her medical history included previously diagnosed hypertensive state and was not on regular medications for the same. She had 3 children through normal vaginal delivery and attained menopause 20 years back.

Detailed examination

On examination, patient was calm, conscious, well oriented to time, place, and person. On inspection, abdomen was distended with umbilicus positioned midway between xiphisternum and symphysis pubis. Respiration was abdominothoracic, with no visible peristalsis and pulsatile movements seen. Superficial palpation revealed tense and distended abdomen with no rise in local temperature in all nine quadrants. A group of lymphnodes in the left supraclavicular region, right and left iliac regions were palpable. All the organs from right iliac fossa to right hypochondrium were deeply palpated, tenderness was not felt over gastric, duodenal, gall bladder, mc burney, amebic and renal point regions. Liver was palpable 1.5 cm below the right subcostal margin and kidneys were not ballotable. No splenomegaly was felt while palpating from right iliac region to left hypochondrium. On further deep palpation, a lump was palpable in the hypogastrum region along with bilateral inguinal lymph nodes, 3–4 lymph nodes in right inguinal region were firm, immobile, oval and rubbery in consistency. Dual notes were obtained on percussion along with a shifting dullness over the abdomen. Percussion further revealed liver dullness starting from the 5th intercostal space along with positive fluid thrill and a negative succession splash.

Imaging

A computed tomography (CT) scan of the abdomen and pelvis was suggested and performed with administration of oral and intravenous contrast [Figures 1 and 2]. CT scans showed an extensive pelvic and abdominal lymphadenopathy along with conglomerate lymphnodal mass seen in retroperitoneum and mesentery regions. Liver and spleen were enlarged to 17 cm and 14 cm, respectively, showed small hypoechoic lesions on USG correlation. CT showed an enlarged retroperitoneum lymphnodal mass extending from the right hypogastrum toward right adnexa. Significant ascites was seen in the peritoneal cavity along with small nodular deposits in omentum.

Histology

A needle biopsy was performed for the right inguinal lymph node and the section examined showed lymph node revealing partial effacement of architecture with cells arranged in follicles. Cells are small to intermediate with cleaved nuclei, open

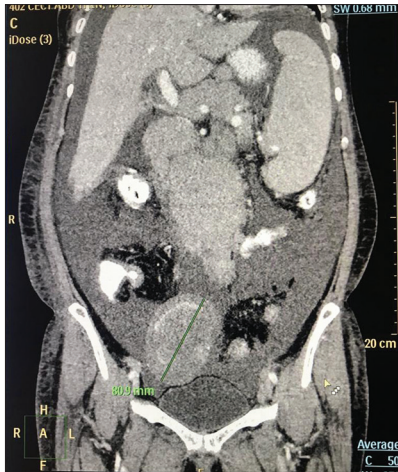

Figure 1: Conglomerate lymph node mass in the detected in the peri-pancreatic region and in the root of the mesentery with discrete nodes in the porta, along celiac axis. Large mass lesion detected in the right hypogastrium extending towards right adnexa

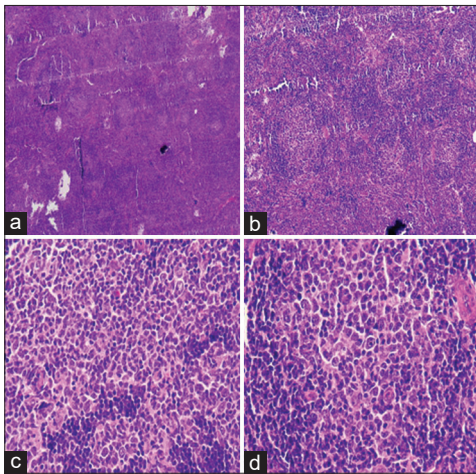


Figure 2: (a-d) H and E Sections of inguinal lymph node

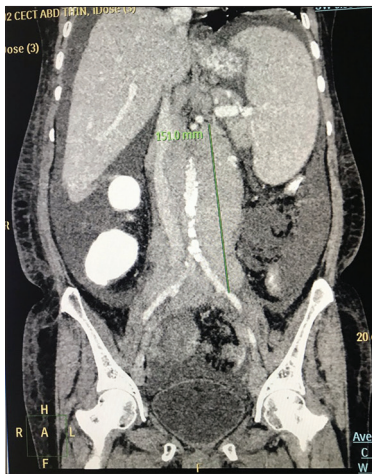


Figure 3: Extensive pelvic and abdominal lymphadenopathy with formation of conglomerate lymph node mass in the retroperitoneum and mesentery. The mass is seen encasing the aorta, common iliacs and the IVC. Hepatosplenomegaly with small hypoechoic lesions

up chromatin, inconspicuous nucleoli and scant cytoplasm. Interspersed in between were large cells with ovoid nuclei, vesicular chromatin, 1–2 nucleoli, and moderate amount of cytoplasm. Immunostaining of the cells showed reactivity to CD3, CD10, CD20, bcl2, cyclinD1 [Figure 2(a)-(d)].

Based on these clinical, radiographic, and histological features, the patient was diagnosed with grade II follicular lymphoma [Figure 3]. As the 65-year-old patient presented with extensive pelvic and abdominal lymphadenopathy, we treated the lymphoma with radiotherapy to minimize the morbidity. Due to the high tumor burden, patient was started with R-CHOP (Rituximab, Cyclophosphamide, Oncovin and Prednisolone) which was followed by six cycles of radiotherapy. She was subjected to 40 gray units at 5 fractions a day. She showed signs of improvement with every cycle with respect to the tumor size and blood investigations.

Discussion

Based on the extent of invasion, follicular lymphoma is categorized into localized and generalized lymphoma. Radiotherapy is the first line of treatment for Stage I and contiguous stage II lymphomas.^[6] Some contiguous stage II lesions may be categorized as generalized lymphomas due to the presence of extended multiple sites as stated in our case report. Due to a sizeable multiorgan invasion of the tumor cells in the abdominal region, radiotherapy along with chemotherapy was considered as the choice of treatment in our case. The rationale for the use of RT is thus based on the results of large mono-institutional experiences or observational cohort studies, which has been incorporated by international cooperative groups.^[7,8] Following radiotherapy, complete regression of the lesions occurs at the irradiated site, however local recurrences may occur distant from the radiotherapy site in 1–11% of the cases.^[9]

The concept of RT has evolved over the years; present-day treatment planning principles are based on defining a gross tumor volume (GTV) and clinical target volume (CTV), which together determine the planning target volume (PTV).^[10] These parameters sequentially determine the dose coverage. The target volumes are calculated based on whether RT is being used as a single treatment modality or in combination therapy. RT is preferred as the first line of treatment in localized aggressive nodal lymphomas which are unsuitable and are refractory to chemotherapy because of serious comorbidities.^[11] Studies show that consolidation RT plays a significant role in improving the outcomes of bulky and extranodal disease, especially in advanced stage lymphomas. The RT fields selected for such extensive lesions was reduced to IFRT (involved field radiation therapy) compared to previously used EFRT (extensive field radiation therapy).^[12] Modern imaging techniques such as computed tomography (CT) and positron emission tomography (PET) have contributed significantly toward planning precise tumor volumes (GTV, CTV and PTV). In INRT (Involved node radiation therapy), only the tissue volume with macroscopic lymphoma is targeted, whereas systemic

therapy targets the lymphoma at microscopic level.^[13,14] With the introduction of INRT technique, the treatment plan was customized according to each patient's lymphoma in a conformal manner. Currently, recommended RT dose for localized follicular lymphoma is 24 Gy.^[15] In the case reported due to the bulk of the tumor, we used 40 Gy units of radiation.

Conclusion

Early diagnosis of follicular lymphoma reduces the morbidity and improves the overall prognosis and quality of life. Primary care centers play a vital role in promoting health and awareness about the importance of screening in high-risk patients. Healthcare providers should be able to identify the alarming symptoms presented by the patients and take necessary steps at the earliest.

Declaration of patient consent

The authors certify that they have obtained all appropriate patient consent forms. In the form the patient(s) has/have given his/her/their consent for his/her/their images and other clinical information to be reported in the journal. The patients understand that their names and initials will not be published and due efforts will be made to conceal their identity, but anonymity cannot be guaranteed.

Financial support and sponsorship

Nil.

Conflicts of interest

There are no conflicts of interest.

References

- Armitage JO, Weisenburger DD. New approach to classifying non-Hodgkin's lymphomas: Clinical features of the major histologic subtypes. Non-Hodgkin's lymphoma classification project. *J Clin Oncol* 1998;16:2780-95.
- Goldin LR, Björkholm M, Kristinsson SY, Turesson I, Landgren O. Highly increased familial risks for specific lymphoma subtypes. *Br J Haematol* 2009;146:91-4.
- Sylvia MT, Dey B, Basu D, Jacob SE, Kar R, Dubashi B. Follicular lymphoma: A clinicopathological analysis from a tertiary care institute in Southern India. *Mediterr J Hematol Infect Dis* 2016;8:e2016060.
- Sasaki J, Kurihara H, Nakano Y, Kotani K, Tame E, Sasaki A. Apparent spontaneous regression of malignant neoplasms after radiography: Report of four cases. *Int J Surg Case Rep* 2016;25:40-3.
- Dreyling M, Ghielmini M, Rule S, Salles G, Vitolo U, Ladetto M. Newly diagnosed and relapsed follicular lymphoma: ESMO clinical practice guidelines for diagnosis, treatment and follow-up. *Ann Oncol* 2016;27(Suppl 5):v83-90.
- Montoto S. Localized FL: How long in response to be cured? *Blood* 2019;133:187-8.
- Tobin JW, Rule G, Colvin K, Calvente L, Hodgson D, Bell S, *et al.* Outcomes of stage I/II follicular lymphoma in the PET era: An international study from the Australian Lymphoma Alliance. *Blood Adv* 2019;3:2804-11.
- Lo AC, Campbell BA, Pickles T, Aquino-Parsons C, Sehn LH, Connors JM, *et al.* Long-term outcomes for patients with limited stage follicular lymphoma: An update of a population-based study. *Int J Radiat Oncol Biol Phys* 2019;105:S33-4.
- Zelenetz AD, Abramson JS, Advani RH, Andreadis CB, Byrd JC, Czuczman MS, *et al.* NCCN clinical practice guidelines in oncology: Non-Hodgkin's lymphomas. *J Natl Compr Canc Netw* 2010;8:288-334.
- Specht L, Yahalom J. The concept and evolution of involved site radiation therapy for lymphoma. *Int J Clin Oncol* 2015;20:849-54.
- Illidge T, Specht L, Yahalom J, Aleman B, Berthelsen AK, Constine L, *et al.* Modern radiation therapy for nodal non-Hodgkin lymphoma—target definition and dose guidelines from the International Lymphoma Radiation Oncology Group. *Int J Radiat Oncol Biol Phys* 2014;89:49-58.
- Yahalom J, Illidge T, Specht L, Hoppe RT, Li YX, Tsang R, *et al.* Modern radiation therapy for extranodal lymphomas: Field and dose guidelines from the International Lymphoma Radiation Oncology Group. *Int J Radiat Oncol Biol Phys* 2015;92:11-31.
- Hoskin PJ, Kirkwood AA, Popova B, Smith P, Robinson M, Gallop-Evans E, *et al.* 4 Gy versus 24 Gy radiotherapy for patients with indolent lymphoma (FORT): A randomised phase 3 non-inferiority trial. *Lancet Oncol* 2014;15:457-63.
- Girinsky T, Specht L, Ghalibafian M, Edeline V, Bonniaud G, Van Der Maazen R, *et al.* The conundrum of Hodgkin lymphoma nodes: To be or not to be included in the involved node radiation fields. The EORTC-GELA lymphoma group guidelines. *Radiother Oncol* 2008;88:202-10.
- Wang L, Wu Z, Xie D, Zeng R, Cheng W, Hu J, *et al.* Reduction of target volume and the corresponding dose for the tumor regression field after induction chemotherapy in locoregionally advanced nasopharyngeal carcinoma. *Cancer Res Treat* 2019;51:685-95.