

Clinico-pathology, hematology, and biochemistry responses toward *Pasteurella multocida* Type B: 2 via oral and subcutaneous route of infections

Eric Lim Teik Chung¹, Faez Firdaus Jesse Abdullah^{1,2}, Lawan Adamu^{1,3}, Ali Dhiaa Marza^{1,4}, Hayder Hamzah Ibrahim^{1,5}, Mohd Zamri-Saad⁶, Abdul Wahid Haron^{1,2}, Abdul Aziz Saharee¹, Mohd Azmi Mohd Lila⁶, Abdul Rahman Omar⁶, Md Zuki Abu Bakar⁷ and Mohd Jefri Norsidin¹

1. Department of Veterinary Clinical Studies, Faculty of Veterinary Medicine, Universiti Putra Malaysia, 43400 Serdang, Selangor, Malaysia; 2. Department of Ruminant Disease, Research Centre for Ruminant Disease, Universiti Putra Malaysia, 43400 Serdang, Selangor, Malaysia; 3. Department of Veterinary Medicine, Faculty of Veterinary Medicine, University of Maiduguri, PMB1069, Borno State, Nigeria; 4. Department of Veterinary Internal Medicine, Faculty of Veterinary Medicine, Al-Qasim Green University, Iraq; 5. Department of Veterinary Medicine, Technical Institute Babil, Al Furat Alawast Technical University, Iraq; 6. Department of Veterinary Pathology and Microbiology, Faculty of Veterinary Medicine, Universiti Putra Malaysia, 43400 Serdang, Selangor, Malaysia; 7. Department of Preclinical, Faculty of Veterinary Medicine, Universiti Putra Malaysia, 43400 Serdang, Selangor, Malaysia.

Corresponding author: Faez Firdaus Jesse Abdullah, e-mail: jesseariasamy@gmail.com, ELTC: eric88lim@gmail.com, LA: drlawan3758@yahoo.com, ADM: ali.alhashimi471969@yahoo.com, HHI: altee.hayder@yahoo.com, MZS: mzamri@upm.edu.my, AWH: wahidh@upm.edu.my, AAS: abdaziz@upm.edu.my, MAML: azmi@upm.edu.my, ARO: aro@upm.edu.my, MZAB: zuki@upm.edu.my, MJN: jaretguli@gmail.com

Received: 04-03-2015, **Revised:** 20-05-2015, **Accepted:** 26-05-2015, **Published online:** 24-06-2015

doi: 10.14202/vetworld.2015.783-792 **How to cite this article:** Chung ELT, Abdullah FFJ, Adamu L, Marza AD, Ibrahim HH, Zamri-Saad M, Haron AW, Saharee AA, Lila MAM, Omar AR, Bakar MZA, Norsidin MJ, Clinico-pathology, hematology and biochemistry responses towards *pasteurella multocida* Type B:2 via oral and subcutaneous route of infections, *Veterinary World* 8(6):783-792.

Abstract

Background: *Pasteurella multocida* a Gram-negative bacterium has been identified as the causative agent of many economically important diseases in a wide range of hosts. Hemorrhagic septicemia is a disease caused by *P. multocida* serotype B:2 and E:2. The organism causes acute, a highly fatal septicemic disease with high morbidity and mortality in cattle and more susceptible in buffaloes. Therefore, the aim of this study was to investigate the clinical signs, blood parameters, post mortem and histopathology changes caused by *P. multocida* Type B:2 infections initiated through the oral and subcutaneous routes.

Methods: Nine buffalo heifers were divided equally into 3 treatment groups. Group 1 was inoculated orally with 10 ml of phosphate buffer saline; Groups 2 and 3 were inoculated with 10 ml of 10¹² colony forming unit of *P. multocida* Type B:2 subcutaneously and orally respectively.

Results: There was a significant difference ($p < 0.05$) in temperature between the subcutaneous and the control group. The results revealed significant differences ($p < 0.05$) in erythrocytes, hemoglobin, packed cell volume, leukocytes, monocytes, and A: G ratio between the subcutaneous and the control group. Furthermore, there were significant differences ($p < 0.05$) in leukocytes, band neutrophils, segmented neutrophils, lymphocytes, eosinophils, basophils, thrombocytes, plasma protein, icterus index, gamma glutamyl transferase and A: G ratio between the oral and the control group. The post mortem lesions of the subcutaneous group buffaloes showed generalized hyperemia, congestion and hemorrhage of the immune organs, gastrointestinal tract organs and vital organs. The oral group buffaloes showed mild lesions in the lung and liver. Histologically, there were significant differences ($p < 0.05$) in hemorrhage and congestion; necrosis and degeneration; inflammatory cells infiltration; and edema in between the groups.

Conclusion: This study was a proof that oral route infection of *P. multocida* Type B:2 can be used to stimulate host cell responses where oral vaccine through feed can be developed in the near future.

Keywords: buffalo heifers, clinico-pathology, hematology and biochemistry responses, oral route, *Pasteurella multocida* Type B:2, subcutaneous route.

Introduction

Hemorrhagic septicemia (HS) disease is a specific form of Pasteurellosis in cattle and buffalo which is different from other Pasteurellosis that play only a secondary role [1]. HS is an acute, fatal, and septicemic disease of cattle and buffaloes caused by a specific serotype of *Pasteurella multocida* which is

a Gram-negative coccobacillus [2-4]. Using a combination of capsular and somatic typing, the two common HS serotypes popularly known as the Asian and African serotypes are designated B:2 and E:2 respectively [5,6]. Buffaloes are more susceptible to the disease and usually occur more frequently in poor husbandry conditions and in countries with disease surveillance that is not well developed [2,7,8]. The disease is of great economic importance in Malaysia and throughout South-east Asia where cattle and buffaloes are abundant for beef and milk production [9-13].

Copyright: The authors. This article is an open access article licensed under the terms of the Creative Commons Attribution License (<http://creativecommons.org/licenses/by/2.0>) which permits unrestricted use, distribution and reproduction in any medium, provided the work is properly cited.

Sudden death in HS is usually the first report among free-ranging animals during outbreaks. There are four clinical syndromes in a diseased animal. Animal will first exhibit elevated temperature above 40°C, followed by submandibular edema and then respiratory distress with profuse nasal discharge, and finally recumbency and death [2]. At post mortem, the most obvious lesions in affected animals are the edema, widely distributed hemorrhages, and generalized hyperemia. In most cases, there will be also clear or straw colored edematous fluid at the head, neck, brisket and musculature region. Petechial hemorrhages are particularly prominent in the pharyngeal and cervical lymph nodes. Besides that, blood tinge fluid is often found in the pericardial sac, thoracic and abdominal cavity [11,14,15]. Meningitis was also observed [16]. Histopathological lesions such as hemorrhage, hyperemia, edema and white blood cells infiltration were observed in the lung, lymph nodes, spleen, gastro-intestinal tract, liver, kidney and the heart [17]. Nevertheless, knowledge on the changes in the immune system organs had yet to be uncovered. Information on this will play a significant role in understanding the pathogenesis of *P. multocida* Type B:2.

There are still many grey areas in the knowledge of HS. Significant gaps exist in understanding the pathogenesis of the disease [2]. The aim of this study was to investigate the clinical responses, hematology and biochemistry alterations, post mortem changes, and cellular changes in tissues of buffaloes challenged with *P. multocida* Type B:2 via oral and subcutaneous routes.

Materials and Methods

Ethical approval

This research was approved by the Animal Care and Use Committee of Universiti Putra Malaysia (approval number: R056/2014).

Animal selection

A 8-month-old, clinically healthy, non-pregnant and non-lactating buffalo heifers were used in this study. On arrival at the Animal Experimental House, Faculty of Veterinary Medicine, Universiti Putra Malaysia, 1 ml/50 kg of anthelmintic (Ivermectin) was administered subcutaneously to control internal parasitism, which has been shown to influence disease development [15]. Besides that, nasal swabs were also collected from all buffaloes to ensure that the animals were free from *P. multocida* prior to the start of the experiment. The buffaloes were placed in an individual pen and were fed with cut grass and supplement with pellets at the rate of 1 kg/animal/day. Water was available ad libitum.

Inoculums preparation

Wild-type *P. multocida* used in this study was isolated from a previous outbreak of HS in the state of Kelantan, Malaysia. The isolate was confirmed to be *P. multocida* Type B:2 via Gram-staining method, biochemical test and polymerase chain reaction method.

Bacteria were then cultured on blood agar plates and incubated at 37°C for 24 h before the concentration was determined by McFarland Nephelometer Barium Sulfate Standards.

Experimental design

All the 9 buffalo heifers were divided equally into 3 treatment groups. Group 1 was the negative control group where the buffaloes were inoculated orally with 10 ml of phosphate buffer saline. Group 2 was the positive control group and was inoculated subcutaneously with 10 ml of 10¹² colony forming unit (CFU) of *P. multocida* Type B:2. Group 3 was the treatment group where the buffaloes were inoculated orally with 10 ml of 10¹² CFU of *P. multocida* Type B:2 using a stomach tube. During the post-infection period, all the buffaloes were observed for clinical signs and clinical response throughout 21 days. The clinical signs that were observed include temperature, heart rate, respiratory rate, mucous membrane, rumen motility, salivation, nasal discharges, edema swelling, movement, and dullness. Blood samples were collected at a predetermined interval. The blood samples were collected via jugular venipuncture into 5 ml plain vacutainers and ethylenediaminetetraacetic acid tubes for complete blood count and biochemistry analyses. At the end of the study, surviving buffaloes after 21 days were euthanized for post-mortem evaluation. Immune organs, gastro-intestinal tract organs and vital organs samples were collected for microscopic examinations and cellular changes evaluation. The immune organs consist of bone marrow, spleen, submandibular lymph nodes, prescapular lymph nodes, femoral lymph nodes, mesenteric lymph nodes and tonsil. The gastrointestinal tract organs collected were esophagus, rumen, reticulum, omasum, abomasum, duodenum, jejunum, ileum, caecum, colon, and rectum. The vital organs collected were lung, heart, liver, and kidneys.

Histopathology analysis and lesion scoring

The samples were preserved in 10% formalin before they were processed using routine histology slide preparation technique and stained with hematoxylin and eosin stain. The cellular changes observed were hemorrhage and congestion; necrosis and degeneration; inflammatory cells infiltration; and edema lesion. These cellular changes were then scored into 4 scores, which include score 0: Normal (normal tissue); score 1: Mild (<25% tissue affected); score 2: Moderate (<50% tissue affected); and score 3: Severe (more than 50% tissue affected).

Statistical analysis

All the data were analyzed using JMP® 11. NC: SAS Institute Inc. software Version. The data were considered significant at p<0.05.

Results

Clinical response

Buffaloes from Group 1 showed normal clinical finding throughout 21 days. The temperature, heart

rate, respiratory rate, mucous membrane, and rumen motility were within the normal range. There were no salivation, nasal discharges, edema swelling, and dullness observed. On the other hand, buffaloes from Group 2 showed typical HS clinical signs and were only able to survive for the first 12 h of the experiment. At 3 h post-infection, all buffaloes started to have serous nasal discharge followed by congested mucous membrane after 4 h, submandibular edema and dullness after 5 h, and finally mucopurulent nasal discharge with respiratory distress and absent of rumen motility after 11 h post infection. All buffaloes from Group 2 were euthanized at 12 h post infection following the Animal Welfare Guidelines where the animals were in recumbency and were having respiratory distress. Group 2 rectal temperatures were high throughout the experimental period where the temperatures were above 39°C (Figure-1). In contrast, Group 3 buffaloes were able to survive throughout the 21 days experiment regardless of showing some mild clinical response. High rectal temperatures (Figure-2) and serous nasal discharges were only observed for the first 4 days. The rumen motility was normal and was not affected by oral inoculation of *P. multocida* Type B:2. After day 5, all parameters were within the normal range. There were significant differences ($p < 0.05$) in temperature between the subcutaneous and oral group compared to the control group.

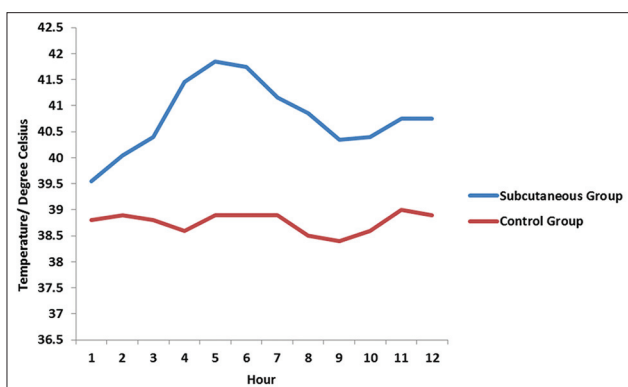


Figure-1: Mean rectal temperatures for the subcutaneous group after 12 h of inoculation with *Pasteurella multocida* Type B:2.

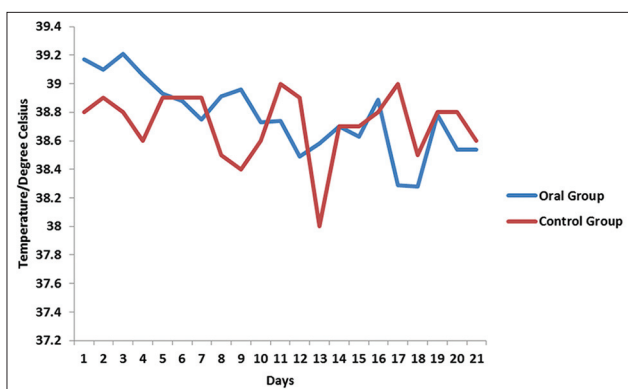


Figure-2: Mean rectal temperatures for the oral group after 21 days of inoculation with *Pasteurella multocida* Type B:2.

Hematology and biochemistry

From the hematology and biochemistry results, there were no significant findings observed in Group 1 buffaloes. However, Group 2 buffaloes showed erythrocytosis, leukopenia and lymphopenia throughout the 12 h of the experiment. In Group 3, all buffaloes were only having leukocytosis for the first 5 days. Other parameters were within the normal range. There were significant differences ($p < 0.05$) in erythrocytes, hemoglobin, packed cell volume (PCV), leukocytes, monocytes, and A: G ratio between the subcutaneous and control group. However, there were no significant differences ($p > 0.05$) in the other parameters (Table-1). In contrast, the oral and control group revealed significant differences ($p < 0.05$) in leukocytes, band neutrophils, segmented neutrophils, lymphocytes, eosinophils, basophils, thrombocytes, plasma protein, icterus index, gamma glutamyl transferase and A: G ratio. There were no significant differences ($p > 0.05$) in the other parameters in buffaloes inoculated orally (Table-2).

Gross lesions

Buffaloes from Group 2 were euthanized after 12 h post infection due to recumbency and sign of respiratory distress. All vital organs including the lung (Figure-3), heart (Figure-4), kidney (Figure-5),

Table-1: Haematological and biochemical alterations in buffaloes after 12 h of subcutaneous inoculation of *Pasteurella multocida* Type B:2.

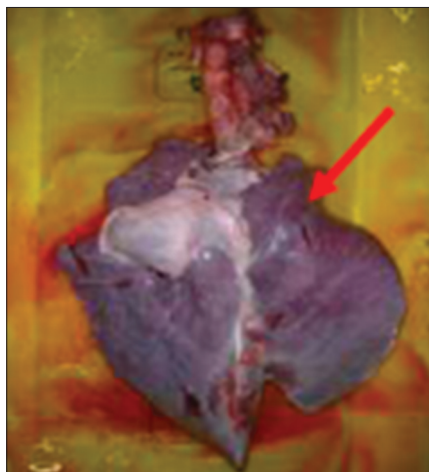Parameters	Control group	Subcutaneous group
Erythrocytes ($\times 10^{12}/L$)	6.86 \pm 0.10 ^b	8.66 \pm 0.20 ^a
Haemoglobin (g/L)	120 \pm 1.78 ^b	152.50 \pm 4.03 ^a
PCV (L/L)	0.36 \pm 0.01 ^b	0.44 \pm 0.01 ^a
MCV (fL)	53 \pm 0.46 ^a	50.56 \pm 0.26 ^a
MCHC (g/L)	333 \pm 2.13 ^a	347.83 \pm 2.94 ^a
Leukocytes ($\times 10^9/L$)	8 \pm 0.37 ^a	3.72 \pm 0.99 ^b
Band neutrophils ($\times 10^9/L$)	0.10 \pm 0.02 ^b	0.09 \pm 0.04 ^b
Seg neutrophils ($\times 10^9/L$)	2 \pm 0.3 ^b	2.33 \pm 0.74 ^b
Lymphocytes ($\times 10^9/L$)	3.04 \pm 0.13 ^b	1.08 \pm 0.25 ^b
Monocytes ($\times 10^9/L$)	0.66 \pm 0.03 ^a	0.23 \pm 0.08 ^b
Eosinophils ($\times 10^9/L$)	0.00 \pm 0.00 ^b	0.00 \pm 0.00 ^b
Basophils ($\times 10^9/L$)	0.00 \pm 0.00 ^b	0.00 \pm 0.00 ^b
Thrombocytes ($\times 10^9/L$)	350 \pm 16.61 ^b	299.89 \pm 35.77 ^b
Plasma protein (g/L)	72 \pm 0.47 ^b	65.89 \pm 0.99 ^b
Icterus index (Unit)	2 \pm 0.18 ^b	4.14 \pm 0.39 ^a
GGT (U/L)	4 \pm 0.28 ^b	3.00 \pm 0.28 ^b
Total protein (g/L)	67.05 \pm 0.52 ^a	63.49 \pm 0.55 ^a
Albumin (g/L)	33.60 \pm 0.28 ^a	32.99 \pm 0.47 ^a
Globulin (g/L)	32.60 \pm 0.50 ^a	30.50 \pm 0.33 ^a
A:G (unit)	1 \pm 0.03 ^b	1.08 \pm 0.02 ^a

All values are expressed as mean \pm SE; ^{a,b}values with superscript within rows are significantly different at $p < 0.05$; PCV=Packed cell volume, MCV=Mean corpuscular volume; MCHC=Mean corpuscular haemoglobin concentration, GGT=Gamma glutamyl transferase; A:G=Albumin:Globulin ratio, SE=Standard error

Table-2: Haematological and biochemical alterations in buffaloes after 21 days of oral inoculation of *Pasteurella multocida* Type B: 2.

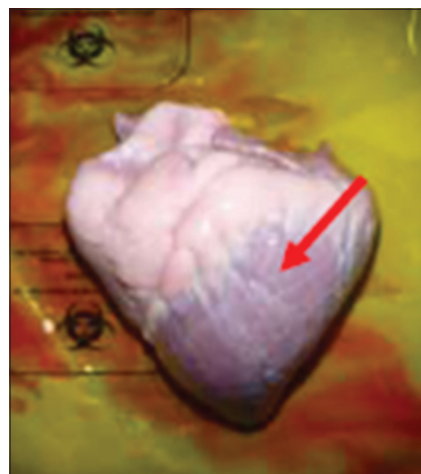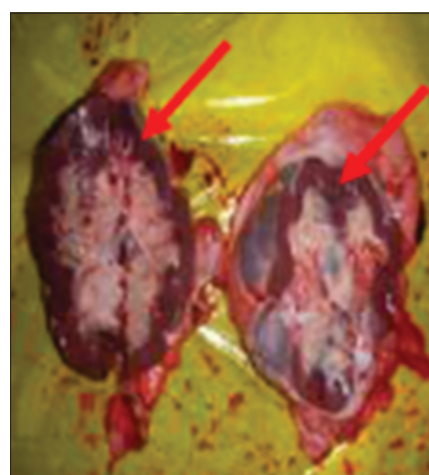
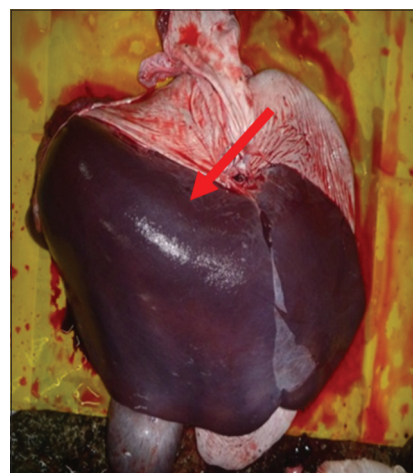
Parameters	Control group	Oral group
Erythrocytes ($\times 10^{12}/L$)	6.86 \pm 0.10 ^b	6.75 \pm 0.21 ^b
Haemoglobin (g/L)	120 \pm 1.78 ^b	120.32 \pm 3.17 ^b
PCV (L/L)	0.36 \pm 0.01 ^b	0.34 \pm 0.01 ^b
MCV (fL)	53 \pm 0.46 ^a	50.75 \pm 1.23 ^a
MCHC (g/L)	333 \pm 2.13 ^a	359.75 \pm 5.13 ^a
Leukocytes ($\times 10^9/L$)	8 \pm 0.37 ^b	13.97 \pm 0.49 ^a
Band neutrophils ($\times 10^9/L$)	0.10 \pm 0.02 ^b	0.25 \pm 0.02 ^a
Seg neutrophils ($\times 10^9/L$)	2 \pm 0.3 ^b	5.30 \pm 0.48 ^a
Lymphocytes ($\times 10^9/L$)	3.04 \pm 0.13 ^b	6.74 \pm 0.25 ^a
Monocytes ($\times 10^9/L$)	0.66 \pm 0.03 ^a	0.79 \pm 0.05 ^a
Eosinophils ($\times 10^9/L$)	0.00 \pm 0.00 ^b	0.72 \pm 0.13 ^a
Basophils ($\times 10^9/L$)	0.00 \pm 0.00 ^b	0.18 \pm 0.04 ^a
Thrombocytes ($\times 10^9/L$)	350 \pm 16.61 ^b	453.53 \pm 31.35 ^a
Plasma protein (g/L)	72 \pm 0.47 ^b	75.85 \pm 0.90 ^a
Icterus index (Unit)	2 \pm 0.18 ^b	3.95 \pm 0.33 ^a
GGT (U/L)	4 \pm 0.28 ^b	8.90 \pm 0.71 ^a
Total protein (g/L)	67.05 \pm 0.52 ^a	65.01 \pm 1.28 ^a
Albumin (g/L)	33.60 \pm 0.28 ^a	33.39 \pm 0.63 ^a
Globulin (g/L)	32.60 \pm 0.50 ^a	31.62 \pm 1.33 ^a
A:G (Unit)	1 \pm 0.03 ^b	1.13 \pm 0.06 ^a

All values are expressed as mean \pm SE; ^{a,b}values with superscript within rows are significantly different at $P<0.05$; PCV=Packed cell volume, MCV=Mean corpuscular volume, MCHC=Mean corpuscular haemoglobin concentration, GGT=Gamma glutamyl tranferase, A:G=Albumin:Globulin ratio, SE=Standard error

**Figure-3:** Congested and hemorrhagic lung.

liver (Figure-6) and spleen (Figure-7) appeared to be hyperemic, congested and hemorrhagic. The gastrointestinal tract such as esophagus, abomasum, duodenum, jejunum, ileum, caecum and rectum also showed similar findings. Straw colored blood tinge fluid was found in the thoracic region (Figure-8).

In contrast, Groups 1 and 3 buffaloes were euthanized only after 21 days for post mortem examination and organs sample collection. All the organs from Group 1 buffaloes appeared to be normal with no significant findings (Figure-9). For Group 3 buffaloes, there were gross lesions in the lung and liver. The left and right cranial lobes of the lung appeared to be congested, fibrinous and firm in consistency (Figure-10). It was consolidated with mosaic/marbling like appearance.

**Figure-4:** Congested and hemorrhagic heart.**Figure-5:** Congested and hemorrhagic kidneys.**Figure-6:** Congested and hemorrhagic liver.

Blood was oozing out upon cutting surface. This condition was also known as fibrinous pleuropneumonia. Besides that, the liver was having mild multifocal hemorrhage and fibrin deposition around the liver surface (Figure-11). Upon cutting the surface, blood was oozing out from the liver. Nevertheless, the immune organs, gastrointestinal organs, and other vital organs from Group 3 buffaloes appeared to be normal grossly.

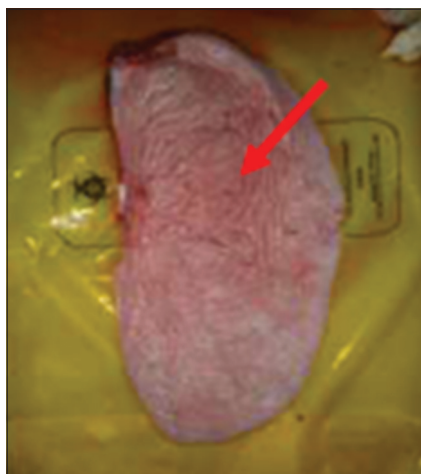

Figure-7: Congested and hemorrhagic spleen.

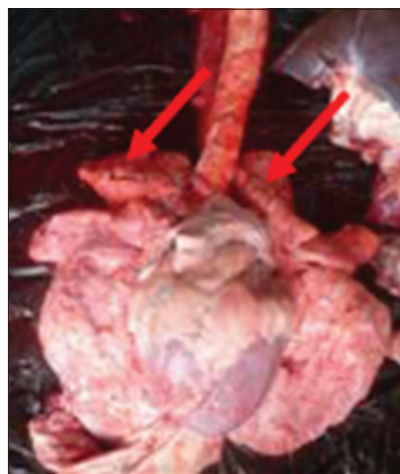


Figure-10: Congested and fibrinous cranial lobes.

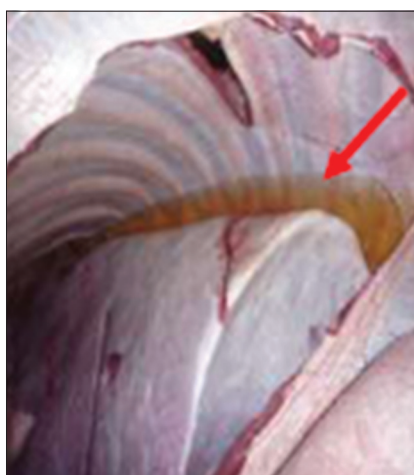

Figure-8: Straw colour fluid in thoracic region.

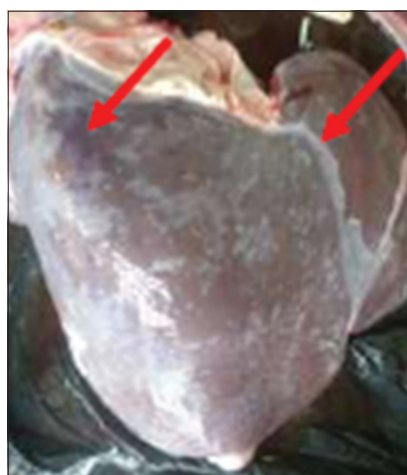

Figure-11: Fibrinous and hemorrhagic liver.

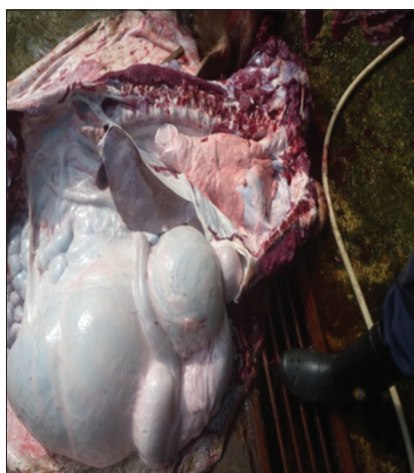

Figure-9: Normal organ *in-situ*.

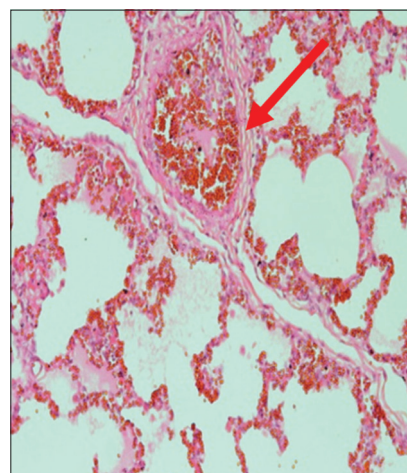


Figure-12: Micrograph of congestion and haemorrhagic in the lung, H and E, $\times 200$, (Group 2).

Histopathology

The immune organs, gastrointestinal tract organs, and the vital organs samples were collected for microscopic examinations. There were no significant histopathology lesions in Group 1 buffaloes. In contrast, buffaloes from Group 2 showed moderate to severe hemorrhage and congestion (Figure-12); necrosis and degeneration (Figure-13); and inflammatory

cell infiltration (Figure-14) in all organs. Also, only the lung showed mild to moderate edema lesions (Figure-15). Group 3 buffaloes also showed mild to moderate hemorrhage and congestion (Figure-16); necrosis and degeneration (Figure-17); and inflammatory cell infiltration (Figure-18) in all organs. Similar to Group 2 buffaloes, only the lung showed normal to

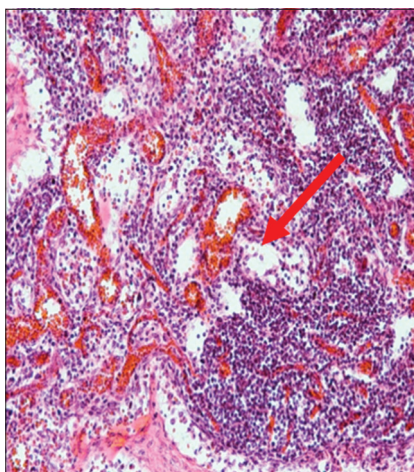


Figure-13: Micrograph of necrosis and degeneration in the submandibular lymph node, H and E, ×200, (Group 2).

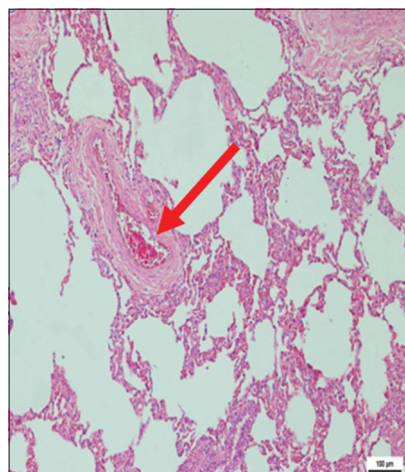


Figure 16: Micrograph of congested and hemorrhagic in the lung, H and E, ×200, (Group 3).

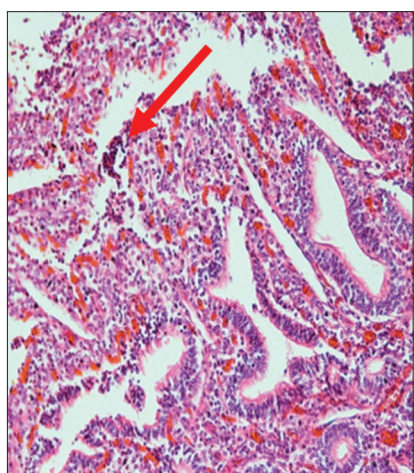


Figure-14: Micrograph of inflammatory cells infiltration in the ileum, H and E, ×200, (Group 2).

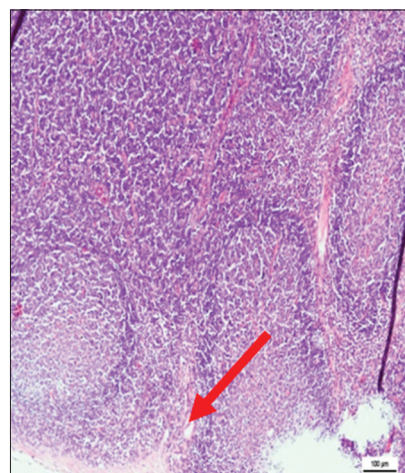


Figure-17: Micrograph of necrosis and degeneration in the submandibular lymph node, H and E, ×200, (Group 3).

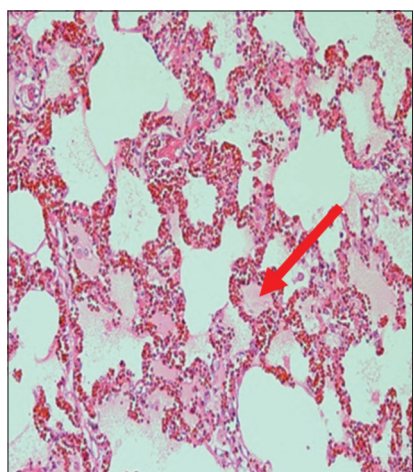


Figure-15: Micrograph of edema in the lung, H and E, ×200, (Group 2).

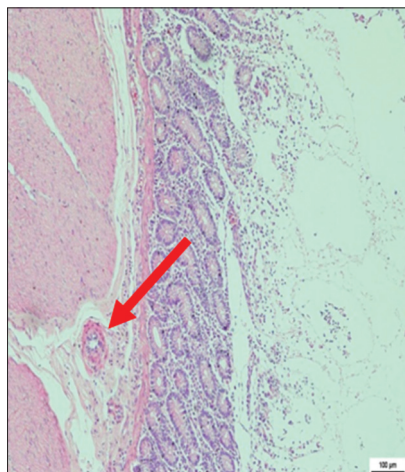


Figure-18: Micrograph of inflammatory cells infiltration in the ileum, H and E, ×200, (Group 3).

mild edema lesions in Group 3 buffaloes (Figure-19). There were significant differences ($p < 0.05$) in hemorrhage and congestion; necrosis and degeneration; and inflammatory cells infiltration in organs comparing Groups 1-3 buffaloes. However, there were no significant differences ($p > 0.05$) in edema lesions in

all organs except for the lung comparing Group 1 to Group 2 (Table-3) and Group 3 buffaloes (Table-4).

Discussion

In most cases, the clinical findings of HS are either acute or peracute, resulting in death within

Table-3: Histopathological alterations in buffaloes after 12 h of subcutaneous inoculations of *Pasteurella multocida* Type B: 2.

Organs	Hemorrhage and congestion		Necrosis and degeneration		Inflammatory cell infiltration		Edema	
	Group 1	Group 2	Group 1	Group 2	Group 1	Group 2	Group 1	Group 2
Bone marrow	0.00±0.19 ^b	2.33±0.19 ^a	0.00±0.00 ^b	1.00±0.00 ^a	0.00±0.11 ^b	0.83±0.11 ^a	0.00±0.00 ^a	0.00±0.00 ^a
Spleen	0.00±0.18 ^b	2.75±0.18 ^a	0.00±0.11 ^b	2.83±0.11 ^a	0.00±0.11 ^b	1.83±0.11 ^a	0.00±0.00 ^a	0.00±0.00 ^a
Submandibular lymph node	0.00±0.00 ^b	2.00±0.00 ^a	0.00±0.14 ^b	1.67±0.14 ^a	0.00±0.14 ^b	1.33±0.14 ^a	0.00±0.00 ^a	0.00±0.00 ^a
Prescapular lymph node	0.00±0.21 ^b	1.83±0.21 ^a	0.00±0.21 ^b	1.83±0.21 ^a	0.00±0.11 ^b	1.17±0.11 ^a	0.00±0.00 ^a	0.00±0.00 ^a
Femoral lymph node	0.00±0.18 ^b	1.75±0.18 ^a	0.00±0.11 ^b	1.67±0.11 ^a	0.00±0.14 ^b	0.67±0.14 ^a	0.00±0.00 ^a	0.00±0.00 ^a
Mesenteric lymph node	0.00±0.11 ^b	1.83±0.11 ^a	0.00±0.11 ^b	1.67±0.11 ^a	0.00±0.11 ^b	0.83±0.11 ^a	0.00±0.00 ^a	0.00±0.00 ^a
Tonsil	0.00±0.14 ^b	2.33±0.14 ^a	0.00±0.14 ^b	1.33±0.14 ^a	0.00±0.14 ^b	0.33±0.14 ^a	0.00±0.00 ^a	0.00±0.00 ^a
Esophagus	0.00±0.08 ^b	1.08±0.08 ^a	0.00±0.20 ^b	1.83±0.20 ^a	0.00±0.15 ^b	0.50±0.15 ^a	0.00±0.00 ^a	0.00±0.00 ^a
Rumen	0.00±0.19 ^b	1.33±0.19 ^a	0.00±0.15 ^b	1.50±0.15 ^a	0.00±0.11 ^b	0.83±0.11 ^a	0.00±0.00 ^a	0.00±0.00 ^a
Reticulum	0.00±0.17 ^b	1.00±0.17 ^a	0.00±0.21 ^b	1.83±0.21 ^a	0.00±0.21 ^b	0.83±0.21 ^a	0.00±0.00 ^a	0.00±0.00 ^a
Omasum	0.00±0.14 ^b	1.33±0.14 ^a	0.00±0.14 ^b	1.67±0.14 ^a	0.00±0.11 ^b	1.17±0.11 ^a	0.00±0.00 ^a	0.00±0.00 ^a
Abomasum	0.00±0.15 ^b	1.50±0.15 ^a	0.00±0.17 ^b	2.00±0.17 ^a	0.00±0.11 ^b	1.17±0.11 ^a	0.00±0.00 ^a	0.00±0.00 ^a
Duodenum	0.00±0.22 ^b	1.75±0.22 ^a	0.00±0.14 ^b	1.33±0.14 ^a	0.00±0.00 ^b	1.00±0.00 ^a	0.00±0.00 ^a	0.00±0.00 ^a
Jejunum	0.00±0.18 ^b	1.75±0.18 ^a	0.00±0.21 ^b	2.17±0.21 ^a	0.00±0.00 ^b	1.00±0.00 ^a	0.00±0.00 ^a	0.00±0.00 ^a
Ileum	0.00±0.12 ^b	2.00±0.12 ^a	0.00±0.14 ^b	2.33±0.14 ^a	0.00±0.15 ^b	1.50±0.00 ^a	0.00±0.00 ^a	0.00±0.00 ^a
Caecum	0.00±0.27 ^b	2.17±0.27 ^a	0.00±0.11 ^b	1.83±0.11 ^a	0.00±0.14 ^b	1.33±0.14 ^a	0.00±0.00 ^a	0.00±0.00 ^a
Colon	0.00±0.15 ^b	1.42±0.15 ^a	0.00±0.21 ^b	1.83±0.21 ^a	0.00±0.11 ^b	1.17±0.11 ^a	0.00±0.00 ^a	0.00±0.00 ^a
Rectum	0.00±0.24 ^b	2.17±0.24 ^a	0.00±0.21 ^b	2.17±0.21 ^a	0.00±0.14 ^b	0.67±0.14 ^a	0.00±0.00 ^a	0.00±0.00 ^a
Trachea	0.00±0.15 ^b	0.50±0.15 ^a	0.00±0.17 ^b	1.00±0.17 ^a	0.00±0.14 ^b	0.33±0.14 ^a	0.00±0.00 ^a	0.00±0.00 ^a
Lung	0.00±0.00 ^b	3.00±0.00 ^a	0.00±0.00 ^b	3.00±0.00 ^a	0.00±0.15 ^b	1.50±0.15 ^a	0.00±0.25 ^b	1.00±0.25 ^a
Heart	0.00±0.15 ^b	1.58±0.15 ^a	0.00±0.22 ^b	1.67±0.22 ^a	0.00±0.11 ^b	1.17±0.11 ^a	0.00±0.00 ^a	0.00±0.00 ^a
Liver	0.00±0.15 ^b	2.50±0.15 ^a	0.00±0.15 ^b	2.50±0.15 ^a	0.00±0.00 ^b	1.00±0.00 ^a	0.00±0.00 ^a	0.00±0.00 ^a
Kidney	0.00±0.13 ^b	2.75±0.13 ^a	0.00±0.14 ^b	2.67±0.14 ^a	0.00±0.15 ^b	1.50±0.15 ^a	0.00±0.00 ^a	0.00±0.00 ^a

All values are expressed as mean±SE; ^{a,b}values with superscript within rows are significantly different at $p < 0.05$, SE=Standard error

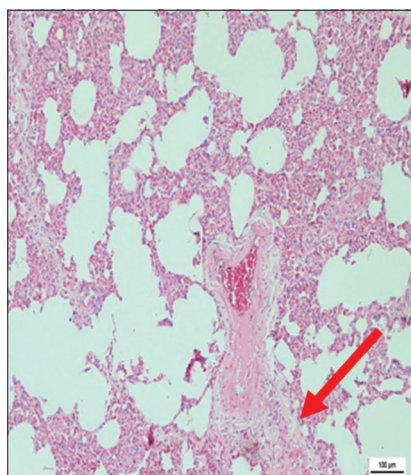


Figure-19: Micrograph of edema in the lung, H and E, ×200, (Group 3).

8-24 h after onset [11]. The disease is more susceptible in young animals ranging from 6 months to a year old [1,16]. Infected animals may be found with elevated temperature, submandibular edema, congested mucous membrane and respiratory distress with profuse nasal discharge [1,3,7]. In this study, all buffaloes were 8 months old where Groups 2 and 3 buffaloes showed typical HS signs such as pyrexia, submandibular edema, congested mucous membrane, nasal discharges and labored breathing. Group 3

buffaloes only showed mild clinical signs such as elevated temperature and serous nasal discharge. The differences in clinical signs can be explained through the route of inoculation. Experimentally, subcutaneous inoculation results in rapid onset and produced more consistent results compared to intranasal or oral route [2,18]. This was also supported by an experiment where orally inoculated buffaloes revealed milder clinical signs as compared to intra-tracheally infected buffaloes [14,15]. The subcutaneous group was only able to survive for 12 h before euthanasia due to recumbency and respiratory distress. However, the oral group was able to survive throughout the 21 days of the experiment.

Clinical pathology such as hematology and biochemistry is of great help to the clinician in arriving at a correct diagnosis, prognosis and efficacy of a treatment [19]. During a bacterial infection, hematological and biochemical changes are first detected during routine blood sampling. However, animal's defense mechanism can react quite differently, and there is no singular pattern in complete blood count that indicates a bacterial infection [20]. There were some hematological and biochemical markers that can be used for early detection in animals infected with wild Type of *P. multocida* [21,22]. Nevertheless, the blood results obtained comparing the subcutaneous and oral group infected buffaloes were documented

Table-4: Histopathological alterations in buffaloes after 21 days of oral inoculations of *Pasteurella multocida* Type B: 2.

Organs	Hemorrhage and congestion		Necrosis and degeneration		Inflammatory cell infiltration		Edema	
	Group 1	Group 3	Group 1	Group 3	Group 1	Group 3	Group 1	Group 3
Bone Marrow	0.00±0.13 ^a	0.25±0.13 ^a	0.00±0.08 ^b	0.92±0.08 ^a	0.00±0.08 ^a	0.08±0.08 ^a	0.00±0.00 ^a	0.00±0.00 ^a
Spleen	0.00±0.13 ^a	0.25±0.13 ^a	0.00±0.15 ^b	0.92±0.15 ^a	0.00±0.00 ^a	0.00±0.00 ^a	0.00±0.00 ^a	0.00±0.00 ^a
Submandibular lymph node	0.00±0.19 ^b	0.50±0.19 ^a	0.00±0.26 ^b	1.58±0.26 ^a	0.00±0.11 ^a	0.17±0.11 ^a	0.00±0.00 ^a	0.00±0.00 ^a
Prescapular lymph node	0.00±0.13 ^a	0.25±0.13 ^a	0.00±0.28 ^b	1.50±0.28 ^a	0.00±0.11 ^a	0.17±0.11 ^a	0.00±0.00 ^a	0.00±0.00 ^a
Femoral lymph node	0.00±0.15 ^b	0.50±0.15 ^a	0.00±0.17 ^b	1.83±0.17 ^a	0.00±0.19 ^b	0.50±0.19 ^a	0.00±0.00 ^a	0.00±0.00 ^a
Mesenteric lymph node	0.00±0.18 ^b	0.67±0.18 ^a	0.00±0.19 ^b	1.58±0.19 ^a	0.00±0.15 ^b	0.50±0.15 ^a	0.00±0.00 ^a	0.00±0.00 ^a
Tonsil	0.00±0.15 ^b	0.42±0.15 ^a	0.00±0.25 ^b	1.25±0.25 ^a	0.00±0.15 ^b	0.92±0.15 ^a	0.00±0.00 ^a	0.00±0.00 ^a
Esophagus	0.00±0.08 ^b	0.92±0.08 ^a	0.00±0.15 ^b	0.42±0.15 ^a	0.00±0.00 ^a	0.00±0.00 ^a	0.00±0.00 ^a	0.00±0.00 ^a
Rumen	0.00±0.14 ^b	0.67±0.14 ^a	0.00±0.15 ^b	0.50±0.15 ^a	0.00±0.13 ^a	0.25±0.13 ^a	0.00±0.00 ^a	0.00±0.00 ^a
Reticulum	0.00±0.15 ^b	0.58±0.15 ^a	0.00±0.22 ^b	0.67±0.22 ^a	0.00±0.13 ^a	0.25±0.13 ^a	0.00±0.00 ^a	0.00±0.00 ^a
Omasum	0.00±0.15 ^b	0.58±0.15 ^a	0.00±0.12 ^b	1.00±0.12 ^a	0.00±0.11 ^a	0.17±0.11 ^a	0.00±0.00 ^a	0.00±0.00 ^a
Abomasum	0.00±0.14 ^b	0.67±0.14 ^a	0.00±0.17 ^b	1.00±0.17 ^a	0.00±0.15 ^b	0.50±0.15 ^a	0.00±0.00 ^a	0.00±0.00 ^a
Duodenum	0.00±0.08 ^b	0.92±0.08 ^a	0.00±0.18 ^b	1.25±0.18 ^a	0.00±0.15 ^b	0.50±0.15 ^a	0.00±0.00 ^a	0.00±0.00 ^a
Jejunum	0.00±0.11 ^b	0.83±0.11 ^a	0.00±0.19 ^b	0.92±0.19 ^a	0.00±0.22 ^b	0.67±0.22 ^a	0.00±0.00 ^a	0.00±0.00 ^a
Ileum	0.00±0.00 ^b	1.00±0.00 ^a	0.00±0.21 ^b	1.00±0.21 ^a	0.00±0.11 ^b	0.83±0.11 ^a	0.00±0.00 ^a	0.00±0.00 ^a
Caecum	0.00±0.13 ^b	0.75±0.13 ^a	0.00±0.19 ^b	0.67±0.19 ^a	0.00±0.13 ^b	0.75±0.13 ^a	0.00±0.00 ^a	0.00±0.00 ^a
Colon	0.00±0.08 ^a	0.08±0.08 ^a	0.00±0.15 ^b	0.92±0.15 ^a	0.00±0.13 ^b	0.75±0.13 ^a	0.00±0.00 ^a	0.00±0.00 ^a
Rectum	0.00±0.15 ^b	0.58±0.15 ^a	0.00±0.18 ^b	0.75±0.18 ^a	0.00±0.08 ^b	0.92±0.08 ^a	0.00±0.00 ^a	0.00±0.00 ^a
Trachea	0.00±0.14 ^b	0.67±0.14 ^a	0.00±0.15 ^b	0.92±0.15 ^a	0.00±0.08 ^a	0.08±0.08 ^a	0.00±0.00 ^a	0.00±0.00 ^a
Lung	0.00±0.17 ^b	2.17±0.17 ^a	0.00±0.15 ^b	2.50±0.15 ^a	0.00±0.17 ^b	1.17±0.17 ^a	0.00±0.20 ^b	0.89±0.20 ^a
Heart	0.00±0.15 ^b	1.58±0.15 ^a	0.00±0.12 ^b	2.00±0.12 ^a	0.00±0.08 ^b	0.92±0.08 ^a	0.00±0.00 ^a	0.00±0.00 ^a
Liver	0.00±0.13 ^b	1.25±0.13 ^a	0.00±0.14 ^b	1.33±0.14 ^a	0.00±0.13 ^b	1.25±0.13 ^a	0.00±0.00 ^a	0.00±0.00 ^a
Kidney	0.00±0.19 ^b	1.42±0.19 ^a	0.00±0.19 ^b	1.08±0.19 ^a	0.00±0.13 ^b	0.75±0.13 ^a	0.00±0.00 ^a	0.00±0.00 ^a

All values are expressed as mean±SE; ^{a,b}values with superscript within rows are significantly different at $p < 0.05$, SE=Standard error

for the first time. Buffaloes infected subcutaneously were having erythrocytosis and leukopenia, however; buffaloes infected orally were having leukocytosis throughout the experiment. It is common for cattle with acute bacterial infections such as the subcutaneous group to have neutropenia because of the small storage pool of segmented neutrophils in the bone marrow [22]. Severe inflammation due to the bacteria endotoxin also contributes to neutropenia due to neutrophil migration and emigration into inflamed tissue exceed the release of neutrophil from the bone marrow [23]. However, within days, neutrophil production and release may result in neutrophilia, which was observed in the oral group. On the other hand, the result of this study revealed significant increase in red blood cells in the subcutaneous group. This is not consistent with findings who concluded that inflammation is able to reduce red blood count leading to anemia [24]. This can be due to dehydration and shock that occurred in buffaloes infected subcutaneously as HS is an acute and hemorrhagic disease.

Histopathology focuses on the interrelationship and integration of molecular and physiological activities within the body [25]. The earliest report on the histopathological changes in HS was done experimentally in bison calf using B2 strain. In the present study, subcutaneous and oral group buffaloes had different post mortem and histopathology findings [17]. Grossly subcutaneous group showed generalized congestion,

hyperemia and hemorrhage in the vital organs, gastrointestinal organs, and immune organs. These findings were consistent with previous HS report and experimental findings [1,2,7,16,17,19,26-29]. In contrast, orally infected group only had mild lesions in the lung and liver. These findings were supported by previous experiments, who stated that buffalo calves inoculated orally showed milder lesions compared to other route of infections [2,14,15]. The lesions such as hemorrhage, edema, and white blood cells infiltration were observed in the lung, lymph nodes, spleen, gastro-intestinal tract, liver, kidney and the heart [27]. Nevertheless, in our study, orally infected group was showing milder histopathological lesions compared to the subcutaneous group. Histological lesions of orally infected group were milder compared to other infected group, which is not a typical sign in HS infected animals [14,15]. Oral route may not play a major role in the development of HS but they carried *P. multocida* organism in the gastrointestinal organs, which may act as carrier animal [14,15].

In summary, this study compared the clinical responses, hematology and biochemistry alterations, post mortem changes, and cellular changes in tissues of buffaloes challenged with *P. multocida* Type B:2 via subcutaneous and oral routes. There were no studies were reported previously to observe the differences in buffaloes response using these two routes of infections. In this study, both treatment groups showed

significant clinical responses. The subcutaneous group showed severe clinical signs and were in agreement with previous studies [14,15,28,29] and all the buffaloes in this group were euthanized within 7 days of post-infection. The novelty of this study was the oral group where the buffaloes in this treatment group survived although these buffaloes exhibit mild clinical signs. The buffaloes in this group survived throughout the stipulated experimental period of 21 days. The data on hematology and biochemistry responses in these two different groups were documented for the first time and there were no previous literatures on these responses. Moreover, the cellular changes in immune organs of subcutaneous and oral groups were added knowledge in HS studies in buffaloes. From this study, we may conclude that oral route infection of *P. multocida* Type B:2 in buffaloes may stimulate the host cell responses. More studies is needed if there is possibilities of oral vaccine through feed that may be developed in future where vaccine administration via feed may increase the coverage of vaccination percentage although oil adjuvant vaccines have been used routinely to control HS, outbreaks among vaccinated animals are not uncommon due to the difficulty of vaccine administration [4,30].

Conclusions

There were changes in clinical signs, blood parameters, post mortem and histopathology following experimental-infection with *P. multocida* Type B:2 via oral route of exposure. This route of infection could lead to mild clinical responses, alteration in hematology and biochemistry, gross lesions in the lung and liver with mild to moderate histopathology modifications.

Authors' Contributions

FFJA, MZS, AWH, AAS, MAML, ARO, and MZAB conceptualized and supervised the research. ELTC, LA, ADM, HHI and MJN collected samples, drafted and revised the manuscript and done statistical analysis. All authors have read and approved the manuscript.

Acknowledgments

The authors would like to thank the staff of the Department of Veterinary Clinical Studies, Universiti Putra Malaysia in particular Mr Yap Keng Chee, and Mr Ganesanmurthi Perumal. The project was funded by Ministry of Higher Education, Malaysia (Grant no: 5524417).

Competing Interests

The authors declare that they have no competing interests.

References

- De Alwis, M.C.L. (1992) Haemorrhagic septicaemia – A general review. *Br. Vet. J.*, 148: 99-112.
- De Alwis, M.C.L. (1999) Haemorrhagic Septicaemia,

- Australian Centre for International Agriculture Research (ACIAR) Monograph 57. ACIAR, Canberra, Australia.
- OIE. (2008) Haemorrhagic septicaemia. OIE Terrestrial Manual. Ch. 2. OIE, United Kingdom. p739-751.
- Zamri-Saad, M. (2013) Haemorrhagic Septicaemia of Cattle & Buffaloes in Asia. Selangor: Universiti Putra Malaysia Press.
- Heddleston, K.L., Gallagher, J.E. and Rebers, P.A. (1972) Fowl cholera: Gel diffusion precipitin test for serotyping *Pasteurella multocida* from avian species. *Am. Assoc. Avian Pathol.*, 14(4): 925-936.
- Carter, G.R. (1962) Further observation on typing *Pasteurella multocida* by the indirect hemagglutination test. *Can. J. Comp. Med. Vet. Sci.*, 26: 238-240.
- DeAlwis, M.C.L. (1981) Mortality among cattle and buffaloes in Sri Lanka due to Haemorrhagic septicaemia. *Trop. Anim. Health Prod.*, 13: 195-202.
- Farooq, U., Saeed, Z., Khan, M.A., Ali, I. and Qamar, M.F. (2011) Sero-surveillance of haemorrhagic septicaemia in buffaloes and cattle in Southern Punjab, Pakistan. *Pak. Vet. J.*, 31(3): 254-256.
- Thomas, J. (1972) The control of haemorrhagic septicaemia in west Malaysia. *Trop. Anim. Health Prod.*, 4: 95-101.
- Saharee, A.A., Salim, N.B., Rasedee, A. and Jainudeen, M.R. (1993) Haemorrhagic septicaemia carriers among cattle and buffalo in Malaysia. *Pasteurellosis in Production Animals*. ACIAR Proceeding No. 43. p89-91.
- Kahn, C.M. and Line, S. (2005) The Merck Veterinary Manual. 9th ed. Merial, USA.
- Jesse, F.F.A., Khaleel, M.M., Adamu, L., Osman, A.Y., Wahid, A., Zamri-saad, M. and Rahman, A. (2013) Polymerase chain reaction detection of *Pasteurella multocida* Type B2 in mice infected with contaminated river water. *Am. J. Vet. Res.*, 8(3): 146-151.
- Ali, O.S., Adamu, L., Abdullah, F.F.J., Ilyasu, Y., Abba, Y., Hamzah, H.B., Mohd-Azmi, M.L., Haron, A.W.B. and Saad, M.Z.B. (2014) Alterations in interleukin-1 β and interleukin-6 in mice inoculated through the oral routes using graded doses of *P. Multocida* Type B: 2 and its lipopolysaccharide. *Am. J. Vet. Res.*, 9(4): 177-184.
- Abubakar, M.S. and Zamri-saad, M. (2011) Clinicopathological changes in buffalo calves following oral exposure to *Pasteurella multocida* B2. *Basic Appl. Pathol.*, 4: 130-135.
- Abubakar, M.S., Zamri-saad, M. and Jasni, S. (2012) Ultrastructural changes and bacterial localization in buffalo calves following oral exposure to *Pasteurella multocida* B: 2. *Pak. Vet. J.*, 33(1): 101-106.
- Lane, E.P., Kock, N.D., Hill, F.W.G. and Mohan, K. (1992) An outbreak of haemorrhagic septicaemia in cattle in Zimbabwe. *Trop. Anim. Health Prod.*, 24: 97-102.
- Rhoades, K.R., Heddleston, K.L. and Rebers, P.A. (1967) Experimental haemorrhagic septicaemia: Gross and microscopic lesions resulting from acute infections and from endotoxin administration. *Can. J. Comp. Med.*, 31: 226-233.
- Zamri-Saad, M., Azri, A. and Sheikh-Omar, A.R. (1994) Experimental respiratory infection of goats with *Mycoplasma argini* and *Pasteurella haemolytica* A: 2. *Pertanika J. Trop. Agric. Sci.*, 17(3): 239-242.
- Sastry, G.A. (2006) Veterinary Clinical Pathology. CBS Publishers & Distributors, New Delhi.
- Weiss, D.J. and Wardrop, K.J. (2010) Schalm's Veterinary Hematology. 6th ed. Wiley-Blackwell, Iowa.
- Jesse, F.F.A., Adamu, L., Osman, A.Y., Wahid, A., Saharee, A.A., Abdullah, R., Zamri-saad, M. and Zakaria, Z. (2013) Biochemical and haematological alterations in mice inoculated with outer membrane protein, lipopolysaccharides and whole cells of *Pasteurella multocida* type B2. *Am. J. Vet. Res.*, 8(3): 152-158.
- Jesse, F.F.A., Osman, A.Y., Adamu, L., Zakaria, Z., Abdullah, R., Zamri-saad, M. and Saharee, A.A. (2013) Haematological and biochemical alterations in calves

- following infection with *Pasteurella multocida* type B: 2, bacterial lipopolysaccharide and outer membrane protein immunogens. *Asian J. Anim. Vet. Adv.*, 8(6): 806-813.
23. Steven, L.S. (2000) Hematologic changes due to bacterial infections. In: Schalm's Veterinary Hematology. 5th ed. Lippincott Williams and Wilkins, USA.
24. Praveena, P.E., Periasamy, S., Kumar, A.A. and Singh, N. (2010) Cytokines profiles, apoptosis and pathology of experimental *Pasteurella multocida* serotype A1 infection in mice. *Res. Vet. Sci.*, 89: 332-339.
25. Samuelson, D.A. (2007) Textbook of Veterinary Histology. Saunders Elsevier, Missouri.
26. Jesse, F.F.A., Affandi, S.A., Osman, A.Y., Adamu, L., Zamri-saad, M., Wahid, A., Rahman, A., Sabri, J. and Saharee, A.A. (2013) Clinico-pathological features in mice following oral exposure to *Pasteurella multocida* B: 2. *IOSR J. Agric. Vet. Sci.*, 3(4): 35-39.
27. Jesse, F.F.A., Adamu, L., Osman, A.Y., Zakaria, Z., Abdullah, R., Zamri-saad, M. and Saharee, A.A. (2013) Clinico-pathological responses of calves associated with infection of *Pasteurella multocida* type B: 2 and the bacterial lipopolysaccharide and outer membrane protein immunogens. *Int. J. Anim. Vet. Adv.*, 5(5): 190-198.
28. Annas, S., Zamri-Saad, M., Jesse, F.F.A. and Zunita, Z. (2014) New sites of localisation of *Pasteurella multocida* B: 2 in buffalo surviving experimental Haemorrhagic septicaemia. *BMC Vet. Res.*, 10(88): 1-7.
29. Annas, S., Zamri-Saad, M., Abubakar, M.S., Jesse, F.F.A. and Zunita, Z. (2014) Distribution of *Pasteurella multocida* B: 2 in the respiratory, gastrointestinal and urinary tracts of buffaloes following experimental subcutaneous inoculation. *J. Vet. Sci. Technol.*, 5(3): 1-6.
30. Rafidah, O. and Zamri-saad, M. (2013) Effect of dexamethasone on protective efficacy of live gdh A derivative *Pasteurella multocida* B: 2 vaccine. *Asian J. Anim. Vet. Adv.*, 8(3): 548-554.
