

Received: 2021.02.24

Accepted: 2021.09.19


Available online: 2021.10.07

Published: 2021.11.05

A 39-Year-Old Woman with Cervicofacial and Mediastinal Emphysema 10 Hours After an Elective Lower Molar Dental Extraction

Authors' Contribution:

Study Design A
Data Collection B
Statistical Analysis C
Data Interpretation D
Manuscript Preparation E
Literature Search F
Funds Collection G

ABCDEF 1 **Jakub B. Nożewski**
CDE 2 **Marta L. Dura**
AEF 3 **Maria Kłopocka** 
ABD 1 **Maja M. Kwiatkowska**
AD 1 **Jakub P. Konieczny**
DEF 4 **Klara K. Nicpoń-Nożewska**

1 Emergency Department, Collegium Medicum, Nicolaus Copernicus University, Bydgoszcz, Poland
2 Department of Radiology, Jan Bizioł University Hospital No. 2 in Bydgoszcz; Collegium Medicum, Nicolaus Copernicus University, Bydgoszcz, Poland
3 Department of Gastroenterology, Collegium Medicum, Nicolaus Copernicus University, Bydgoszcz, Poland
4 Department and Clinic of Geriatrics, Collegium Medicum, Nicolaus Copernicus University, Bydgoszcz, Poland

Corresponding Author: Jakub B. Nożewski, e-mail: jbnoz@wp.pl
Financial support: None declared
Conflict of interest: None declared

Patient: Female, 39-year-old
Final Diagnosis: Pneumomediastinum
Symptoms: Chest discomfort • dyspnea • oedema of the face
Medication: —
Clinical Procedure: Antibiotics • CT scan
Specialty: Critical Care Medicine





Objective: Rare disease
Background: Mediastinal emphysema, also called pneumomediastinum, is a very infrequent condition in patients reporting to an Emergency Department. Mediastinal emphysema is the pathologic presence of free air enclosing the mediastinal structures. In the case of chest pain in a young healthy adult, pneumomediastinum as a differential diagnosis will undoubtedly be omitted. This would be especially likely if the symptoms are not preceded by an injury, intense vomiting, or an infection in this area.

Case Report: We present a case in which a previously healthy 39-year-old woman experienced painless progressive face and neck swelling, dyspnea, and retrosternal pain several hours after a dental procedure. Physical examination revealed crackles on palpation of the skin on the right part of the face, neck, and chest. Neck and chest computed tomography confirmed subcutaneous neck and upper chest emphysema and pneumomediastinum. The patient was transferred to the thoracic surgery ward. After 2 days of prophylactic intravenous administration of antibiotics, she was discharged for further scheduled treatment at the Maxillofacial Surgery Clinic.

Conclusions: This report presented a rare case of a woman who reported to the Emergency Department with subcutaneous and mediastinal emphysema following routine molar dental extraction. Emergency Department physicians should be aware of the possibility of delayed complications after standard dental procedures. A detailed medical history and clinical examination will enable making a correct diagnosis so as not to jeopardize the health of a patient, and in the case of the development of mediastinitis, even the patient's life.

Keywords: Dyspnea • Mediastinal Emphysema • Tooth Extraction

Full-text PDF: <https://www.amjcaserep.com/abstract/index/idArt/931793>

 2174  —  2  23



Background

Mediastinal emphysema, also known as pneumomediastinum (PM), is the pathologic presence of free air enclosing mediastinal structures [1]. PM is usually divided into 2 types: spontaneous and secondary. Spontaneous PM has some well-known triggers, such as asthma, coughing, sneezing, Valsalva maneuver, vomiting, intense exercise, and playing a wind instrument [2]. Secondary mediastinal emphysema is associated with trauma and iatrogenic injury [3]. Mediastinal emphysema after a dental procedure is a rare iatrogenic condition despite several million people receiving dental care every day worldwide. Among cases of PM after dental extraction, 90% occur within 60 min of the procedure, but in some cases symptoms appear a week after extraction [4]. Based on a search of PubMed, 37 cases of PM after a dental procedure have been reported in the literature since 1973, but the real number of cases found worldwide seems to be greatly underestimated. Although treatment in most cases requires only several hours of observation and prophylactic administration of antibiotics [1], lack of knowledge about the complication after dental intervention may lead to pericarditis, sepsis, and multiple-organ failure [5]. In 2011, Romeo et al [6] reported a case in which a 25-year-old woman underwent a scheduled third-molar extraction. During the procedure, massive swelling of the right side of her face occurred, including her right eye socket. The patient felt no pain, but only a sensation of fullness in her face. She could not open her eye on her right side. The procedure was completed, and sutures and a dressing were placed in the empty tooth socket. The patient received steroids and an antibiotic intravenously, and after 2 h of observation, she was discharged with a recommendation for follow-up in 7 days. The patient continued antibiotics for 5 days and was advised to use painkillers as needed. After 7 days, her symptoms were resolved. She had no signs of emphysema, and she could open her eyes easily and symmetrically. No local or systemic infection occurred. In 2017, Akra and Yousif [7] reported a comparable case in a much older patient. A 72-year-old woman made an appointment with the dentist after a few days of toothache. During tooth extraction, sudden right facial swelling developed, and the patient was transferred to the nearest Emergency Department (ED) because of a rapid increase in the swelling. After primary examination, she was sent home with a review appointment scheduled for the next day. The swelling decreased overnight, but the patient reported some odynophagia without respiratory difficulties. She was observed in the ED and discharged after 24 h. In 14 days, the swelling and crepitus resolved completely. Another interesting case was described by Chen et al [1] in 1999. A 32-year-old woman underwent a scheduled removal of the third molar. Six hours after the procedure, she developed swelling of the right side of her face and neck. The patient contacted the doctor who performed the procedure. The dentist recognized

the procedure-related edema and sent the patient home with anti-inflammatory drugs. The next day, the patient reported to the ED due to a significant progression of symptoms. Neck X-ray and chest computed tomography (CT) were performed. Bronchoscopy and upper gastrointestinal tract contrast examinations showed no signs of a bronchial tear or contrast medium extravasation. Her radiographic symptoms resolved within 2 weeks with conservative treatment.

The current report involves a 39-year-old woman who developed cervicofacial and mediastinal emphysema 10 h after elective extraction of her right lower second molar. This case is an important review of the management and possible differential diagnosis of such cases, especially for ED physicians without prior dental experience.

Case Report

A 39-year-old woman presented at the ED owing to tightness in the chest and a feeling of “bubble wrap” under the skin of the neck and breastbone of several hours’ duration. Ten hours before admission, she had a planned extraction of her lower right second molar. During the dental procedure, when the dentist used an air syringe, the patient felt that air got into the gingival tissue and she experienced swelling in the right side of her face. Neither the dentist nor her assistant had seen a similar case previously, and they recommended that the patient should return home and rest. Because the patient lived in the city center close to the hospital, she was advised to go to the ED if her status did not improve in a few hours. In the ED she was triaged as urgent (yellow) according to the Manchester Triage Scale. Her temperature was normal, respiration was 16 breaths/min, oxygen saturation was 99% in air, blood pressure was 140/69 mmHg, and pulse rate was 100 beats/min. She had no history of chronic diseases, anaphylaxis, or drug use. She did not smoke, and she drank alcohol only occasionally (2-3 times a year). She denied trauma or vomiting. Physical examination showed no puffiness or open wounds within oral cavity, especially around the extracted tooth socket. Her mouth opening was normal. The trachea was midline, and she phonated normally.

Subcutaneous emphysema with crepitation upon palpation of the right buccal, submandibular, and anterior triangle of the neck and a limited area of the right subclavian were found. Crunching was heard in the fourth and fifth intercostal space along the left sternal edge (positive Hamman sign). The maxillofacial surgeon on duty was consulted about the patient’s symptoms, and he stated that they could not be related to the tooth extraction. Neck and chest CT was done to determine the origin of the subcutaneous air collection. Results revealed bilateral edema of the soft tissue of the maxilla, mandible, and

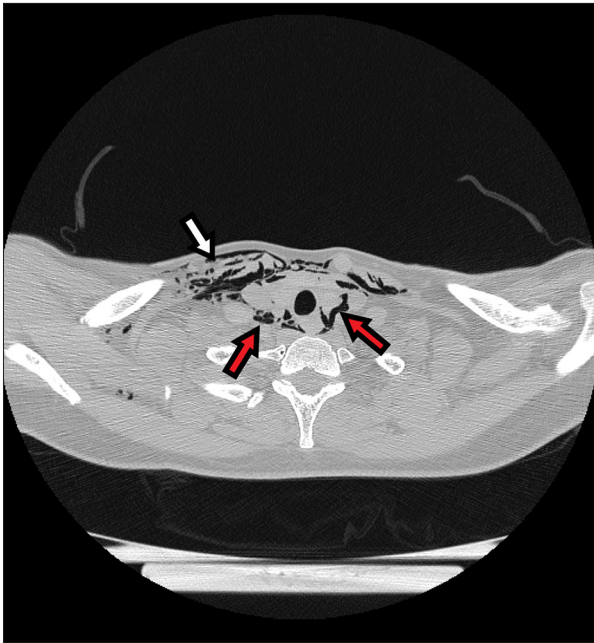

Figure 1. Computed tomographic axial view of the emphysema in the chest wall (white arrows) and in the mediastinum, outlining the vessels and thyroid (red arrows).

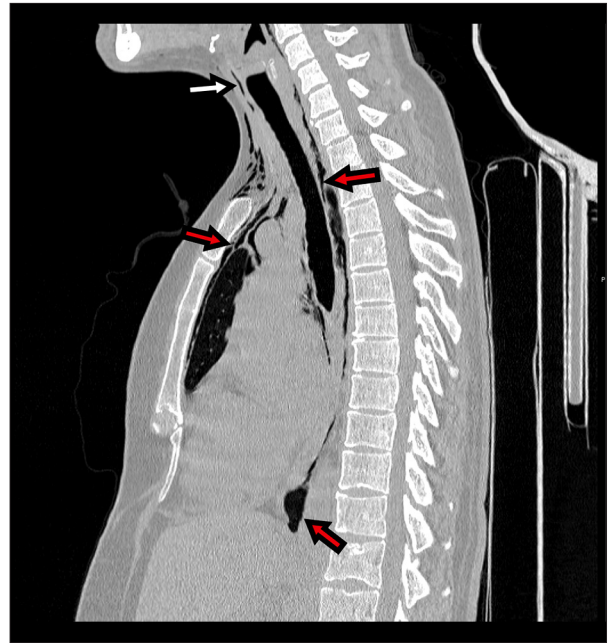


Figure 2. Sagittal neck and chest computed tomography scan demonstrates free air in the subcutaneous tissue of the chest and neck (white arrows) and gas surrounding the vessels, esophagus, trachea, and posterior pericardium (red arrows).

neck, with greater intensity on the right side, and free air surrounding the thyroid, vessels, esophagus, trachea, and posterior pericardium (Figures 1, 2). The emphysema passed to the anterolateral chest wall and was present in the mediastinum. After telephone consultation, the patient was transferred to the Thoracic Surgery Department of a voivodeship (province) lung disease center for observation. The patient was discharged from the Thoracic Surgery Department after 2 days of prophylactic broad-spectrum antibiotic therapy for low inflammatory markers and relief of dyspnea. She remained at home for the next few days, and all symptoms resolved within 10 days. Currently, the patient has no symptoms and is waiting for an appointment at the Maxillofacial Surgery Clinic for further dental treatment.

Discussion

This case highlights a rare complication of dental procedures. Among emergency medicine doctors, nontraumatic subcutaneous emphysema is not a well-known pathology. The present case alerts clinicians to the diagnosis, introduces differential recognition, indicates the necessary diagnostics, and presents the best possible management to avoid unnecessary tests and thus reduce the cost of hospitalization. Mediastinal emphysema, or PM, is defined as the pathologic presence of free air around mediastinal structures. The word emphysema comes from the

Greek word *empysan*, which means “to puff.” It usually occurs after blunt, penetrating trauma or barotrauma that leads to a sudden increase in alveolar pressure and the destruction of the airtightness of the tracheobronchial system or digestive track [8]. It can also arise as a result of cancerous or infectious lesions. Mediastinal emphysema can also occur spontaneously after minor activities such as coughing, vomiting, weightlifting, and shouting [9]. In addition, it can be caused by many common in-hospital procedures, such as intubation, bronchoscopy, gastroscopy, improper central venous placement, and mechanical ventilation [1,3]. The pathomechanism of mediastinal emphysema was first described in 1944 [10]. The putative course of air entry in patients after tooth extraction is beneath the mucosa near the tonsillar fossa and the superior pharyngeal constrictor muscle, to the retropharyngeal space, and then down the carotid sheaths [11]. The most common symptoms reported by patients include dyspnea, cough, puffy face, subcutaneous emphysema, and retrosternal and back pain [12]. On physical examination, the Hamman sign can be detected [13] and is present in about half of the cases of mediastinal emphysema or left pneumothorax [14]. In the vast majority of cases, a clicking sound occurs during systole. The pathophysiology of the Hamman sign remains unclear [15]. Nonspecific ST-T changes can be seen on electrocardiograms in mediastinal emphysema, although there is no characteristic pattern [16,17]. To confirm the diagnosis of mediastinal emphysema, CT has become the criterion standard. A chest X-ray may not show changes in

5-33% of cases [18]. If there is no access to CT, a lateral thoracic projection is additionally performed to increase the probability of making a correct diagnosis. Linear lucencies surrounding the mediastinum will be visible in chest radiography. To date, many radiological signs of PM have been described in the literature, including ring-around artery sign, tubular artery sign, double bronchial wall sign, continuous diaphragm sign, Neclario V sign, and in children, Haystack sign [19,20]. The first case report of subcutaneous emphysema after a dental procedure was described in 1900 [4]. Since then, cases of mediastinal emphysema have been described following various dental procedures, from standard hygiene procedures using air-driven dental handpieces to endodontic treatment [7]. Air-driven handpieces are a very well-known cause of subcutaneous emphysema. In the analyzed medical records of 32 cases of subcutaneous pneumothorax after dental procedures, half were caused by air-driven handpieces [6].

In the case reported by Romeo et al [6], the symptoms occurred with a planned extraction of a molar on the right side and appeared during procedure, the same as in our patient. However, in the case described by Romeo et al [6], the maxillofacial surgeon was aware of the possibility of the complication. After initial observation, he sent the patient home, which highlights the need to publish cases to raise awareness of the risk. The maxillofacial surgeon on duty in our unit, despite nearly 20 years of work experience, had never encountered a similar case. Akra and Yousif [7] described a similar case in a patient who was more than twice as old as our patient. Their patient was sent home after the initial examination, but when odynophagia appeared, she presented again. CT was performed due to suspicion of a small esophageal disruption. The radiologist recommended endoscopy, but the emergency physician, in consultation with the maxillofacial surgeon, refrained from performing the procedure owing to the lack of obvious symptoms of esophageal perforation. After observation in the ED, the patient was discharged. Chen et al [1] reported a comparable case, but the misdiagnosis was made by the dentist who was performing the procedure. In contrast, our patient developed symptoms several hours after surgery. Due to the lack of awareness of PM occurrence after dental surgery, unnecessary procedures were performed, including bronchoscopy and a CT examination of the upper gastrointestinal with contrast.

Most cases of mediastinal emphysema that occur after a dental procedure are probably not reported because patients do not experience dyspnea or any severe pain, and symptoms resolve without any treatment after a few days. A differential diagnosis of a sudden onset of facial swelling and shortness of

breathing during a dentist appointment first raises the suspicion of anaphylaxis, angioedema, hematoma, or cellulitis [21]. Initial management is to immediately stop the procedure that is causing the edema. In most cases, mediastinal emphysema is mild and requires only 24-h observation in the ED, oxygen supplementation, and administration of analgesics. Oxygen supplementation (100%) is used to hasten the absorption of free air. Some authors suggest using steroids to decrease edema, but this approach is very controversial. In view of the risk of fatal infection, the potential benefits of reducing edema are clearly not justifiable [22]. Owing to the risk of infection during the course of PM after dental procedures and the high risk of mortality in case of full-blown mediastinitis, prophylactic broad-spectrum antibiotics should be administered routinely. Due to the typical buccal flora, penicillin and metronidazole remain the drugs of choice in most of the described cases [23]. All patients should be advised to avoid actions that could further increase intraoral pressure.

The course of mediastinal emphysema depends on the amount of air collected in mediastinum [13]. The prognosis of PM is not always mild; for example, mediastinitis is a life-threatening condition with very high mortality. Another serious complication can be tension PM, also called malignant PM, in which a clinical image resembling cardiac tamponade evolves due to air accumulated in the mediastinum. Management of mediastinal emphysema is usually conservative, and most cases resolve within 3-5 days of rest at home.

Conclusions

This report presented a rare case in which a healthy woman presented to the ED with subcutaneous and mediastinal emphysema following routine molar dental extraction. Physicians working in EDs should consider the possibility that PM has developed in all cases of unexplained chest pain after a dental procedure. It is necessary to keep in mind that patients may not associate a dental appointment with the onset of chest pain. Negligently collected medical history may hinder reaching a correct diagnosis, especially when the patient denies the occurrence of trauma, lung diseases, or vomiting (ie, the typical causes of PM).

Declaration of Figures' Authenticity

All figures submitted have been created by the authors who confirm that the images are original with no duplication and have not been previously published in whole or in part.

References:

1. Chen SC, Lin FY, Chang KJ. Subcutaneous emphysema and pneumomediastinum after dental extraction. *Am J Emerg Med.* 1999;17(7):678-80
2. Gupta A, Rizvi I, Srivastava VK, et al. Spontaneous pneumomediastinum. *Med J Armed Forces India.* 2015;71(Suppl. 1):S85-88
3. Sapmaz E, Işık H, Doğan D, et al. A comparative study of pneumomediastinums based on clinical experience. *Ulus Travma Acil Cerrahi Derg.* 2019;25(5):497-502
4. Ocakcioglu I, Koyuncu S, Kupeli M, Bol O. Pneumomediastinum after tooth extraction. *Case Rep Surg.* 2016;2016:4769180
5. de Figueiredo EL, Aires CCG, Neres BJCM, et al. Persistent necrotizing mediastinitis after dental extraction. *Case Rep Dent.* 2019;2019:6468348
6. Romeo U, Galanakis A, Lerario F, et al. Subcutaneous emphysema during third molar surgery: A case report. *Braz Dent J.* 2011;22:83-86
7. Akra GA, Yousif K. Cervicofacial and mediastinal emphysema complicating tooth extraction in an elderly patient: A preventable complication. *BMJ Case Rep.* 2017;2017:bcr2017219245
8. Agustín M, David G, Kang JY, et al. Spontaneous pneumomediastinum and diffuse subcutaneous emphysema after methamphetamine inhalation. *Case Rep Pulmonol.* 2020;2020:7538748
9. Banki F, Estrera AL, Harrison RG, et al. Pneumomediastinum: Etiology and a guide to diagnosis and treatment. *Am J Surg.* 2013;206(6):1001-6; discussion 1006
10. Murayama S, Gibo S. Spontaneous pneumomediastinum and Macklin effect: Overview and appearance on computed tomography. *World J Radiol.* 2014;6(11):850-54
11. Clancy DJ, Lane AS, Flynn PW, et al. Tension pneumomediastinum: A literal form of chest tightness. *J Intensive Care Soc.* 2017;18(1):52-56
12. Thompson C, Gohil R. Pneumatic dental extractions: An unusual cause of extensive cervical surgical emphysema. *BMJ Case Rep.* 2017;2017:bcr2016218677
13. Kouritas VK, Papagiannopoulos K, Lazaridis G, et al. Pneumomediastinum. *J Thorac Dis.* 2015;7(Suppl. 1):S44-49
14. Guataqui AEC, Muniz BC, Ribeiro BNF, et al. Hamman's syndrome accompanied by pneumorrhachis. *Radiol Bras.* 2019;52(1):64-65
15. Jimidar N, Lauwers P, Govaerts E, Claeys M. The clicking chest: what exactly did Hamman hear? A case report of a left-sided pneumothorax. *Eur Heart J Case Rep.* 2020;4(6):1-5
16. Tsuchiya K, Sagisaka S, Suda T. Mediastinal emphysema with electrocardiogram abnormality. *Intern Med.* 2020;59(14):1783-84
17. Lolay GA, Burchett A, Ziada KM. Pneumomediastinum and ST-segment elevation. *Am J Cardiol.* 2016;118(10):1603-4
18. Dirweesh A, Alvarez C, Khan M, et al. Spontaneous pneumomediastinum in a healthy young female: A case report and literature review. *Respir Med Case Rep.* 2017;20:129-32
19. Komaru Y, Maeda A. Naclerio's V sign and continuous diaphragm sign after endoscopy. *BMJ Case Rep.* 2018;2018:bcr2018226021
20. Agarwal PP. The ring-around-the-artery sign. *Radiology.* 2006;241(3):943-44
21. Aslaner MA, Kasap GN, Demir C, Akkaş M, Aksu NM. Occurrence of pneumomediastinum due to dental procedures. *Am J Emerg Med.* 2015;33(1):125.e1-3
22. Wong P, Palacios S, Kashtwari D. Managing subcutaneous emphysema following dental procedures. *Decisions in Dentistry.* 2017 Aug 025. <https://decisionsindentistry.com/article/managing-subcutaneous-emphysema-following-dental-procedures/>
23. Ebina M, Inoue A, Takaba A, Ariyoshi K. Management of spontaneous pneumomediastinum: Are hospitalization and prophylactic antibiotics needed? *Am J Emerg Med.* 2017;35(8):1150-53