

Multiple Recurrences in Aggressive Forms of Dupuytren's Disease—Can Patients Benefit from Repeated Selective Fasciectomy?

Sören Könniker, MD*
 G. Felix Broelsch, MD*
 Nicco Krezdorn, MD*
 Khaled Dastagir, MD*
 Jörn W. Kubbier, MD*
 Felix J. Paprottka, MD†
 Peter M. Vogt, MD*

Background: In Dupuytren's disease (DD), limited fasciectomy is the mainstay of surgical therapy in patients at risk of contractures and disease recurrences. New minimally invasive treatments such as injection of collagenase *clostridium histolyticum* have evolved as a common tool for the preliminary treatment of Dupuytren's contractures. However, recurrences and their therapy remain controversial. In this study, we evaluate the benefit of repeated limited fasciectomy in patients with aggressive forms of the disease and multiple recurrences of contractures.

Methods: We evaluated the outcome of 16 patients undergoing limited fasciectomy 3 or more times on a single hand.

Results: Postoperatively, 10 of 13 (76.9%) patients were satisfied with the clinical result after the last operation; 10 of 12 (83.3%) patients would choose to have their surgery repeated, if so needed. The mean improvement of proximal interphalangeal joint range of motion was 59.2 degrees (SD 26.8) and 86.2% (SD 19.9). There were no severe complications after treatment within the observed time period.

Conclusions: Our findings demonstrate that patients with recurrence of contractures after multiple previous treatments in aggressive forms of DD can benefit from surgical intervention. In conclusion, repeated limited fasciectomy remains indicated in patients after previous surgeries with DD. (*Plast Reconstr Surg Glob Open* 2017;5:e-1247; doi: 10.1097/GOX.0000000000001247; Published online 23 February 2017.)

INTRODUCTION

Dupuytren's disease (DD) is a hyperproliferative disorder of cellular and connective tissue of the palmar aponeurosis. Its prevalence rates vary from 3% in the US population to 56% of upper age groups in specific European regions.¹

*From the *Department of Plastic, Aesthetic, Hand and Reconstructive Surgery, Hannover Medical School, Hannover, Germany; and †Department of Plastic, Aesthetic and Reconstructive Surgery, Hand Surgery, AGAPLESION Diakonieklinikum Rotenburg, Rotenburg (Wümme), Germany.*

Received for publication September 15, 2016; accepted January 4, 2017.

Drs. Könniker and Broelsch contributed equally to this work.

Presented in part at the 2013 Annual Meeting of the German Society of Hand Surgery, in Düsseldorf, Germany, October 10–13, 2013 and in part at the 2014 Annual Meeting of the German Society of Surgery, in Berlin, Germany, March 25–28, 2014.

None of the authors has a financial interest in any of the products, devices, or drugs mentioned in this article.

Copyright © 2017 The Authors. Published by Wolters Kluwer Health, Inc. on behalf of The American Society of Plastic Surgeons. This is an open-access article distributed under the terms of the Creative Commons Attribution-Non Commercial-No Derivatives License 4.0 (CCBY-NC-ND), where it is permissible to download and share the work provided it is properly cited. The work cannot be changed in any way or used commercially without permission from the journal.

DOI: 10.1097/GOX.0000000000001247

About 200 years after the first description of digitopalmar contractures by Guillaume Dupuytren, the etiology of DD is still widely unknown.² Latest research suggests a greater focus on genetics^{3,4} and molecular biology.^{2,5,6} Hindocha et al.⁷ described 5 statistical risk factors for recurrence of the disease after treatment: family history, bilateral occurrence, ectopic lesions, male sex, and age of onset ≤ 50 years. According to the literature, surgery is the most widely accepted option to treat contractures in DD.^{8–11} Without treatment, DD can lead to severe flexion contraction at the MCP or PIP joints and cause functional loss of the hand. DD is still a predominant reason for elective finger amputation.¹² However, treatment options of DD are changing dramatically toward minimally invasive treatments, for example, injection of collagenase *clostridium histolyticum*, which are becoming more and more common especially in early stages of the disease. Consequently, the benefit of open surgery in Dupuytren treatment is being challenged medically and socioeconomically.^{13–18}

With open surgery, there is a lower risk for local recurrences in Dupuytren's contracture in comparison to other

Disclosure: This research received no specific grant from any funding agency in the public, commercial, or not-for-profit sectors. The authors declared no potential conflicts of interest with respect to the research, authorship, and/or publication of this article. The Article Processing Charge will be paid for by the authors.

techniques,¹⁸ but there is no therapy available to avoid recurrences completely. We claim that limited fasciectomy remains the standard therapy for recurrences. Therefore, we examined the outcome of repeated limited fasciectomy in patients with aggressive forms and multiple recurrences of DD.

PATIENTS AND METHODS

Patients

Inclusion criterion was DD with 3 or more surgical interventions on a single hand. Of note, initial surgeries of all patients were not performed in our clinic. Subsequent surgeries were performed in our department.

Measurement of Outcome

For outcome measurement, we examined clinical results including complications, such as infection, circulation disorders of the treated finger, delayed wound healing, and need of extended aftercare. The time from surgical treatment to the end of wound healing (absence of serous spotting on the dressing) for each procedure was recorded.

Mobility of digital joints was examined via range of motion (ROM) and measurement of fingernail to table and fingertip to palm distance. To assess the postoperative clinical outcome of our patient cohort, we took into account the recurrence definition of Felici et al.²⁴ defined as passive extension deficit of more than 20 degrees for at least 1 treated joint, in the presence of a palpable cord, compared with the result at time 0.

Subjective patient satisfaction of hand functional change was queried and objectified by a validated instru-

ment, the Disabilities of the Arm, Shoulder, and Hand (DASH) Measure Score.¹⁹ The DASH was scored so that 0 represented the least disability and 100 the most disability.

Indication and Surgical Technique

Our indication for the repeated surgery was the subjectively described and objectively comprehensible functional deficit of the hand or finger due to contraction and associated patient discomfort.

In all cases, the senior author performed a limited fasciectomy of the affected palmar aponeurosis including deep palmar fibers and fibers to subcutaneous tissue. We also performed microsurgical neurolysis and arterioly-sis by default. Release of the PIP joint was performed as described by Beyermann et al.²⁰ and Belusa et al.²¹ Each patient received a night splint postoperatively for at least the time of wound healing. The procedures performed in the last surgery before examination of clinical results are demonstrated in Table 1.

Ethical Approval

This retrospective study was approved by the ethics committee of Hannover Medical School (No. 2557-2015). All participating patients provided voluntary written informed consent.

RESULTS

We studied 16 patients with a total of 97 invasive treatments including a minimum of 3 limited fasciectomies on a single hand (Fig. 1). Retrospectively, 16 patients [13 male and 3 female, mean age 65 (SD 9)] were examined with DD after more than or equal to 2 previous operations on a single hand. In total, 8 patients underwent fasciec-

Table 1. Left Panel: Patient Characteristics; Right Panel: Procedures Performed in the Last Operation: 14 Arthrolyses, 68 Arteriolyse and Neurolyses

ID	Sex	Age	No. Operations			Site of Last Operation	Last Procedure						
			Left Hand	Right Hand	Total		Arthrolysis	Arteriolyse	Neurolysis	Skin Graft	Kirschner-wire	Other Procedures	
1	m	59	7	2	9	Left	Open	4	4				Arterial anastomosis, local flap
2	m	59	1	6	7	Right	Open	3	3	1			
3	m	51	5	2	7	Left		2	2				Local flap
4	m	64	2	3	5	Right	Closed	4	4				Local flap
5	m	83	0	3	3	Right	Open 3×	6	6	4			Local flap 2×
6	m	66	1	3	4	Right	Closed 2×	4	4				
7	m	74	3	1	4	Left	Open	3	3	1			Local flap
8	m	56	1	3	4	Right	Open	4	4		1		Arterial anastomosis, local flap 3×
9	m	78	5	1	6	Left	Open 2×	4	4	1	1		Exarticulation DV
10	f	60	5	5	10	Right		8	8	1			Local flap 3×
11	m	69	2	7	9	Right	Open	6	6				Arterial anastomosis, local flap 2×
12	m	53	9	2	11	Left							Resection arthrodesis of PIP joint
13	m	67	5	0	5	Left		4	4				Local flap
14	f	66	3	2	5	Left							Exarticulation DV
15	f	62	1	3	4	Right		3	3	2			Arterial anastomosis, local flap
16	m	72	1	3	4	Right	Closed	3	3				

Two patients were treated with temporary K-wire fixation. In 4 cases, arterial anastomosis was performed. Sixteen local flaps including z-plastic, jumping-man plastic, and advancement flaps were used to close minor skin defects. One arthrodesis and 2 amputations were performed in one of several affected fingers. In these cases, the other finger rays were treated with limited fasciectomy. DV, little finger.

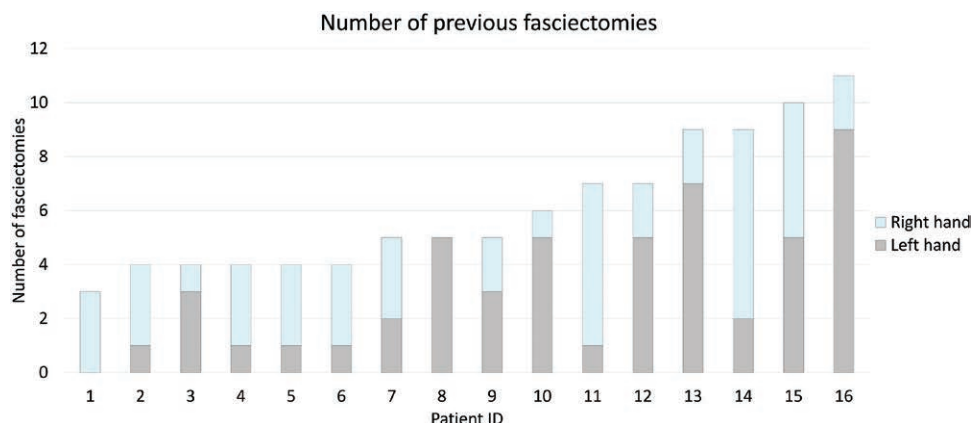


Fig. 1. Number of surgical treatments of each patient including a minimum of 3 limited fasciectomy on a single hand.

tomy 3 times and 8 patients underwent surgery and/or minimally invasive treatment between 4 and 8 times. All patients were affected bilaterally. The average age of onset was 39 years (25–50 years). Three patients had known DD in their family history. One patient had Ledderhose disease in his medical history. The mean follow-up was 40 (SD 26) months.

The examination results of subjective patient satisfaction via mail questionnaire are summarized in Figure 2: 76.9% of the examined patients were satisfied with the results of repeat surgery, whereas 83.3% would have another surgical procedure performed if needed. After treatment in our clinic, 3 patients continued their follow-up treatment by other surgeons close to home.

In 13 of 16 patients, fasciectomy was performed on the PIP joint, followed by the metacarpophalangeal joint (MCP) in the remaining cases (n = 3). The mean improvement for the PIP joint was 59.2 degrees (SD 26.8) and 86.2% (SD 19.9; Table 2).

Reviewing the surgical notes, digital blood vessels were often adherent in fibrotic and scar tissue (Fig. 3). In 4 cases, adhesiolysis severed the artery and required arterial anastomosis (Table 1).

In retrospect, we assessed if there were any wound healing disorders, for example, delayed wound healing, infections, or other complications after the last surgery. In 42.9% wound healing disorders and in 64.3% remain-

ing extension deficits (finger nail table distance > 0 cm) were observed in the immediate postoperative period (Fig. 4). Within 4 weeks, all wounds healed completely, and remaining extension deficits were mostly insignificant (Table 2). Furthermore, we examined the resulting ROM 40 months after our last open surgical treatment. Here, the difference in ROM of the last treated joints was less than or equal to 10 degrees in all cases compared with the immediate postoperative result. We observed no major complications (eg, perfusion disorders postoperatively). In one case, with long-term contracture of the little finger, its amputation was performed after preoperative decision according to the preferences of the patient. A single patient with an affected little finger was insensitive to cold after surgery. Another patient continued treatment with a K-wire infection at a different institution.

In average, DASH scores were 15.6 (SD 20.1) in disability and symptom section 40 months after surgery. In high-performance section, mean DASH scores were 13.3 (SD 27.2) in work section (only 8 of 16 patients were scored) and 31.3 (SD 32.3) in sports/music (only 9 patients of 16 were scored; Fig. 5).

DISCUSSION

Many patients with DD report surgeons’ hesitation to perform further surgery in cases of multiple recurrences.

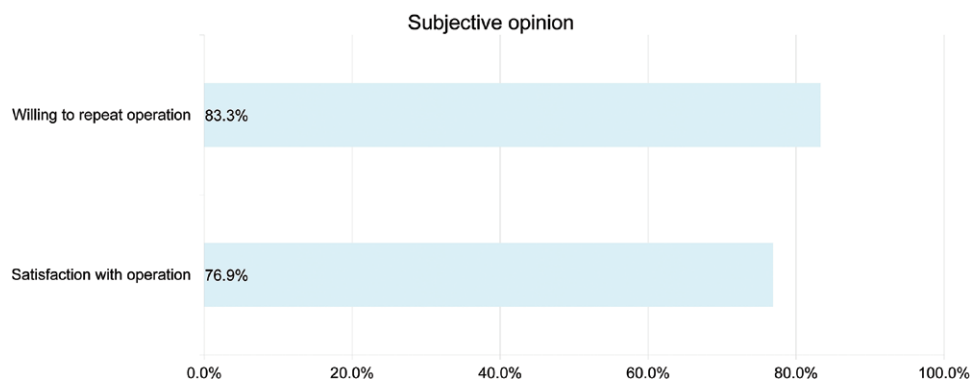


Fig. 2. Shown are the results of patient satisfaction and willingness to repeat surgery if needed.

Table 2. Pre- and Postoperative Active ROM Measurement

ID	Joint	Before	After	Difference (degrees)	Difference (%)
1	PIP DV	45	30	15	33.3
2	PIP DIV	90	35	55	61.1
3	PIP DIII	80	0	80	100.0
4	MCP DII	20	md	md	md
5	PIP DV	90	0	90	100.0
6	PIP DV	90	5	85	94.4
7	PIP DV	90	20	70	77.8
8	PIP DV	90	10	80	88.9
9	PIP DIV	90	0	90	100.0
10	PIP DV	md	0	md	md
11	PIP DIV	60	0	60	100.0
12	PIP DV	md	md	md	md
13	MCP DV	60	10	50	83.3
14	PIP DIII	40	0	40	100.0
15	MCP DV	10	0	10	100.0
16	PIP DIII	55	10	45	81.8
			Mean	59.2	86.2
			SD	26.8	19.9

Extension deficits of last treated joint. Shown are the improvement in degree and the percentage of angle improvement of the operated joints. md, missing data. DII, index finger. DIII, middle finger. DIV, ring finger. DV, little finger.

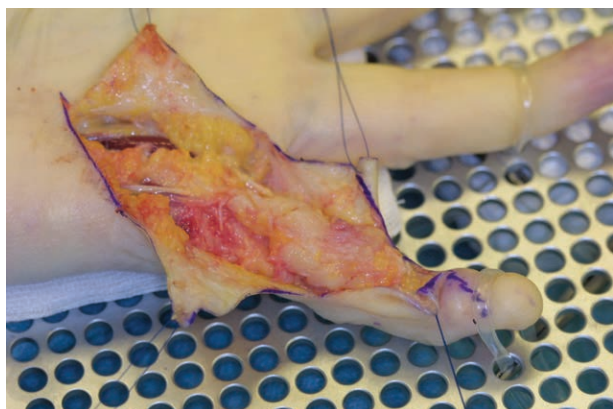


Fig. 3. Intraoperative photographic documentation of digital vessels adhered in cords and scar tissue.

Although these opinions suggest that treatment of recurrence should be avoided due to potential complications of surgery and recurrence rates, we were able to demonstrate success of repeated fasciectomy in DD. Patient satisfaction mainly manifested itself in improvement of ROM and regaining functionality of the hand (Fig. 6A, B). In 15 of 16 patients, no severe postoperative complications were observed with exception of 1 patient with osteomyelitis and resulting finger amputation due to delayed K-wire extraction because of patient noncompliance.

Considering ongoing discussions about the importance of a refined recurrence definition²²⁻²⁴ and due to our retrospective study design, we differentiated between contracture and disease recurrence. Due to missing data from the onset of disease until the initial presentation at our clinic, we could not apply Felici et al.²⁴ definitions of recurrence. Instead, we used the number of surgeries per hand to define the disease history.

Our DASH scores demonstrated a good outcome after 40 months of follow-up. Interestingly, 6 of 8 patients did not exhibit any problems at work. Hunsaker et al.²⁵ reported

DASH scores of 10.1 (SD 14.7) in the general population. In our cohort, we found 5 people with a disability score of greater than or equal to 10.1. We report very good DASH scores in the disability and work section and higher scores in the sports/music section by trend. Ultimately, we demonstrate that patients can benefit from repeated limited fasciectomy. In addition, the functionality of the affected hand can be kept high (Fig. 5).²⁶

Considering that contracture recurrence (not disease recurrence) can be predicted as early as 6 months after surgery for DD,²⁷ we observe excellent medium-term results after limited fasciectomy. Unfortunately, due to our study design, average follow-up varied greatly between 14 and 40 months. However, using the Felici et al.²⁴ definition of recurrence, we did not find any recurrences after 40 months of follow-up. We postulate this is due to the surgical technique as described in the Patients and Methods section performed by our senior surgeon.

The average age of onset of DD was 39 (SD 10) years. However, the exact age may have been earlier, as patients often remembered the date of their first operation but not the onset of their first clinical symptoms. In this cohort, patients had at least 2 risk factors for recurrence as proclaimed by Hindocha et al.,⁷ which are family history, bilateral occurrence, ectopic lesions, male sex, and age of onset less than 50 years.

As digital blood vessels are often adhered or walled in cords and scar tissue, there is a risk of perfusion disorders, especially under treatment of local contracture recurrence. We found enormous scarring with indistinguishable tissues including vessels. To correct recurrent contractions, walled vessels had to be severed in 4 cases. After removing the cords completely, these vessels were reconstructed. It would be interesting to compare these results with those of collagenase-treated recurrences. In contrast to collagenase treatment, open surgical techniques seem safer because structures can be dissected distinctly and preserved. Vessel injuries can be detected and treated immediately as shown in our studies.

Long-term results for treatment with collagenase injection have yet to be reported.¹¹ Little is known about the quality of tissue after collagenase treatment. To date, few studies demonstrate higher recurrence rates compared with open surgery²⁸ (van Rijssen).

Delayed wound healing was found in every second patient (42.9%), but all wounds healed completely within 4 weeks (closed and epithelialized wounds). In 64.3% of our patients, remaining extension deficits were observed. We explain this high rate with the long time of contracture and skin tissue quality. Nevertheless, contractures were corrected as far as possible, and overall patient satisfaction was as high as 76.9%.

Unfortunately, we could not include DASH score differences in this study because of missing DASH scores before our first surgery. Additionally, new alternative patient-reported outcome measurements like The Unité rhumatologique des affections de la main scale have not been applied consistently at time of treatment and there-

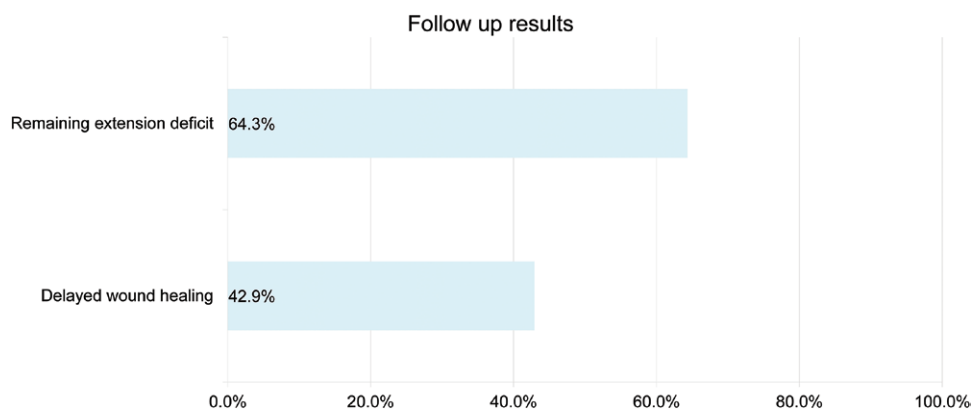


Fig. 4. Follow-up results, that is, wound healing disorders and remaining extension.

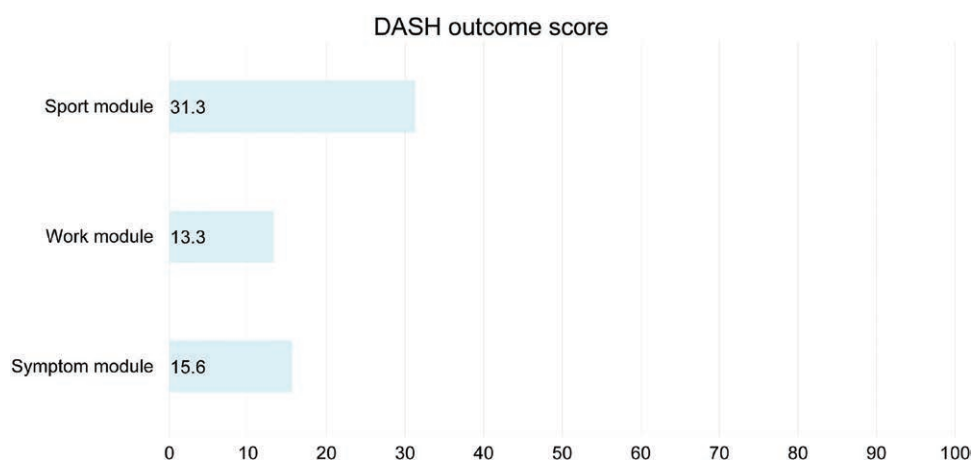


Fig. 5. DASH outcome measurements. Overall scores were very low.

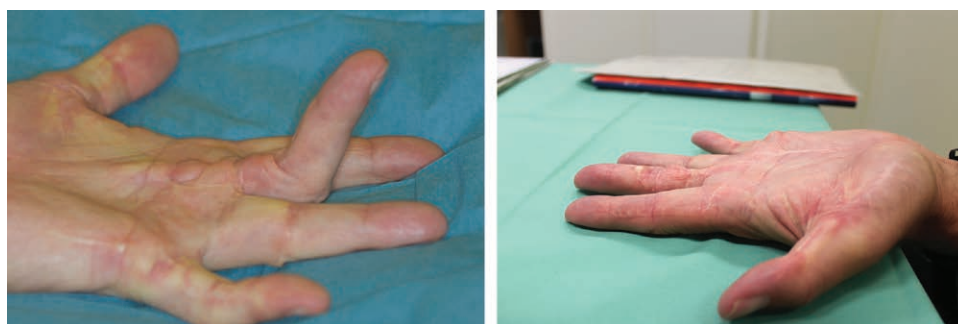


Fig. 6. (A) Pre- and (B) postoperative results of patient (#1).

fore was not collected. However, our results demonstrate that the majority of our patients with rapidly progressive forms of DD can benefit from repeat surgeries.

We want to highlight that the patients observed for this study do not represent the average patient with DD. Our small sample stands for a cohort with highly aggressive forms of the disease with early age of onset and rapid progress. In summary, for these patients, we showed excellent results after recurrent fasciectomy. Patients have to be informed about

the increased but acceptable risk for delayed wound healing in cases of repeated fasciectomies. Remaining extension deficits are to be expected but limited fasciectomy is still likely to be superior to alternative minimal invasive treatments.

Our results suggest that decision for repeated surgery should not depend upon the number of previous surgeries but should rather be an individually based decision taking into account the clinical symptoms and expectations of each patient.

Sören Kömneker, MD

Hanover Medical School
Department of Plastic, Aesthetic
Hand and Reconstructive Surgery
Carl-Neuberg-Str. 1
30625 Hanover
Germany

E-mail: koemneker.soren@mh-hannover.de

REFERENCES

- Hindocha S, McGrouther DA, Bayat A. Epidemiological evaluation of Dupuytren's disease incidence and prevalence rates in relation to etiology. *Hand (N Y)*. 2009;4:256–269.
- Shih B, Bayat A. Scientific understanding and clinical management of Dupuytren disease. *Nat Rev Rheumatol*. 2010;6:715–726.
- Michou L, Lermusiaux JL, Teysseidou JP, et al. Genetics of Dupuytren's disease. *Joint Bone Spine*. 2012;79:7–12.
- Sedic M, Jurisic D, Stanec Z, et al. Functional genomics in identification of drug targets in Dupuytren's contracture. *Front Biosci (Landmark Ed)*. 2010;15:57–64.
- O'Gorman DB, Vi L, Gan BS. Molecular mechanisms and treatment strategies for Dupuytren's disease. *Ther Clin Risk Manag*. 2010;6:383–390.
- Rehman S, Goodacre R, Day PJ, et al. Dupuytren's: a systems biology disease. *Arthritis Res Ther*. 2011;13:238.
- Hindocha S, Stanley JK, Watson S, et al. Dupuytren's diathesis revisited: evaluation of prognostic indicators for risk of disease recurrence. *J Hand Surg Am*. 2006;31:1626–1634.
- Huisstede BM, Hooglyet P, Coert JH, et al.; European HANDGUIDE Group. Dupuytren disease: European hand surgeons, hand therapists, and physical medicine and rehabilitation physicians agree on a multidisciplinary treatment guideline: results from the HANDGUIDE study. *Plast Reconstr Surg*. 2013;132:964e–976e.
- Warwick D, Arner M, Pajardi G, et al.; POINT X Investigators. Collagenase clostridium histolyticum in patients with Dupuytren's contracture: results from POINT X, an open-label study of clinical and patient-reported outcomes. *J Hand Surg Eur Vol*. 2015;40:124–132.
- Zhou C, Hovius SE, Slijper HP, et al. Collagenase clostridium histolyticum versus limited fasciectomy for Dupuytren's contracture: outcomes from a multicenter propensity score matched study. *Plast Reconstr Surg*. 2015;136:87–97.
- Eaton C. Evidence-based medicine: Dupuytren contracture. *Plast Reconstr Surg*. 2014;133:1241–1251.
- Degreef I, De Smet L. Dupuytren's disease: a predominant reason for elective finger amputation in adults. *Acta Chir Belg*. 2009;109:494–497.
- Frueh FS, Calcagni M. [Collagenase-A revolution of Dupuytren's therapy]. *Ther Umsch*. 2014;71:379–384.
- Povlsen B, Povlsen SD. What is the better treatment for single digit Dupuytren's contracture: surgical release or collagenase clostridium histolyticum (Xiapex) injection? *Hand Surg*. 2014;19:389–392.
- Henry M. Dupuytren's disease: current state of the art. *Hand (N Y)*. 2014;9:1–8.
- Rizzo M, Stern PJ, Benhaim P, et al. Contemporary management of Dupuytren contracture. *Instr Course Lect*. 2014;63:131–142.
- Chen NC, Shauver MJ, Chung KC. Cost-effectiveness of open partial fasciectomy, needle aponeurotomy, and collagenase injection for Dupuytren contracture. *J Hand Surg Am*. 2011;36:1826–1834.e32.
- van Rijssen AL, ter Linden H, Werker PM. Five-year results of a randomized clinical trial on treatment in Dupuytren's disease: percutaneous needle fasciectomy versus limited fasciectomy. *Plast Reconstr Surg*. 2012;129:469–477.
- Hudak PL, Amadio PC, Bombardier C. Development of an upper extremity outcome measure: the DASH (disabilities of the arm, shoulder and hand) [corrected]. The Upper Extremity Collaborative Group (UECG). *Am J Ind Med*. 1996;29:602–608.
- Beyermann K, Prommersberger KJ, Jacobs C, et al. Severe contracture of the proximal interphalangeal joint in Dupuytren's disease: does capsuloligamentous release improve outcome? *J Hand Surg Br*. 2004;29:240–243.
- Belusa L, Buck-Gramcko D, Partecke BD. [Results of interphalangeal joint arthrolysis in patients with Dupuytren disease]. *Handchir Mikrochir Plast Chir*. 1997;29:158–163.
- Werker PM, Pess GM, van Rijssen AL, et al. Correction of contracture and recurrence rates of Dupuytren contracture following invasive treatment: the importance of clear definitions. *J Hand Surg Am*. 2012;37:2095–2105.e7.
- Kan HJ, Verrijp FW, Huisstede BM, et al. The consequences of different definitions for recurrence of Dupuytren's disease. *J Plast Reconstr Aesthet Surg*. 2013;66:95–103.
- Felici N, Marcoccio I, Giunta R, et al. Dupuytren contracture recurrence project: reaching consensus on a definition of recurrence. *Handchir Mikrochir Plast Chir*. 2014;46:350–354.
- Hunsaker FG, Cioffi DA, Amadio PC, et al. The American academy of orthopaedic surgeons outcomes instruments: normative values from the general population. *J Bone Joint Surg Am*. 2002;84-A:208–215.
- Kennedy CA, Beaton DE, Solway S, et al. *The DASH Outcome Measure User's Manual*. 3rd ed. Institute for Work & Health (IWH): Toronto; 2011.
- Dias JJ, Singh HP, Ullah A, et al. Patterns of recontracture after surgical correction of Dupuytren disease. *J Hand Surg Am*. 2013;38:1987–1993.
- Peimer CA, Blazar P, Coleman S, et al. Dupuytren contracture recurrence following treatment with collagenase clostridium histolyticum (CORDLESS study): 3-year data. *J Hand Surg Am*. 2013;38:12–22.