

Case report

Pseudozyma aphidis bloodstream infection in a patient with aggressive lymphoma and a history of intravenous drug use: Case report and review of the literature

Angelo Maccaro^a, Renato Pascale^a, Andrea Liberatore^{b,c}, Gabriele Turello^c, Simone Ambretti^c, Pierluigi Viale^a, Monica Cricca^{b,c,d,*}

^a Infectious Diseases Unit, Department of Medical and Surgical Sciences, IRCCS S. Orsola-Malpighi Hospital, University of Bologna, 40138, Bologna, Italy

^b Center for Applied Biomedical Research (CRBA), University of Bologna, 40138, Bologna, Italy

^c Unit of Microbiology, IRCCS S. Orsola-Malpighi Hospital, Via G. Massarenti, 9, 40138, Bologna, Italy

^d Department of Experimental, Diagnostic and Specialty Medicine - DIMES, Alma Mater Studiorum, University of Bologna, 40138, Bologna, Italy



ARTICLE INFO

Keywords:

Pseudozyma aphidis
Fungemia
Intravenous drug use
Basidiomycete yeasts
Antifungal resistance

ABSTRACT

Pseudozyma aphidis is an environmental fungus which causes opportunistic infections in immunocompromised patients. Here we report the case of a 54-year-old, intravenous drug user woman, newly diagnosed to have an aggressive lymphoma, who developed a bloodstream infection caused by *P. aphidis* treated successfully with amphotericin-B therapy. The precise identification was assessed by sequencing. We propose to consider intravenous drug use as a risk factor for invasive infections due to this environmental yeast.

1. Introduction

Yeasts other than *Candida*, such as *Saprochaete* spp, *Cryptococcus* spp, *Malassezia* spp, *Rhodotorula* spp, *Trichosporon* spp, *Pseudozyma* spp etc. are known for having low pathogenicity in immunocompetent hosts, but they cause rare invasive infections in immunocompromised ones or in patients with predisposing conditions such as central venous catheter and parental nutrition [1]. *Pseudozyma* species are environmental Basidiomycete yeasts which belong to the Ustilaginales family, that were mainly studied for their potential industrial application due to their biosurfactant capacities [2]. *Pseudozyma* spp. has been occasionally recognised as a human pathogen, generally affecting immunocompromised patients, and causing mainly bloodstream infections. Infections due to this yeast present some challenges for the polymorphous clinical presentation, the difficult diagnosis, and the limited therapeutic options [3]. Here, we report a *Pseudozyma aphidis* bloodstream infection (BSI) in an intravenous drug user (IVDU) female patient suffering from aggressive lymphoma.

2. Case

A 54-year-old, IVDU woman, with a medical history notable for hepatitis C and metabolic syndrome, was admitted to our hospital for fever, right leg cellulitis and bilateral inguinal lymphadenopathies (day 0). Blood tests showed a normal complete blood count, C-reactive protein was 7.9 mg/dL (reference negative range <0.50), and procalcitonin was negative (day + 1).

At day +2, blood cultures were collected through a peripherally-inserted central catheter (PICC) and tested negative after 7 days of incubation into BACTEC™ Aerobic and Anaerobic Medium (BD, Italy) at 35 °C in the Bactec FX Instrument. After blood collection broad-spectrum antibiotic treatment was started with teicoplanin and ceftazidime (800 mg/day after loading dose, and 6 g/day respectively). PICC became soon unusable due to catheter-related thrombosis, thus it was removed at day +7, and the culture of its tip resulted negative.

In the meantime, diagnostic work-up for lymphadenopathies continued: HIV test, IGRA, syphilis serology, urine PCR for *C. trachomatis* and *N. gonorrhoeae* were all negative. Lymph node excisional biopsy was performed and turned out diagnostic for aggressive lymphoma (follicular lymphoma grade 3B/diffuse large B-cells

* Corresponding author. Infectious Diseases Unit, Department of Medical and Surgical Sciences, IRCCS S. Orsola-Malpighi Hospital, University of Bologna, 40138, Bologna, Italy.

E-mail address: monica.cricca3@unibo.it (M. Cricca).

<https://doi.org/10.1016/j.mmcr.2021.05.002>

Received 18 April 2021; Received in revised form 26 May 2021; Accepted 29 May 2021

Available online 2 June 2021

2211-7539/© 2021 The Authors. Published by Elsevier B.V. on behalf of International Society for Human and Animal Mycology. This is an open access article

under the CC BY-NC-ND license (<http://creativecommons.org/licenses/by-nc-nd/4.0/>).

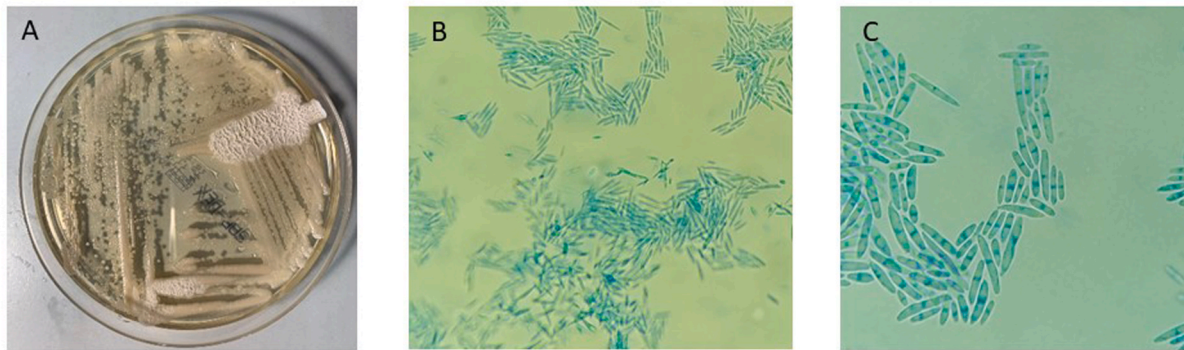


Fig. 1. *Pseudozyma aphidis* on Sabouraud dextrose agar after 5 days of culture at 32 °C (A); microscopic examination with lactophenol cotton blue stain, 20x (B) and 40× (C) magnification. (For interpretation of the references to colour in this figure legend, the reader is referred to the Web version of this article.)

lymphoma).

In the following days, despite antibiotic treatment, fever persisted, and CRP progressively increased up to 13.45 mg/dL. Hence, two blood cultures were collected by venipuncture at day +12 and turned out positive at day +15. At direct Gram stain examination, blastospores with short hyphae and fusiform cells with polar buddings were observed; thus, antifungal treatment with caspofungin (50 mg/day after a 70 mg

loading dose) was started on day + 16.

Blood was subcultured on Sabouraud-dextrose and Chrome Candida agar plates (Vakutainer Kima, Padova, Italy) for 48 hours at 32 °C (Fig. 1). An attempt of identification was performed in triplicate by MALDI-TOF mass spectrometry (Bruker Daltonics, Italy) using the Biotyper Software (BrukerDaltonics). The identification was positive with a low score for *P. Aphidis* (1.680, mean value). Misidentification as

Table 1

Characteristics of patients with *Pseudozyma* spp infections.

Autor, year	Country	N. of cases	Age (years)	Risk factors	Type of infection	Species isolated	Treatment	Outcome
Sugita, 2003 [4]	Thailand	3	NA	NA	BSI	<i>P. antarctica</i> <i>P. parantarctica</i> <i>P. thailandica</i>	NA	NA
Lin, 2008 [9]	USA	1	7	Short bowel syndrome CVC Parenteral nutrition Antibiotic treatment	BSI, CVC-related	<i>P. aphidis</i>	ITZ IV followed by oral ITZ for other 10 days	Survival
Hwang, 2010 [5]	Korea	1	78	Anaplastic astrocytoma	Cerebral abscess after biopsy	<i>Pseudozyma</i> sp	Drainage, no antifungal treatment	Death
Parahym, 2013 [12]	Brazil	1	17	Burkitt lymphoma Neutropenia due to CHT CVC Antibiotic treatment	Fungal pneumonia	<i>P. aphidis</i>	AMB for 10 days, followed by oral VCZ for 15 days	Survival
Mekha, 2014 [6]	Thailand	3	NA	NA	BSI	<i>P. alboarmeniaca</i> , <i>P. crassa</i> , <i>P. siamensis</i>	NA	NA
Prakash, 2014 [7]	India	1	2 days	Neonate CVC Antibiotic treatment	BSI	<i>P. aphidis</i>	AMB for 17 days followed by oral VCZ for 7 days	Survival
Siddiqui, 2014 [10]	USA	1	52	Crohn's disease CVC Antibiotic treatment	BSI, CVC-related	<i>Pseudozyma</i> sp	VCZ for 14 days	Survival
Orecchini, 2015 [13]	Argentina	1	6	Osteosarcoma Neutropenia due to CHT CVC Antibiotic treatment	BSI, CVC-related	<i>P. aphidis</i>	AMB for 14 days	Survival
Herb, 2015 [14]	France	1	68	Metastatic adenocarcinoma of the ampulla of Vater CVC Antibiotic treatment	BSI, possibly CVC-related	<i>P. aphidis</i>	CVC removal AMB for 14 days	Survival
Joo, 2016 [8]	Korea	1	51	AML CVC Antibiotic treatment	BSI	<i>P. aphidis</i>	CVC removal AMB followed by oral ITZ for 3 weeks, then oral VCZ for 4 months	Survival
Pande, 2017 [11]	USA	1	44	CML relapsing after HSCT CVC Antibiotic treatment	BSI and skin lesions	<i>Pseudozyma</i> sp	CVC removal VCZ IV (failed), AMB for 21 days followed by oral VCZ for 3 months	Survival
Our case	Italy	1	54	IVDU, aggressive NHL CVC Antibiotic treatment	BSI (venipuncture, central blood sample NA)	<i>P. aphidis</i>	L-AMB for 14 days after first negative FUBC	Survival

Abbreviations: AMB: amphotericin B, AML: acute myeloid leukemia. BSI: bloodstream infection, CHT: chemotherapy, CVC: central venous catheter, HSCT: hematopoietic stem-cell transplantation, ITZ: itraconazole, NA: not available, NHL: Non-Hodgkin lymphoma, VCZ: voriconazole.

Cryptococcus was obtained with the VITEK®2 Yeast identification card (BioMérieux, Italy). In the end, only sequencing has allowed an accurate identification of fungal isolate by ITS1/4 and NL1/4 primer pairs, targeting rDNA internal transcribed spacer (ITS) region and 28S rDNA, respectively. The sequence obtained showed 99.73% (ITS1) and 99.05% (ITS4) agreement with the exotype of *Pseudozyma aff. aphidis* DSM 101929 (GenBank KX067825.1) for ITS1/4 sequencing and 100% agreement with *Pseudozyma aphidis* strain JCM 10318 (GenBank JN940519.1) for NL sequencing, ITS and NL nucleotide sequences of the isolate were deposited in the GenBank database under the accession number MW750598 and MW750607, respectively.

Antifungal susceptibility testing was assessed by a commercial microdilution test (Micronaut, Bruker, Italy) showing the following MIC values: caspofungin, anidulafungin and micafungin >8 µg/ml, fluconazole, 4 µg/ml, amphotericin B, 0.5 µg/ml, voriconazole, 0.031 µg/ml, posaconazole, 0.031 µg/ml, itraconazole, 0.5 µg/ml. Thus, liposomal amphotericin-B therapy – 3 mg/kg/day, i.e. 200 mg/day – was introduced at day +19, and caspofungin and antibiotic treatment were suspended.

Instrumental examinations, echocardiogram, total-body CT scan and ophthalmoscopy, were performed in order to assess the infection source and potentially septic metastatic emboli. All tests were negative. Blood cultures collected at day +22, after liposomal amphotericin-B initiation, resulted negative as well. After amphotericin-B therapy was started, fever subsided in a few days (+21). Antifungal treatment was suspended at day +36, 14 days after the first negative follow-up blood culture, and no relapse occurred in the following 7 months.

Written informed consent for publication of clinical details was obtained from the patient.

3. Discussion

Pseudozyma spp. are described as environmental yeasts, but they have also been identified as rare human pathogens in immunocompromised patients. Only few data are available about *P. aphidis* in the literature. Since 2003, 15 human infections due to *Pseudozyma* spp have been described [3] of which 9 identified in Asia [4–8], 3 in the US [9–11], 2 in South America [12,13] and 1 in Europe (France) [14]. Our case report is the first described in Italy. Overall, in 13/15 cases (87%) there was a bloodstream infection (BSI) and among BSI, 3/15 were CVC-related; the last 2 cases (2/15) showed a cerebral abscess [5] and pneumonia [12]. Essential clinical data are available for 9/15 (60%) cases [Table 1].

The most common risk factors were hematologic malignancies (3/9, 33%) [8,11,12] and locally invasive or metastatic solid tumours (3/9, 33%) [5,13,14], a CVC in place (8/9, 88%) [7–14], previous antibiotic treatment (8/9, 88%) [7–14], and bowel diseases such as Crohn's and short bowel syndrome [9,10]. Disruption of gastrointestinal mucosal barrier due to chemotherapy mucositis or inflammatory bowel diseases could favour fungal translocation from the gastrointestinal tract to the bloodstream, thus representing an important risk factor for *Pseudozyma* spp invasive infections, especially considering that this yeast may contaminate edible cereals, so it could colonize the gut by oral-faecal route [3].

Pseudozyma aphidis infections might be underdiagnosed, due to the fact that, at the moment, only sequencing allows an accurate identification of this yeast. Misidentifications as *Cryptococcus* have been described with the VITEK 2 (bioMérieux) system [10, 15]. As for our isolate, mass spectrometry analysis suggested *P. aphidis*, but with a low score, which is most likely due to an insufficient number of spectra in the databank. Non-traditional microbiological methods, such as sequencing, correctly identify *Pseudozyma* spp. at species level. In our case, the specific *Albifimbria* species was identified by sequencing of ITS and 28S regions of eukaryotic ribosomal RNA of fungi.

The choice of the first line antifungal therapy is important in case of non-*Candida* yeasts, as many other genera are resistant to caspofungin

and/or azoles. It has been reported that *Pseudozyma* spp showed sensitivity to amphotericin B, decreased sensitivity to azoles and resistance to echinocandins [3]. A notable exception was *P. aphidis*, that proved to be sensitive to voriconazole and posaconazole [7,9,12–14]. The most commonly used antifungal regimen was amphotericin B followed by oral voriconazole or itraconazole [7,8,11,12]. Overall, mortality rates due to *Pseudozyma* spp was very low, and only one patient, who did not receive any treatment, died [5].

Our patient showed some risk factors for *Pseudozyma* spp BSI that have already been described, namely a hematologic malignancy, a broad-spectrum antibiotic treatment, and a CVC in place. However, a CVC-related BSI was not documented, and no chemotherapy had been introduced, so we underline how intravenous drug use may represent a new potential portal of entry for this yeast, assuming that accidental autoinoculation of this environmental yeast can occur.

In conclusion, even though *Pseudozyma* spp infections are very rare and seem to be relatively benign if treated, this opportunistic pathogen shows decreased sensitivity to azoles and resistance to echinocandins, making rapid and correct identification at species level crucial for an efficient therapy. The evaluation of predisposing risk factors, including intravenous drug use, may contribute to the diagnostic work-up.

Ethical form

Written informed consent was obtained for the publication of this case report and any potentially-identifying information/images.

Declaration of competing interest

The authors declare that the research was conducted in the absence of any commercial or financial relationships that could be construed as a potential conflict of interest. All the authors agree on the final version of the manuscript.

Acknowledgements

Not applicable.

References

- [1] M.C. Arendrup, T. Boekhout, M. Akova, J.F. Meis, O.A. Cornely, O. Lortholary, European society of clinical microbiology and infectious diseases fungal infection study group, European confederation of medical mycology. ESCMID and ECMM joint clinical guidelines for the diagnosis and management of rare invasive yeast infections, *Clin. Microbiol. Infect.* 20 (Suppl 3) (2014 Apr) 76–98.
- [2] A. Saika, H. Koike, T. Fukuoka, T. Morita, Tailor-made mannosylerythritol lipids: current state and perspectives, *Appl. Microbiol. Biotechnol.* 102 (2018) 6877–6884.
- [3] J.P. Telles, V.S.T. Ribeiro, L. Kraft, F.F. Tuon, *Pseudozyma* spp. human infections: a systematic review, *Med. Mycol.* 59 (1) (2021 Jan 4) 1–6.
- [4] T. Sugita, M. Takashima, N. Poonwan, N. Mekha, K. Malaitthao, B. Thungmuthasawat, et al., The first isolation of ustilaginomycetous anamorphic yeasts, *Pseudozyma* species, from patients' blood and a description of two new species: *P. parantarctica* and *P. thailandica*, *Microbiol. Immunol.* 47 (2003) 183–190.
- [5] S. Hwang, J. Kim, S. Yoon, Y. Cha, M. Kim, D. Yong, et al., First report of brain abscess associated with *Pseudozyma* species in a patient with astrocytoma, *Korean J. Lab. Med.* 30 (3) (2010 Jun) 284–288.
- [6] N. Mekha, M. Takashima, J. Boon-Long, O. Cho, T. Sugita, Three new basidiomycetous yeasts, *Pseudozyma alboarmeniaca* sp. nov., *Pseudozyma crassa* sp. nov. and *Pseudozyma siamensis* sp. nov. isolated from Thai patients, *Microbiol. Immunol.* 58 (1) (2014 Jan) 9–14.
- [7] A. Prakash, S. Wankhede, P.K. Singh, K. Agarwal, S. Kathuria, S. Sengupta, et al., First neonatal case of fungemia due to *Pseudozyma aphidis* and a global literature review, *Mycoses* 57 (1) (2014 Jan) 64–68.
- [8] H. Joo, Y.G. Choi, S.Y. Cho, J.K. Choi, D.G. Lee, H.J. Kim, et al., *Pseudozyma aphidis* fungaemia with invasive fungal pneumonia in a patient with acute myeloid leukaemia: case report and literature review, *Mycoses* 59 (2016) 56–61.
- [9] S.S. Lin, T. Prankoff, S.F. Smith, M.E. Brandt, K. Gilbert, E.L. Palavecino, et al., Central venous catheter infection associated with *Pseudozyma aphidis* in a child with short gut syndrome, *J. Med. Microbiol.* 57 (2008) 516–518.
- [10] W. Siddiqui, Y. Ahmed, H. Albrecht, S. Weissman, *Pseudozyma* spp catheter-associated bloodstream infection, an emerging pathogen and brief literature

- review, *BMJ Case Rep.* 2014 (2014 Dec 12), <https://doi.org/10.1136/bcr-2014-206369>.
- [11] A. Pande, L.R. Non, R. Romee, C.A.Q. Santos, *Pseudozyma* and other non-*Candida* opportunistic yeast bloodstream infections in a large stem cell transplant center, *Transpl. Infect. Dis.* 19 (2) (2017 Apr).
- [12] A.M. Parahym, C.M. Da Silva, I. Domingos, S.S. Gonçalves, MdM. Rodrigues, V. L. Lins de Morais, et al., Pulmonary infection due to *Pseudozyma aphidis* in a patient with Burkitt lymphoma: first case report, *Diagn. Microbiol. Infect. Dis.* 75 (1) (2013 Jan) 104–106.
- [13] L.A. Orecchini, E. Olmos, G.C. Taverna, O.A. Murisengo, W. Szuzs, W. Vivot, et al., First case of fungemia due to *Pseudozyma aphidis* in a pediatric patient with osteosarcoma in Latin America, *J. Clin. Microbiol.* 53 (11) (2015 Nov) 3691–3694.
- [14] A. Herb, M. Sabou, J.B. Delhorme, P. Pessaux, D. Mutter, E. Candolfi, et al., *Pseudozyma aphidis* fungemia after abdominal surgery: first adult case, *Med. Mycol. Case Rep.* 8 (2015 Mar 6) 37–39.
- [15] E. Gil, M.T. Duràn, J.L. Rodriguez-Tudela, M. Cuenca-Estrella, M. Cartelle, F. Molina, et al., *Pseudozyma* sp.: colonizer of the respiratory tract in critical patients, *Enferm. Infecc. Microbiol. Clín.* 21 (1) (2003 Jan) 65.